

Management of long span partially edentulous maxilla with fixed removable denture prosthesis

MAHILAN I. JEYAVALAN, NARASIMMAN M., VENKATAKRISHNAN C. J., PHILIP JACOB M.

Abstract

Restoration of a long span partially edentulous maxilla with tooth supported prosthesis is challenging because of inherent anatomic limitations and unfavourable biomechanics present after the loss of teeth. A tooth supported fixed-removable prosthesis is a treatment option for restoration of such long span partially edentulous maxillary arches. This prosthesis meets the requirements for esthetics, phonetics, comfort, and hygiene, as well as favourable biomechanical stress distribution to the remaining natural tooth abutments. This article presents a procedure for fabrication of a fixed-removable prosthesis that has cement-retained custom cast bar metal substructure and a ball attachment retained removable superstructure prosthesis.

Keywords: Fixed removable prosthesis, hybrid prosthesis, long span edentulous ridge

Introduction

Several treatment options have been described for long span partially edentulous maxillary arch. Prosthesis design is based on prosthodontic criteria of support, stability, and retention. When considering the anatomic limitations of a partially edentulous maxilla, the need for a properly designed prosthesis that results in favourable biomechanical stress distribution, esthetics, phonetics, comfort, and hygiene is of prime importance.^[1]

Prosthodontic options for these patients include fixed dental prosthesis, an implant retained prosthesis and a removable partial denture. Another option, which has all the advantages of overdenture prosthesis in addition to support, stability, and retention characteristics similar to a fixed prosthesis, is the hybrid or fixed-removable prosthesis. Treatment with a hybrid denture is an affordable choice to fulfil the patient's esthetic demands together with providing good prognosis for the prostheses

and preservation of the remaining dentition. This article presents a restorative option to optimize aesthetics by using auxiliary attachments for retention of the prosthesis.

Case Report

A 55-year-old male patient reported to the department of prosthodontics, Tagore Dental College and Hospital, Chennai, complaining of missing mandibular anterior teeth and unesthetic appearance of maxillary anterior teeth. Clinical examination [Figure 1] revealed missing 13, 31, 41 and 42, grossly decayed 27, mesially tilted 21 and 43, gingival recession with furcation involvement in 36, generalized plaque and calculus and mobile 32.

Radiographic examination [Figure 2] revealed a maxillary radiolucency extending from 15 to 24, involving an impacted 13. The Orthopantomogram also revealed generalized interdental bone loss, grossly decayed 27 and periapical radiolucency in relation to 36.

The patient was diagnosed with the following problems.

- Impacted 13 with Odontogenic Kerato Cyst (OKC)
- Dental caries with chronic pulpitis and gross destruction in 27
- Generalized chronic gingivitis with localized chronic Periodontitis in relation to 32, 36.
- Partially edentulous mandibular arch.

The following teeth were extracted along with the OKC-13, 15, 14, 13, 12, 11, 21, 22, 23, and 27. A tooth supported fixed partial denture was fabricated for replacement of the missing mandibular anterior teeth using 33, 44, and 45 as abutments after extraction of 32.

Treatment options presented for replacement of missing maxillary teeth were a removable cast partial denture and an implant supported fixed dental prosthesis. The patient did not

Department of Prosthodontics, Tagore Dental College and Hospital, Vandalur, Chennai, India

Correspondence: Dr. I. Mahilan Jeyavalan, Department Of Prosthodontics, Tagore Dental College, Rathinamangalam, Vandalur Post, Chennai- 600 048, India.
E-mail mahilan@live.co.uk

Access this article online	
Quick Response Code: 	Website: www.contempclindent.org
	DOI: 10.4103/0976-237X.103625

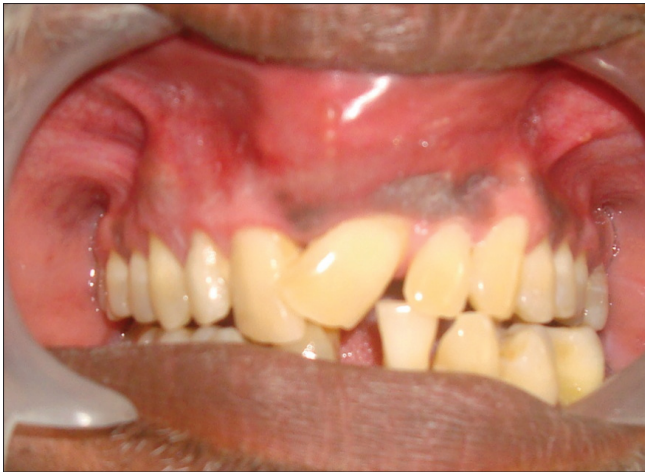

Figure 1: Preoperative intraoral view

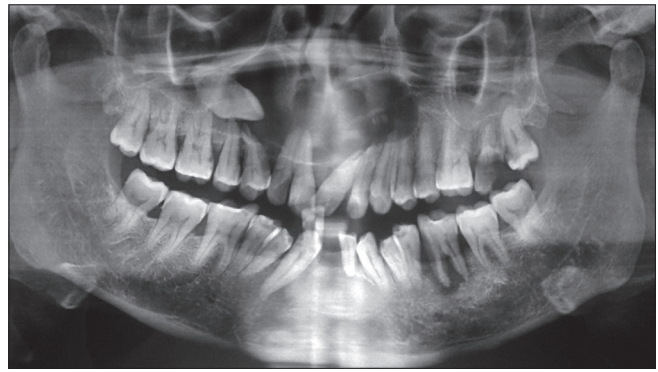


Figure 2: Preoperative orthopantomogram

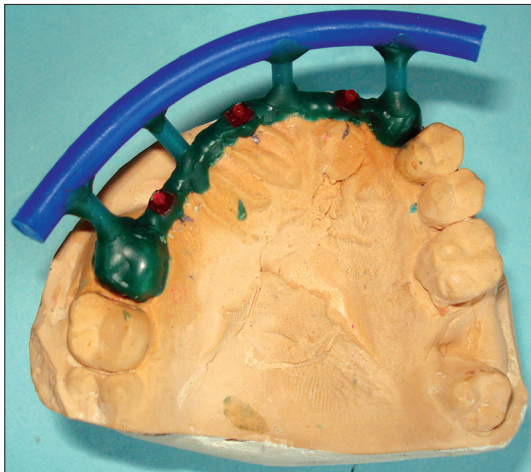


Figure 3: Ball attachment patterns attached on the custom bar

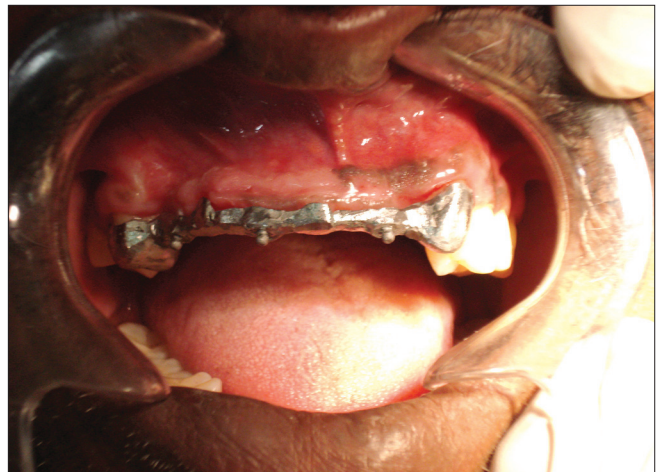

Figure 4: Framework try in

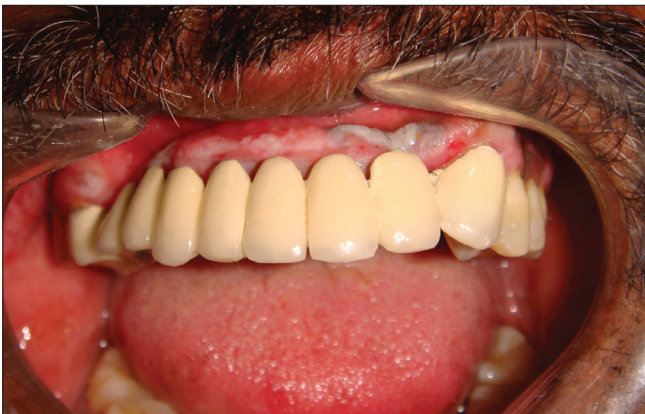

Figure 5: Final prosthesis in the patient

putty, light body impression, was made and poured in die stone (Ultrarock, Kalabhai Karson, India).

A wax pattern (Yeti, GmbH, Germany) was fabricated for metal copings on 16 and 23 with a custom bar in between using the putty index. Ball attachment patterns (Rhein 83, USA)

favour a removable cast partial denture and could not afford the cost of an implant supported fixed dental prosthesis. A tooth supported conventional fixed partial denture could not be used in this situation because of the unfavourable long-term prognosis of a long span tooth supported fixed partial denture.

As an alternative, we suggested a fixed removable dental prosthesis using cement retention for the fixed bar framework and ball retention for the metal fused to ceramic removable partial denture. This treatment option was favourable to the patient.

Diagnostic impression of the maxillary and mandibular arches was made using irreversible hydrocolloid (Zelgan, Dentsply, India). Casts were poured using model plaster (Orthocal, Kalabhai Karson, India) and articulated (Hanau, Whipmix, Fort Collins, USA).

A wax pattern with acrylic teeth replacing the missing teeth was fabricated and patient approval was obtained.

A putty index of this pattern was made using addition silicone putty material (Aquasil, Dentsply, India).

16 and 23 were prepared to receive metal retainers and a

were attached on the wax bar in the position of 15, 13, and 33 [Figure 3].

This pattern was cast using Ni-Cr alloy (Auriloy N.P. Aurium, USA). The metal framework was finished and evaluated in the patient's mouth. Ceramic (Vita VMK Master, Vita Zahnfabrik, Germany) was built up on the metal coping of 16 and 23 and evaluated in the patient's mouth [Figure 4].

This framework was picked up using putty-light body addition silicone impression material and the cast poured using die stone.

A wax pattern was fabricated for the metal copings of 15 to 22 on the metal bar substructure and cast using Ni-Cr alloy.

After the metal framework was finished and evaluated in the patient's mouth, ceramic was built up on the superstructure framework for 15 to 22 and silicone housings (Rhein 83, USA) were incorporated in this removable PFM prosthesis.

The bar framework was cemented on to the abutment teeth using glass ionomer cement (GC Luting and lining cement, GC Corporation, Japan) and the removable PFM framework was attached to the fixed substructure framework using the ball attachment [Figure 5].

Discussion

Partial over dentures supported by natural dentition are not new to dentistry. Many authors have described tissue bars attached to teeth adjacent to the edentulous span and having the pontic section attach onto the tissue bar with a clip or ball attachment.^[2,3]

Lothigius *et al.*^[4-6] have described techniques for fabrication of a hybrid maxillary prosthesis by using attachments. Van Roekel^[7] has described a technique for using electrical discharge machining (spark erosion), which was devised by Sillard, to fabricate a fixed-removable prosthesis. Precision attachment system provides esthetics, resiliency and easy replacement of worn attachment. Partial dentures with these attachments have the advantage of being more stable and retentive than partial dentures without attachments.

A fixed removable prosthesis is an efficient and cost-effective treatment option for long span partially edentulous ridge. There are several advantages to such prosthesis. The adaptation of the secondary casting to the cast bar provides added retention and stability not available in implant- and tissue-supported prostheses. The prosthesis is rigid, it splints the teeth, and lacks cantilevering, which results in a favourable biomechanical design. Proper oral hygiene procedures can be performed by patients, and minimal soft tissue coverage by the superstructure promotes mucosal health. The replaceable housings can be removed and reinserted to provide easy serviceability of the attachment system. The laboratory procedures involved in

fabricating this type of prosthesis do not differ substantially from conventional laboratory techniques.

Although there are many advantages to this prosthesis, proper execution of all clinical and laboratory procedures requires knowledge of important laboratory techniques and clinical skills. The amount of wear of the ball housing, as a result of engagement of the superstructure, must be critically investigated; however, initial observations have not revealed significant wear.

The occlusal scheme recommended for a fixed-removable prosthesis is group function.^[8] The indirect retention provided by the engagement of the superstructure casting with the ball attachment and the direct retention provided by the luting cement may make prosthesis insertion and removal difficult for some patients. Patients are asked to practice insertion and removal of the prosthesis in the presence of the dentist. Patients are also given oral hygiene instructions for plaque control.

Conclusion

The application of a fixed-removable tooth supported prosthesis with a custom made bar and ball attachments, and a porcelain fused to metal superstructure for treatment of maxillary long span partially edentulous jaw has been presented. Clinical and laboratory procedures, and advantages and disadvantages of this type of prosthesis have been discussed.

References

1. Chee WW. Treatment planning: Implant-supported partial overdentures. *J Calif Dent Assoc* 2005;33:313-6.
2. de Carvalho WR, Barboza EP, Caula AL. Implant-retained removable prosthesis with ball attachments in partially edentulous maxilla. *Implant Dent* 2001;10:280-4.
3. Asvanund C, Morgano SM. Restoration of unfavorably positioned implants for a partially edentulous patient by using an overdenture retained with a milled bar and attachments: A clinical report. *J Prosthet Dent* 2004;91:6-10.
4. Lothigius E, Smedberg JI, De Buck V, Nilner K. A new design for a hybrid prosthesis supported by osseointegrated implants: 1. Technical Aspects. *Int J Oral Maxillofac Implants* 1991;6:80-6.
5. Smedberg JK, Lothigius E, Nilner K, De Buck V. A new design for a hybrid prosthesis supported by osseointegrated implants: 2. Preliminary clinical aspects. *Int J Oral Maxillofac Implants* 1991;6:154-9.
6. Kramer A, Weber H, Benzing U. Implant and prosthetic treatment of the edentulous maxilla using a bar-supported prosthesis. *Int J Oral Maxillofac Implants* 1992;7:251-5.
7. Van Roekel NB. Prosthesis fabrication using electrical discharge machining. *Int J Oral Maxillofac Implants* 1992;7:56-61.
8. Davodi A, Nishimura R, Beumer J 3rd. An implant-supported fixed-removable prosthesis with a milled tissue bar and Hader clip retention as a restorative option for the edentulous maxilla. *J Prosthet Dent* 1997;78:212-7.

How to cite this article: Jeyavalan MI, Narasimman M, Venkatakrishnan CJ, Jacob MP. Management of long span partially edentulous maxilla with fixed removable denture prosthesis. *Contemp Clin Dent* 2012;3:314-6.

Source of Support: Nil. **Conflict of Interest:** None declared.