



King Saud University

Saudi Journal of Biological Sciences

www.ksu.edu.sa
www.sciencedirect.com



ORIGINAL ARTICLE

Protective effect of berberine chloride on *Plasmodium chabaudi*-induced hepatic tissue injury in mice



Mohamed A. Dkhil ^{a,b,*}, Saleh Al-Quraishy ^a, Ahmed Al-Shamrany ^a,
Ahmed S. Alazzouni ^b, Mahmoud Y. Lubbad ^{a,c}, Esam M. Al-Shaebi ^a,
Noory T. Taib ^a

^a Department of Zoology, College of Science, King Saud University, Saudi Arabia

^b Department of Zoology and Entomology, Faculty of Science, Helwan University, Egypt

^c General Directorate of Environmental and Occupational Health, Public Health Agency, Ministry of Health, Riyadh, Saudi Arabia

Received 1 November 2014; revised 23 November 2014; accepted 25 November 2014

Available online 3 December 2014

KEYWORDS

Berberine;
Plasmodium chabaudi;
Liver;
Mice

Abstract The present study aimed to investigate the protective role of berberine (BER) against *Plasmodium chabaudi*-induced infection in mice. Animals were divided into three groups. Group I served as a vehicle control. Group II and group III were infected with 1000 *P. chabaudi* infected erythrocytes. Group III was gavaged with 100 µl of 10 mg/kg berberine chloride for 10 days. All mice were sacrificed at day 10 post-infection. The percentage of parasitemia was significantly reduced more than 30%, after treatment of mice with BER. Infection caused marked hepatic injuries as indicated by histopathological alterations as evidenced by the presence of hepatic lobular inflammatory cellular infiltrations, dilated sinusoids, vacuolated hepatocytes, increased number of Kupffer cells and the malaria pigment, hemozoin. These changes in livers led to the increased histological score. Also, infection induced a significant increase in liver alanine aminotransferase and aspartate aminotransferase and a significant increase in the total leucocytic count. Moreover, mice became anemic as proved by the significant decrease in erythrocyte number and haemoglobin content. BER showed a significant protective potential by improving the above mentioned

* Corresponding author at: Zoology Department, College of Science, King Saud University, P.O. Box: 2455, Riyadh 11451, Saudi Arabia. Tel.: +966 14675754; fax: +966 14678514.

E-mail address: mohameddkhil@yahoo.com (M.A. Dkhil).

Peer review under responsibility of King Saud University.



Production and hosting by Elsevier

parameters. Based on these results, it is concluded that berberine could offer protection against hepatic tissue damage.

© 2014 The Authors. Production and hosting by Elsevier B.V. on behalf of King Saud University. This is an open access article under the CC BY-NC-ND license (<http://creativecommons.org/licenses/by-nc-nd/3.0/>).

1. Introduction

Malaria was recognized as a human disease more than 5000 years ago (Sherman, 1999). It continues to be a major health threat in tropic countries. Malaria infects 225 million people and kills 781,000 people, mainly African children, worldwide per annum (Garcia, 2010; WHO, 2010). An estimated 5.1 billion dollars is required to control malaria each year (WHO, 2012).

The liver is known as the site of preerythrocytic development of *Plasmodium* parasites and it is also an important effector against malarial blood stages (Frevert and Nardin, 2008). In particular, the reticular endothelial system of the liver is able to eliminate parasite-derived hemozoin and even *Plasmodium*-infected erythrocytes through phagocytosis (Krücken et al., 2009).

Phillips et al. (1997) reported that, a convenient model to study the role of the liver in malaria is the murine malaria *Plasmodium chabaudi*, which shares several common characteristics with the most dangerous human parasite *Plasmodium falciparum*, causing malaria tropica.

Recently, attention has been focused on the protective role of naturally occurring antioxidants, generally in biological systems (Van Wyk and Wink, 2004; Wunderlich et al., 2014a,b) and specifically against malaria (Mubaraki et al., 2014).

Berberine is a plant alkaloid with a long history of medicinal use in both Ayurvedic and Chinese medicine (Kulkarni and Dhir, 2008; Bhutada et al., 2010). Previous studies have shown that BER has a wide ranging pharmacological and biological activities including anti-protozoal infection (Malik et al., 2014). Also, Dkhil (2014) reported the antischistosomal activity of berberine as well as its ameliorative effect on the induced liver injury due to infection with *Schistosoma mansoni*. The present study aimed to investigate the protective role of berberine against *P. chabaudi*-induced infection in mice.

2. Materials and methods

2.1. Animals

Thirty male Swiss albino mice were bred under specified pathogen-free conditions and fed a standard diet and water *ad libitum*. The experiments were performed only on mice at an age of 10–12 weeks and were approved by state authorities and followed Saudi Arabian rules for animal protection.

2.2. Infection of mice

The strain of *P. chabaudi* was kindly provided by Prof. Wunderlich (Heinrich Heine University, Dusseldorf, Germany). Blood stages of *P. chabaudi* were weekly passaged in Swiss albino mice. Experimental animals were challenged with 1000 *P. chabaudi*-parasitized erythrocytes. Parasitemia was evaluated in Giemsa stained blood smears, and total erythrocytes were counted in a Neubauer chamber.

2.3. Experimental design

Animals were divided into three groups. The first group served as a vehicle control. The second and the third group were infected with 1000 *P. chabaudi*-parasitized erythrocytes. The third group was gavaged with 100 μ l of 10 mg/kg berberine chloride for 10 days (Jahnke et al., 2006). All mice were sacrificed at day 10 post-infection.

2.4. Liver histology

Pieces of the liver were fixed in 10% buffered formalin at room temperature overnight and embedded in paraffin, and 5 μ m sections were stained with hematoxylin and eosin.

For the liver, the extent of histological changes was scored according to Jamshidzadeh et al. (2008) as follows: 0: absent; +: mild; ++: moderate; and +++: severe. The liver activity index was estimated using a modified quantitative Ishak scoring system (Ishak et al., 1995); scores of 1–3 were assigned to cases of minimal liver damage, scores of 4–8 to mild, scores of 9–12 to moderate, and scores of 13–18 to severe cases.

2.5. Hematological studies

Blood was collected into tubes containing ethylene diamine tetra acetic acid for the determination of some important hematological parameters (total erythrocyte count, total leucocytic count and haemoglobin content) using an automatic counter (VET-530 CA Medonic; Medonic, Stockholm, Sweden).

2.6. Biochemical studies

Blood plasma was separated and kept at -20°C until use. Plasma was then analyzed using commercial kits (Biomerieux, Marcy l'Etoile, France) for alanine amino transferase (ALT), aspartate aminotransferase (AST) and alkaline phosphatase (ALP).

2.7. Statistical analysis

One-way ANOVA was carried out. The data were analyzed by using Excel 2007 (Microsoft, USA), and SigmaPlot 2001 (SPSS, USA). $P \leq 0.05$ is considered to be statistically significant. The obtained data were presented as means \pm standard deviation.

3. Results

Parasitemia reached about 40% at day 10 p.i. with *P. chabaudi* (Fig. 1). The percentage of parasitemia was significantly reduced more than 50%, after treatment of mice with berberine (Fig. 1).

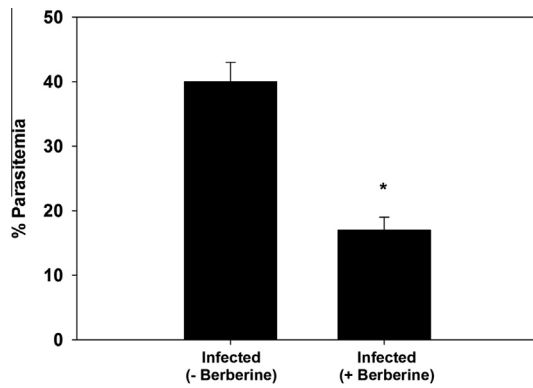


Figure 1 Berberine lowers the percentage of parasitemia at day 10 p.i. with *P. chabaudi*-parasitized erythrocytes. Values are means \pm SD. * $P \leq 0.05$, significant against the non-infected group.

The liver of mice infected with *P. chabaudi* was severely damaged compared to the non-infected mice: The liver became dark-brown and it also appeared with dilated sinusoids containing macrophages and parasitized erythrocytes (Fig. 2). Moreover, there was always a severe inflammation throughout the stroma of the liver compared to the non-infected mice. This lobular inflammation was characterized by the predominant infiltration of lymphocytes, plasma cells, and histiocytes, which were localized in the perivascular and parenchymal areas. Furthermore, apoptotic bodies were rare, and the Kupffer cells were enlarged and, occasionally, appeared to be in the process of phagocytosis of the *P. chabaudi*-parasitized erythrocytes (Fig. 2). All these alterations are considered in the histological liver activity index compiled according to [Ishak et al. \(1995\)](#), which can be categorized as 13–15 for the liver at maximal parasitaemia in comparison with 2 for uninfected controls and to 6–8 in berberine treated mice (Table 1).

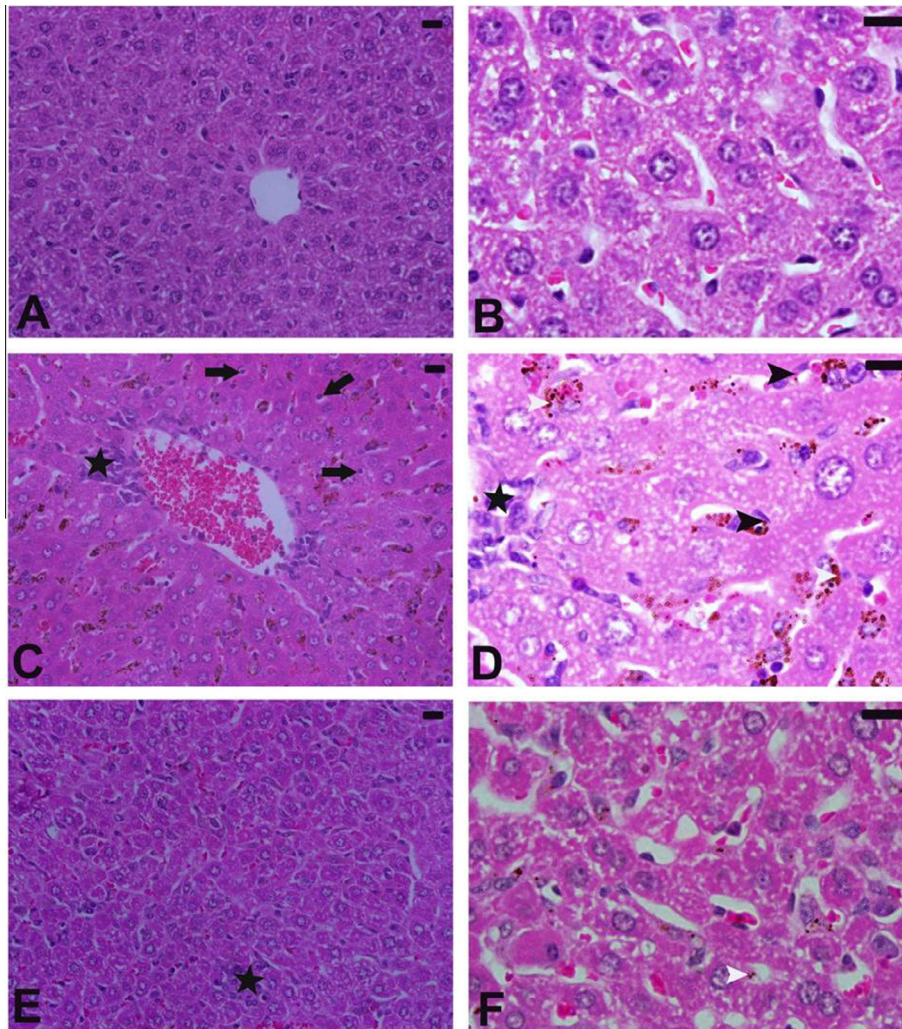


Figure 2 Berberine improved hepatic histopathological changes induced by *P. chabaudi*-parasitized erythrocytes. (A,B) Non-infected liver with normal architecture. (C,D) Infected liver at day 10 p.i.. Pathological changes consist of necro-inflammatory changes dominated by lymphocytes (star), *Plasmodium*-infected erythrocytes, apoptotic bodies (black arrow), hemozoin (white arrow head) in Kupffer cells and *P. chabaudi*-parasitized erythrocytes attached to Kupffer cell. (E,F) Infected-treated mice with berberine. Liver appeared with less lesion and improved tissue damage. Sections are stained with hematoxylin and eosin. Bar = 25 μ m.

Table 1 Berberine induced histopathological changes in liver of mice infected with *P. chabaudi*-parasitized erythrocytes.

Group	Histological activity index ^a	Microscopic observation					
		Necrosis or apoptosis	Hemorrhage	Disorganized sinusoids	Infiltration of lymphocytes	Hyperplasia of Kupffer cells	Hepatocytic swelling
Non-infected	2	0	0	0	0	0	0
Infected (–berberine)	13–15	++	+++	+	+++	++	++
Infected (+berberine)	6–8	+	+	+	+	++	+

^a Modified according to [Ishak et al. \(1995\)](#). Score: 1–3, minimal; 4–8, mild; 9–12, moderate; 13–18, Severe: 0: absent; +: mild; ++: moderate; and +++: severe.

Table 2 Changes in leucocyte count, erythrocyte count and haemoglobin due to berberine treatment of mice infected with *P. chabaudi* infected erythrocytes.

Parameter	Non-infected	Infected	
		(–berberine)	(+berberine)
Leucocytes $\times 10^3/\text{mm}^3$	6.4 \pm 1	9.5 \pm 3.5 ^a	6.5 \pm 3.4 ^b
Erythrocytes $\times 10^6/\text{mm}^3$	7.9 \pm 2	6.1 \pm 0.7 ^a	8.5 \pm 1.7 ^b
Haemoglobin (g/dL)	14.5 \pm 3.4	9.4 \pm 2.4 ^a	13.4 \pm 0.7 ^b

Values are means \pm SD.

^a Significant change at $P \leq 0.05$ with respect to control non-infected mice.

^b Significant change at $P \leq 0.05$ between infected mice (–berberine) and infected mice (+berberine).

Anemia was diagnosed by measuring the haemoglobin content (9.4 g/dL \pm 2.4) and erythrocyte counts ($6.1 \times 10^6/\text{mm}^3 \pm 0.24$) on day 10 p.i., compared with uninfected mice which had erythrocytic counts equal to $7.9 \times 10^6/\text{mm}^3 \pm 0.51$ and haemoglobin values equal to 14.5 g/dL \pm 3.4 ([Table 2](#)). Berberine was able to improve the induced alteration in both of erythrocytic count and haemoglobin content ([Table 2](#)). Also, leucocytes were significantly increased due to *P. chabaudi* infection ([Table 2](#)). Berberine could significantly lower the increased number of leucocytes ([Table 2](#)).

Moreover, infected animals suffered impaired liver function. The levels of ALT and AST enzymes increased significantly when compared to the non-infected animals ([Table 3](#)) while the level of ALP was not significantly changed. The levels of ALT and AST were improved after berberine treatment ([Table 3](#)).

4. Discussion

Mice infected with *P. chabaudi* are characterized by parasitemia reaching about 40% of infected erythrocytes and the liver became inflamed. Berberine was able to reduce the parasitemia by about 50% indicating its antimalarial effect. The berberine induced a clearance of malaria parasites. This clearance may be mediated by both acquired and innate immune responses ([Trubowitz and Mazek, 1968](#)). [Wunderlich et al. \(2014a,b\)](#) reported that “The liver-produced cytokines are not only important for the local response in the liver, but also have presumably an impact for the systemic response to blood-stage malaria”.

Anaemia is the major clinical sign and cause of mortality in animals with malaria infection where malaria parasites, invade

Table 3 Changes in ALT, AST and ALP due to berberine treatment of mice infected with *P. chabaudi* infected erythrocytes.

Parameter	Non-infected	Infected	
		(–berberine)	(+berberine)
ALT (U/L)	58.5 \pm 4	115 \pm 23 ^a	93 \pm 11 ^{a,b}
AST (U/L)	210 \pm 30	396 \pm 18 ^a	269 \pm 63 ^{a,b}
ALP (U/L)	132 \pm 48	90 \pm 26	100 \pm 42

Values are means \pm SD.

^a Significant change at $P \leq 0.05$ with respect to control non-infected mice.

^b Significant change at $P \leq 0.05$ between infected mice (–berberine) and infected mice (+berberine).

erythrocytes of infected animals, resulting in the destruction of the parasitized erythrocytes. In this study, berberine was able to significantly increase the reduced number of erythrocytes as well as the haemoglobin content.

[Wunderlich et al. \(2005\)](#) reported that, the liver is considered to be an effector against *P. chabaudi* infection. The presence of hemozoin granules formed by the intraerythrocytic parasitic stages of *P. chabaudi* liberated during the digestion of haemoglobin by the parasite was intensively present in the liver sinusoids ([Prada et al., 1996](#)). Also, [Schwarzer et al. \(2003\)](#) reported that, accumulation of hemozoin granules causes a decline of phagocytosis after a while, as hemozoin has been shown to exhibit an inhibitory effect on the activity of macrophages.

Kupffer cells constitute about 70–80% of the total macrophages of the reticular-endothelial system. Kupffer cells are able to phagocytose both parasitized red blood cells (pRBC) and hemozoin. In this study, berberine is able to regulate the immune response and increase the number of macrophages to fade the parasite ([Kim et al., 2003](#)).

P. chabaudi induced a remarkable cellular infiltration in the hepatic tissue. The abundance of leucocytes, in general, and lymphocytes, in particular, are a prominent response of body tissues facing any injurious impacts ([Wunderlich et al., 2005](#)). Other evidences of the induced inflammatory response by such infection were in the form of increased activities of plasma enzymes of alanine and aspartate transaminases. BER acts as an anti-inflammatory agent and could reduce these inflammatory events induced by the parasite ([Küpele et al., 2002](#)).

Collectively, it appears that berberine has a potential protective role against malarial infection which can be used in controlling the disease.

Acknowledgment

The authors would like to extend their sincere appreciations to the Deanship of Scientific Research at King Saud University for its funding this Research group No. (RG-1435-198).

References

- Bhutada, P., Mundhada, Y., Bansod, K., Dixit, P., Umathe, S., Mundhada, D., 2010. Anticonvulsant activity of berberine, an isoquinoline alkaloid in mice. *Epilepsy Behav.* 18, 207–210.
- Dkhil, M.A., 2014. Role of berberine in ameliorating schistosoma mansoni-induced hepatic injury in mice. *Biol. Res.* 47, 8.
- Frevert, U., Nardin, E., 2008. Cellular effector mechanisms against *Plasmodium* liver stages. *Cell Microbiol.* 10 (10), 1956–1967.
- Garcia, L.S., 2010. Malaria. *Clin. Lab. Med.* 30, 93–129.
- Ishak, K., Baptista, A., Bianchi, L., Callea, F., Degroote, J., Gudat, F., Denk, H., Desmet, V., Korb, G., Macsween, R.N.M., Phillips, M.J., Portmann, B.G., Poulsen, H., Scheuer, P.J., Schmid, M., Thaler, H., 1995. Histological grading and staging of chronic hepatitis. *J. Hepatol.* 22, 696–699.
- Jahnke, G.D., Price, C.J., Marr, M.C., Myers, C.B., George, J.D., 2006. Developmental toxicity evaluation of berberine in rats and mice. *Birth Defects Res. (Part B)* 77, 195–206.
- Jamshidzadeh, A., Baghban, M., Azarpira, N., Bardbori, A.M., Niknahad, H., 2008. Effects of tomato extract on oxidative stress induced toxicity in different organs of rats. *Food Chem. Toxicol.* 46, 3612–3615.
- Kim, T.S., Kang, B.Y., Cho, D., Kim, S.H., 2003. Induction of interleukin-12 production in mouse macrophages by berberine, a benzodioxoloquinoline alkaloid, deviates CD4 T cells from a Th2 to a Th1 response. *Immunology* 109, 407–414.
- Krücken, J., Delic, D., Pauen, H., Woytalla, A., El-Khadragy, M., Dkhil, M.A., Mossmann, H., Wunderlich, F., 2009. Augmented particle trapping and attenuated inflammation in the liver by protective vaccination against *Plasmodium chabaudi* malaria. *Malar. J.* 8, 54–67.
- Kulkarni, K.S., Dhir, A., 2008. On the mechanism of antidepressant-like action of berberine chloride. *Eur. J. Pharmacol.* 589, 163–172.
- Küpeli, E., Koşar, M., Yeşilada, E., Hüsnü, K., Başer, C., 2002. A comparative study on the anti-inflammatory, antinociceptive and antipyretic effects of isoquinoline alkaloids from the roots of Turkish berberis species. *Life Sci.* 72, 645–657.
- Malik, T.A., Kamili, A.N., Chishti, M.Z., Tanveer, S., Ahad, S., Johri, R.K., 2014. In vivo anticoccidial activity of berberine [18, 5,6-dihydro-9,10-dimethoxybenzo(g)-1,3-benzodioxolo(5,6-a) quinoxalinium] – an isoquinoline alkaloid present in the root bark of *Berberis lycium*. *Phytomedicine* 21 (5), 663–669.
- Mubaraki, M.A., Dkhil, M.A., Al-Shaebi, E.M., Lubbad, M.Y., Ibrahim, K.E., Al-Quraishy, S., 2014. The protective effect of pomegranate, *Punica granatum*, on murine malaria. *Pak. J. Zool.* 46, 1345–1350.
- Phillips, R.S., Brannan, L.R., Balmer, P., Neuville, P., 1997. Antigenic variation during malaria infection – the contribution from the murine parasite *Plasmodium chabaudi*. *Parasite Immunol.* 427–434.
- Prada, J., Malinowski, J., Müller, S., Bienzle, U., Kremsner, P.G., 1996. Effects of *Plasmodium vinckei* hemozoin on the production of oxygen radicals and nitrogen oxides in murine macrophages. *Am. J. Trop. Med. Hyg.* 54, 620–624.
- Schwarzer, E., Kühn, H., Valente, E., Arese, P., 2003. Malaria-parasitized erythrocytes and hemozoin nonenzymatically generate large amounts of hydroxy fatty acids that inhibit monocyte functions. *Blood* 101, 722–728.
- Sherman, I.W., 1999. *Plasmodium*. In: *Nature Encyclopedia of Life Sciences*. Nature Publishing Group, London, <<http://www.els.net/>>.
- Trubowitz, S., Mazek, B., 1968. *Plasmodium falciparum*: phagocytosis by polymorphonuclear leukocytes. *Science* 162, 273–274.
- Van Wyk, B.E., Wink, M., 2004. *Medicinal Plants of the World: An Illustrated Scientific Guide to Important Medicinal Plants and Their Uses*. Timber Press, Portland, OR, USA, 480p.
- WHO, 2010. *World Malaria Report*. World Health Organization, Geneva.
- WHO, 2012. *World Health Organization, World Malaria Report: 2012*. World Health Organization, Geneva, pp. 260.
- Wunderlich, F., Al-Quraishy, S., Dkhil, M.A., 2014a. Liver-inherent immune system: its role in blood-stage malaria. *Front. Microbiol.* 4, 559.
- Wunderlich, F., Al-Quraishy, S., Steinbrenner, H., Sies, H., Dkhil, M.A., 2014b. Towards identifying novel anti-Eimeria agents: trace elements, vitamins, and plant-based natural products. *Parasitol Res.* 113 (10), 3547–3556.
- Wunderlich, F., Dkhil, M.A., Mehnert, L.I., Braun, J.V., El-Khadragy, M., Borsch, E., Hermsen, D., Benten, W.P., Pfeffer, K., Mossmann, H., Krücken, J., 2005. Testosterone responsiveness of spleen and liver in female lymphotoxin-beta receptor-deficient mice resistant to blood-stage malaria. *Microbes Infect.* 7, 121–129.