



Open Access

ORIGINAL ARTICLE

Operational Andrology

# Anatomical retroperitoneoscopic retroperitoneal lymph node dissection for clinical stage I nonseminomatous germ cell tumors: initial operative experience

Kai Yao, Zai-Shang Li, Fang-Jian Zhou, Zi-Ke Qin, Zhuo-Wei Liu, Yong-Hong Li, Hui Han

To introduce the technique of anatomical retroperitoneoscopic retroperitoneal lymph node dissection (ARRPLND) was performed in 12 consecutive patients with a clinical stage I nonseminomatous germ-cell tumor (NSGCT) between February 2008 and October 2010. All procedures were performed using a modified template nerve-sparing approach. The retroperitoneal space was adequately expanded using double gasbags. After the retroperitoneal fat was cleared, two relatively bloodless planes were entered consecutively to expose the lymph node and permit dissection. Dissection proceeded first in the plane between the anterior renal fascia and posterior peritoneum, and secondly in the avascular plane between the posterior renal fascia and transversalis fascia. The proximal spermatic vein was clipped at the initial stage. En bloc resection of the lymph tissue and fat between the anterior renal fascia and posterior renal fascia were performed. Three patients (25%) had pathologic stage IIA disease and received adjuvant chemotherapy. No recurrence was observed during follow-up ranging from 26 to 58 months. The median operative time was 205 min (range: 165–430 min) and median estimated blood loss was 320 ml (range: 100–1200 ml). There were two intraoperative complications (Clavien grade II) and one open conversion due to perforation of the peritoneum. Postoperative complications (Clavien I) developed in three patients. Normal antegrade ejaculation recovered by 1 month following the operation. Our preliminary results indicate that ARRPLND is technically feasible and associated with satisfactory clinical outcomes for clinical stage I NSGCT. Further studies are necessary to evaluate this technique.

*Asian Journal of Andrology* (2014) 16, (136–139); doi: 10.4103/1008-682X.122188; published: 16 December 2013

**Keywords:** nonseminomatous; retroperitoneoscopic; retroperitoneal lymph node; testicular cancer

## INTRODUCTION

The optimal treatment of clinical stage I (CS I) testicular cancer, including the role of retroperitoneal lymph node dissection (RPLND), remains controversial. Deciding between possible therapeutic options is based on an analysis of cost, risk and benefits of the treatment, and the likelihood of patient compliance to follow-up. RPLND is considered an optional staging procedure in low stage nonseminomatous germ-cell tumors (NSGCT).<sup>1</sup> As 70% of patients undergoing RPLND or chemotherapy have no metastases and are thus treated unnecessarily, a minimally invasive approach such as laparoscopic RPLND is highly attractive. Nevertheless, controversies associated with laparoscopic RPLND still exist, including the curative *versus* diagnostic intent and variable templates. Regarding the usefulness of laparoscopic RPLND, the European Association of Urology guidelines state: “If there is a rare indication to perform a staging RPLND, a laparoscopic or robot-assisted RPLND is feasible in expert hands”.<sup>2</sup>

Typically, laparoscopic RPLND has been performed via either a transperitoneal or a retroperitoneoscopic approach. Despite debate regarding the advantages and disadvantages of the two approaches, the transperitoneal approach is often preferred by surgeons. Histological

and anatomical studies revealed that the perirenal space is made up of a single multilaminated structure as well as the vascular compartment of the retroperitoneum, including all primary landing sites of lymph node metastases from testicular cancer.<sup>3–5</sup> From an oncologic standpoint, the retroperitoneoscopic approach may be more appropriate for en bloc removal of lymphatic tissue.

In this study we introduce the anatomical retroperitoneoscopic RPLND (ARRPLND) technique; a novel approach for treating testicular cancer. Via the interfascial plane of the retroperitoneum, the ARRPLND technique provides access to the great vessels and retroperitoneal lymph nodes in a retroperitoneal manner. We report our experience with ARRPLND for CS I nonseminomatous testicular cancer in 12 consecutive patients.

## PATIENTS AND METHODS

### Clinical data

A total of 215 patients with nonseminomatous tumors were treated at Sun Yat-Sen University Cancer Center from February 2008 to October 2010, among whom 105 had CS I NSGCT. Of the 105 patients, 48 were under surveillance, 30 underwent RPLND and 27 underwent

chemotherapy after orchidectomy. After obtaining approval from our institutional review board, we performed a retrospective review of the medical records of 12 patients who underwent ARRPLND for CS I NSGCT of the testes.

All patients had previously undergone radical orchiectomy, including eight of the left and four of the right testicle. The average time interval from orchiectomy to RPLND was 4.8 weeks (range: 3–6 weeks). All cases were preoperatively staged using tumor markers ( $\alpha$ -fetoprotein,  $\beta$ -human chorionic gonadotropin and lactate dehydrogenase), computed tomography (CT) of the abdomen/pelvis and chest CT or X-ray. Staging was performed according to the 2009 TNM system of the International Union Against Cancer (UICC).<sup>6</sup> All patients had CS I disease and negative serum tumor markers before RPLND, and most were categorized as high risk for occult metastasis due to presence of lymphovascular invasion or a predominant component of embryonal carcinoma. Patients were counseled regarding the various treatment options and were informed of the novelty of the ARRPLND technique as well as the plan to switch intraoperatively to laparotomy if complications arose.

A single surgeon (Hui Han) performed all procedures. Before initiation of this procedure, the surgeon had performed >30 open RPLNDs and >500 laparoscopic surgeries. Data from all patients undergoing ARRPLND were prospectively recorded. Postoperative complications were stratified into five grades according to the modified Clavien classification system.

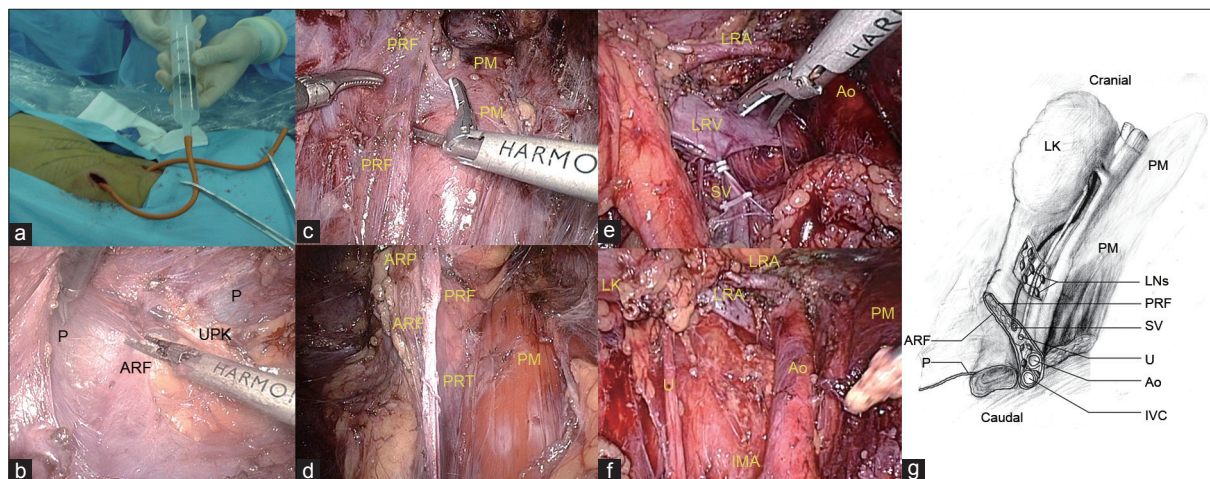
### Treatment

Patients were placed under general anesthesia while in the lateral decubitus position. A 2 cm skin incision was made below the 12<sup>th</sup> rib in the posterior axillary line, bounded by the lateral edges of the latissimus dorsi and external oblique muscles. A canal was created down to the retroperitoneal space, and the peritoneum was pushed forward by an index finger. Under palpation of the index finger that was introduced via the primary access, a 5-mm or 10-mm trocar was inserted under the subcostal margin in the anterior axillary line. Also, a 10-mm trocar was placed directly above the iliac crest in the midaxillary line for placement of the laparoscope. Two homemade balloon dissectors were inserted through the first and third skin incision and inflated over 3–5 min with

800 ml of air. The inflated balloon dissectors created the retroperitoneal working space (**Figure 1a**). A pneumoretroperitoneal pressure of 15 mmHg was achieved by instilling carbon dioxide through the insufflation channel of the port.

The retroperitoneal fat tissue outside of Gerota's fascia is sharply dissected near the diaphragm until it prolapses downward to the iliac fossa. The lateral conical fascia was exposed and incised widely along the border of quadratus lumborum. We prefer to begin the first dissection on a plane between the anterior renal fascia and the posterior peritoneum located at the superomedial side of the upper kidney pole, a potential anatomical plane (**Figure 1b**). The second dissection plane is between the posterior renal fascia and the surface of the psoas major and quadratus lumborum muscles, meeting laterally with the first dissection plane laterally (**Figure 1c and g**). The wide longitudinal incision further opens the retroperitoneal space thereby adding to the effect of the CO<sub>2</sub> insufflation in allowing retraction of the peritoneum and greater exposure of anatomical landmarks. The psoas muscle was exposed up to the level of the diaphragm, abdominal aorta or vena cava, allowing access to the renal hilum. This location represented the cranial borderline of retroperitoneal lymphadenectomy. The lymphatic and fat tissue is dissected en bloc between the anterior and posterior renal fascia to the bifurcation of the abdominal aorta (left) or inferior vena cava (right; **Figure 1d**). The spermatic vein is exposed and clipped at its confluence to the renal vein on the left or to the vena cava on the right (**Figure 1e**). Next, the ureter was isolated and retracted medially. Lymphadenectomy was performed within the boundaries described by Weissbach and Boedefeld,<sup>7</sup> including dissection of the lumbar vessels and removal of the posterior lymphatic tissue (**Figure 1f**). On the right side, retroperitoneal dissection also included the interaortocaval zone. After ligation of the posterior lumbar veins, the irrigation/suction device can be used to retract the vena cava anteriorly, and the interaortocaval nodes can be removed. Sympathetic chains were preserved and an effort was made to spare all efferent nerves. The last step of the procedure involved dealing with the spermatic vessels, which were followed down to the spermatic cord stump in the internal inguinal ring.

The resected tissue was placed in an entrapment sack and retrieved through the posterior-axillary trocar port site. Air pressure was



**Figure 1:** Left anatomical retroperitoneoscopic retroperitoneal lymph node dissection (ARRPLND). (a) Two balloon dissectors were placed through the first and third skin incision and subsequently inflated to create the retroperitoneal working space. (b) First dissection plane between the posterior peritoneum (p) and anterior renal fascia (ARF) at the superomedial side of the upper kidney pole (UPK) and the surface of psoas muscle (PM). (c) Second dissection plane between the posterior renal fascia (PRF) and the surface of psoas muscle (PM). (d) The lymphatic tissue and fat is dissected en bloc between the anterior and posterior renal fascia (ARF and PRF, respectively). (e) The spermatic vein (SV) is exposed and clipped at its confluence to the left renal vein (LRV). (f) Endoscopic view after ARRPLND. (g) Schematic drawings of the anatomy of fascial planes.

decreased to 5–6 mmHg to identify potential bleeding and/or confirm complete hemostasis. The operative field was routinely drained for 2 days. Operative time was defined as the time from skin incision to skin closure. Patients with pathologic stage II disease received two postoperative cycles of cisplatin-based chemotherapy.

**Data collection and follow-up**

In all patients, follow-up examinations were performed at 3-month intervals during the first 2 years, 6-month intervals for years 3 and 4, and annually thereafter. Follow-up examination included medical history, physical examination, serum tumor markers and chest radiography. Annual abdominopelvic CTs were recommended for 5 years. The most recent follow-up of patients was conducted via phone interview.

**RESULTS**

The patient characteristics and treatment outcomes were listed in **Table 1**. A median number of 26 nodes were removed per patient. A total of two intraoperative complications (17%) and a single open conversion (8%) were noted. Complications included injuries (Clavien grade II) to the renal and inferior mesenteric arteries, which were repaired laparoscopically without further sequelae. The open conversion was performed due to a perforation of the peritoneum (Clavien grade I). Two patients (17%) received intraoperative blood transfusions. Minor (Clavien grade I) postoperative complications developed in three patients (25%), including a wound infection, chylous ascites and fever. Postoperative convalescence was uneventful. Average time to oral intake and ambulation were 1.2 and 1.0 days, respectively. Antegrade ejaculation was preserved in all patients. No recurrences were noted following a median follow-up was 46 months.

**DISCUSSION**

Ongoing controversy exists regarding the best management option for patients with CS I NSGCT. Approximately 25%–30% of patients with CS I NSGCT will have metastatic disease spread to the retroperitoneum that is undetected by radiographic imaging.<sup>8</sup> The European Association of Urology guidelines state: “In low-risk patients not willing (or suitable) to undergo surveillance, adjuvant chemotherapy or nerve-sparing RPLND are treatment options.”<sup>2</sup> In this small (<10%)

subgroup of patients with CS I NSGCT, laparoscopic RPLND has been demonstrated to be a feasible, safe and effective treatment option at large-volume institutions with experienced laparoscopic surgeons.<sup>9–11</sup> A meta-analysis of 34 contemporary laparoscopic RPLND articles revealed that modified templates were used in all of the laparoscopic RPLND reports.<sup>1</sup> Given that the oncological efficacy of template-limited dissection has recently been reassessed due to concerns regarding extratemplate disease,<sup>10,12</sup> all patients in our series were treated with a modified unilateral template dissection.<sup>7</sup>

**Surgical treatments**

Due to its inherent advantages, including a wider working space and familiar anatomy, transperitoneal laparoscopic RPLND is often preferred by many surgeons.<sup>9,10</sup> However, the retroperitoneal approach appears to be more appropriate for en bloc RPLND, which can clearly demonstrate the anatomy of the perirenal fascial structure and provide anatomical access to the retroperitoneal lymph nodes. The ARRPLND technique was developed in February of 2008 and consists of three main technical points: (i) creating the retroperitoneal working space with two balloon dissectors, (ii) initially ligating the proximal end of the spermatic vein and subsequently dissecting it distally and (iii) easily entering into two relatively bloodless fascial planes for en bloc lymph node dissection. Using these techniques we have achieved good surgical results.

First, we used two balloon dissectors to create the retroperitoneal working space. The development of the retroperitoneal space is crucial for obtaining a wide surgical view during retroperitoneoscopic RPLND. In prior reports, the retroperitoneal space has been created bluntly using the forefinger<sup>11</sup> or by inflating a single distension balloon within iliac fossa,<sup>13</sup> both of which provided less space and poor visibility of anatomical landmarks. These methods were used for the initial two patients and resulted in difficulty achieving sufficient retroperitoneal working space. Accordingly, two balloon dissectors were subsequently used to create adequate retroperitoneal working space at the level of lower pole of kidney and iliac fossa.

Second, dissecting the lymph node en bloc between two relatively bloodless fascial planes is the key to the surgical design. An innovative surgical technique often requires the reconsideration of traditional surgical anatomy. The retroperitoneum is bounded by the posterior parietal peritoneum, transversalis fascia and perirenal fascia. The lateroconal fascia emerges from Gerota’s fascia at the fascial trifurcation.<sup>5</sup> The testicular lymphatics ascend with the testicular vessels. At the level where the spermatic vessels cross the ureter, the lymphatics deviate medially from the spermatic vessels and terminate in the paraaortic and pericaval lymph nodes.<sup>14</sup> The paraaortic and pericaval retroperitoneal lymph nodes connect with small lymph nodes and a rich network of lymphatics in the perinephric space that involves the interfascial planes. The anterior and posterior renal fascial layers approximate one another as the cone of perirenal fat diminishes in volume inferiorly.<sup>5</sup>

Based on anatomical study we confirmed that a relatively bloodless potential plane exists between the anterior renal fascia and posterior peritoneum, as well as the posterior renal fascia and transversalis fascia. In prior studies, the retroperitoneoscopic RPLND is initiated by complete incision of Gerota’s fascia, which does not provide a clear anatomic dissection plane or allow the en bloc removal of the lymph nodes.<sup>11,14</sup> Once the retroperitoneal fat was cleared off, the lateral conical fascia were exposed and two relatively bloodless planes were entered and lymphatic tissue and fat were dissected en bloc. Our ARRPLND technique includes the following features: en

**Table 1: Patient demographic and outcomes data**

Characteristics	Median	IQR	n (%)
Age, year	32	25–41	NA
BMI, kg m <sup>-2</sup>	24	21–27	NA
Operative time, min	205	165–430	NA
Estimated blood loss, ml	320	100–1200	NA
Lymph node yield	26	22–31	NA
Length of stay, day	3	2–6	NA
Follow-up, month	46	26–58	NA
Left side	NA	NA	8 (66)
Right side	NA	NA	4 (33)
Orchiectomy histology			
Mixed	NA	NA	6 (50)
Pure embryonal	NA	NA	2 (17)
Pure teratoma	NA	NA	1 (8)
Pure yolk sac	NA	NA	3 (25)
LVI	NA	NA	6 (50)
RPLND pathology positive	NA	NA	3 (25)
Anterograde ejaculation	NA	NA	12 (100)

BMI: body mass index; IQR: interquartile range; LVI: lymphovascular invasion; NA: not applicable; RPLND: retroperitoneal lymph node dissection.

bloc RPLND between fascial layers, entry into relatively bloodless fascial planes, and the dissection and removal en-bloc of retroaortic or retrocaval tissue.

Third, the proximal end of spermatic vein was ligated early in the procedure. In prior studies, the spermatic vein is dissected free along its entire course starting at the internal inguinal ring.<sup>7,9-11,15,16</sup> Anatomic studies revealed that the testicular lymphatic vessels accompany the spermatic vessels through the internal ring to the point where those vessels cross the ureter and to their origin firstly.<sup>14</sup> In our study, the spermatic vein was first ligated at the proximal end and then followed caudally to the previous surgical ligation. Early ligation of spermatic vein was performed since this fulfills the tumor-free principles and because the Hemolock clipping in the spermatic cord can be used for traction and marking of the renal perivascular lymphatic tissue.

### Complications

We noted one open conversion due to a perforation of the peritoneum and two intraoperative vessel injuries in our series. In the literature, the rate of open conversion is approximately 3%.<sup>1,16</sup> The conversion occurred early in our early experience and thus should not be viewed as a treatment failure. The most common intraoperative complications in laparoscopic RPLND are vascular injuries, which occur among 2.2%–20% of cases.<sup>17</sup> Our experience corroborates these earlier reports. The postoperative complications of ARRPLND were minor and self-limited. Moreover, accumulated experience may help to avoid the incidence of complications and extend the limits of dissection to the appropriate anatomic boundaries.

The current study has a number of limitations, including its retrospective design and lack of randomization to an active control treatment. This small series also represented limited experience. Further long-term follow-up with more patients are warranted to validate these preliminary findings.

### CONCLUSIONS

Our preliminary results indicate that ARRPLND is a safe, effective and technically feasible procedure for managing CS I NSGCT. Further studies are necessary to evaluate this technique.

### AUTHOR CONTRIBUTIONS

HH, KY, ZSL and YHL designed the study and performed the surgeries. FJZ, ZKQ and ZWL performed the statistical analysis. KY, ZSL and HH drafted the manuscript. ZSL, KY and HH completed the patients' follow-up data. All authors read and approved the revised manuscript.

### COMPETING INTERESTS

All authors declare that there are no competing interests.

### ACKNOWLEDGMENTS

This study was supported by grants from the Science and Technology Foundation of the Guangdong Province (No. 2009B030801191).

### REFERENCES

- Rassweiler JJ, Scheitlin W, Heidenreich A. Laparoscopic retroperitoneal lymph node dissection: does it still have a role in the management of clinical stage I nonseminomatous testis cancer? A European perspective. *Eur Urol* 2008; 54: 1004–9.
- Albers P, Albrecht W, Algaba F, Bokemeyer C, Cohn-Cedermark G, *et al*. European Association of Urology. EAU guidelines on testicular cancer. *Eur Urol* 2011; 60: 304–19.
- Robin CE. The renal fascia and its relation to transversalis fascia. *Anat Rec* 1944; 89: 295–9.
- Moore KL. The developing human: clinically Oriented Embryology. Philadelphia: Saunders; 2003. p. 211–6.
- Mark AH. Abdominopelvic fasciae. *Am J Anat* 1950; 87: 119–32.
- Sobin LH, Gospodariwicz M, Wittekind C. TNM classification of malignant tumors. UICC International Union Against Cancer, 7<sup>th</sup> ed. Hoboken: Wiley-Blackwell; 2009. p. 249–53.
- Weissbach L, Boedefeld EA. Localization of solitary and multiple metastases in stage II nonseminomatous testis tumors as basis for a modified lymph node dissection in stage I. *J Urol* 1987; 138: 77–82.
- Stephenson AJ, Bosl GJ, Motzer RJ, Bajorin DF, Stasi JP, *et al*. Retroperitoneal lymph node dissection for nonseminomatous germ cell testicular cancer: impact of patient selection factors on outcome. *J Clin Oncol* 2005; 23: 2781–7.
- Nicolai N, Miceli R, Necchi A, Biondi D, Catanzaro M, *et al*. Retroperitoneal lymph node dissection with no adjuvant chemotherapy in clinical stage I nonseminomatous germ cell tumours: long-term outcome and analysis of risk factors of recurrence. *Eur Urol* 2010; 58: 912–6.
- Elias SH, Phillip P, Ornat P. Laparoscopic Retroperitoneal Lymph Node Dissection for Clinical Stage I Nonseminomatous Germ Cell Tumor: a Large Single Institution Experience. *J Uro* 2012; 187: 487–91.
- Leblanc E, Caty A, Dargent D, Querleu D, Mazeman E. Extraperitoneal laparoscopic para-aortic lymph node dissection for early stage nonseminomatous germ cell tumors of the testis with introduction of a nerve sparing technique: description and results. *J Urol* 2001; 165: 89–93.
- Eggerer SE, Carver BS, Sharp DS, Motzer RJ, Bosl GJ. Incidence of disease outside modified retroperitoneal lymph node dissection templates in clinical stage I or IIA nonseminomatous germ cell testicular cancer. *J Urol* 2007; 177: 937–40.
- Hara I, Kawabata G, Yamada Y, Tanaka K, Kamidono S. Extraperitoneal laparoscopic retroperitoneal lymph node dissection in supine position after chemotherapy for advanced testicular carcinoma. *Int J Urol* 2004; 11: 934–7.
- Jeremiah CH, Martin EA. Retroperitoneal cavity. In: Gray's Anatomy, 39<sup>th</sup> ed. In: Susan S, Harold E, Jeremiah CH, David J, Andrew W, editors. Edinburgh: Churchill Livingstone; 2008. p. 854–76.
- Rassweiler JJ, Frede T, Lenz E, Redorta JP, Bassi P. Long-term experience with laparoscopic retroperitoneal lymph node dissection in the management of low-stage testis cancer. *Eur Urol* 2000; 37: 251–7.
- Albqami N, Janetschek G. Laparoscopic retroperitoneal lymph node dissection in the management of clinical stage I and II testicular cancer. *J Endourol* 2005; 19: 683–7.
- Kenney PA, Tuerk IA. Complications of laparoscopic retroperitoneal lymph node dissection in testicular cancer. *World J Urol* 2008; 26: 561–6.

**How to cite this article:** Yao K, Li ZS, Zhou FJ, Qin ZK, Liu ZW, Li YH, Han H. Anatomical retroperitoneoscopic retroperitoneal lymph node dissection for clinical stage I nonseminomatous germ cell tumors: initial operative experience. *Asian J Androl* 2013 Dec 16. doi: 10.4103/1008-682X.122188. [Epub ahead of print]