

mour that may recur locally or metastasise.<sup>1</sup> The term pleomorphic dermal sarcoma was introduced to reclassify atypical fibroxanthoma (AFX)-like tumours that have additional high-risk features suggestive of a greater malignant potential.<sup>2</sup> Diagnostic differentiation from AFX requires the presence of one or more of: deep adipose tissue invasion, tumour necrosis, lymphovascular invasion, and/or perineural invasion.<sup>2</sup> Clinically, PDS is indistinguishable from AFX and appears to form part of a biological continuum, with PDS having a significantly higher rate of local recurrence and metastatic spread.<sup>1,3,4</sup> The first reported case series of PDS reviewed 32 cases and found tumour necrosis in 53%, lymphovascular invasion in 26%, and perineural infiltration in 29%, with CD10 expressed in all cases tested and a metastatic rate of 10%.<sup>3</sup> The second reported series of 18 patients with PDS found that tumours arose mainly on the scalp and face of elderly patients (median age 81).<sup>1</sup> Consistent histopathological features included spindle cells arranged in a fascicular pattern, and the presence of epithelioid and multinucleate giant cells with pleomorphic vesicular nuclei. Lesions in all patients demonstrated invasion to the subcutis with additional necrosis identified in 3 patients. Follow-up data revealed that 20% developed local recurrence and 20% distant metastases to the skin, lymph nodes, and/or lungs.<sup>1</sup>

Due to the predominant tumour location on the head and neck, complete histological clearance of the primary or recurrent tumour may be unachievable. Treatment with adjuvant radiotherapy may then be considered.<sup>4</sup> In large defects the initiation of adjuvant radiotherapy tends to be delayed whilst waiting for wound healing.<sup>5</sup> Müller *et al.* achieved successful graft healing without complications by treating a patient with an innovative technique where adjuvant radiotherapy was started immediately following excision and reconstruction performed subsequently.<sup>5</sup>

Our report highlights the risk of local recurrence and metastatic spread in this rare cutaneous tumour. Recognition of this greater malignant potential emphasises the need for evidence-based guidelines for the treatment of pleomorphic dermal sarcoma. □

#### REFERENCES

1. Tardio JC, Pinedo F, Aramburu JA, Suárez-Massa D, Pampín A, Requena L, et al. Pleomorphic dermal sarcoma: a more aggressive neoplasm than previously estimated. *J Cutan Pathol.* 2016;43:101-12.
2. McCalmont TH. Correction and clarification regarding AFX and pleomorphic dermal sarcoma. *J Cutan Pathol.* 2012;39:8.
3. Miller K, Goodlad JR, Brenn T. Pleomorphic dermal sarcoma: adverse histologic features predict aggressive behavior and allow distinction from atypical fibroxanthoma. *Am J Surg Pathol.* 2012;36:1317-26.
4. Davidson JS, Demsey D. Atypical Fibroxanthoma: Clinicopathological determinants for recurrence and implications for surgical management. *J Surg Oncol.* 2012;105:559-62.
5. Müller CS, Jungmann J, Pföhler C, Mohammad F, Rube C, Vogt T. Report on immediate irradiation of a rapidly growing sarcoma of the scalp prior to wound closure. *J Dtsch Dermatol Ges.* 2016;14:539-42.

**How to cite this article:** Kravvas G, Veitch D, Logan IT, Perrett CM. Metastatic pleomorphic dermal sarcoma: an uncommon skin tumour. *An Bras Dermatol.* 2018;93(2):307-8.

## Atypical aquagenic keratoderma treated with oxybutynin chloride\*

Niharika Dixit<sup>1</sup>  
Kabir Sardana<sup>1</sup>  
Sidharth Tandon<sup>1</sup>  
Yogita Singh<sup>1</sup>

DOI: <http://dx.doi.org/10.1590/abd1806-4841.20187262>

Dear Editor,

A 36-year-old male presented with a three-year history of thickened, dark coloured skin over dorsal aspect of hands, volar aspect of wrists and circumferentially around the ankles, which become whitish and wrinkled within a few minutes of sweating or immersion into water. There were no associated complaints of pruritus, burning sensation, pain or hyperhidrosis. Physical examination revealed well defined hyperpigmented, hyperkeratotic plaques over the above-mentioned sites, with sparing of palms and soles (Figure 1A and 1B). After immersing the hands in water for 5 minutes, the plaques became whitish, wrinkled and sodden (Figure 1C and 1D) and reverted back to the hyperpigmented morphology within 30 minutes. A diagnosis of aquagenic keratoderma was considered and a biopsy was done after immersion of hands in water for 5 minutes which was consistent with keratoderma.

The patient was started on oral oxybutynin chloride 2.5mg twice daily and after three weeks there was a substantial amelioration of the disorder even after exposure to water (Figure 2). The patient was continued on oxybutynin and a topical keratolytic (salicylic acid 12%) was initiated to promote a faster clinical response.

AK is a rare disorder affecting the palms and occasionally soles of adolescent females. It is an acquired disease, mostly spo-

Received on 12.06.2017.

Approved by the Advisory Board and accepted for publication on 17.09.2017.

\* Work performed at the Department of Dermatology, Venereology and Leprosy Dr. Ram Manohar Lohia Hospital and Post Graduate Institute of Medical Education and Research Baba Khark Singh Marg - New Delhi, India.

Financial support: None.

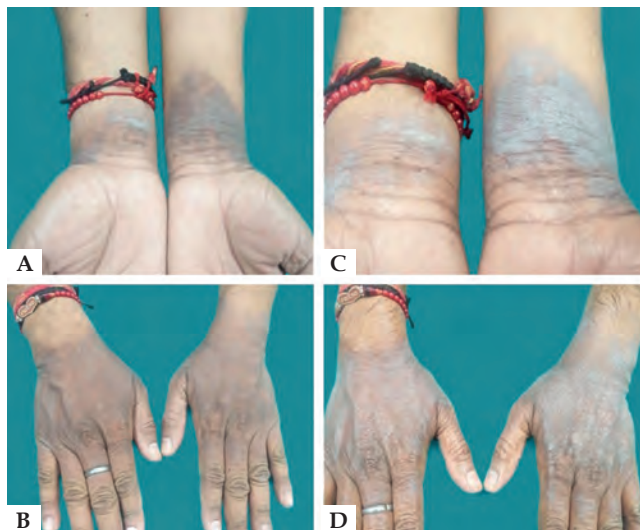
Conflict of interests: None.

<sup>1</sup> Department of Dermatology, Venereology and Leprosy Dr. Ram Manohar Lohia Hospital and Post Graduate Institute of Medical Education and Research - New Delhi, India.

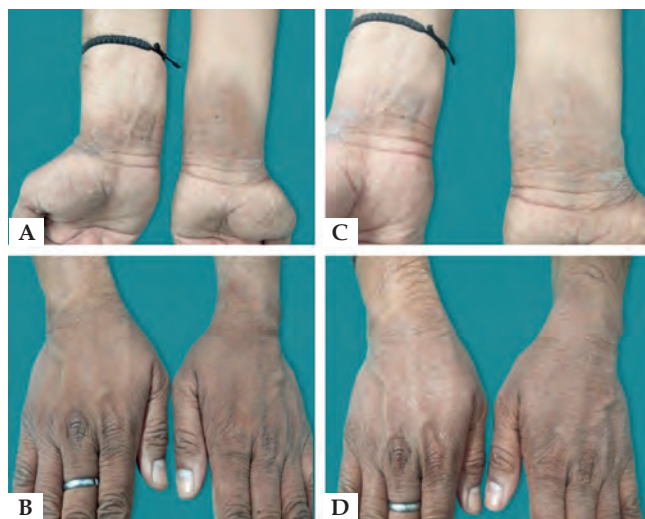
MAILING ADDRESS:

Niharika Dixit

E-mail: [drniharikadixit@gmail.com](mailto:drniharikadixit@gmail.com)



**FIGURE 1:** Atypical aquagenic keratoderma treated with oxybutynin chloride. Pre-treatment: **A** and **B** - before immersing in water **C** and **D** - after immersing in water



**FIGURE 2:** Atypical aquagenic keratoderma treated with oxybutynin chloride. Post-treatment: **A** and **B** - before immersing in water **C** and **D** - after immersing in water

radic with a few instances of familial inheritance.<sup>1</sup> It is characterized by recurrent episodes of pebbly thickening and wrinkling, triggered on exposure to water or due to hyperhidrosis and can be associated with burning sensation, tenderness and pruritus.<sup>1</sup> Unlike the bilateral involvement of palms and soles reported in most cases, our patient had an atypical involvement of dorsum of hands, wrists and ankles akin to previous reports.<sup>2,3</sup>

The etiopathogenesis is still a topic of debate and various theories proposed include, alteration in the salt concentration of the epidermal cells, increase in the water-binding capacity of keratins,

alteration of the barrier function of stratum corneum, role of the osmosensitive receptor transient vanilloid receptor type -1 (TVRT-1), and an increased expression of aquaporins.<sup>3</sup>

A more plausible theory relates to an influx of water via an osmotic gradient into eccrine ducts. Mac Cormack *et al.* suggested that an aberration of the sweat ducts could be the possible origin of AK and this is reinforced by the excellent response to botulinum toxin.<sup>2</sup>

Although spontaneous remission has been described,<sup>2</sup> in most cases AK tends to persist and can cause significant physical and psychological discomfort. Various treatment modalities have been used including aluminum-based, urea or salicylic-acid based products, formalin 3% in alcohol, antihistamines, botulinum toxin injections and iontophoresis.<sup>2</sup>

The reported role of eccrine glands in this disorder prompted us to intervene with oxybutynin, an anticholinergic agent, which is effective in hyperhidrosis, including palmoplantar hyperhidrosis.<sup>4</sup> The sweat glands are innervated by the sympathetic postganglionic nerves and acetylcholine is the primary neurotransmitter. The anticholinergic agents act by competitive inhibition of acetylcholine at the muscarinic receptors present on clear cell plasma membrane, thereby decreasing sweat production.<sup>5</sup>

The perceptible improvement both in the keratoderma and the aquagenic wrinkling after three weeks of therapy opens up another novel indication for oxybutynin which is a cheaper and less cumbersome modality than botulinum toxin (Figure 2). This reaffirms the pivotal role of eccrine glands in the pathogenesis of aquagenic keratoderma. □

#### REFERENCES

1. Saray Y, Seçkin D. Familial aquagenic acrokeratoderma: Case reports and review of the literature. *Int J Dermatol.* 2005;44:906-9.
2. Houle MC, Al Dhaybi R, Benohanian A. Unilateral aquagenic keratoderma treated with botulinum toxin A. *J Dermatol Case Rep.* 2010;4:1-5.
3. Tchernev G, Semkova K, Cardoso JC, Ananiev JJ, Wollina U. Aquagenic keratoderma. Two new case reports and a new hypothesis. *Indian Dermatol Online J.* 2014;5:30-3.
4. Wolosker N, de Campos JR, Kauffman P, Neves S, Yazbek G, Jatene FB, et al. An alternative to treat palmar hyperhidrosis: use of oxybutynin. *Clin Auton Res.* 2011;21:389-93.
5. Glaser DA. Oral medications. *Dermatol Clin.* 2014;32:527-32.

**How to cite this article:** Dixit N, Sardana K, Tandon S, Singh Y. Atypical aquagenic keratoderma treated with oxybutynin chloride. *An Bras Dermatol.* 2018;93(2):308-9.