


Prevention of postoperative adhesions after flexor tendon repair with acellular dermal matrix in Zones III, IV, and V of the hand

A randomized controlled (CONSORT-compliant) trial

Yeon Ji Lee, MD, Hyun Jung Ryoo, MD, Hyung-Sup Shim, MD, PhD* 

Abstract

Background: Various techniques have been attempted for preventing postoperative flexor tendon adhesion, such as modification of suture technique, pharmacological agents, and mechanical barriers. However, there is no evidence of the efficacy of these methods in clinical settings. In this study, we present the long-term outcomes of a randomized prospective study in which acellular dermal matrix (ADM) was used to prevent postoperative adhesions after tendon injury in the hand.

Methods: From January 2017 to January 2020, all patients with an acute single flexor tendon injury in hand Zones III, IV, or V were candidates. A single-digit, total tendon rupture repaired within 48 hours, from the index finger to the little finger, was included in the study. Patients were randomly allocated to either a control or ADM group. Complications and the range of movements were recorded. Functional outcomes and a patient satisfaction questionnaire were evaluated after 12 months following the tendon repair surgery. The present study is adhered to the CONSORT guidelines.

Results: A total of 25 patients was enrolled in the study: 13 patients in the ADM group and 12 in the control group. According to Buck-Gramcko II criteria, the postoperative functional outcome score was 14.38 ± 1.71 in the ADM group and 13.08 ± 1.82 in the control group (P value = .0485). Patient satisfaction was recorded at 8.38 ± 1.44 in the ADM group and 7.08 ± 1.58 in the control group (P value = .0309), a significant difference. There were no differences in complications between the 2 groups.

Conclusion: The beneficial effects of ADM after tendon repair were confirmed by improved postoperative functional outcome at flexor Zones III, IV, and V, preventing peritendinous adhesions and acting effectively as an anti-adhesive barrier.

Abbreviations: ADM = acellular dermal matrix, HA = hyaluronic acid.

Keywords: acellular dermal matrix, flexor tendon injury, hand injury, peritendinous adhesion

1. Introduction

Flexor tendon injury is one of the most common hand injuries and has been repaired using various techniques. However, it is

difficult to completely restore hand function after repair.^[1] Adhesion formation between repaired tendons and the surrounding tissue has been thought to be one of the most important factors that disturbs functional restoration. It is estimated that the adhesion, which can cause significant disability, occurs in about 30% of cases.^[2,3]

Numerous techniques have been attempted to prevent postoperative flexor tendon adhesions, such as modification of the suture technique with multistranded low friction methods, pharmacological agents regulating inflammatory response or tissue remodeling, and mechanical barriers forming a gliding surface between repaired tendons and surrounding proliferating tissue.^[4,5] The beneficial biological and histological effects of these techniques for preventing postoperative adhesions have been reported through in vitro studies and in vivo animal studies. However, there is no evidence of efficacy in clinical settings due to lack of clinical trials.^[6–9] With mechanical barriers, along with development of tissue engineering, various kinds of synthetic matrices enhancing biocompatibility combined with pharmacological agents have been actively introduced, but evidence for clinical use is insufficient.^[10,11]

It is reported that the acellular dermal matrix (ADM), commonly used as a replacement for skin grafts and a supplement for tissue defects,^[12] has been applied for tendon augmentation in Achilles tendon repair and as tendon scaffold in tendon gap repair.^[13–15] However, to our knowledge, the effects of using an ADM as the mechanical anti-adhesive barrier when repairing

Editor: Valerio D'Orazi.

This research was supported financially by Hyundai Bioland.

The authors have no conflicts of interest to disclose.

All data generated or analyzed during this study are included in this published article [and its supplementary information files].

Department of Plastic and Reconstructive Surgery, St. Vincent's Hospital, The Catholic University of Korea, Republic of Korea.

*Correspondence: Hyung-Sup Shim, Department of Plastic and Reconstructive Surgery, St. Vincent's Hospital, The Catholic University of Korea, College of Medicine, Joongbu-Daero 93, Paldal-Gu, Suwon City 16247, Republic of Korea (e-mail: sharpshim@catholic.ac.kr).

Copyright © 2022 the Author(s). Published by Wolters Kluwer Health, Inc. This is an open access article distributed under the terms of the Creative Commons Attribution-Non Commercial License 4.0 (CCBY-NC), where it is permissible to download, share, remix, transform, and buildup the work provided it is properly cited. The work cannot be used commercially without permission from the journal.

How to cite this article: Lee YJ, Ryoo HJ, Shim HS. Prevention of postoperative adhesions after flexor tendon repair with acellular dermal matrix in Zones III, IV, and V of the hand: a randomized controlled (CONSORT-compliant) trial. *Medicine* 2022;101:3(e28630).

Received: 22 September 2021 / Received in final form: 28 December 2021 / Accepted: 30 December 2021

<http://dx.doi.org/10.1097/MD.00000000000028630>

flexor tendon injuries have not been documented yet. In this study, we present the long-term outcomes of a randomized prospective study in which ADM was used to prevent postoperative adhesions after tendon injury.

2. Patients and methods

2.1. Ethical statement

This study was approved by the Institutional Review Board of the Catholic Center Office of the Human Research Protection Program (No. of IRB VC17DESI0222) in The Catholic University of Korea (Seoul, Korea). All data were analyzed anonymously and according to the principles in the Declaration of Helsinki 1975 (revised in 2008).

2.2. Patients

The study was designed as a prospective, randomized controlled trial and conducted with patients seen from January 2017 to January 2020. This study was designed followed by CONSORT-compliant. All patients with acute single-digit flexor tendon injury in Zone III, IV, or V between the palmar digital crease and the proximal border of the transverse carpal ligament were candidates. Patients with single-digit, 1- or 2-tendon rupture from the index finger to the little finger repaired within 48 hours were included. The exclusion criteria were flexor tendon injury in Zones I and II and flexor pollicis longus injury. Patients who underwent surgery after 48 hours of tendon injury were also excluded from this study. Patients were randomly stratified into 2 groups using a random number table: the control and ADM group. The random allocation sequence was generated by surgeon and patients were assigned by a research assistant.

All patients were provided the informed consent for the publication of this study.

2.3. Surgical technique

Tenorrhaphy was performed under general anesthesia. Once the hand was draped in an aseptic manner, the skin laceration was extended to expose the ruptured tendon, and if necessary, the standard Bruner incision was carried out. After the defect of the tendon sheath was completely exposed for tendon repair, the tendon was mended with a core suture using the 4-strand double modified Kessler technique with #4-0 polypropylene sutures and peripheral sutures using a continuous running suture technique with #6-0 polypropylene sutures (Fig. 2A). After debridement of the dirty margin of the tendon sheath, the ADM (Insuregraf, Hyundai Bioland, Cheonan, Korea) was applied over the repaired tendon in a slightly larger size than the defect in the tendon sheath in a wrapping manner (Fig. 2B) before skin closure; this was defined as a case group. On the other hand, the control group with core suture alone, peripheral suture, and debridement of a dirty margin of the tendon sheath was conducted in the same manner as the case group but without ADM wrapping. The overlying skin and subcutaneous tissue were closed with #5-0 nylon sutures with a buried suture if necessary. Stitches of the skin suture were removed 10 to 14 days postoperatively.

Passive physical therapy was started 3 to 5 days after the surgery once acute postoperative pain improved, and early controlled active physical therapy was started at 7 days postoperative. The physical therapy schedule was the same for

both groups, and passive and active exercises were maintained every twice a week for the following 8 weeks as scheduled.

Postoperative complications including infection, re-rupture, and wound disruption were recorded during the follow-up period.

The functional outcome of flexor tendon repair was assessed by Buck-Gramcko II criteria based on nail to palm crease distance, total extension defect, and modified total active motion score. Based on the score assigned according to this scoring system, the results were evaluated using a 5-stage classification.^[16] The functional outcomes were measured at 12 months postoperatively. In addition, patient scores on the Patient Satisfaction Questionnaire ranging from 0 (bad) to 10 (good) compared with pre-injury status were obtained by questionnaire in which recovery of daily motor function was rated.

2.4. Statistical analysis

Patient demographics of age, sex, injured zone of flexor tendon, injured tendon, injured finger, and mechanism of injury were compared between groups using the Mann-Whitney *U* test and Fisher exact test.

The functional outcomes assessed by Buck-Gramcko II criteria including score and classification were analyzed and compared using the Mann-Whitney *U* test and Fisher exact test. The patient scores on the Patient Satisfaction Questionnaire were analyzed using the Mann-Whitney *U* test. *P* values less than .05 were considered statistically significant. All statistical analyses were executed in GraphPad Prism version 9.0.1 (GraphPad software Inc., San Diego, CA).

3. Results

Among the patients with acute tendon injury who underwent tenorrhaphy ($n=106$), 25 patients were enrolled in the study: 13 in the case group and 12 in the control group. Eighty-one patients were excluded from this study: 76 patients did not meet the inclusion criteria and 5 patients were lost to follow-up at 12 months.

Ten (76.69%) patients from the case group and 9 (75.00%) patients from the control group were males, no significant difference was found (*P* value > .999). The mean age was similar in both groups (44.15 ± 6.04 years in the case group and 44.58 ± 9.09 years in the control group). The most common mechanism of injury was deep laceration by sharp objects such as broken glasses, cooking knife, and cutting knife used for suicidal attempt. The demographics of the patients including zone of injury, the location of injury in terms of finger and tendon, and mechanism of injury are described in Table 1.

One case of postoperative infection involving mild redness and discharge was recorded in each group, and the symptoms subsided soon after oral antibiotic medications were provided. Wound disruption was observed in 1 patient in the case group and 2 in the control group; all healed spontaneously without additional surgical intervention. Neither re-rupture nor nerve injury-related complications were reported in either group.

Postoperative functional outcomes evaluated at 12 months from tendon repair surgery showed total scores based on Buck-Gramcko II criteria of 14.38 ± 1.71 in the case group and 13.08 ± 1.82 in the control group, a significant difference (*P* value = .0485). In the classification using Buck-Gramcko II criteria, the range of movement was excellent in 2 patients (15.38%) in the

Table 1**Patient demographics.**

	Total	Case group	Control group	P value
Age	44.36 (± 7.49)	44.15 (± 6.04)	44.58 (± 9.09)	.631 (NS)
Sex	25	13	12	>.999 (NS)
Male	19	10 (76.69%)	9 (75%)	
Female	6	3 (23.08%)	3 (25%)	
Mechanism of injury				.786 (NS)
Deep laceration	13	6 (46.15%)	7 (58.33%)	
Crushing injury	9	5 (38.46%)	4 (33.33%)	
Penetrating injury	3	2 (15.38%)	1 (8.33%)	
Injured zone				.405 (NS)
Zone III	9 (36%)	4 (30.77%)	5 (41.67%)	
Zone IV	12 (40%)	7 (53.85%)	5 (41.67%)	
Zone V	3 (12%)	2 (15.38%)	2 (16.67%)	
Injured finger				.816(NS)
Index	8 (32%)	5 (38.46%)	4 (33.33%)	
Middle	6 (24%)	4 (30.77%)	2 (16.67%)	
Ring	5 (20%)	2 (15.38%)	3 (25.00%)	
Little	4 (16%)	2 (15.38%)	2 (16.67%)	
Injured tendons				.216 (NS)
FDS	17 (36%)	7 (53.85%)	10 (83.33%)	
FDS + FDP	8 (40%)	6 (46.15%)	2 (16.67%)	

FDP = flexor digitorum profundus, FDS = flexor digitorum superficialis, NS = no significance.

case group and in none of the control group; very good in 8 (61.53%), the case group and 5 (41.67%), the control group; good in 3 (23.06%), the case group and 7 (58.33%), the control group (Table 2 and Fig. 1A and B).

Patient-reported outcomes were significantly different, 8.38 ± 1.44 in the case group and 7.08 ± 1.58 in the control group (P value = .0309) as shown in Table 2 and Figure 1C. All patients had no limitation on activities of daily life.

According to the number of injured tendons, the functional outcomes by total scores based on Buck-Gramcko II criteria and patient scores on the Patient Satisfaction Questionnaire were investigated. There were no significant differences in functional outcome and patient satisfaction between patients with flexor digitorum superficialis injury and those with combined flexor digitorum superficialis/flexor digitorum profundus injury (Table 3).

4. Discussion

The risk factors that increase the incidence of postoperative adhesions after flexor tendon repair are associated with the immobilization following excision of the synovial sheath. The more severe the damage to the synovial sheath is (especially in the cases with 3 mm or more of the sheath gap), the more severe the adhesion occurs. Corrections not found on the server^[17] Various available options for preventing peritendinous adhesions have been introduced: suture technique, pharmacological agents regulating inflammatory response or remodeling of tissue, and mechanical barriers placed between the tendons and proliferating tissue for maintaining a gliding surface (Fig. 3).^[4]

Advancement of surgical techniques for preventing peritendinous adhesions focused on the number of suture strands and the amount of friction energy exerted at the ruptured section of the

Table 2**Functional outcomes.**

	Case group	Control group	P value
Score using Buck-Gramcko II criteria	14.38 (± 1.71)	13.08 (± 1.82)	.0485(*)
Free nail palm crease distance	5.69 (± 0.48)	5.58 (± 0.67)	
Total extension deficit	2.85 (± 0.38)	2.50 (± 0.77)	
Modified total active motion	5.84 (± 1.28)	5.16 (± 1.74)	
Classification using Buck-Gramcko II criteria			.1189 (NS)
Excellent	2 (15.38%)	—	
Very good	8 (61.53%)	5 (41.67%)	
Good	3 (23.08%)	7 (58.33%)	
Fair	—	—	
Poor	—	—	
Patient Satisfaction Questionnaire	8.38 (± 1.44)	7.08 (± 1.44)	.0309 (*)
Postoperative complication			—
Infection	1	1	
Wound disruption	1	2	
Re-rupture	0	0	

NS = no significance.

* indicates statistically significant.

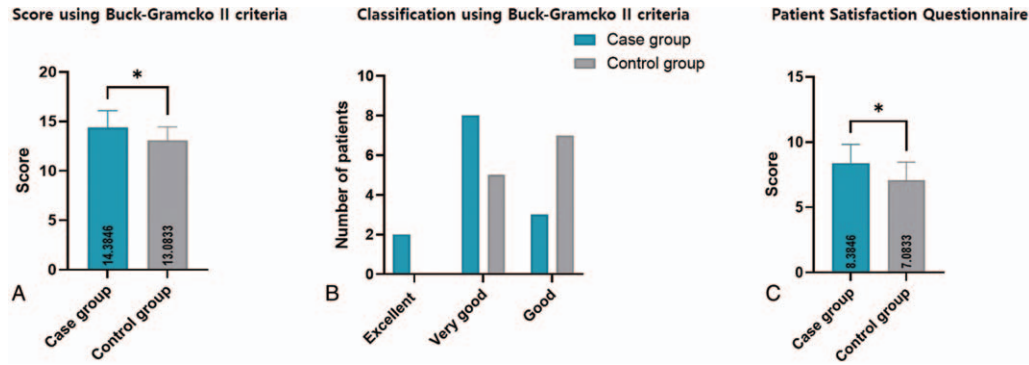


Figure 1. Functional outcomes at 12 months after surgery. (A) Total scores using the Buck-Gramcko II criteria were recorded at 14.38 ± 1.71 in the case group and 13.08 ± 1.82 in the control group (P value = .0485). (B) In the classification using Buck-Gramcko II criteria, the range of movement score was excellent in 2 patients (15.38%) in the case group and none in the control group, very good in 8 (61.53%) patients in the case group and 5 (41.67%) in the control group, and good in 3 (23.06%) in the case group and 7 (58.33%) in the control group. (C) Patient scores on the Patient Satisfaction Questionnaire were significantly different, at 8.38 ± 1.44 in the case group and 7.08 ± 1.58 in the control group ($P = .0309$).

tendon. Though 2-strand repair has been widely used, 4-, 6-, and 8-strand repair techniques are preferred to reduce adhesion nowadays because the latter enables early rehabilitation.^[18–22] A high-friction suture technique and repair of the tendon sheath together do not contribute to enhance the gliding function of the tendon in vitro.^[22] However, due to the paucity of clinical studies, the effectiveness of preventing adhesions has not been clearly proven in the clinical setting.^[23] Moreover, advanced techniques using a multistranded manner could not completely prevent postoperative adhesions cover the residual tendon sheath defect.^[22]

Non-steroidal anti-inflammatory drugs are the most popular pharmacological agents for preventing peritendinous adhesions and reducing peritendinous fibroplasias by inhibiting the metabolism of arachidonic acid and pro-inflammatory agents. In addition, these drugs help reduce postoperative adhesions.^[24,25] Hyaluronic acid (HA) was considered to have no significant effect in postoperative total active motion in a prospective, double-blind, randomized, and controlled clinical

trial.^[26] Five-fluorouracil and transforming growth factor beta inhibitor, which modulate fibroblast activity and reduce the response of transforming growth factor beta 1,^[8,27] improve the range of motion after flexor tendon repair. However, the evidence is further required in order to utilize as the treatment option.^[28]

Physical barriers, such as a biocompatible and diffusible membrane acting as a tendon sheath and creation of intra-synovial environments, have been applied to secure a gliding surface by separating the repaired tendon from the surrounding tissue. The classic barrier is a microporous synthetic material made of expanded polytetrafluoroethylene.^[9] Recently, non-steroidal anti-inflammatory drugs-combined physical barriers, and mitomycin-C-combined physical barriers have been reported to lower postoperative adhesion.^[7,17,29] Moreover, the tissue engineering processes used to develop the various synthetic physical barriers enhancing biocompatibility are evolving these days. Ibuprofen-loaded HA nanofibrous membranes^[10]; multifunctional, electrospun antibacterial core-shell nanofibrous membranes^[30]; and dual crosslinked HA nanofibrous membranes^[11] are the good examples known.

Since synthetic matrices used as physical barriers cannot perfectly replicate the natural extracellular matrix, several researchers have preferred autogenous tissue, allograft, or xenograft as physical barriers due to the limitation of synthetic

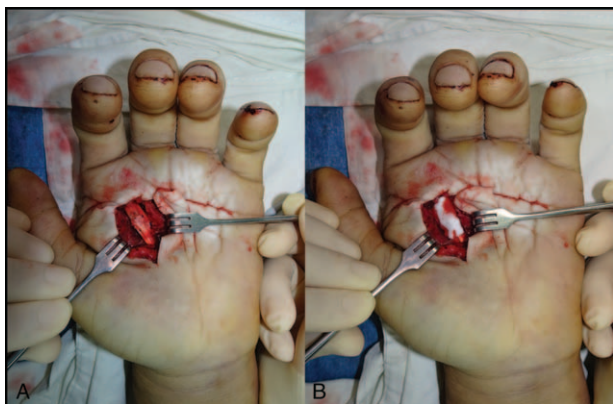


Figure 2. A 51-year-old male patient with a second FDP and FDS tendon injury at the Zone III flexor tendon level. (A) Clinical photograph showing repaired FDP and FDS tendons during surgery with a core suture in the 4-strand double modified Kessler technique and peripheral sutures in the continuous running suture technique. (B) Porcine ADM was applied to the repaired tendon using a wrapping method. ADM = acellular dermal matrix, FDP = flexor digitorum profundus, FDS = flexor digitorum superficialis.

Table 3

Functional outcomes by injured tendons.

	FDS injury	FDS/FDP combined injury	P value
Patients number	17	8	
Score using Buck-Gramcko II criteria	13.852 (± 1.54)	13.63 (± 1.76)	.788 (NS)
Classification using Buck-Gramcko II criteria			–
Excellent	2 (11.76%)	–	
Very good	7 (41.18%)	5 (62.50%)	
Good	8 (47.10%)	3 (37.50%)	
Fair	–	–	
Poor	–	–	
Patient Satisfaction Questionnaire	7.71 (± 1.69)	7.88 (± 1.08)	.803 (NS)

FDP = flexor digitorum profundus, FDS = flexor digitorum superficialis, NS = No significance.

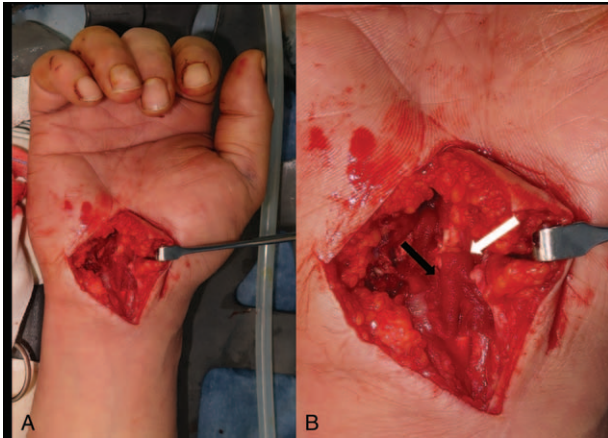


Figure 3. A 44-year-old male patient had a third FDP and FDS tendon injury at the Zone IV flexor tendon level. (A) This clinical photograph shows repaired FDP and FDS tendons covered with porcine ADM using a wrapping method. (B) The black arrow indicates the repaired tendon, and the white arrow indicates the blood-tinged applied porcine ADM. ADM = acellular dermal matrix, FDP = flexor digitorum profundus, FDS = flexor digitorum superficialis.

barriers in promoting tendon healing.^[31] In addition to the traditionally used fascia lata patch grafts and autogenous free sheaths,^[4] the use of collagen or ADM which promotes tendon healing and supplements the surrounding structure is increasing.^[13,32] In this study, for repair of injury of the flexor tendon Zones III, IV, and V, the porcine ADM Insuregraf was used as a physical barrier to confirm improvement in long-term functional outcome after surgery compared to a control group.

As an ADM, Insuregraf is a 3-dimensional matrix composed of native, intact collagen derived from porcine skin to promote migration of cells and vascularization, supporting dermal regeneration.^[4] Considering that porcine-derived dermal matrix has proven superior mechanical strength compared to bovine collagen matrix or human dermis,^[33,34] application of Insuregraf as an adhesion barrier between the tendon and surrounding tissues can provide a gliding surface, reduce adhesions between the tendon and surrounding tissues, and improve long-term functional outcome. The pathophysiologic mechanism of ADM was engraftment of dermal matrix by revascularization from the vascular tissue around the repaired tendon, creating a gliding surface. In cases of full-thickness burn wounds, the porcine ADM increases the expression of healing-promoting factors such as PCNA, integrin-B1, K-19, and PDGF. The effect is highest on the third to fifth day in terms of wound healing, when collagen deposition most actively takes place in. This indicates that ADMs most actively progress on the third to fifth days after application.^[35] Based on the pathophysiology, the porcine ADM could generate barrier tissue and mimic the natural tendon sheath with passive physical therapy from ADM engraftment on the surrounding tissue and can promote active tissue regeneration. These all encourage earlier initiation of physical rehabilitation thus leading to better functional outcome. As a result, it is favorable to apply ADM over the ruptured tendon accompanied with the deficiency of soft tissue such as crushing and avulsive injuries.^[36]

Because Zone II flexor tendon injuries, the most common hand injury, are more complicated compared to those in other zones, many studies have focused on preventing postoperative adhesions and improving surgical outcome. Anatomically narrow

spaces and complex structures called “no man’s land” lead to the higher rate of complications.^[37,38] In this study, we suggest to use the artificial ADM as a physical barrier for flexor tendon injury in Zones III, IV, and V. In flexor tendon injury in Zone III, IV, or V, the incidence of postoperative adhesions is relatively low, but previous studies have not revealed the methods for preventing postoperative adhesion. In this study, we mainly concentrated at Zone III, IV, or V flexor tendon injury because its less complex anatomy, compared to Zone II injury, could enable easier correlation between the use of ADMs and reduced postoperative adhesions in cases of single-tendon rupture, minimizing the bias of other factors that could affect functional outcome. This allows our results to be widely applicable to injuries in any other zones.

One limitation of this study was the small number of patients. Even though the results demonstrated statistically significant differences, further studies with the large number of populations are needed. Nevertheless, through this randomized controlled study, it is confirmed that the use of porcine ADMs as a physical barrier is related to excellent functional outcome compared to the control group. As described above, the porcine ADM has mechanical and histological superiority to the bovine ADM and human ADM: no special storage or handling is required. However, an additional study comparing the human-derived, bovine-derived, and porcine-derived ADM and their impacts on functional outcomes must be conducted in the future.

Also, it is estimated that the cost of surgery with ADM increases slightly by 15%, which is partially covered by the national insurance system in South Korea. However, in order to accurately evaluate the cost effectiveness, it is necessary to consider the cost reduction effect through reducing complication and lowering the incidence of re-operation due to postoperative adhesion. Although the sample size of this study is not so large, from the results of this study, we could assume that the cost-effectiveness will be agreeable in terms of total cost for revisional operation and postoperative rehabilitation. In addition, the cost effectiveness could be verified by conducting further large-scale study that can prove beneficial effects of the ADM.

5. Conclusion

In this study, the beneficial effects of using ADM as an anti-adhesive barrier in patients with an injured Zones III, IV, and/or V flexor tendon was confirmed to improve the long-term functional outcomes after surgery compared to the control group. Based on the results, we suggest the application of ADM when repairing flexor tendons is a favorable option for preventing postoperative peritendinous adhesions in the hand.

Author contributions

Conceptualization: Hyung-Sup Shim.

Formal analysis: Yeon Ji Lee.

Methodology: Yeon Ji Lee, Hyung-Sup Shim.

Supervision: Hyung-Sup Shim.

Visualization: Hyun Jung Ryoo.

Writing – original draft: Yeon Ji Lee.

References

- [1] de Jong JP, Nguyen JT, Sonnema AJ, Nguyen EC, Amadio PC, Moran SL. The incidence of acute traumatic tendon injuries in the hand and wrist: a 10-year population-based study. *Clin Orthop Surg* 2014;6:196–202.

- [2] Dy CJ, Hernandez-Soria A, Ma Y, Roberts TR, Daluiski A. Complications after flexor tendon repair: a systematic review and meta-analysis. *J Hand Surg Am* 2012;37:543–51.e1.
- [3] Pennisi E. Tending tender tendons. *Science* 2002;295:1011.
- [4] Khanna A, Friel M, Gougoulis N, Longo UG, Maffulli N. Prevention of adhesions in surgery of the flexor tendons of the hand: what is the evidence? *Br Med Bull* 2009;90:85–109.
- [5] Lilly SI, Messer TM. Complications after treatment of flexor tendon injuries. *J Am Acad Orthop Surg* 2006;14:387–96.
- [6] Leppanen OV, Karjalainen T, Goransson H, et al. Outcomes after flexor tendon repair combined with the application of human amniotic membrane allograft. *J Hand Surg Am* 2017;42:474.e1–8.
- [7] Zhao X, Jiang S, Liu S, et al. Optimization of intrinsic and extrinsic tendon healing through controllable water-soluble mitomycin-C release from electrospun fibers by mediating adhesion-related gene expression. *Biomaterials* 2015;61:61–74.
- [8] Khan U, Kakar S, Akali A, Bentley G, McGrouther DA. Modulation of the formation of adhesions during the healing of injured tendons. *J Bone Joint Surg Br* 2000;82:1054–8.
- [9] Hanff G, Abrahamsson SO. Cellular activity in e-PTFE reconstructed pulleys and adjacent regions of deep flexor tendons. An experimental biochemical study in rabbits. *J Hand Surg Br* 1996;21:419–23.
- [10] Chen CT, Chen CH, Sheu C, Chen JP. Ibuprofen-loaded hyaluronic acid nanofibrous membranes for prevention of postoperative tendon adhesion through reduction of inflammation. *Int J Mol Sci* 2019;20:5038.
- [11] Sheu C, Shalumon KT, Chen CH, Kuo CY, Fong YT, Chen JP. Dual crosslinked hyaluronic acid nanofibrous membranes for prolonged prevention of post-surgical peritoneal adhesion. *J Mater Chem B* 2016;4:6680–93.
- [12] Widjaja W, Tan J, Maitz PKM. Efficacy of dermal substitute on deep dermal to full thickness burn injury: a systematic review. *ANZ J Surg* 2017;87:446–52.
- [13] Bertasi G, Cole W, Samsell B, Qin X, Moore M. Biological incorporation of human acellular dermal matrix used in Achilles tendon repair. *Cell Tissue Bank* 2017;18:403–11.
- [14] Cole W, Samsell B, Moore MA. Achilles tendon augmented repair using human acellular dermal matrix: a case series. *J Foot Ankle Surg* 2018;57:1225–9.
- [15] Zhang YJ, Zhang C, Wang Q, Lin XJ. Augmented versus nonaugmented repair of acute Achilles tendon rupture: a systematic review and meta-analysis. *Am J Sports Med* 2018;46:1767–72.
- [16] Chan TK, Ho CO, Lee WK, Fung YK, Law YF, Tsang CY. Functional outcome of the hand following flexor tendon repair at the ‘no man’s land’. *J Orthop Surg (Hong Kong)* 2006;14:178–83.
- [17] Legrand A, Kaufman Y, Long C, Fox PM. Molecular biology of flexor tendon healing in relation to reduction of tendon adhesions. *J Hand Surg Am* 2017;42:722–6.
- [18] Aoki M, Manske PR, Pruitt DL, Larson BJ. Work of flexion after tendon repair with various suture methods. A human cadaveric study. *J Hand Surg Br* 1995;20:310–3.
- [19] Hwang MD, Pettrone S, Trumble TE. Work of flexion related to different suture materials after flexor digitorum profundus and flexor digitorum superficialis tendon repair in zone II: a biomechanical study. *J Hand Surg Am* 2009;34:700–4.
- [20] Strickland JW. Development of flexor tendon surgery: twenty-five years of progress. *J Hand Surg Am* 2000;25:214–35.
- [21] Wilgenbusch CS, Dust PW, Sunderland IR. Development of an acute care plastic surgery service in the Saskatoon Health Region: effects on flexor tendon management. *Plast Surg (Oakv)* 2015;23:195–8.
- [22] Strick MJ, Filan SL, Hile M, McKenzie C, Walsh WR, Tonkin MA. Adhesion formation after flexor tendon repair: a histologic and biomechanical comparison of 2- and 4-strand repairs in a chicken model. *J Hand Surg Am* 2004;29:15–21.
- [23] Peterson WW, Manske PR, Kain CC, Lesker PA. Effect of flexor sheath integrity on tendon gliding: a biomechanical and histologic study. *J Orthop Res* 1986;4:458–65.
- [24] Kulick MI, Brazlow R, Smith S, Hentz VR. Injectable ibuprofen: preliminary evaluation of its ability to decrease peritendinous adhesions. *Ann Plast Surg* 1984;13:459–67.
- [25] Nishimura K, Shimanuki T, diZerega GS. Ibuprofen in the prevention of experimentally induced postoperative adhesions. *Am J Med* 1984;77:102–6.
- [26] Golash A, Kay A, Warner JG, Peck F, Watson JS, Lees VC. Efficacy of ADCON-T/N after primary flexor tendon repair in Zone II: a controlled clinical trial. *J Hand Surg Br* 2003;28:113–5.
- [27] Cerovac S, Afoke A, Akali A, McGrouther DA. Early breaking strength of repaired flexor tendon treated with 5-fluorouracil. *J Hand Surg Br* 2001;26:220–3.
- [28] Bates SJ, Morrow E, Zhang AY, Pham H, Longaker MT, Chang J. Mannose-6-phosphate, an inhibitor of transforming growth factor-beta, improves range of motion after flexor tendon repair. *J Bone Joint Surg Am* 2006;88:2465–72.
- [29] Jiang S, Yan H, Fan D, Song J, Fan C. Multi-layer electrospun membrane mimicking tendon sheath for prevention of tendon adhesions. *Int J Mol Sci* 2015;16:6932–44.
- [30] Shalumon KT, Sheu C, Chen CH, et al. Multi-functional electrospun antibacterial core-shell nanofibrous membranes for prolonged prevention of post-surgical tendon adhesion and inflammation. *Acta Biomater* 2018;72:121–36.
- [31] Cheng CW, Solorio LD, Alsberg E. Decellularized tissue and cell-derived extracellular matrices as scaffolds for orthopaedic tissue engineering. *Biotechnol Adv* 2014;32:462–84.
- [32] Wichelhaus DA, Beyersdoerfer ST, Gierer P, Vollmar B, Mittlmeier T. The effect of a collagen-elastin matrix on adhesion formation after flexor tendon repair in a rabbit model. *Arch Orthop Trauma Surg* 2016;136:1021–9.
- [33] Adelman DM, Selber JC, Butler CE. Bovine versus porcine acellular dermal matrix: a comparison of mechanical properties. *Plast Reconstr Surg Glob Open* 2014;2:e155.
- [34] Ge L, Zheng S, Wei H. Comparison of histological structure and biocompatibility between human acellular dermal matrix (ADM) and porcine ADM. *Burns* 2009;35:46–50.
- [35] Chen X, Shi Y, Shu B, et al. The effect of porcine ADM to improve the burn wound healing. *Int J Clin Exp Pathol* 2013;6:2280–91.
- [36] Yoon D, Cho YS, Joo SY, Seo CH, Cho YS. A clinical trial with a novel collagen dermal substitute for wound healing in burn patients. *Biomater Sci* 2020;8:823–9.
- [37] Dy CJ, Daluiski A. Update on Zone II flexor tendon injuries. *J Am Acad Orthop Surg* 2014;22:791–9.
- [38] Manske PR. History of flexor tendon repair. *Hand Clin* 2005;21:123–7.