

Functional fat injection in the treatment of dysphagia following surgery

Francesco Mozzanica^{1,2}  | Antonio Schindler³ | Francesco Ottaviani^{1,2}

¹Department of Otorhinolaryngology, Ospedale San Giuseppe IRCCS Multimedica, Milan, Italy

²Department of Clinical Sciences and Community Health, University of Milan, Milan, Italy

³Department of Biomedical and Clinical Sciences, L. Sacco Hospital, University of Milan, Milan, Italy

Correspondence

Francesco Mozzanica, Department of Clinical Sciences and Community Health, University of Milan, Via San Vittore 12, Milan, Italy.

Email: francesco.mozzanica@gmail.com

Abstract

Functional fat injection under local anesthesia could be useful in the treatment of chronic dysphagia in selected patients with tissue loss secondary to laryngeal surgery.

KEYWORDS

dysphagia, fat injection, head and neck cancer

The application of functional fat injection (FFI) in the treatment of dysphagia following laryngeal surgery is presented. FFI was performed under local anesthesia using a

transcervical approach in order to correct the tissue loss causing dysphagia (Video S1). The control of injection depth and site was performed through a transnasal flexible endoscope (Video S2).

Dysphagia is a common complication after partial laryngectomies (PL). Behavioral swallowing rehabilitation allows adequate management in most of the cases; however, long-term feeding tube dependency is unavoidable in some patients. In order to overcome this problem, our group recently proposed a new treatment for dysphagia following PL, the functional fat injection (FFI) performed under local anesthesia. The underlying hypothesis is that tissue loss related to surgery might reduce airway protection acting as a funnel toward the larynx (Figure 1). The correction of tissue loss using fat might improve the safety of swallowing (Video S3). A case of FFI is presented.

CONFLICT OF INTEREST

Nothing to declare.

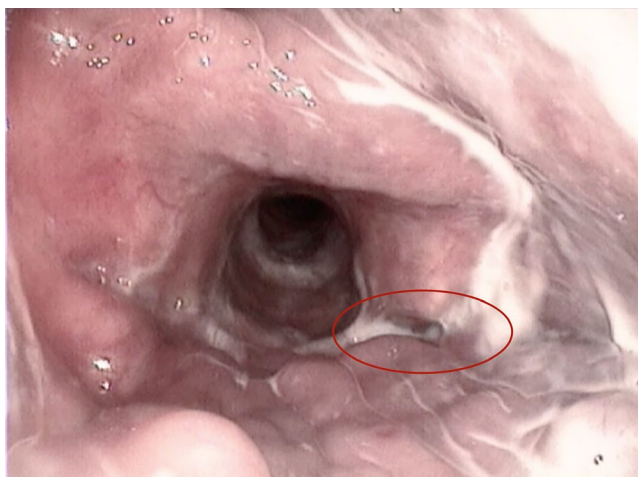


FIGURE 1 After a partial laryngectomy an important tissue loss at the level of the tongue base and of the left aryepiglottic fold, acting like a slope for the ingested food was found

This is an open access article under the terms of the Creative Commons Attribution-NonCommercial-NoDerivs License, which permits use and distribution in any medium, provided the original work is properly cited, the use is non-commercial and no modifications or adaptations are made.

© 2020 The Authors. *Clinical Case Reports* published by John Wiley & Sons Ltd

AUTHOR CONTRIBUTIONS

FM: made substantial contribution to conception and design of the study; drafting the manuscript, involved in final approval of the version to be published, and agreed to be accountable for all aspects of the work in ensuring that questions related to the accuracy or integrity of any part of the work are appropriately investigated and resolved. AS and FO: made substantial contribution to design of the study, revised the manuscript for important intellectual content, involved in final approval of the version to be published, and agreed to be accountable for all aspects of the work in ensuring that questions related to the accuracy or integrity of any part of the work are appropriately investigated and resolved.

ORCID

Francesco Mozzanica  <https://orcid.org/0000-0003-2591-4063>

REFERENCES

1. Schindler A, Pizzorni N, Mozzanica F, et al. Functional outcome after supracricoid laryngectomy: what do we not know and what do we need to know? *Eur Arch Otorhinolaryngol*. 2016;273:3459-3475.
2. Ottaviani F, Schindler A, Klinger F, Scarponi L, Succo G, Mozzanica F. Functional fat injection under local anesthesia to treat severe post-surgical dysphagia, case report. *Head Neck*. 2019;41:E17-E21.

SUPPORTING INFORMATION

Additional supporting information may be found online in the Supporting Information section.

How to cite this article: Mozzanica F, Schindler A, Ottaviani F. Functional fat injection in the treatment of dysphagia following surgery. *Clin Case Rep*. 2020;8:1860–1861. <https://doi.org/10.1002/ccr3.3006>