



Frontoethmoidal encephalocele in a cat

Dennis J Woerde¹, Karon L Hoffmann^{1,2}
and Narelle L Brown¹

Journal of Feline Medicine and Surgery Open Reports
1–4

© The Author(s) 2018

Reprints and permissions:

sagepub.co.uk/journalsPermissions.nav

DOI: 10.1177/2055116918783147

journals.sagepub.com/home/jfmsopenreports

This paper was handled and processed

by the European Editorial Office (ISFM)

for publication in *JFMS Open Reports*



Abstract

Case summary An 11-month-old female neutered domestic shorthair cat presented for further investigation of a 1 month history of generalised tonic–clonic seizures. Physical examination revealed microphthalmia of the left eye and right-sided hemiparesis. MRI of the brain and cranial neck was performed using a 1.5-Tesla system. MRI revealed a left frontoethmoidal encephalocele and microphthalmia of the left eye. Conservative treatment with antiepileptic medication was elected. The cat was managed on phenobarbitone and levetiracetam. Seizures have remained well controlled 12 months post-diagnosis.

Relevance and novel information This is the first known case report of a frontoethmoidal encephalocele in a cat. This case was presented to increase clinical awareness of this congenital malformation and as a differential diagnosis for any young cat that presents with seizures.

Keywords: Seizures, encephalocele, meningoencephalocele, brain

Accepted: 18 May 2018

Case description

An 11-month-old female neutered domestic shorthair cat presented to the referring veterinary surgery for seizures. Generalised tonic–clonic seizures began 1 month prior to presentation. Initially, the seizures occurred once weekly, increasing in frequency to every 5–6 h. Each seizure lasted approximately 30 s, with a postictal period lasting several hours. Partial seizures involving solely the head were also reported approximately 4 months prior to presentation. There were no interictal abnormalities reported apart from a mild right thoracic limb paresis.

The cat was obtained at 5 months of age and housed both indoors and outdoors. Commercial supermarket wet and dry food was fed. Vaccination and worming status were current.

Routine biochemistry, including resting bile acids, performed at the referring veterinary surgery was within normal limits. Haematology revealed mild lymphopenia ($1.4 \times 10^9/l$; reference interval [RI] $1.60\text{--}7.0 \times 10^9/l$) and monocytosis ($0.7 \times 10^9/l$; RI $<0.6 \times 10^9/l$). *Toxoplasma gondii* and *Cryptococcus gattii* antibody titres were negative.

The cat's feline immunodeficiency virus/feline leukaemia virus status was also negative. The cat was referred for further management and diagnostics.

On referral, physical examination revealed non-visual microphthalmia of the left eye (Figure 1) and right-sided hemiparesis. A full neurological examination, including cranial nerve assessment, revealed proprioceptive deficits present in both the right forelimb and right hindlimb. No other neurological abnormalities were identified.

A generalised tonic–clonic seizure occurred during the examination, lasting 30 s and requiring no intervention.

¹Animal Referral Hospital, Homebush, NSW, Australia

²Imaging Vets, Putney, NSW, Australia

Corresponding author:

Dennis Woerde BVSc (Hons), Animal Referral Hospital, 250 Parramatta Road Homebush, NSW 2140, Australia.

Email: dennis.woerde@gmail.com



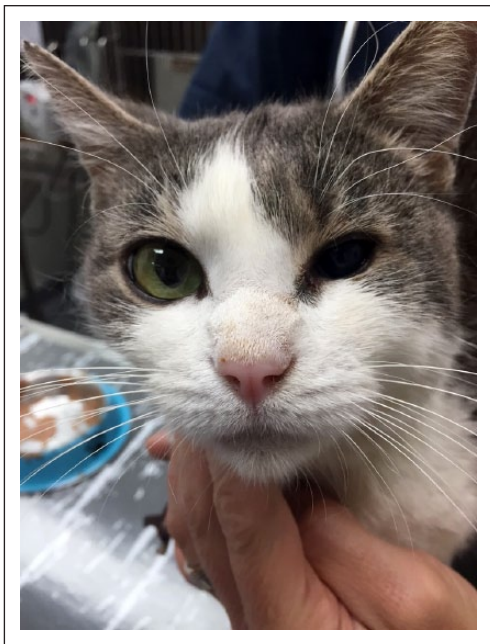


Figure 1 Microphthalmia of the left eye

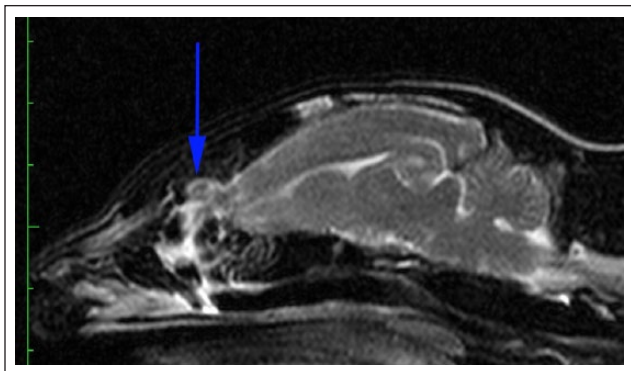


Figure 2 A T2-weighted image in the left parasagittal plane. Note: the left rostral rhinencephalon protruding through the cribriform plate (arrow) into the left caudal nasal cavity. High signal fluid is present within the left caudal nasal cavity and ventral meatus

Seizures are generally indicative of a forebrain disorder. Causes can be either intracranial or extracranial in origin. In this case, given the concurrent microphthalmia, a congenital intracranial forebrain lesion was suspected.

This was further localised to the left given the contralateral hemiparesis and proprioceptive deficits.

The cat was commenced on phenobarbitone intravenously (IV) loaded at 15 mg/kg over a 24 h period. There were no further seizures noted during this period. The cat was discharged the following day on 2.15 mg/kg phenobarbitone PO q12h and returned 1 week later for advanced imaging.

The cat was sedated with 0.2 mg/kg butorphanol IV and anaesthesia was induced with 1 mg/kg alfaxalone

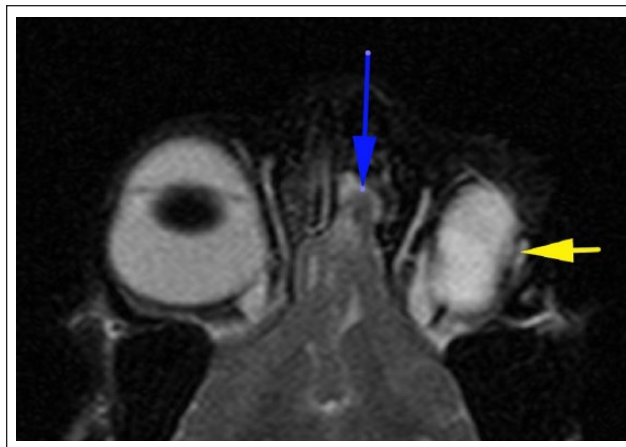


Figure 3 A T2-weighted image of the rostral brain in the dorsal plane. Note: the left rostral rhinencephalon protruding into the left caudal nasal cavity (blue arrow). There is a small amount of high signal fluid present adjacent to the rhinencephalon. The left globe (yellow arrow) is reduced in size, elliptical in shape and the lens is absent

(Alfaxan; Jurox) IV. MRI of the brain and cranial neck was performed using a 1.5-Tesla MRI system (Siemens Avanto). T2-weighted Turbo Spin Echo, fluid-attenuation inversion recovery and short T1 inversion recovery sequences were performed with 3 mm slice thickness. Pre- and post-intravenous gadolinium contrast (Magnevist 0.2 ml/kg) T1-weighted sequences were performed with 3 mm and 1.6 mm slice thickness.

MRI revealed protrusion of the left rostral rhinencephalon through the left cribriform plate into the left caudal nasal cavity consistent with a left frontoethmoidal encephalocele (Figure 2). Increased T2-weighted signal was present around the protruding rostral brain tissue, ventral nasal meatus and left caudal nasal cavity consistent with inflammatory exudate or cerebrospinal fluid.

The left globe was reduced in size, elliptical in shape and the lens was absent. This was consistent with congenital microphthalmia with aphakia (Figure 3).

The cat recovered uneventfully from anaesthesia. Conservative therapy with antiepileptic medication was elected and surgical correction was not performed. The cat was discharged the following day on the previously prescribed phenobarbitone.

Leviteracetam (Keppra; UCB Pharma) was additionally commenced 4 weeks later at 22 mg/kg PO q8h as the cat presented to the clinic following two generalised tonic-clonic seizures in close succession. Seizures recurred again 3 months later and the phenobarbitone dose was subsequently increased to 4 mg/kg PO q12h.

The cat responded to the increased phenobarbitone dose and seizures have been well controlled 12 months post-diagnosis of the encephalocele.

Discussion

The MRI findings in this case are consistent with a frontoethmoidal encephalocele. An encephalocele refers to a protrusion of cranial contents through a defect in the skull base.¹ Depending on the type of contents protruding they are classified as either meningocele (containing meninges) or meningoencephalocele (containing both brain matter and meninges). Encephaloceles are then further categorised depending on which part of the cranium is affected.² There is some conjecture in the human literature as to the anatomical classification, with several classification systems present and inconsistent nomenclature used. A broad classification as either frontoethmoidal, cranial vault (convex or parietal), occipital or basal is widely accepted.³ Frontoethmoidal encephaloceles are alternatively referred to as sincipital or intranasal.

There are few case reports of encephaloceles in veterinary literature.^{4–11}

While encephaloceles have been reported in cats,^{12–15} this is the first known case report of a frontoethmoidal encephalocele occurring.

In people, the vast majority of encephaloceles are congenital in nature, caused by a disruption in neural tube closure.¹⁶ Acquired encephaloceles have also been reported secondary to trauma, surgery, intracranial tumours and hydrocephalus.¹⁷

The exact aetiology of congenital encephaloceles is not well understood.

Hereditary encephaloceles have been reported in a familial cluster of Burmese cats,¹³ suggesting an underlying genetic cause. However, a study by Suwanwela et al found only one in a pair of identical twins affected,¹⁸ making a purely genetic mechanism unlikely.

Parietal and basal encephaloceles have been reported in cats following exposure of the pregnant queen to teratogenic substances, including methylmercury,¹⁴ hydroxyurea¹⁹ and griseofulvin.¹⁵ Hyperthermia and viral infections during pregnancy have also been theorised as potential causes in human literature.²⁰

Studies in people have also found a higher prevalence in patients living in rural lower socioeconomic areas,²¹ with some authors suggesting a possible link to vitamin deficiency, although the link is not closely established. Encephalocele formation has also been shown experimentally to form secondary to excessive vitamin A in rats.²²

The presenting clinical sign in this case was seizures. This is consistent with the presenting complaint seen in dogs with this condition.^{4,6,7} This differs from people, with the primary clinical signs consisting of facial swelling, nasal congestion or cerebrospinal fluid rhinorrhea.^{20,23} Neurological signs are generally uncommon, although seizures can be a feature.^{24,25} Cerebrospinal fluid rhinorrhea has also been reported in dogs with frontoethmoidal encephaloceles.⁶

Pain is generally not a feature of this condition in people,²⁰ and was not appreciated in the cat in our case.

Although uncommon, hemiparesis has been reported secondary to encephaloceles in people.^{26,27} The hemiparesis occurring in the cat presented this study is consistent with its cerebral lesion, occurring on the contralateral side to the encephalocele. In the study by Lazzarini et al,⁶ neurological abnormalities on examination of dogs with frontoethmoidal encephaloceles included circling, proprioceptive deficits and reduced menace response. In this study, 6/17 dogs with frontoethmoidal encephaloceles had normal neurological examination findings.⁶

The exact mechanism by which frontoethmoidal encephaloceles cause seizures is poorly understood. Jeffery theorised that the vascular mucosa of the encephalocele is prone to trauma within the nasal cavity.⁴ Encephaloceles in people have been reported to cause recurrent meningoencephalitis,²⁸ with communication to the external environment an entry point for microorganisms. *Streptococcus pneumoniae* and *Staphylococcus aureus* are commonly isolated.³ Histopathological examination of the herniated brain tissue in dogs has shown signs of inflammation and haemorrhage.^{4,6}

The ipsilateral microphthalmia is an interesting concurrent finding in this case. In people, frontoethmoidal encephaloceles can occur in association with other craniofacial congenital abnormalities.³ In the study by Lazzarini et al,⁶ 3/17 dogs with frontoethmoidal encephaloceles had concurrent malformations such as hydrocephalus ex vacuo and possible cerebellar hypoplasia. Studies in rats examining hyperthermia during the gastrulation process found hyperthermia-induced encephalocele formation and other head defects such as microphthalmia.²⁹ In this study encephaloceles and microphthalmia were common concurrent abnormalities.²⁹

Surgery is considered the treatment of choice for encephaloceles in people.²⁰ Surgery was recommended in this case; however, the cat was elected to be managed on antiepileptic drugs and surgery was not attempted. Successful surgical correction of a frontoethmoidal encephalocele has been reported in a 5-month-old Border Collie.⁷ The dog was weaned off phenobarbitone 7 months postoperatively and remained seizure-free.⁷ Similarly, successful surgical correction of a parietal meningoencephalocele in a 4-month-old domestic shorthair cat has been reported.¹² Postoperative complications in human literature include transient cerebrospinal fluid leakage and secondary central nervous system infections.^{30,31} The surgical mortality rate is relatively low in human medicine, with 2/124 perioperative deaths in one study.³¹

The response to antiepileptic drugs is variable if surgery is not performed. Some dogs with frontoethmoidal encephaloceles are ultimately euthanased due to refractory seizures.^{4,6} Of the 11 dogs treated with antiepileptic

drugs in the study by Lazzerini et al,⁶ 2/11 dogs were seizure-free and 3/11 had a seizure reduction of $\geq 50\%$. In this case the cat was initially prescribed phenobarbitone; however, a second antiepileptic drug was required (levetiracetam) to control the seizures. Seizures remain well controlled 12 months post diagnosis.

Conclusions

This is the first known report of a frontoethmoidal encephalocele occurring in a cat. Although a rare condition, this congenital defect may be considered as a differential diagnosis for any young cat that presents with seizures.

Conflict of interest The authors declared no potential conflicts of interest with respect to the research, authorship, and/or publication of this article.

Funding The authors received no financial support for the research, authorship, and/or publication of this article.

References

- Cullu N, Deveer M, Karakas E, et al. **Traumatic frontoethmoidal encephalocele: a rare case.** *Eurasian J Med* 2015; 47: 69–71.
- David DJ and Proudman TW. **Cephaloceles: classification, pathology, and management.** *World J Surg* 1989; 13: 349–357.
- Singh AK and Upadhyaya DN. **Sincipital encephaloceles.** *J Craniofac Surg* 2009; 20: 1851–1855.
- Jeffery N. **Ethmoidal encephalocele associated with seizures in a puppy.** *J Small Anim Pract* 2005; 46: 89–92.
- Vogt DW, Ellersieck MR, Deutsch WE, et al. **Congenital meningocele-encephalocele in an experimental swine herd.** *Am J Vet Res* 1986; 47: 188–191.
- Lazzerini K, Gutierrez-Quintana R, José-López R, et al. **Clinical features, imaging characteristics, and long-term outcome of dogs with cranial meningocele or meningoencephalocele.** *J Vet Intern Med* 2017; 31: 505–512.
- Martlé VA, Caemaert J, Tshamala M, et al. **Surgical treatment of a canine intranasal meningoencephalocele.** *Vet Surg* 2009; 38: 515–519.
- Parker AJ and Cusick PK. **Meningoencephalocele in a dog (a case history).** *Vet Med Small Anim Clin* 1974; 69: 206–207.
- Rosenblatt AJ, Scrivani PV, Caserto BG, et al. **Imaging diagnosis – meningoencephalitis secondary to suppurative rhinitis and meningoencephalocele infection in a dog.** *Vet Radiol Ultrasound* 2014; 55: 614–619.
- Geelen JA. **A case of hydrocephalus and meningoencephalocele in a rabbit, caused by aqueductal malformation.** *Lab Anim* 1974; 8: 167–176.
- Wijeratne WV, Beaten D and Cuthbertson JC. **A field occurrence of congenital meningo-encephalocele in pigs.** *Vet Rec* 1974; 95: 81–84.
- Dewey CW, Brewer DM, Cautela MA, et al. **Surgical treatment of a meningoencephalocele in a cat.** *Vet Surg* 2011; 40: 473–476.
- Sponenberg DP and Graf-Webster E. **Hereditary meningoencephalocele in Burmese cats.** *J Hered* 1986; 77: 60.
- Khera KS. **Teratogenic effects of methylmercury in the cat: note on the use of this species as a model for teratogenicity studies.** *Teratology* 1973; 8: 293–303.
- Scott FW, LaHunta A, Schultz RD, et al. **Teratogenesis in cats associated with griseofulvin therapy.** *Teratology* 1975; 11: 79–86.
- Hoving EW. **Nasal encephaloceles.** *Childs Nerv Syst* 2000; 16: 702–706.
- Holmes AD, Meara JG, Kolker AR, et al. **Frontoethmoidal encephaloceles: reconstruction and refinements.** *J Craniofac Surg* 2001; 12: 6–18.
- Suwanwela C, Sukabote C and Suwanwela N. **Frontoethmoidal encephalomeningocele.** *Surgery* 1971; 69: 617–625.
- Khera KS. **A teratogenicity study on hydroxyurea and diphenylhydantoin in cats.** *Teratology* 1979; 20: 447–451.
- Tirumandas M, Sharma A, Gbenimacho I, et al. **Nasal encephaloceles: a review of etiology, pathophysiology, clinical presentations, diagnosis, treatment, and complications.** *Childs Nerv Syst* 2013; 29: 739–744.
- Morina A, Kelmendi F, Morina Q, et al. **Treatment of anterior encephaloceles over 24 years in Kosova.** *Med Arh* 2011; 65: 122–124.
- Theodosios DT and Fraser FC. **Early changes in the mouse neuroepithelium preceding exencephaly induced by hypervitaminosis A.** *Teratology* 1978; 18: 219–232.
- Mahapatra AK and Suri A. **Anterior encephaloceles: a study of 92 cases.** *Pediatr Neurosurg* 2002; 36: 113–118.
- Saavalainen T, Jutila L, Mervaala E, et al. **Temporal antero-inferior encephalocele: An underrecognized etiology of temporal lobe epilepsy?** *Neurology* 2015; 85: 1467–1474.
- Faulkner HJ, Sandeman DR, Love S, et al. **Epilepsy surgery for refractory epilepsy due to encephalocele: a case report and review of the literature.** *Epileptic Disord* 2010; 12: 160–166.
- Fountas KN, Smith JR, Jenkins PD, et al. **Spontaneous motor cortex encephalocele presenting with simple partial seizures and progressive hemiparesis. Case report and review of the literature.** *Neurosurg Focus* 2005; 19: 1–5.
- Shi C, Flores B, Fisher S, et al. **Symptomatic parietal intradiploic encephalocele – a case report and literature review.** *J Neurol Surg Rep* 2017; 78: 43–48.
- Dhirawani RB, Gupta R, Pathak S, et al. **Frontoethmoidal encephalocele: case report and review on management.** *Ann Maxillofac Surg* 2014; 4: 195–197.
- Webster WS, Germain MA and Edwards MJ. **The induction of microphthalmia, encephalocele, and other head defects following hyperthermia during the gastrulation process in the rat.** *Teratol* 1985; 31: 73–82.
- Oucheng N, Lauwers F, Gollogly J, et al. **Frontoethmoidal meningoencephalocele: appraisal of 200 operated cases.** *J Neurosurg Pediatr* 2010; 6: 541–519.
- Arshad AR and Selvapragasam T. **Frontoethmoidal encephalocele: treatment and outcome.** *J Craniofac Surg* 2008; 19: 175–183.