

# Reopenable clip-over-the-line method for closing large mucosal defects following colorectal endoscopic submucosal dissection: A feasibility study



## Authors

Tatsuma Nomura<sup>1,2</sup>, Shinya Sugimoto<sup>3</sup>, Taishi Temma<sup>4</sup>, Jun Oyama<sup>1</sup>, Keiichi Ito<sup>2</sup>, Akira Kamei<sup>1</sup>

## Institutions

- 1 Gastroenterology, Ise Red Cross Hospital, Ise-shi, Japan
- 2 Gastroenterology, Mie Prefectural Shima Hospital, Shima-shi, Japan
- 3 Gastroenterology, Ise Sekijūji Byoin, Ise, Japan
- 4 gastroenterology, Yamada Red Cross Hospital, Ise, Japan

received 11.11.2022

accepted after revision 9.5.2023

accepted manuscript online 16.5.2023

## Bibliography

Endosc Int Open 2023; 11: E697–E702

DOI 10.1055/a-2095-0033

ISSN 2364-3722

© 2023. The Author(s).

This is an open access article published by Thieme under the terms of the Creative Commons Attribution-NonDerivative-NonCommercial License, permitting copying and reproduction so long as the original work is given appropriate credit. Contents may not be used for commercial purposes, or adapted, remixed, transformed or built upon. (<https://creativecommons.org/licenses/by-nc-nd/4.0/>)

Georg Thieme Verlag KG, Rüdigerstraße 14,  
70469 Stuttgart, Germany

## Corresponding author

Dr. Tatsuma Nomura, Ise Red Cross Hospital,  
Gastroenterology, 1-471-2 Funae, Ise, Mie, JP 516-8512, 516-8512 Ise-shi, Japan  
m06076tn@icloud.com

## ABSTRACT

**Background and study aims** Complete closure of large defects after colorectal endoscopic submucosal dissection (ESD) can be problematic, especially in challenging areas or lesions larger than half the lumen circumference. We report a reopenable clip-over-the-line method for such defects and aim to investigate its feasibility through a case series.

**Patients and methods** We retrospectively evaluated data from 30 consecutive patients who underwent ESD with defect closure using the reopenable clip-over-the-line method between October 2020 and September 2022. This method requires the first clip-with-line grasp of the oral side's defect edge and muscle layer. The next reopenable clip (with a line fed through a hole in the reopenable clip tooth) is placed on the opposing mucosal defect edge and muscle layer. This process is repeated until complete closure. The primary study outcome was the rate of complete mucosal defect closure. We also reported post-procedure bleeding or perforation.

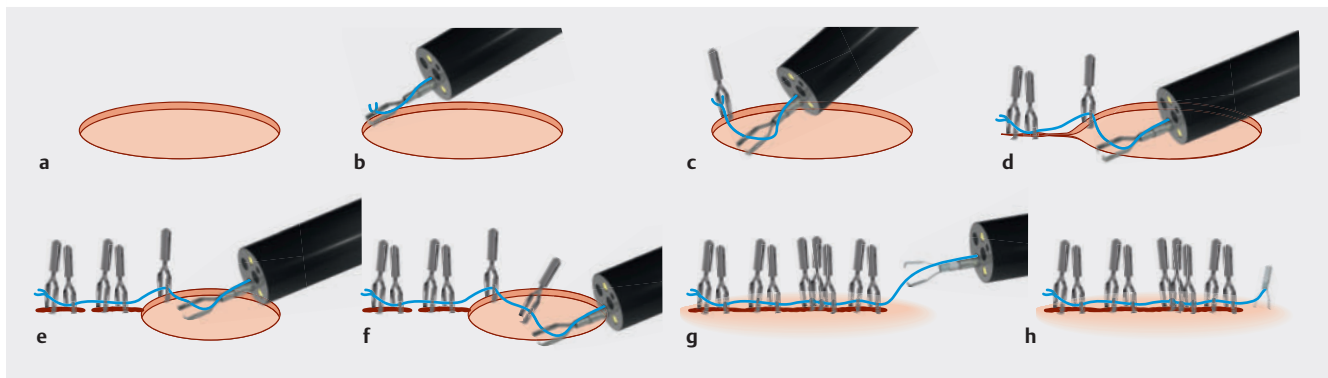
**Results** The median dimensions of the resected specimens were 45 mm (range, 35–70) by 39 mm (range, 29–60). Complete closure was achieved for all defects, including nine rectal defects, of which three bordered the anal verge. Of the 30 defects included in this study, nine were larger than half the lumen circumference. The median closure time was 25 minutes (range, 14–52), and the median clip number was 17 (range, 9–42). No post-procedure bleeding or perforation occurred.

**Conclusions** The reopenable clip-over-the-line method is a feasible technique for the complete closure of large colorectal defects after endoscopic submucosal dissection, regardless of location.

## Introduction

Colorectal endoscopic submucosal dissection (ESD) is a technique that can be used to resect large colorectal tumors [1]. While ESD is an excellent minimally invasive treatment, post-operative bleeding and perforation after colorectal ESD are ad-

verse events (AEs) that should be prevented. An increased risk of post-ESD bleeding has been reported for rectal lesions and large defects [2]. Some methods of prophylactic mucosal defect closure using clips have been reported to reduce the risk of AEs [3,4,5]. However, mucosal defect closure with clips is especially difficult in the rectum, which has a thick mucosa



► **Fig. 1** Scheme for the reopenable clip-over-the-line method (ROLM). **a** A clip with an affixed line is placed such that it is grasping the defect edge and muscle layer. **b** Line from the accessory channel is threaded through the hole in one tooth of the clip. The clip is then inserted through the accessory channel. We continue by grasping the opposing edge of the mucosal defect and muscle layer. **c** Clip-with-lines (threaded through the tooth hole of each clip) are alternately placed to close mucosal defect closure. **d, e, f** If there is a gap between the defect edges, a clip-with-line is fastened to the muscle layer alone. Grasping the opposing defect edge and muscle layer with the clip, the line is pulled taut to approximate the defect edges. **g** After complete defect closure using ROLM, a locking-clip technique is used to secure the line to the clip base. **h** The clip is placed on the normal mucosa. The thread is then pulled by hand, and the line is cut at the base of the clip.

and muscularis propria [6,7]. While various closure devices have been investigated, complete closure of the rectum has been achieved using an over-the-scope clip (OTSC, Ovesco Endoscopy AG, Tuebingen, Germany) system [8] and endoscopic ligation with O-ring closure (E-LOC). The OTSC system is a special device for closure of full-thickness defects of the gastrointestinal tract with a strong grasping force. In the E-LOC technique, conventional hemostatic clips and O-rings are used in combination to achieve closure of post-ESD mucosal defects [9]. These are new techniques that differ from simple closure with clips and are expected to reduce the incidence of adverse events in rectal ESD. However, mucosal defect closure by OTSC or E-LOC may be more difficult than colorectal ESD itself if one or more of the following conditions exist in the colon rather than the rectum: narrow lumen, too long colon, right-sided deep colon, or limited endoscopic maneuverability. To overcome these difficult conditions, we have invented and reported the reopenable clip-over-the-line method (ROLM) using only a clip and a nylon line, and this does not require withdrawal and reinsertion of the endoscope [10, 11]. Although ROLM is a novel closure method, it is difficult to demonstrate its feasibility based on our case reports alone. Therefore, the present study was designed to demonstrate the feasibility of ROLM in a series of 30 consecutive cases without limitations of lesion location or size.

## Patients and methods

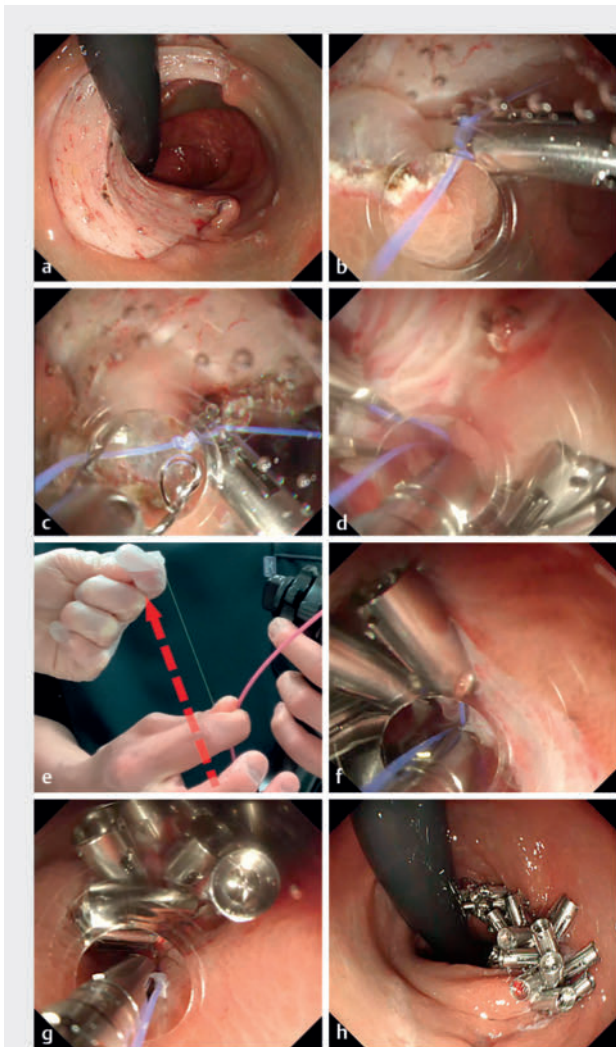
### Study design and patients

This study included 30 patients who underwent colorectal ESD at the Ise Red Cross Hospital and Mie Prefectural Shima Hospital between October 2020 and September 2022. The ROLM closure procedures were performed consecutively by one endoscopist (T.N.). Study-eligible patients were those with mucosal defects >30 mm after ESD for colorectal tumors, aged  $\geq 20$  years, and who provided informed consent. The exclusion criterion was a

circumferential intestinal defect post-ESD. This study was performed in compliance with the principles of the Declaration of Helsinki. We obtained approval from the ethics committees of the Ise Red Cross Hospital (Approval Number ER2020–100 dated March 5, 2021) and Mie Prefectural Shima Hospital (Approval Number 16 dated November 29, 2022) as well as written informed consent for study participation from all the patients involved in this study.

### ROLM procedure

Although various endoscopes were used while carrying out ROLM closure, the endoscopes primarily employed were the PCF-H290ZI (Olympus Medical Systems, Tokyo, Japan) and the GIF-Q260J endoscope (Olympus Medical Systems Corp., Tokyo, Japan) models. The attachment cap was a calibrated small-caliber tip with a transparent hood (CAST hood; TOP, Tokyo, Japan) or a cylindrical hood (D-201–10804, Olympus) hood. Additionally, the clip and line used for ROLM closure were a reopenable clip (Sure clip, Micro-tech, Nanjing, China) and a line (4–0 nylon) (► **Fig. 1, Fig. 2, Fig. 3, Video 1**). First, a clip tied with a line (the first clip) was inserted through an accessory channel. Under the endoscopic view, the first clip grasped the edge of the mucosal defect and muscle layer. Next, the end of the line exiting the accessory channel of the endoscope was passed through the hole in one tooth of a second reopenable clip (the second clip). Finally, the second clip was inserted into the endoscope and grasped the mucosal defect edge and muscle on the opposite side of the first clip. Similarly, the next clip with a line through it was placed on the contralateral defect edge. By repeating this procedure, the mucosal defect was gradually closed. Following the complete closure of the defect, the line was cut and the procedure was completed. The line can also be fixed to the clip and normal mucosa using a locking-clip technique as we have previously reported [9]. Alternatively, it is possible to leave approximately 1 cm of thread by cutting the thread using scissor forceps (FS-3L-1, Olympus, Tokyo, Ja-



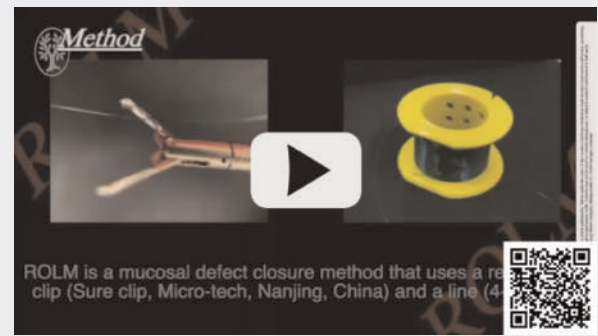
► **Fig. 2** Mucosal defect closure after the endoscopic submucosal dissection (ESD) of a rectal lesion using ROLM. **a** Mucosal defect after ESD of a rectal lesion present over half of the 60-mm rectal lumen. **b** First, a clip with an affixed line is placed to grasp the mucosal defect margin and the muscle layer on the oral side. **c** After passing the line through the tooth hole of the clip, the clip is inserted through the accessory channel. We continue by grasping the defect edge and the adjacent muscle layer on the side opposing the first clip. **d, e, f** With the clips fastened to the tissue, the line at hand is pulled taut to approximate the defect edges, under endoscopic visualization. **g** Alternation in the placement of clips-with-line (with the line threaded through the tooth hole of each clip) completely closes the mucosal defect. **h** The mucosal defect is completely closed on the retroflex view.

pan) or a loop cutter (FS-5L-1; Olympus). The frictional force between the line, clip, and tissue does not cause wound rupture breakage.

### Outcome assessment

The outcome measures were the success rate, duration of the ROLM procedure, and AEs, including post-ESD bleeding and perforation. ROLM procedure success was defined as approxi-

### VIDEO



► **Video 1** Details of the reopenable clip-over-the-line method (ROLM) technique and post-endoscopic submucosal dissection (ESD) defect closure for cases described in this study.

mated mucosa after closure without visible submucosa. ROLM procedure duration was the time from the first clip placement until the last clip placement for defect closure. Post-ESD bleeding was assessed based on the need for emergency endoscopic hemostasis or blood transfusion for bleeding or when hemoglobin levels decreased to  $> 2$  g/dL on post-procedure Day 1. Post-ESD perforation was assessed when free air was confirmed on abdominal computed tomography accompanied by patient complaints of abdominal pain, despite no perforation during the procedure.

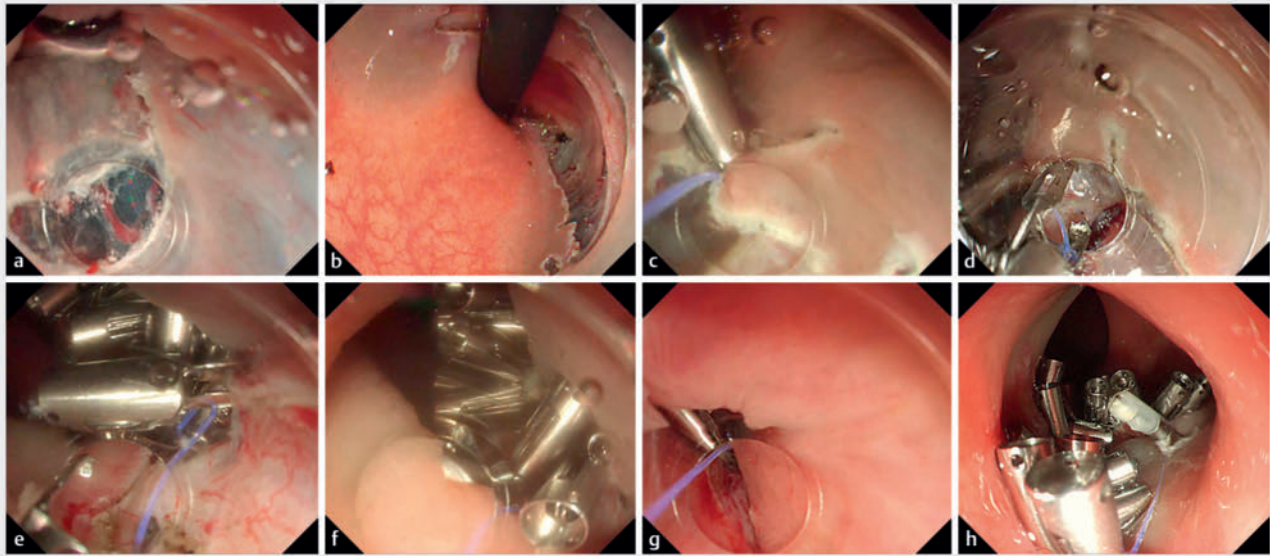
### Results

The characteristics of patients treated with ROLM and their tumors are shown in ► **Table 1**. One lesion was located in the cecum, six in the ascending colon, four in the transverse colon, one in the descending colon, nine in the sigmoid colon, and nine in the rectum. This included nine rectal defects of which three bordered the anal verge. Nine of the 30 defects were larger than half the lumen circumference. The median long axis of the resected specimens measured 45 mm (range, 35–70), and the short axis measured 39 mm (range, 29–60).

The results of ROLM are listed in ► **Table 2**. Defect closure was achieved in 100% (30/30) of cases. The median procedural time of ROLM was 25 minutes (range, 14–52); the median number of clips was 17 (range, 9–42). No postoperative bleeding or perforation was observed after ESD.

### Discussion

The ROLM technique enables closure of large mucosal defects. This technique can be used for mucosal closure in areas with thick mucosa and intrinsic muscles, such as the rectum, and in sites with poor scope maneuverability, such as the colon, including the right colon. In the present study, mucosal defect closure was achieved for all lesions. This included the closure of defects that exceeded half of the bowel circumference and those that were close to the anal verge.



► **Fig. 3** Mucosal defect closure post-endoscopic submucosal dissection (ESD) using ROLM on lesions close to the anal verge. **a** The first incision is placed above the anal verge. **b** A 56-mm mucosal defect bordering the anal verge. **c** The first clip-with-line is placed to grip the defect edge and muscle layer of the oral side. **d** The next clip-with-line (with the line threaded through the tooth hole) is placed on the opposing mucosal defect edge and muscle layer. **e** The defect is gradually closed with the continued placement of clips-with-line. **f** The lumen narrowed accordingly, but the use of a calibrated, small-caliber tip and transparent hood (CAST hood) enables clip placement without burying the clip. **g** The defect is completely closed by placing the clip at the defect edge to the proximal anal verge. **h** The post-ESD mucosal defect after complete closure.

► **Table 1** Characteristics of patients and lesions.

Patient characteristics	
Age, years	69 (53–86)
Sex, male/female	19/11
Lesion location	
Cecum	1
Ascending colon	6
Transverse colon	4
Descending colon	1
Sigmoid colon	9
Rectum	9
Mucosal defect characteristics	
Close to the anal verge	3
Larger than half the colorectal lumen circumference	
Lesion characteristics	
Resected specimen major axis, mm	45 (35–70)
Resected specimen minor axis, mm	39 (29–60)
Adenoma/ adenocarcinoma/ SSL	13/15/2
Adenocarcinoma, Tis (M)/T1a (SM ≤ 1,000 μm)/ T1b > 1,000 μm	11/4/0
Continuous variables are presented as median (range), whereas categorical variables are presented as numbers. M, mucosa; SM, submucosa; SSL, sessile serrated lesion.	

► **Table 2** Reopenable clip-over-the-line method (ROLM) case results.

Outcome	
Defect closure success rate of ROLM, %	100
Procedure time of ROLM, min	25 (14–52)
Number of clips used for each lesion	17 (9–42)
No. patients with post-ESD adverse events	
Post-ESD bleeding, %	0
Post-ESD perforation, %	0
Continuous variables are presented as median (range) and categorical variables as numbers. The success rate and post-ESD adverse events are reported as percentages for 30 patients. ROLM, reopenable clip-over-the-line method; ESD, endoscopic submucosal dissection.	

The most valuable advantage of ROLM is the ability to completely close a mucosal defect simply by placing a reopenable clip on one side of the defect edge. Unlike conventional techniques in which clip closure requires a special device to approximate the defect edges and an extra clip to secure the edges together, ROLM does not require an additional reopenable clip to secure the bilateral edges of defect [12]. Endoscopic hand-suturing [13] and an endoscopic suturing device (OverStitch, Apollo Endosurgery, Austin, Texas, United States) [14] can reliably close mucosal defects, but they both require an adequate intestinal working space to manipulate the endoscope. In contrast, ROLM places a single clip on one side of the defect margin

and does not require a large working space. In addition, ROLM can close the defect as long as an attachment cap is used and the edge where the clip is placed is visible through the endoscope. Because the endoscope does not need to be removed to achieve closure, it is possible to close the defect of the colon on the oral side of the transverse colon following ESD. A total of 11 lesions in the cecum, ascending colon, and transverse colon were included in this study, and closure was achieved in all defects.

Clip closure of large mucosal defects after endoscopic mucosal resection (EMR) can prevent postoperative bleeding [15]. However, the limited clip opening width and an inability to grasp the edges of large mucosal defects can result in uncertain closures. Moreover, EMR is performed for large tumors mainly in Western countries. In this technique, clip closure is especially difficult with the bulging residual mucosa after injections of localized fluids, including hyaluronic acid with its high viscosity. In our experience, when the surrounding mucosa continues to bulge, the tension is increased, making it especially difficult to grasp the defect edges and clip them together. We achieved complete defect closure in this study after ESD using ROLM and hyaluronic acid solution only. We were also able to achieve complete closure of defects at the anal verge and of those that were more than half the bowel circumference. ROLM can be applied to complex defect closures after EMR, as long as at least one defect edge is visible endoscopically. With the ROLM method, using a tapered tip with a hood, including the CAST hood, enables visualization of the defect margins without interference from the previously placed clips [11].

Various closure methods using a loop attached to a clip or line have been devised to close mucosal defect margins [16, 17, 18]. However, the closure of the thick mucosa and muscularis propria of the rectum is difficult because of the narrow width of the clip and the limited grasping force. A specific strong clip, such as the OTSC mentioned previously, is needed. The endoscope must be withdrawn to attach the OTSC to the endoscope tip [8]. With ROLM, the normal mucosa is grasped on one side along with the nearby muscle layer. Pulling the suture line can manually approximate the defect edges. The greater the number of clips, the more force is distributed along the defect edges, thereby bringing the edges together with tension. For large defect closures, a reopenable clip-with-line was placed running through the muscle layer in the center of the mucosal defect only, to minimize the submucosal dead space between the mucosa and muscle layers [3]. E-LOC is a similar method of grasping the muscle layer with a clip; however, the median defect closure of the mucosal defect in the rectum was 29 mm, and closure was achieved in only 24 of 30 defects (80%) [19]. Our study included nine rectal mucosal defects, and all mucosal defects were completely closed with no adverse events.

Although ROLM is a simple technique to implement, there is a learning curve. With a method such as endoscopic hand suturing, it is difficult to achieve closure in the deep colon and good endoscope maneuverability is required [13, 20]. With ROLM, the first deep colon closure will be difficult for a beginner. We previously carried out a prospective study of 50 conse-

cutive cases of mucosal defect closure after gastric ESD [21]. During that time, we identified several technical improvements that enable proper ROLM implementation. We recommend that the endoscopist first acquire experience in implementing this procedure in the stomach and rectum, after which the procedure can be performed in the deep colon, an area that offers less maneuverability. For these reasons, a single expert endoscopist performed all ROLM procedures in this study.

Our study has some limitations. First, this was a small, retrospective case study; therefore, we were unable to investigate the absence of adverse events after ESD. Second, the longevity of closure should be confirmed by additional colonoscopies; it is currently unknown how long the defect closure is maintained. To resolve these issues, a multicenter randomized controlled trial is warranted in the future, with reduced adverse events as the primary objective.

## Conclusions

In conclusion, ROLM is a feasible method for the closure of large colorectal mucosal defects. Moreover, ROLM has the potential for complete closure of rectal defects near the anal verge and ESD defects over half the colon circumference, including the right colon.

## Conflict of Interest

The authors declare that they have no conflict of interest.

## References

- [1] Ohata K, Kobayashi N, Sakai E et al. Long-term outcomes after endoscopic submucosal dissection for large colorectal epithelial neoplasms: a prospective, multicenter, cohort trial from Japan. *Gastroenterology* 2022; 163: 1423–1434.e2
- [2] Liu M, Zhang Y, Wang Y et al. Effect of prophylactic closure on adverse events after colorectal endoscopic submucosal dissection: A meta-analysis. *J Gastroenterol Hepatol* 2020; 35: 1869–1877 doi:10.1111/jgh.15148
- [3] Nomura T, Sugimoto S, Temma T et al. Reopenable clip over-the-line method with muscle layer grasping clips for large duodenal post-endoscopic submucosal dissection defects. *Endoscopy* 2022; 54: E782–E783
- [4] Nomura T, Matsuzaki I, Sugimoto S et al. Clip-on-clip closure method for a mucosal defect after colorectal endoscopic submucosal dissection: a prospective feasibility study. *Surg Endosc* 2020; 34: 1412–1416 doi:10.1007/s00464-019-07195-x
- [5] Kato M, Takeuchi Y, Yamasaki Y et al. Technical feasibility of line-assisted complete closure technique for large mucosal defects after colorectal endoscopic submucosal dissection. *Endosc Int Open* 2017; 5: E11–E16 doi:10.1055/s-0042-121002
- [6] Nomura T, Sugimoto S, Temma T et al. Suturing techniques with endoscopic clips and special devices after endoscopic resection. *Dig Endosc* 2022; 35: 287–301
- [7] Otake Y, Saito Y, Sakamoto T et al. New closure technique for large mucosal defects after endoscopic submucosal dissection of colorectal tumors (with video). *Gastrointest Endosc* 2012; 75: 663–667

- [8] Fujihara S, Mori H, Kobara H et al. The efficacy and safety of prophylactic closure for a large mucosal defect after colorectal endoscopic dissection. *Oncol Rep* 2013; 30: 85–90 doi:10.3892/or.2013.2466
- [9] Tada N, Kobara H, Nishiyama N et al. Endoscopic ligation with O-ring closure for a large artificial defect after rectal endoscopic submucosal dissection. *Dig Liver Dis* 2022; 54: 142–143
- [10] Nomura T, Sugimoto S, Kawabata M et al. Large colorectal mucosal defect closure post-endoscopic submucosal dissection using the reopenable clip over line method and modified locking-clip technique. *Endoscopy* 2022; 54: E63–E64 doi:10.1055/a-1381-6435
- [11] Nomura T, Sugimoto S, Temma T et al. Mucosal defect closure using a calibrated, small-caliber-tip, transparent hood after colorectal endoscopic submucosal dissection. *Endoscopy* 2022; 54: E691–E692 doi:10.1055/a-1750-8800
- [12] Nomura T, Sugimoto S, Nakamura H et al. Reopenable clip over line method for the closure of full-thickness defect after gastric endoscopic full-thickness resection. *Endoscopy* 2022; 54: E808–E809 doi:10.1055/a-1824-4919
- [13] Abe S, Saito Y, Tanaka Y et al. A novel endoscopic hand-suturing technique for defect closure after colorectal endoscopic submucosal dissection: a pilot study. *Endoscopy* 2020; 52: 780–785 doi:10.1055/a-1120-8533
- [14] Kantsevov SV, Bitner M, Mitrov AA et al. Endoscopic suturing closure of large mucosal defects after endoscopic submucosal dissection is technically feasible, fast, and eliminates the need for hospitalization (with videos). *Gastrointest Endosc* 2014; 79: 503–507
- [15] Albéniz E, Álvarez MA, Espinós JC et al. Clip closure after resection of large colorectal lesions with substantial risk of bleeding. *Gastroenterology* 2019; 157: 1213–1221.e4
- [16] Kato M, Takeuchi Y, Yamasaki Y. Line-assisted complete closure of a large colorectal mucosal defect after endoscopic submucosal dissection. *Dig Endosc* 2016; 28: 686 doi:10.1111/den.13052
- [17] Yamasaki Y, Takeuchi Y, Iwatsubo T et al. Line-assisted complete closure for a large mucosal defect after colorectal endoscopic submucosal dissection decreased post-electrocoagulation syndrome. *Dig Endosc* 2018; 30: 633–641 doi:10.1111/den.13052
- [18] Yoshida A, Kurumi H, Ikebuchi Y et al. New closure method using loop and open-close clips after endoscopic submucosal dissection of stomach and colon lesions. *J Clin Med* 2021; 10: 3260 doi:10.3390/jcm10153260
- [19] Tada N, Kobara H, Nishiyama N et al. Endoscopic ligation with O-ring closure for mucosal defects after rectal endoscopic submucosal dissection: a feasibility study (with video). *Digestion* 2023; 11: 1–10
- [20] Akimoto T, Goto O, Sasaki M et al. Endoscopic suturing promotes healing of mucosal defects after gastric endoscopic submucosal dissection: endoscopic and histologic analyses in in vivo porcine models (with video). *Gastrointest Endosc* 2020; 91: 1172–1182
- [21] Nomura T, Sugimoto S, Temma T et al. Reopenable clip-over-the-line method for closing large mucosal defects following gastric endoscopic submucosal dissection: Prospective feasibility study. *Dig Endosc* 2022; 35: 505–511 doi:10.1111/den.14466