

OPEN

# Antiphospholipids Syndrome Complicated by a Systemic Capillary Leak-Like Syndrome Treated With Steroids and Intravenous Immunoglobulins

## A Case Report

Marcella Prete, MD, PhD, Livio Urso, MD, Maria Celeste Fatone, MD, Vincenzo Pinto, MD, and Federico Perosa, MD, PhD

**Abstract:** This report describes the onset of systemic capillary leak (SCL)-like syndrome in a 30-year-old woman with antiphospholipids syndrome (APS) during puerperium.

Twelve hours after a cesarean section, she presented a sudden fever and abdominal pains followed by dyspnea, severe edema of the limbs and pelvis.

Computer tomography shows congestion of interstitial pulmonary parenchyma, pericardial and pleural effusion, edema of intestinal wall and of perivisceral adipose tissue, and periportal lymphedema. Laboratory tests showed neutrophilic leukocytosis, hypoalbuminemia, and an increase of erythrocyte sedimentation rate and C-reactive protein. Because fever and raised inflammation parameters are not observed in idiopathic capillary leak syndrome (SCLS; Clarkson disease), a diagnosis of SCL-like syndrome was made.

Albumin solution, high-dose methylprednisolone and intravenous immunoglobulins (IVIG) infusion were administered with a rapid improvement of her clinical condition.

The prompt treatment with steroids and IVIG likely prevented the life-threatening shock syndrome that can occur in SCLS, with acute hypotensive attacks, and severe limbs edema requiring fasciotomy.

All clinical and laboratory findings supported autoinflammation as the underlying pathogenic mechanism of the syndrome. The data indicate that SCL-like syndrome can be considered a novel clinical syndrome, which can complicate APS.

(*Medicine* 95(5):e2648)

**Abbreviations:** aCL = anticardiolipin antibodies, ANA = antinuclear antibodies, APS = antiphospholipid syndrome, CAPS = catastrophic antiphospholipid syndrome, CRP = C-reactive protein, CT = computed tomography, ENA = extractable nuclear antigen, ESR = erythrocyte sedimentation rate, IVIG = intravenous

immunoglobulins, SCL = systemic capillary leak, sPAP = systolic pulmonary arterial pressure.

## INTRODUCTION

Idiopathic systemic capillary leak syndrome (SCLS; Clarkson disease) features transient, severe hypotensive shock, hypoalbuminemia, and anasarca. It is caused by a reversible microvascular barrier dysfunction characterized by the leakage of fluids and macromolecules (up to 900 kDa) into the extravascular compartment.<sup>1,2</sup> This very rare condition was recognized for the first time as a distinct clinical entity by Dr Bayard Clarkson in 1960.<sup>3</sup> Most of the cases reported in the literature were associated to a serum monoclonal component,<sup>1,2,4-6</sup> none of which was reported in the context of antiphospholipid syndrome (APS). The 5-year overall survival rate of SCLS has been estimated to range between 59% and 97%, depending on complications related to the acute phase of the disease characterized by severe limb edema, often requiring fasciotomy and by severe hypotensive shock, requiring intensive care therapy.<sup>4,7</sup>

Herein, we report the case of a young woman affected by APS who, after a caesarean section, rapidly developed widespread peripheral and internal tissues edema with no apparent cause, a condition resembling an SCLS.

## Case Report

A 30-year-old Caucasian woman with a mild mitral valve prolapse, osteopenia, and APS presented with fever, chills, and abdominal pains that arose suddenly 12 h after an uncomplicated delivery. The diagnosis of primary APS had been made in 1999 on the basis of the detection of a postischemic area of gliosis at the cerebellar vermis as well as increased lupus anticoagulant and anticardiolipin antibodies (aCL) levels (31.9 MpL/mL; normal range 0–15). She had also complained of mild arthralgia, successfully treated with low-dose prednisone, whereas acetyl salicylic acid was given for ischemic prophylaxis. Diagnostic criteria for systemic lupus erythematosus were never satisfied. In 2011, she suffered a first-trimester miscarriage. In January 2012, when she became pregnant again, therapy with enoxaparin sodium (6000 IU/day) was added. Immunological screening showed positive antinuclear antibodies (ANA) (titer 1:160), low positivity for aCL, and a reduced C4 complement fragment, whereas antidualstranded DNA Ab and -ENA were consistently negative. No monoclonal component was noted. C-reactive protein (CRP) and erythrocyte sedimentation rate (ESR) were within normal range. Due to asymmetrical intrauterine fetal growth retardation, a lower segment caesarean section was planned for

Editor: Ken Rosenthal.

Received: December 11, 2015; revised: December 31, 2015; accepted: January 6, 2016.

From the Department of Biomedical Science and Human Oncology (DIMO), Systemic Rheumatic and Autoimmune Diseases Unit (MP, LU, MCF, FP); and Second Unit of Obstetrics and Gynecology, University of Bari Medical School (VP), Bari, Italy.

Correspondence: Federico Perosa, Department of Biomedical Science and Human Oncology (DIMO), Systemic Rheumatic and Autoimmune Diseases Unit, University of Bari Medical School, Bari, Italy (e-mail: federico.perosa@uniba.it).

The authors have no conflicts of interest to disclose.

Copyright © 2016 Wolters Kluwer Health, Inc. All rights reserved.

This is an open access article distributed under the Creative Commons Attribution-NoDerivatives License 4.0, which allows for redistribution, commercial and non-commercial, as long as it is passed along unchanged and in whole, with credit to the author.

ISSN: 0025-7974

DOI: 10.1097/MD.0000000000002648

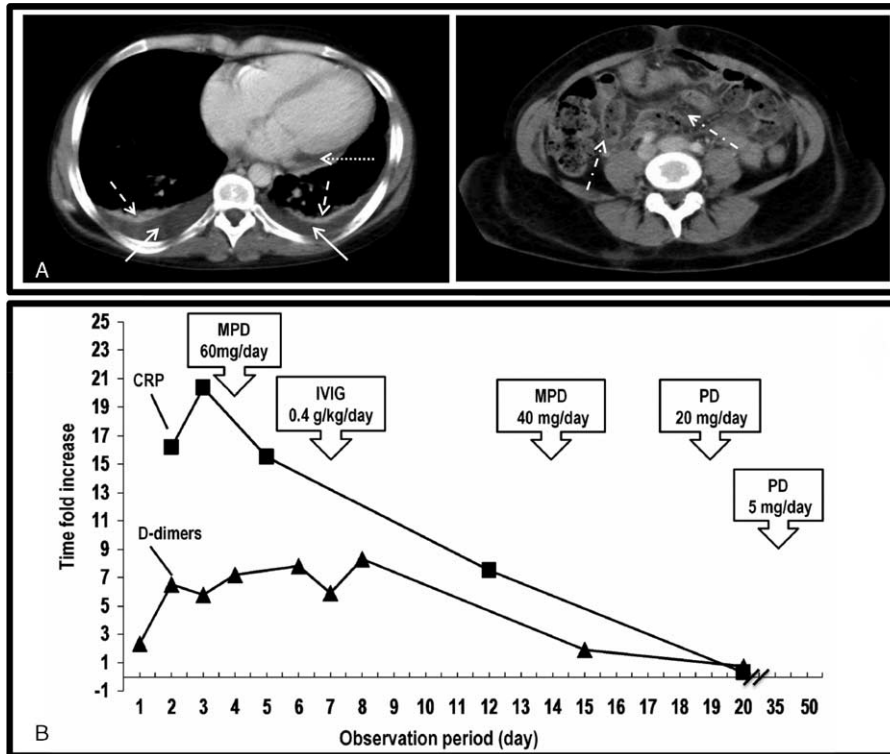
the 38th week of gestation. The newborn was alive and vital (weight 2300 g, APGAR index 8). Twelve hours after delivery, despite prophylactic therapy with metronidazole benzoate, levofloxacin and cefazoline, she rapidly developed a continuous remitting fever of up to 39°C, with chills and abdominal pain in the epigastrium and mesogastrium. On physical examination, blood pressure was 100/60 mm Hg and heart rate 70 beats per minute; the abdomen was painful on palpation of all quadrants; visible mucous membranes were dehydrated. She was given supportive therapy with electrolytic solutions and rifaximin. On the second day after delivery she complained of sudden dyspnea and severe edema of the pelvis and of proximal and distal parts of the limbs. Computed tomography (CT) pulmonary angiography, CT angiography of the abdominal vessels, and abdominal x-ray excluded signs of pulmonary embolism, arterial and venous thrombosis of abdominal vessels and intestinal occlusion. Chest–abdomen–pelvis CT showed interstitial pulmonary parenchymal congestion, bilateral pleural effusions associated with atelectasis, cardiomegaly, congestion of the liver with periportal edema, peritoneal effusion, distension of the gallbladder, and ileal and colonic loops. Edema of the entire intestinal wall and of perivisceral adipose tissue was observed (Figure 1, panel A). Transthoracic Doppler echocardiogram revealed a mild enlargement of the whole heart, a slight dilatation of the inferior vena cava, minor mitral valve prolapse, an estimated pericardial effusion of 200 to 500 mL, an estimated systolic pulmonary arterial pressure (sPAP) of 25 mm Hg, mild mitral and tricuspid regurgitation and normal

systolic function (EF 60%). Other findings included neutrophilic leukocytosis, increased erythrocyte sedimentation rate (ESR), D-dimers, C-reactive protein (CRP) and fibrinogen, red blood cell count at the lower normal limits, normochromic normocytic anemia with no schistocytes, along with a decreased potassium, albumin concentration, and platelets count (Table 1). ANA positivity (titer: 1:640) and the presence of lupus anticoagulant were detected. Microbiological cultures, virological tests, and procalcitonin were negative. 24-hour urine protein was 300 mg.

Based on these data, a diagnosis of a systemic capillary leak (SCL)-like syndrome was made. Albumin solution and methylprednisolone (60 mg/day) were added to the previous therapy. Intravenous immunoglobulins (IVIg) infusion (0.4 g/kg/day for 5 days) were started on the seventh day. After a few days her clinical conditions rapidly improved, and she developed marked polyuria. Hemoglobin, leukocytes, albumin, potassium, D-dimers, and inflammatory indices gradually returned to normal (representative results in Figure 1, panel B). At 3 months follow-up, she was in good health and laboratory tests were normal. Finally, the enoxaparin was switched to acetyl salicylic acid.

**DISCUSSION**

Transient, severe hypotensive shock, anasarca, and hypoalbuminemia in the absence of nephrotic proteinuria are typical features of SCLS. Some of the signs of SCLS were present in our patient, namely edema of the peripheral and



**FIGURE 1.** (A) Computerized axial tomography of chest (left panel) and abdomen-pelvis (right panel) during the acute event and (B) C-reactive protein and D-dimers changes during the acute event and in the days after therapy was started. (A) Bilateral pleural effusions (continuous arrows) associated to atelectasis (dashed arrow); cardiomegaly and pericardial effusion (dotted arrow); edema of the intestinal wall and of perivisceral adipose tissue (dashed-dotted arrows). (B) CRP and D-dimers are expressed as time fold increase above normal reference values. CRP=C-reactive protein, IVIG=high-dose intravenous immunoglobulins, MPD=methylprednisolone, PD=prednisolone.

**TABLE 1.** Patient’s Laboratory Data at Onset

	Analysis	Values (IS)	Normal Range
Blood	Erythrocytes	$4.08 \times 10^{12}/L$	(4.00–5.20)
	Leukocytes	$15.29 \times 10^9/L$	(3.54–9.06)
	Neutrophils	0.96	(0.40–0.70)
	Lymphocytes	0.03	(0.20–0.50)
	Monocytes	0.01	(0.04–0.08)
	Eosinophils	0	(0.0–0.6)
	Basophils	0	(0.0–0.02)
	Hemoglobin	95 g/L	(120–158)
	Hematocrit	0.29	(0.35–0.44)
	MCV	88.1 fL	(79–93.3)
	MCHC	329 g/L	(323–359)
	Platelets count	$124 \times 10^9/L$	(165–415)
	Creatinine	73.33 $\mu\text{mol}/L$	(44–80)
	Urea nitrogen	2.17 mmol/L	(2.5–7.1)
	Glucose	3.7 mmol/L	(3.6–5.3)
	AST	35 U/L	(15–37)
	ALT	19 U/L	(12–78)
	Amylase	52 U/L	(20–96)
	Lipase	355 U/L	(73–393)
	Total bilirubin	15.3 $\mu\text{mL}/L$	(5.1–22)
	Albumin	21 g/L	(40–50)
	Potassium	2.9 mmol/L	(3.5–5.0)
	Sodium	147 mmol/L	(136–146)
	Chloride	112 mmol/L	(102–109)
	ESR	66 mm/h	(1–20)
	CRP	204 mg/L	(<10)
	NT-proBNP	1794 ng/L	(< 125 up to 75 years)
	Troponin T	<0.015 $\mu\text{g}/L$	(0–0.01)
	D-dimers	1794 ng/mL	(< 300)
	PT	12.2 s	(12.7–15.4)
	PTT	37.3 s	(26.3–39.4)
	TT	18.2 s	(15.3–18.5)
	Functional Antithrombin III	0.76 U/L	(0.7–1.30)
Fibrinogen	8.48 g/L	(2.33–4.96)	
Total protein	51 g/L	(67–86)	
C3	1.04 g/L	(0.83–1.77)	
C4	0.2 g/L	(0.16–0.47)	
Procalcitonin	0.1 $\mu\text{g}/L$	(< 0.1)	
Urine	pH	6.5	(5.0–9.0)
	Glucose	0 mg/dL	(0–10.0)
	Protein	100 mg/dL	(<30)
	Hemoglobin	0.00 mg/dL	(0–0.03)
	Ketones	15 mg/dL	(0–5)
	Bilirubin	0.0 mg/dL	(0–0.2)
	Urobilinogen	0.2 mg/dL	(0.2–1)
	Leukocytes	0 Leu/ $\mu\text{L}$	(0–25)
Blood gas analysis	Urinary sediment abnormality	None	
	pH	7.45	7.35–7.45
	pCO <sub>2</sub>	29.90 mm Hg	35–45
	pO <sub>2</sub>	74.00 mm Hg	80–100
	HCO <sub>3</sub> <sup>-</sup>	20.20 mmol/L	21–29

ALT = alanine transaminase, AST = aspartase transaminase, CRP = C-reactive protein, ESR = erythrocyte sedimentation rate, MCHC = mean corpuscular haemoglobin concentration, MCV = mean corpuscular volume, PT = prothrombin time, PTT = partial thromboplastin time, TT = thrombin time.

internal tissues, hypoalbuminemia (Table 2).<sup>8,9</sup> The normal procalcitonin values, the absence of nephrotic proteinuria, negative blood microbiological cultures along with the results of virological tests and transthoracic Doppler echocardiogram ruled

out a number of clinical conditions which could have mimicked SCLS. These included nephrotic syndrome, sepsis, or heart dysfunction.<sup>1,4</sup> Even so, the diagnosis of SCLS “sensu strictiore” could not be formulated because of the presence of high

**TABLE 2.** Clinical Profile of Idiopathic Systemic Capillary Leak Syndrome (SCLS)<sup>8</sup> and Classification Criteria of Catastrophic Antiphospholipid Syndrome (CAPS),<sup>9</sup> Compared to the Clinical and Laboratory Characteristics in Our Patient

Clinical and Laboratory Features	SCLS*	CAPS†	Our Patient
Severe attacks of hypotension	+		–
Hemoconcentration	+		–
Hypoalbuminemia	+		+
Severe edema	+		+
Evidence of involvement of 3 organs, systems, and/or tissues		+	+
Development of manifestations simultaneously or in <1 week		+	+
Confirmation by histopathology of small vessels occlusion in at least 1 organ/tissue		+	N.D.
Laboratory confirmation of the presence of aPL (LAC and/or aCL and/or anti-β2GPI at titers exceeding 40 UI/I)		+	+

aCL = anticardiolipin antibodies, anti-β2GPI = anti-β2glycoprotein antibodies, aPL = antiphospholipid antibodies, CAPS = catastrophic antiphospholipid syndrome, N.D. = not determined, SCLS = systemic capillary leak syndrome, WBC = white blood cells.

\* All criteria are required for the diagnosis of SCLS, after the exclusion of other causes of edema.

† Definite CAPS includes all 4 criteria; probable CAPS: all 4 criteria, except for the involvement of only 2 organs, systems, and/or tissues; or all 4 criteria, except for the absence of laboratory confirmation at least 6 weeks apart associated to the early death of a patient never tested for aPL before the onset of CAPS; or 1, 2, and 4 criteria; or 1, 3, and 4, plus the development of a third event in >1 week but <1 month, despite anticoagulation treatment.

fever and increased inflammation parameters (neutrophilic leukocytosis, ESR, CRP, and D-dimers), which are not usually observed in SCLS.<sup>1</sup> Therefore, the diagnosis of SCL-like syndrome was made.

SCLS has been reported to be mostly associated with monoclonal gammopathies of undetermined significance, typed as IgG kappa in 89% of cases, that have a mortality rate ranging between 35% and 70%.<sup>4,5</sup> There has been 1 report of the syndrome occurring as the clinical presentation of Kawasaki disease.<sup>10</sup> The pathogenic mechanisms underlying microvascular barrier dysfunction are unknown. It is thought that in some patients with SCLS, inflammatory cytokines may play a role in inducing and/or maintaining microvascular permeability. The increased serum IL-6 and TNF-α levels,<sup>11,12</sup> the improved clinical condition obtained in some patients with TNF inhibitors during acute episodes,<sup>11</sup> and the use of IVIG both in the acute phase and as disease prophylaxis,<sup>5,13,14</sup> support this view.<sup>11,12</sup> A similar conclusion can be reached for the syndrome described here, in which the presence of high fever, neutrophilic leukocytosis and high serum CRP levels, besides the prompt response to steroids and IVIG, supported autoinflammation as the underlying pathogenic mechanism. The same pathogenic mechanism has also been recognized as responsible for catastrophic APS (CAPS), a rare but severe complication of APS, characterized by a sudden onset of multi-organ failure due to widespread microthrombosis,<sup>15–17</sup> puerperium being one of the triggering factors.<sup>18</sup>

Interestingly, a comparison of the 4 classification criteria which define CAPS<sup>9</sup> with the clinical and laboratory characteristics in our patients showed that at least 3 of them were present. These criteria were (1) the evidence of involvement of 3 organs, systems, and/or tissues, (2) the development of manifestations simultaneously in <1 week, and (3) the positive APS serology (Table 2). These similarities raised the question whether or not SCL-like syndrome and CAPS are 2 different clinical entities or could be considered 2 sides of the same autoinflammation process complicating APS in the presence of specific triggering factors (eg puerperium or other prothrombotic conditions).<sup>15,19</sup>

The case reported here highlights that SCL-like syndrome may arise as a complication of APS and warrants therapy of the

type administered for CAPS. It is likely that the prompt treatment and response to therapy in our patient prevented the life-threatening shock syndrome, related to acute hypotensive attacks, and the more severe limbs edema requiring fasciotomy, as observed in the acute phase of SCLS.

## CONSENT

Written informed consent was obtained from the patient before and after all procedures, and for the publication of this report.

## ACKNOWLEDGMENTS

The authors are grateful to Mr. Vito Iacovizzi for his excellent secretarial assistance. They thank Mary V. Pragnell BA for language assistance.

## REFERENCES

- Druey KM, Greipp PR. Narrative review: the systemic capillary leak syndrome. *Ann Intern Med.* 2010;153:90–98.
- Zancanaro A, Serafini F, Fantin G, et al. Clinical and pathological findings of a fatal systemic capillary leak syndrome (Clarkson disease): a case report. *Medicine (Baltimore).* 2015;94:e591.
- Clarkson B, Thompson D, Horwith M, et al. Cyclical edema and shock due to increased capillary permeability. *Am J Med.* 1960;29:193–216.
- Kapoor P, Greipp PT, Schaefer EW, et al. Idiopathic systemic capillary leak syndrome (Clarkson's disease): the Mayo clinic experience. *Mayo Clin Proc.* 2010;85:905–912.
- Gousseff M, Arnaud L, Lambert M, et al. The systemic capillary leak syndrome: a case series of 28 patients from a European registry. *Ann Intern Med.* 2011;154:464–471.
- Rabbolini DJ, Ange N, Walters GD, et al. Systemic capillary leak syndrome: recognition prevents morbidity and mortality. *Intern Med J.* 2013;43:1145–1147.
- Lamou H, Grassmann JP, Betsch M, et al. Systemic capillary leak syndrome associated with a rare abdominal and four-limb compartment syndrome: a case report. *J Med Case Rep.* 2014;8:196.

8. Xie Z, Ghosh CC, Patel R, et al. Vascular endothelial hyperpermeability induces the clinical symptoms of Clarkson disease (the systemic capillary leak syndrome). *Blood*. 2012;119:4321–4332.
9. Cervera R, Rodriguez-Pinto I, Colafrancesco S, et al. 14th International Congress on Antiphospholipid Antibodies Task Force Report on Catastrophic Antiphospholipid Syndrome. *Autoimmun Rev*. 2014;13:699–707.
10. Natterer J, Perez MH, Di BS. Capillary leak leading to shock in Kawasaki disease without myocardial dysfunction. *Cardiol Young*. 2012;22:349–352.
11. Dowden AM, Rullo OJ, Aziz N, et al. Idiopathic systemic capillary leak syndrome: novel therapy for acute attacks. *J Allergy Clin Immunol*. 2009;124:1111–1113.
12. Xie Z, Ghosh CC, Parikh SM, et al. Mechanistic classification of the systemic capillary leak syndrome: Clarkson disease. *Am J Respir Crit Care Med*. 2014;189:1145–1147.
13. Sheehan JR, Keating L, Chan A, et al. Distributive shock due to systemic capillary leak syndrome treated with high-dose immunosuppression. *BMJ Case Rep*. 2013; doi:10.1136/bcr-2013-009048.
14. Xie Z, Chan EC, Long LM, et al. High-dose intravenous immunoglobulin therapy for systemic capillary leak syndrome (Clarkson disease). *Am J Med*. 2015;128:91–95.
15. Asherson RA, Cervera R, Piette JC, et al. Catastrophic antiphospholipid syndrome: clues to the pathogenesis from a series of 80 patients. *Medicine (Baltimore)*. 2001;80:355–377.
16. Gomez-Puerta JA, Martin H, Amigo MC, et al. Long-term follow-up in 128 patients with primary antiphospholipid syndrome: do they develop lupus? *Medicine (Baltimore)*. 2005;84:225–230.
17. Cervera R, Bucciarelli S, Plasín MA, et al. Catastrophic antiphospholipid syndrome (CAPS): descriptive analysis of a series of 280 patients from the “CAPS Registry”. *J Autoimmun*. 2009;32:240–245.
18. Asherson RA, Cervera R, de Groot PG, et al. Catastrophic antiphospholipid syndrome: international consensus statement on classification criteria and treatment guidelines. *Lupus*. 2003;12:530–534.
19. Espinosa G, Cervera R, Asherson RA. Catastrophic antiphospholipid syndrome and sepsis. A common link? *J Rheumatol*. 2007;34:923–926.