




OPEN ACCESS

A proposed classification for intrauterine device position: the Tal-Reeves classification

Michael G Tal,¹ Matthew F Reeves ,^{2,3,4,5} Mark J Hathaway,⁶ Juan M Canela,⁷ Bob Katz⁸

¹Hadassah Medical Center, Jerusalem, Israel

²DuPont Clinic, Washington, DC, USA

³Department of Obstetrics & Gynecology, Stanford University School of Medicine, Stanford, California, USA

⁴Department of Obstetrics & Gynecology, The George Washington University School of Medicine and Health Sciences, Washington, DC, USA

⁵Department of Population, Family, and Reproductive Health, Johns Hopkins Bloomberg School of Public Health, Baltimore, Maryland, USA

⁶Jhpiego, Baltimore, MD, USA

⁷La Clinica Canela, La Romana, Dominican Republic

⁸ForwardVue Pharma, Inc, San Jose, California, USA

Correspondence to

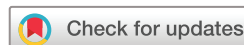Dr Matthew F Reeves, DuPont Clinic, Washington, District of Columbia, USA; mreeves5@jhu.edu

Received 10 September 2021

Accepted 25 October 2021

Published Online First

13 June 2022



© Author(s) (or their employer(s)) 2022. Re-use permitted under CC BY-NC. No commercial re-use. See rights and permissions. Published by BMJ.

To cite: Tal MG, Reeves MF, Hathaway MJ, et al. *BMJ Sex Reprod Health* 2022;**48**:157–159.

BACKGROUND

The lack of a common system for classification of intrauterine device (IUD) position is problematic. In one study, where IUD position was determined by expert opinion alone, increased IUD removal resulted in more pregnancies, while no pregnancies occurred among those with a ‘mal-positioned’ IUD with no specific criteria used.¹ In practice, physicians often see patients with IUDs located in different areas of the uterus and the position changes over time.² After initial placement, some IUDs are found higher in the uterus while others are found lower. Aside from the multiple locations of the IUD in the uterus, unilateral or bilateral ‘embedment’ or penetration of the IUD’s arms into the myometrium is also common. Patients using IUDs often present symptoms relating to the device including pain, menstrual cramps and bleeding. The symptoms may be related to the position of the IUD in the uterus and the amount of arm embedment into the myometrium, but without a system for classification of position, it is not possible to conduct adequate clinical research on the relationship between position and symptoms.

Terminology for describing IUD location has not been standardised.^{1 3 4} IUD position has been studied in terms of relationship to the uterine fundus.^{5 6} However, in clinical practice, the distance from the uterine fundus is irrelevant. The distance from the fundus depends on the size of uterine cavity rather than migration. If the uterine cavity is large and the IUD is within the uterine cavity, the distance from the fundus has no known clinical value. In contrast, in a small nulliparous uterus, an IUD which is 2 cm from the fundus may extend into the cervix. Furthermore, symptoms do not correlate with the distance between

the IUD and uterine fundus and the distance to the fundal-most portion of endometrial cavity.⁷ Not surprisingly, the position of the IUD changes during the menstrual cycle.² Movement within the uterine cavity is normal, but, as an *intra-uterine* contraceptive, the IUD should not be located below the internal cervical os, the anatomic landmark defining the start of the uterine cavity. Using distance from the fundus, the location of the IUD relative to the internal cervical os is not captured.

Similarly, extension of the arms of an IUD into the myometrium (commonly referred to as ‘embedment’) has been associated with pain and bleeding.⁸ Thus it is important to capture intramural extension of IUD arms in a classification of IUD position. Currently, this imaging feature is not routinely used as part of the imaging description of the position of IUDs.

We developed this classification system over the course of a randomised study of two copper IUDs. In one arm of this study, we performed transvaginal ultrasonography and hysterosalpingography before and after each insertion of 99 copper T-shaped IUDs (T380S). At 3-month intervals over the first year, we performed transvaginal ultrasonography and, if ultrasonography was not clearly normal, we also performed hysterosalpingography. During the course of the study we observed a substantial number of participants with partial expulsion and intramural extension of the arms, leading to the development of this classification system. However, as this classification system developed through discussion over the course of the study, we did not classify IUD position prospectively to allow correlation with symptoms.

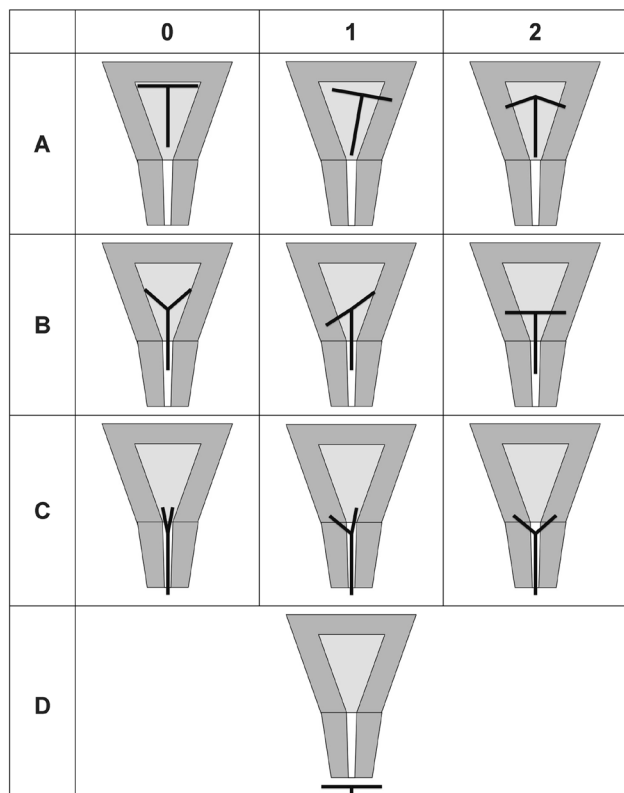


Figure 1 Conceptual diagram of the Tal-Reeves classification of intrauterine device position.

PROPOSED IUD POSITION CLASSIFICATION

We propose classifying IUD position based on IUD location in relation to the cervix and intramural extension of the IUD arms, using a two-part nomenclature of one letter and one number. The letter defines the position of the inferior-most point of the IUD: (A) above the internal cervical os (ICO); (B) inferior tip of IUD is below the ICO; (C) IUD completely within the cervix, usually visible on speculum examination; and (D) IUD outside cervix (complete expulsion). We classified the IUD arms as follows: (0) no intramural extension; (1) unilateral; or (2) bilateral extension into the myometrium. **Figure 1** shows conceptual diagrams of the classification system. **Figures 2 and 3** show examples of hysterosalpingogram and ultrasonographic images, respectively, of this classification system.

DISCUSSION

We propose a simple, feasible and practical classification that uses the position of the IUD in relation to the internal os rather than the fundus. Modern ultrasound imaging enables visualisation of the location of the IUD in relationship to the cervical os as well as extension into the myometrium. The goal of the Tal-Reeves classification system is to allow standardisation of reporting of IUD location both for clinical use and research for evaluation of new IUD designs. The system proposed is based on the concept that defining

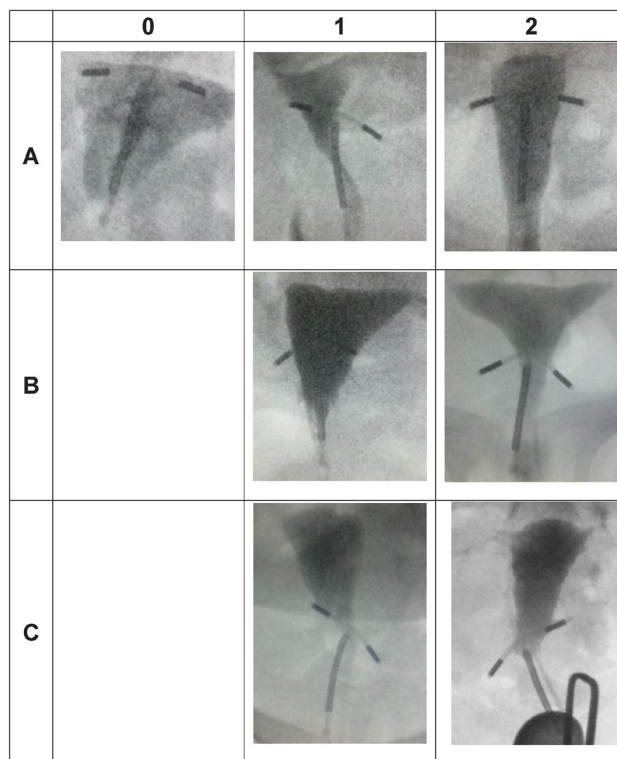


Figure 2 Hysterosalpingogram images of the Tal-Reeves classification of intrauterine device position.

‘normal position’ is less important than defining what is abnormal.

This system does not include IUD position within the abdomen or other unusual positions which are, fortunately, much less common. Although these IUD locations are well known, over 130 person-years of observation with the T380S we did not find any cases that could not be described using this system, indicating the relative infrequency that other positions are observed. Importantly, those rare IUD positions can be accurately described based on other anatomic landmarks. Adding those positions to the proposed system is unlikely to be useful.

We believe that the proposed system parsimoniously balances precision with simplicity. Although one could contemplate measuring the distance that the IUD lies above or below the internal os, the distance is only relevant for a particular uterus. For example, an IUD 4cm below the internal os could be in position B (inside the cervix) for a patient with a 5 cm cervix, or for a patient with a 3 cm cervix, the IUD could be in position C, extending outside the external os.

On ultrasound imaging, the relationship of the bottom of the IUD and the internal os is easily identified by anyone experienced in sonography (**figure 3**). The difference between classification A and B is defined simply by that relationship. If it is above the internal os it is A (Above), and if it is below, it is B (Below). If it is seen through the cervix (you can ‘C’ it) it is C, and if it is not seen at all it is D (Disappeared).

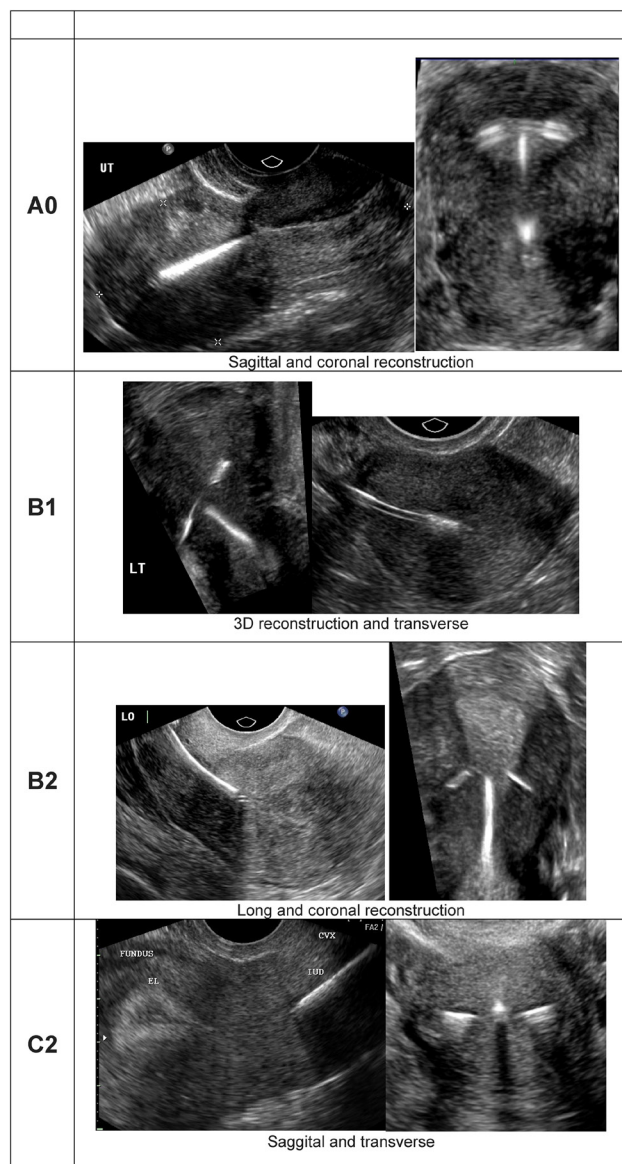


Figure 3 Ultrasonographic images of the Tal-Reeves classification of intrauterine device position.

We observed excellent correlation between hysterosalpingography and ultrasonography findings, suggesting that the classification can be made based on ultrasound imaging alone.

Imaging of IUDs is increasingly common both in clinical practice and in research. We need a common language to communicate the IUD position. In newer IUD efficacy studies, ultrasonography is used almost universally but with differing definitions of partial expulsion.^{9 10} The use of a classification system would provide a common language for communicating IUD position. We believe that the Tal-Reeves classification proposed here can fulfil that need. In the future, we hope that having a common language for reporting IUD position will facilitate research into the relationship between position and clinical outcomes.

Twitter Matthew F Reeves @reevesdupont

Contributors MGT and MFR developed the concepts and wrote the manuscript. MJH, JMC and BK assisted in development of the concepts and critically reviewed the manuscript.

Funding The authors have not declared a specific grant for this research from any funding agency in the public, commercial or not-for-profit sectors.

Competing interests MFR, MJH and JMC were consultants for ContraMed and now Sebela Pharma. MGT and BK were employees of ContraMed LLC. MJH does Nexplanon training for Merck.

Patient consent for publication Not applicable.

Ethics approval Not applicable.

Provenance and peer review Not commissioned; externally peer reviewed.

Open access This is an open access article distributed in accordance with the Creative Commons Attribution Non Commercial (CC BY-NC 4.0) license, which permits others to distribute, remix, adapt, build upon this work non-commercially, and license their derivative works on different terms, provided the original work is properly cited, appropriate credit is given, any changes made indicated, and the use is non-commercial. See: <http://creativecommons.org/licenses/by-nc/4.0/>.

ORCID iD

Matthew F Reeves <http://orcid.org/0000-0001-7749-7447>

REFERENCES

- 1 Braaten KP, Benson CB, Maurer R, *et al*. Malpositioned intrauterine contraceptive devices: risk factors, outcomes, and future pregnancies. *Obstet Gynecol* 2011;118:1014–20.
- 2 Faúndes D, Bahamondes L, Faúndes A, *et al*. T-shaped IUD move vertically with endometrial growth and involution during the menstrual cycle. *Contraception* 1998;57:413–5.
- 3 Shipp TD, Bromley B, Benacerraf BR. The width of the uterine cavity is narrower in patients with an embedded intrauterine device (IUD) compared to a normally positioned IUD. *J Ultrasound Med* 2010;29:1453–6.
- 4 Boortz HE, Margolis DJA, Ragavendra N, *et al*. Migration of intrauterine devices: radiologic findings and implications for patient care. *Radiographics* 2012;32:335–52.
- 5 Aleem HA, Kamel HS, Aboul-Oyoun EM. Role of ultrasonography in managing IUD-related complaints. *Contraception* 1992;46:211–20.
- 6 Petta CA, Faúndes D, Pimentel E, *et al*. The use of vaginal ultrasound to identify copper T IUDs at high risk of expulsion. *Contraception* 1996;54:287–9.
- 7 Faúndes D, Bahamondes L, Faúndes A, *et al*. No relationship between the IUD position evaluated by ultrasound and complaints of bleeding and pain. *Contraception* 1997;56:43–7.
- 8 Benacerraf BR, Shipp TD, Bromley B. Three-dimensional ultrasound detection of abnormally located intrauterine contraceptive devices which are a source of pelvic pain and abnormal bleeding. *Ultrasound Obstet Gynecol* 2009;34:110–5.
- 9 Eisenberg DL, Schreiber CA, Turok DK, *et al*. Three-year efficacy and safety of a new 52-mg levonorgestrel-releasing intrauterine system. *Contraception* 2015;92:10–16.
- 10 Nelson A, Apter D, Hauck B, *et al*. Two low-dose levonorgestrel intrauterine contraceptive systems: a randomized controlled trial. *Obstet Gynecol* 2013;122:1205–13.