

Regression of lumbar disc herniation with non-surgical treatment: a case report

Journal of International Medical Research

49(6) 1–5

© The Author(s) 2021

Article reuse guidelines:

sagepub.com/journals-permissions

DOI: 10.1177/03000605211020636

journals.sagepub.com/home/imrRui Wang  and Huasong Luo 

Abstract

To date, only a few reports have described the regression of lumbar disc herniation, which may be because of a failure to follow up patients treated conservatively. We report a case of a 25-year-old man who presented with a 2-month history of pain and soreness owing to lumbar disc herniation. He was managed conservatively, and his presenting symptoms and scoliosis gradually decreased over approximately 5 months. Two years later, he returned unexpectedly and was advised to undergo magnetic resonance imaging, which revealed regression of the disc herniation; the patient also confirmed that the pain had not recurred. After 8 months, he underwent repeat magnetic resonance imaging, and the findings pertaining to disc herniation were normal. Our findings suggest that previous cases should be retrospectively studied to establish a prediction model for the outcomes of conservative treatment in patients with lumbar disc herniation. We also emphasize the significance of selecting suitable patients for conservative treatment to obtain the best therapeutic outcomes. The CARE guidelines have been followed in the reporting of this case.

Keywords

Lumbar disc herniation, regression, conservative treatment, prediction model, case report, magnetic resonance imaging

Date received: 30 October 2020; accepted: 5 May 2021

Introduction

Low back pain has become a global epidemic and is observed even among young people between the ages of 20 to 40 years.^{1,2} In China, the number of patients with low back pain is increasing, which has attracted

Department of Massage, Hangzhou Hospital of Traditional Chinese Medicine, Hangzhou, Zhejiang Province, P.R. China

Corresponding author:

Huasong Luo, Department of Massage, Hangzhou Hospital of Traditional Chinese Medicine, 453 Tiyuchang Street, Hangzhou, Zhejiang Province, 310007, P.R. China. Email: hzszyllhs@126.com



Creative Commons Non Commercial CC BY-NC: This article is distributed under the terms of the Creative Commons Attribution-NonCommercial 4.0 License (<https://creativecommons.org/licenses/by-nc/4.0/>) which permits non-commercial use, reproduction and distribution of the work without further permission provided the original work is attributed as specified on the SAGE and Open Access pages (<https://us.sagepub.com/en-us/nam/open-access-at-sage>).

the attention of the scientific community.³ Lumbar disc herniation (LDH) is a common cause of low back pain, radicular pain, and radiculopathy, which in turn causes disability. The surgical removal of a herniated disc is one of the most commonly used treatments for patients with disc herniation.⁴ However, studies have revealed that LDH regression can occur without surgical intervention, although this is a rare phenomenon.⁵⁻⁷ Herein, we report the case of a 25-year-old man with low back pain and radicular pain due to an LDH that resolved after the symptoms were relieved through conservative treatment. This case shows that failure to follow up conservatively treated patients in a timely manner, and recommending surgical treatment without offering standardized non-surgical interventions, may have contributed to the lack of widespread detection of this rare phenomenon. The reporting of this study conforms to the CARE guidelines.⁸

Case report

A 25-year-old Chinese man first experienced low back pain and radicular pain in May 2017. The pain began spontaneously, worsened after long car drives, and was accompanied by lumbar discomfort. Subsequently, he experienced left gluteal and left leg pain along with paresthesia in his posterior left leg. He had received acupuncture treatment in other hospitals, but his symptoms worsened; thus, 2 months later, he visited our hospital. The patient was 185 cm tall and weighed 70 kg. His body mass index (BMI) was 20.4 kg/m², and there was no history of cigarette smoking or alcohol abuse, and no other relevant medical history. On admission, he had a pain score of 6 on a visual analog scale. Physical examination indicated left L3-L5 paraspinal muscle tenderness and L4-S1 percussive radicular pain, extending from the left gluteus to the back of the left leg

and the sole of the ipsilateral foot. Let muscle strength and tone appeared normal, and the patellar and ankle reflexes in both lower limbs were symmetrical. Lasegue test results were 30° and 75° for the left and right legs, respectively. The Naffziger test and the test of abdominal external pressure both yielded positive results. The patient underwent lumbar magnetic resonance imaging (MRI) that revealed a large left-sided paracentral disc herniation at the L5/S1 intervertebral space, compressing the traversing S1 nerve root and resulting in spinal stenosis, consistent with his symptoms (Figure 1a).

The patient was advised to undergo surgical treatment using percutaneous endoscopic lumbar discectomy; however, he declined because of fear of surgery. Therefore, only physiotherapy and non-steroidal anti-inflammatory drugs were prescribed. He underwent low-intensity transcutaneous electric neuromuscular stimulation (TENS; 25 Hz, 200 μs, 50 mA, for 30 minutes) over the painful areas of his back and left leg daily, and he was prescribed 75 mg of Voltaren (diclofenac sodium sustained-release tablets, 75 mg per capsule; Novartis, Peking, China) once daily. The patient also received three weekly epidural steroid injections (ESIs). The treatment regimen is summarized in Table 1.

After receiving the third ESI, the patient's pain subsided, and he was discharged. He was followed-up intermittently at our outpatient department, and the symptoms persisted. Four months after he was discharged, his symptoms improved considerably. Two years later, the patient visited our department and stated that he had no symptoms of low back pain or sciatica. A second MRI was performed, revealing regression of the L5/S1 disc herniation (Figure 1b). The patient was monitored for another 8 months, and lumbar spine MRI revealed no recurrence

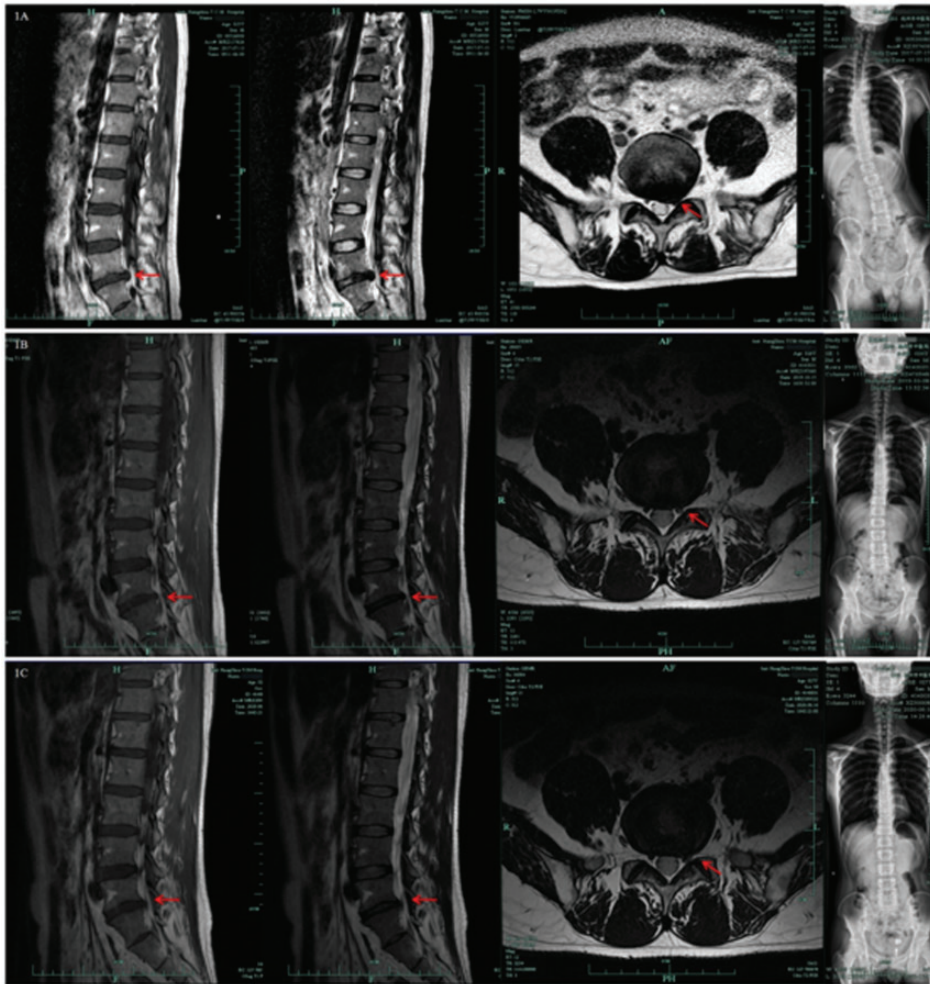


Figure 1. Axial and sagittal T1-weighted and T2-weighted magnetic resonance images (MRI) of the lumbar spine and radiographs of the entire spine. (a) Disc herniation at L5/S1 compressing the traversing S1 nerve roots (arrows) in July 2017 accompanied by significant scoliosis; (b) Significant resolution of the herniation 2 years later (arrows), in October 2019, with mild scoliosis; (c) No appearance of new herniation 3 years later (arrows), in June 2020, with no scoliosis.

Table 1. The treatment process during the patient’s hospitalization.

	July 2017																						
Treatment process	3	4	5	6	7	8	9	10	11	12	13	14	15	16	17	18	19	20	21	22	23	24	25
TENS																							
Voltaren																							
ESI																							

The gray areas indicate the day of treatment. TENS, electric neuromuscular stimulation; ESI, epidural steroid injection.

(Figure 1c). This case shows that even a large disc herniation can resolve gradually.

Discussion

The possibility of LDH regression has been reported in many publications after the first report by Guinto et al.⁹ A review of previous reports of regression revealed that sequestration or transligamentous extrusion are more likely to spontaneously resolve compared with other subtypes of LDH.⁷ Our review also revealed that symptomatic and radiographic resolution may occur 2 to 12 months before the resolution of the lumbar protrusion.¹⁰

The mechanism of LDH regression remains unclear. Some proposed hypotheses implicate inflammation or autoimmunity, and others hypothesize a relationship between disc hernia and the vascular system. The chemical mediators released during the inflammatory response and vascular proliferation after disc herniation can lead to the migration of inflammatory cells, such as macrophages, fibroblasts, and lymphocytes, to the site of disc herniation. The severity of the inflammatory reaction is also proportional to the degree of protrusion.¹¹ In experiments, the degradation imbalance of autologous matrix metalloproteinase-3 and -7 in disc herniation decreased the pressure and promoted absorption of the herniated disc.¹² Immune-related inflammatory cytokines, including interleukin-4, -6, -12, and -17, and interferon- γ , are strongly expressed in disc hernias, possibly by the herniated disc after it has been exposed to macrophages.¹³

Clinical reports of LDH regression are uncommon. In addition to its low incidence, the lack of timely follow-up of patients is another contributing factor. Furthermore, MRI examinations are substantially expensive. How to screen the population and identify those who are most likely to have regression is the next aim of

our research. After elucidating the best clinical pathway for the conservative treatment of LDH, our department intends to follow-up a total of approximately 3000 patients whom we had treated previously. In accordance with previous studies,^{14,15} we intend to select the cases most likely to undergo resorption, follow them, and observe whether the hypotheses in previous studies can be verified. The parameters we intend to evaluate are the mechanism of occurrence, predilections of LDH subtypes, occurrence time, and imaging characteristics of the resorption. We also intend to evaluate the correlation and establish a prognosis prediction model to assess whether resorption of the ruptured lumbar nucleus pulposus occurs. Additionally, we will calculate the weight of different factors to obtain a possible score to indicate the expected degree of resorption. A continuation of this study will involve cooperation with other institutions in China to constantly update the data and increase the accuracy of the model calculation. The results of the follow-up study may lead to an increasing appreciation of the value of conservative treatment, rather than the immediate recommendation of surgical treatment for patients with lumbar disc herniation.

Acknowledgments

The authors thank Professor Qiang Zhan from Hangzhou Children's Hospital, who supported us at every step of this study.

Author contributions

RW and HSL treated and clinically evaluated the patient; RW drafted the manuscript and was the principal author of the paper. All authors contributed to manuscript revision and approved the final version.

Declaration of conflicting interest

The authors declare that there is no conflict of interest.


Ethics statement

The Ethical Review Board of Guangxing Hospital Affiliated to Zhejiang University of Traditional Chinese Medicine (Hangzhou Hospital of Traditional Chinese Medicine) approved the study protocol [(R)-ZD-010(04)-05]. Written informed consent for publication of the clinical details and clinical images was obtained from the patient.

Funding

This research received no specific grant from any funding agency in the public, commercial, or not-for-profit sectors.

ORCID iDs

Rui Wang  <https://orcid.org/0000-0003-0735-2888>

Huasong Luo  <https://orcid.org/0000-0003-1950-3997>

References

- Buchbinder R, Van Tulder M, Öberg B, et al. Low back pain: a call for action. *Lancet* 2018; 391: 2384–2388.
- Hartvigsen J, Hancock MJ, Kongsted A, et al. What low back pain is and why we need to pay attention. *Lancet* 2018; 391: 2356–2367.
- Zhou M, Wang H, Zeng X, et al. Mortality, morbidity, and risk factors in China and its provinces, 1990–2017: a systematic analysis for the Global Burden of Disease Study 2017. *Lancet* 2019; 394: 1145–1158.
- Foster NE, Anema JR, Cherkin D, et al. Prevention and treatment of low back pain: evidence, challenges, and promising directions. *Lancet* 2018; 391: 2368–2383.
- Zhong M, Liu J, Jiang H, et al. Incidence of spontaneous resorption of lumbar disc herniation: a meta-analysis. *Pain Physician* 2017; 20: E45–E52.
- Hong J and Ball PA. IMAGES IN CLINICAL MEDICINE. Resolution of lumbar disk herniation without surgery. *N Engl J Med* 2016; 374: 1564.
- Yang X, Zhang Q, Hao X, et al. Spontaneous regression of herniated lumbar discs: report of one illustrative case and review of the literature. *Clin Neurol Neurosurg* 2016; 143: 86–89.
- Gagnier JJ, Kienle G, Altman DG, et al. The CARE guidelines: consensus-based clinical case reporting guideline development. *Headache* 2013; 53: 1541–1547.
- Guinto FC Jr, Hashim H and Stumer M. CT demonstration of disk regression after conservative therapy. *AJNR Am J Neuroradiol* 1984; 5: 632–633.
- Macki M, Hernandez-Hermann M, Bydon M, et al. Spontaneous regression of sequestered lumbar disc herniations: literature review. *Clin Neurol Neurosurg* 2014; 120: 136–141.
- Cunha C, Silva AJ, Pereira P, et al. The inflammatory response in the regression of lumbar disc herniation. *Arthritis Res Ther* 2018; 20: 251.
- Haro H, Komori H, Kato T, et al. Experimental studies on the effects of recombinant human matrix metalloproteinase on herniated disc tissues-how to facilitate the natural resorption process of herniated discs. *J Orthop Surg Res* 2005; 23: 412–419.
- Shamji MF, Setton LA, Jarvis W, et al. Proinflammatory cytokine expression profile in degenerated and herniated human intervertebral disc tissues. *Arthritis Rheum* 2010; 62: 1974–1982.
- Liu JT, Li XF, Yu PF, et al. Spontaneous resorption of a large lumbar disc herniation within 4 months. *Pain Physician* 2014; 17: E803–E806.
- Brauge D, Madkouri R, Clément R, et al. What are the possibilities of spontaneous resorption of a thoracic disc herniation occupying more than 20% of the spinal canal in the asymptomatic subject? Comparative study. *J Clin Neurosci* 2017; 44: 269–273.