

Clinical study of histologically proven conjunctival cysts



Shreya Thatte*, Jagriti Jain, Mallika Kinger, Sapan Palod, Jatin Wadhva, Avijit Vishnoi

Abstract

Purpose: This is a clinico-histopathological study of different varieties of conjunctival cysts where modification of surgical technique was done as per requirement for intact removal of cysts to minimise recurrence rate.

Materials and methods: Retrospective study of 40 cases of conjunctival cysts. A thorough ocular examination and basic haematological work up was done for all patients. B-scan USG and MRI was done wherever required to see the posterior extent. All patients underwent surgical excision of cyst followed by histo-pathological examination.

Results: The various types of conjunctival cysts found in our study were primary inclusion cyst 12 (30%), secondary inclusion cyst 6 (15%), pterygium with cysts 15 (37.5%), parasitic cyst 4 (10%), lymphatic cyst 2 (5%), and orbital cyst with rudimentary eye 1 (2.5%). The common symptoms noted were progressive increase in size of cyst (39.45%), cosmetic disfigurement (26.23%), foreign body sensations (27.86%), proptosis (1.6%), ocular motility restrictions (3.2%) and decreased visual acuity (1.6%). The patients were followed till one year after surgical excision for any recurrence and complications and no recurrence was seen.

Conclusion: Careful and intact removal of conjunctival cyst is important to prevent recurrence. Minor modifications in surgical technique according to the size, site and nature of cyst help in intact removal and prevent recurrence.

Keywords: Conjunctival cysts, Surgical excision, Prevent recurrence, Primary inclusion cysts, Secondary inclusion cysts

© 2014 Saudi Ophthalmological Society, King Saud University. Production and hosting by Elsevier B.V. All rights reserved.
<http://dx.doi.org/10.1016/j.sjopt.2014.06.009>

Introduction

Conjunctival cysts are thin walled and slowly progressing cysts. They are usually symptomless but can cause cosmetic disfigurement, reduced motility, foreign body sensation, dry eye due to unstable tear film when they increase in size. They can be primary or secondary inclusion cysts. Primary cysts are congenital, which remains hidden in the fornix and gradually increases with age. Secondary cyst can be parasitic cysts, implantation cysts due to trauma and degenerative cysts.^{1–3} Remedy for cysts is complete excision. As the cysts are thin walled, rupture is common during excision. Recurrence is the main postoperative concern. Careful and intact removal of cyst is necessary to prevent recurrence.

Materials and methods

This is a retrospective study which adhered with the tenets of the Declaration of Helsinki, consists of 40 cases of conjunctival cysts attending ophthalmology OPD between March 2007 and April 2013. A thorough work up which included a detailed history, visual acuity and ocular motility testing, slit lamp and fundus examination was performed in all the patients. All patients underwent basic haematological work up, B-scan USG and MRI of cyst was done whenever required to see the posterior extent. A careful surgical excision was done in a non-traumatic method. All excised cyst were subjected to histological examination to confirm the diagnosis.

Single cyst (more than 3 mm size) could be excised with careful dissection without rupture. Majority of the cases were

Received 25 November 2013; received in revised form 16 June 2014; accepted 23 June 2014; available online 3 July 2014.

Sri Aurobindo Institute of Medical Sciences PG Institute Boransala, Indore Ujjain Road, Indore (MP), India

* Corresponding author. Address: Chaitanya, 17 Yeshwant Colony, Behind Sita Building, Indore (MP) 452003, India. Tel.: +91 9302104864.
e-mail address: shreyathatte@gmail.com (S. Thatte).



Peer review under responsibility
of Saudi Ophthalmological Society,
King Saud University



Production and hosting by Elsevier

Access this article online:
www.saudiophthaljournal.com
www.sciencedirect.com

managed by simple dissection under sub-conjunctival anaesthesia. Only one case with hydatid cyst which required lateral orbitotomy was operated under general anaesthesia.

Surgical method

During excision of cyst conjunctiva along with tenon's was held with non-traumatic forceps gently above the cyst, a small incision was given and the blunt tip of scissors introduced between cyst and tenon's to separate the cyst from the surrounding tissue. Conjunctiva above the cyst was left as such, which helped to hold the cyst firmly during blunt dissection. Care was taken to keep the tip of the corneal scissors away from the cyst. After separating the cyst from all sides, its base was dissected carefully, as the base of the cyst ruptures most commonly during the dissection. Conjunctiva above the cyst was pulled in the opposite direction of the dissection area, so that fibrous attachments at the base of the cyst were stretched and became easily visible which helped in intact cyst removal.

In one patient of the large hydatid cyst lateral orbitotomy was required for complete excision. Patients with parasitic cysts were treated with anti-helminthic therapy following the excision.

Cysts smaller than 3 mm size and multiple small cysts in lymphatic cyst were removed along with the adjoining sub conjunctival tissue. Cysts with pterygium were excised along with pterygium tissue. Reverse peeling of pterygium was performed in all patients to avoid rupture of cyst, which was particularly located at the head of pterygium. In reverse peeling, body of pterygium was cut near the canthus and reflected back on the cornea, then it was peeled off by holding the pterygium tissue near the limbus.

All the patients were followed up for a minimum period of 1 year of surgery for the recurrence and development of any complications.

Observations

A total of 40 patients with conjunctival cysts were studied. Of these 12 patients had primary inclusion conjunctival cysts, 28 patients had secondary inclusion cysts, out of which 4 patients developed conjunctival cysts following SICS, 2 patients had post traumatic cysts, 15 patients had cysts in the pterygium, 4 patients had parasitic cysts, 2 patients had lymphatic cysts and 1 patient had an orbital cyst with rudimentary eye (Table 1).

Common symptoms that were noted in these patients were progressive increase in the size of the cyst (39.45%), cosmetic disfigurement (26.23%), foreign body sensation (27.86%), proptosis (1.6%), ocular motility restriction (3.2%) and blurred vision (1.6%). More than one symptom was also noted in many patients (Table 2).

The age group of 12 patients with primary inclusion cysts ranged from 18 to 45 years with the size of these cysts between 10 and 25 mm. Cysts were noted in early childhood in all 12 patients which progressed in size to cause various symptoms, and there was no history of trauma or ocular surgery in any of the patients. The cysts were typically located in the supero-nasal part of the orbit in 10 patients and in 2 patients it was located temporally, which was not a common site. In one young female patient the cyst was large (nearly 25 mm), temporally located, the cyst in this patient was big

Table 1. Types of cysts.

Type of cyst	Number of patients	Percentage (%)
Primary inclusion conjunctival cyst	12	30
Conjunctival cyst following SICS	4	10
Post traumatic cyst	2	5
Cyst in pterygium	15	37.5
Parasitic cyst	4	10
Lymphatic cyst	2	5
Orbital cyst with rudimentary eye	1	2.5
TOTAL	40	100

Table 2. Common symptoms.

Symptoms	Number of patients	Percentage
Progressive increase in size of cyst	24	39.45
Cosmetic disfigurement	16	26.23
Foreign body sensation	17	27.86
Proptosis	1	1.6
Ocular motility restriction	2	3.2
Blurred vision	1	1.6

enough to cause ocular motility restriction during abduction (Fig. 1A). In another young female with nasal primary cyst we noted a capillary haemangioma on the temporal side of contralateral forehead (Fig. 1B).

Complete removal of the primary cyst was possible in all cases, cysts were found to be free from surrounding tissues. Complications in the form of minor fat prolapse during dissection were noted in one patient while no intraoperative or post-operative complications were noted in other patients. Histopathology showed cysts lined with a single layer of stratified squamous epithelium containing amorphous material (Fig. 1C).

Conjunctival cyst following SICS was observed in 4 patients. In one patient cyst was 6 × 8 mm located at 10 o'clock limbus, in the second patient it was 7 × 6 mm at 12 o'clock position (Fig. 2A). In the other two patients cysts were small nearly 5 × 5 mm and located at 12 o'clock position at the limbus. Complete excision of cyst was possible in all the cases. Histopathology of the excised cyst showed a conjunctival cyst lined by the stratified squamous epithelium filled with amorphous material inside (Fig. 2B).

Of the two cases of post traumatic conjunctival cyst, one was present temporally near the lateral canthus, it resulted a month after lateral canthus tear repair (Fig. 2C). Second patient with post traumatic cyst had surgery for the repair of medial canthus nearly 6 months back, the cyst was located near the lower canaliculus. In both the cases cysts were nearly 5 × 5 mm in size, both the cysts were excised completely and histopathology showed cysts lined by stratified squamous epithelium filled with proteinaceous material.

Pterygium with cyst was seen in 15 patients (Fig. 3A). In 10 patients cyst was located at the head of the pterygium, while in rest of the 5 cases it was embedded in the body. There was no adherence of the cyst to the underlying structures in any of the patients. These cases were managed by excision of the cyst along with the reverse peeling of pterygium. Histopathology showed pterygium with stratified squamous epithelium

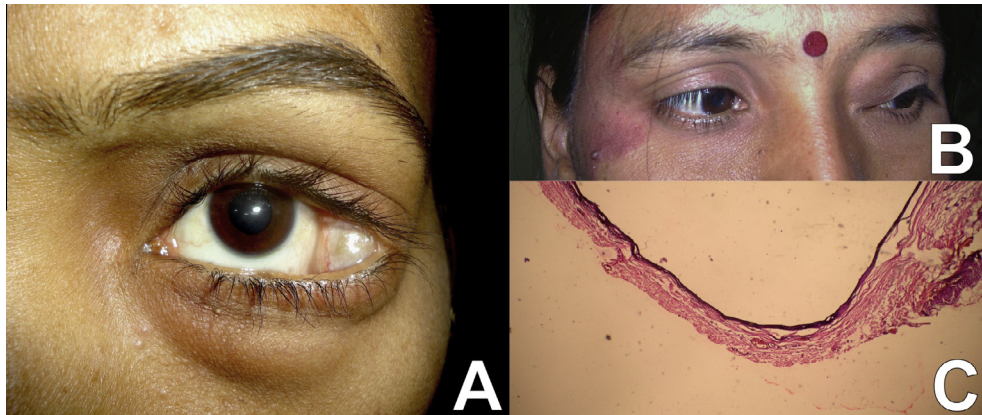


Figure 1. (A) Primary conjunctival cyst on the temporal side. (B) Primary conjunctival cyst on the nasal side. (C) Primary conjunctival cyst histopathology (cyst lined with single layer of stratified squamous epithelium containing amorphous material).

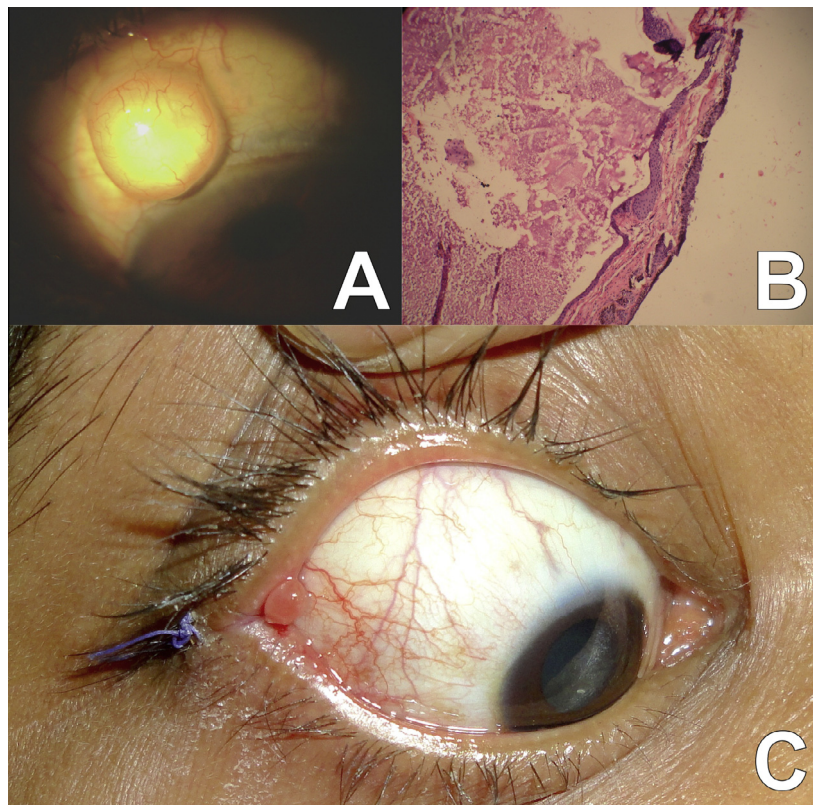


Figure 2. (A) Post SICS cyst. (B) Post SICS cyst histopathology (cyst lined by stratified squamous epithelium filled with amorphous material inside). (C) Post traumatic cyst.

lining with cystic changes, mild chronic inflammatory reaction was seen around the cyst (Fig. 3B).

All 4 patients of parasitic cysts were young males. The largest parasitic cyst was a hydatid cyst measuring 29×24 mm which was located in retro-orbital position in the temporal orbit, causing proptosis, a swelling on the temporal conjunctiva near lateral canthus, esotropia, limitation of abduction and blurred vision on the affected side (Fig. 4A). The cyst was actually pressing the eyeball which resulted in a vertically elongated optic disc. Cyst excision was performed by lateral orbitotomy (Fig. 4B), wound was irrigated with hypertonic saline to prevent recurrence and toxic reaction from accidental spillage of the cyst contents. The other three parasitic cysts were medium sized (8–10 mm in diameter),

located in the superior fornix. Progressive increase in the size of the cyst was the only complaint in these patients (Fig. 5A). Surgical excision was performed in all cases (Fig. 5B). Histopathology showed conjunctival cyst with embedded parasite showing features of *cysticercus cellulosae*. There was chronic inflammatory cell infiltrates with lymphocytes, eosinophils and giant cells in the cyst wall (Fig. 5C).

Conjunctival lymphatic cysts were seen in two male middle aged patients. In both patients cysts were located inferiorly on the bulbar surface near the fornix. In the first patient the larger cyst was 3×3 mm, associated with multiple horizontally oval small cysts (Fig. 6), it was managed by excision of the larger cyst and resection of the subconjunctival tissue in areas of smaller cysts. The second patient had multiple small

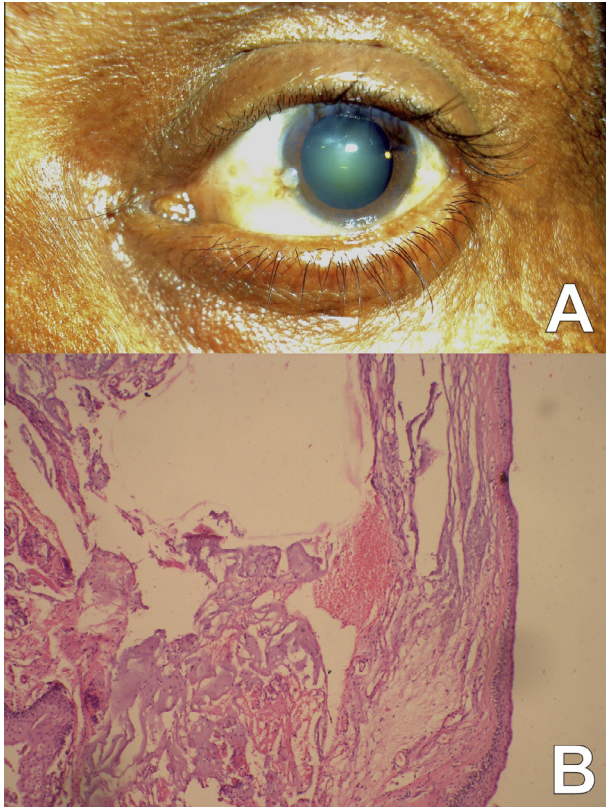


Figure 3. (A) Pterygium with cyst. (B) Pterygium with cyst histopathology (pterygium with stratified squamous epithelium lining with cystic changes, mild chronic inflammatory reaction was seen around the cyst).

(1 × 1 mm) cysts, which were removed by resection of the entire subconjunctival tissue in the affected area.

In one patient who was a one and a half year old female child a progressively increasing 37.5 × 37.5 mm swelling was seen in the orbit which was bulging through the lower lid (Fig. 7A). MRI showed absence of the eye ball in the orbit (Fig. 7B), while excision at the base of cyst was found to be firmly adherent to the base of orbit from where it got ruptured during separation (Fig. 7C). It was diagnosed as congenital cyst with anophthalmos. The histopathology revealed a unilocular cyst with its wall showing neural tissue (Fig. 7D).

Discussion

After reviewing the literatures, we did not find much work on conjunctival cysts. Apart from the study done by Nath et al.¹ we did not come across any study where clinical presentation and histopathology of various types of conjunctival cysts were studied. In a study done by Nath et al. 45 conjunctival cysts were surgically treated and histologically examined.

Inclusion cysts are benign cysts filled with clear serous fluid containing shed cells or gelatinous mucous material. Cyst wall consists of several layers of non-keratinised lining epithelium and connective tissue. 80% of the entire cystic lesions of conjunctiva are inclusion cysts. They can be primary or secondary.¹

Most common location of the primary orbital cyst is superonasal followed by the superotemporal region where bone involvement has been described.^{2,3} 12 cases of primary

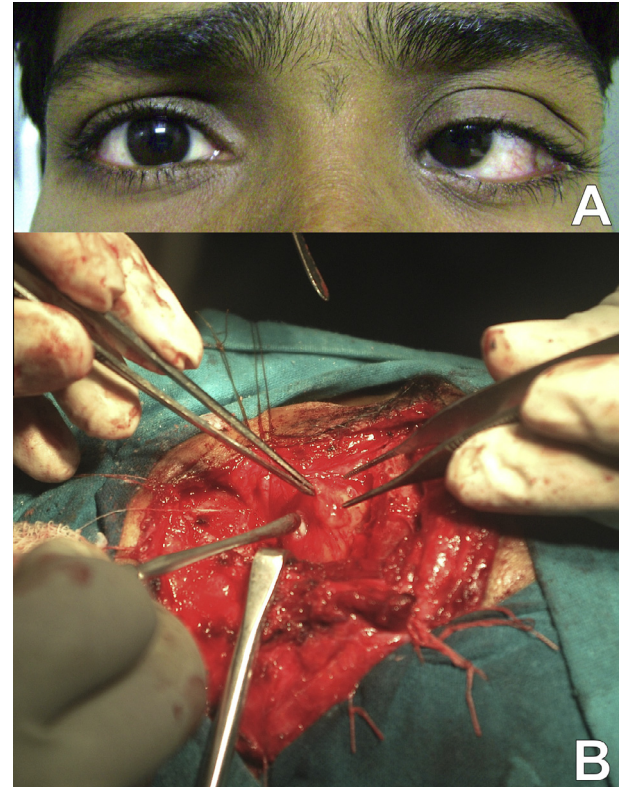


Figure 4. (A) Hydatid cyst with esotropia. (B) Hydatid cyst intra-operative, lateral orbitotomy.

inclusion cyst were seen in the present study, cysts were typically located in the superonasal part in 10 cases which is the most common location for the primary inclusion cyst. However in two young females cysts were located in the temporal quadrant, out of these one cyst was large enough to cause limitation of movements in abduction. Pathogenesis of primary inclusion cyst is due to excessive invagination of the caruncular epithelium or the fornix during embryonic development.⁴ Age of presentation of these cysts range from birth to 70 years, typical clinical features consists of painless cystic masses of small to moderate size. These cysts are mostly masses of thin walls and low pressure which generally do not induce significant mechanical alterations, however they can rarely erode adjacent bony structures and cause visual symptoms. Guijarro-Oria reported a case of orbital giant conjunctival epithelial primary cyst of 3.5 × 2 cm in the superior orbit which was removed by trans-conjunctival orbitotomy.⁵ In our study all the cysts were removed with intact walls without any requirement for orbitotomy.

Secondary inclusion cysts are more common, they occur either naturally or under inflammatory condition of the conjunctiva. In most cases it is developed by detachment of a portion of conjunctival epithelium by surgery or trauma^{6,7} and even subtenon anesthesia⁸ and its following implantation into the conjunctival epithelium. In the present study cysts following small incision cataract surgery were seen in 4 patients. They were excised completely without rupture and histo-pathologically proven to be inclusion cysts. Narayanappa et al. reported 2 cases of inclusion cysts following SICS but the cysts got ruptured during the removal in both cases.⁹ Shreya Thatte et al. also reported 2 cases of conjunctival

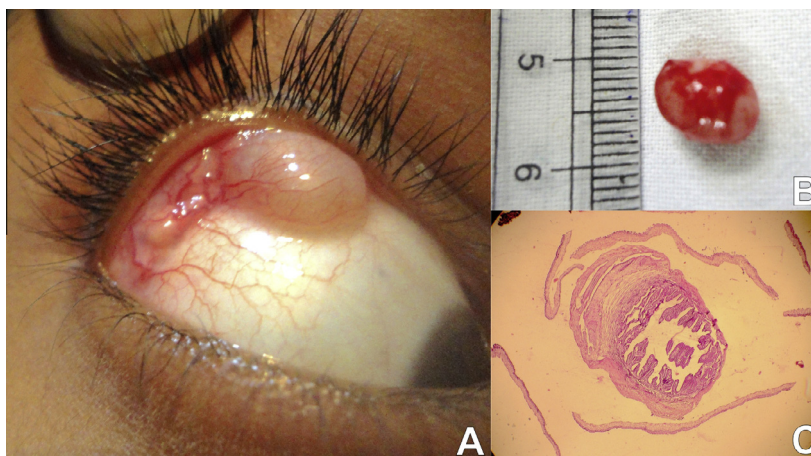


Figure 5. (A) Cysticercosis cyst. (B) Excised Cysticercosis cyst. (C) Cysticercosis cyst histopathology (cyst with embedded parasite, with chronic inflammatory cell infiltrate with lymphocytes, eosinophils and giant cells in the cyst wall).

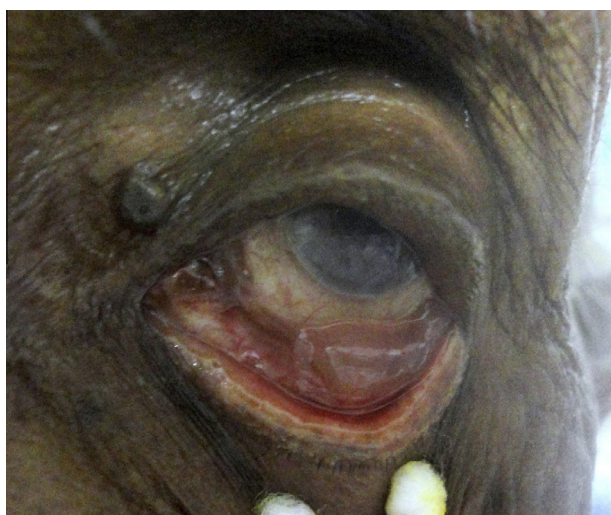

Figure 6. Lymphatic cyst pre-operative.

inclusion cysts following SICS, they were able to excise intact cysts in both cases.¹⁰ Chief differential diagnosis is the filtering bleb. This complication occurs due to implantation of conjunctival tissue during construction of tunnel or dragging of conjunctiva during IOL implantation. This can be prevented by careful reflection of the conjunctiva during surgery. Inclusion cysts have also been reported in conditions of chronic inflammation like VKC.¹¹

In the present study 40 cases of conjunctival cysts were studied. The various types of cysts noted were primary (30%) and secondary (15%) inclusion cysts, pterygium associated cysts (37.5%), parasitic (10%), lymphatic (5%) and congenital cysts with anophthalmos (2.5%). In study by Nath et al. the types of cysts studied were epithelial inclusion cysts (60%), dermoid cysts (17.77%), parasitic cysts (8.88%), lymphatic (8.88%) and pigmented cyst (4.44%).

Cystic changes in the pterygium were noted in 15 patients in our study. All cases were managed by excision of the pterygium itself, the cysts were found to be free from underlying structures in all cases. Kapoor et al. reported two cases of pterygium with cystic degeneration. In one of their patient they performed surgical excision of the pterygium along with

cyst and studied it histologically which showed a cyst lined with stratified squamous epithelium with mild inflammatory reaction surrounding the cyst wall. They mentioned that these cysts are the result of cellular down growth following degenerative changes in the stroma of the pterygium.¹² Cysts can be congenital when they are deep to the pterygium and fixed to deeper structures.

4 cases of conjunctival cysts in our study were found to be parasitic, 3 of them were cysticercus while one was a hydatid cyst. After reviewing the literatures we could not find percentage of various types of parasitic conjunctival cyst, however parasitic conjunctival cysts due to cysticercus appear to be most common. In a study on conjunctival cysts done by Nath et al.,¹ all the parasitic cysts were found to be cysticercus cellulosae, all these cysts in their study were located nasally. Literatures also state the medial side to be more commonly involved than lateral on account of the anatomic course of the ophthalmic artery, while in our study all 3 cysticercus cysts were located superiorly. Conjunctival involvement in cysticercus is usually in the form of a painless or painful nodular subconjunctival mass with surrounding congestion,¹³ rarely a subconjunctival abscess or granuloma may form, spontaneous extrusion of cysts has also been reported.¹⁴ In our study a progressively growing mass was the only feature in all patients, no other ocular structure was found to be affected in any of the patients. Patients were managed by complete surgical excision followed by albendazole therapy in a dose of 15 mg/kg/day in two divided dose for four weeks in tapering doses. Removal of cysticercus is the recommended treatment for subconjunctival space cysticercosis, as it gives excellent results.^{15,16} If the cyst wall is accidentally opened, the content should be aspirated and the area irrigated with hypertonic saline.

One parasitic cyst was a hydatid cyst, it was large, located retro-orbitally, causing proptosis, with limitation of abduction and visual dysfunction which was removed after lateral orbitotomy. Hydatid cysts mostly occur in young people between 10 and 30 years. They most frequently present as exophthalmos, chemosis, lid oedema, visual impairment and restriction of extraocular movement.^{17,18} Sudden exacerbation of pain, increase in proptosis, and local inflammatory reaction in eye is an important diagnostic clue to the hydatid cyst.¹⁹ Definitive treatment is surgical excision.^{20,21}

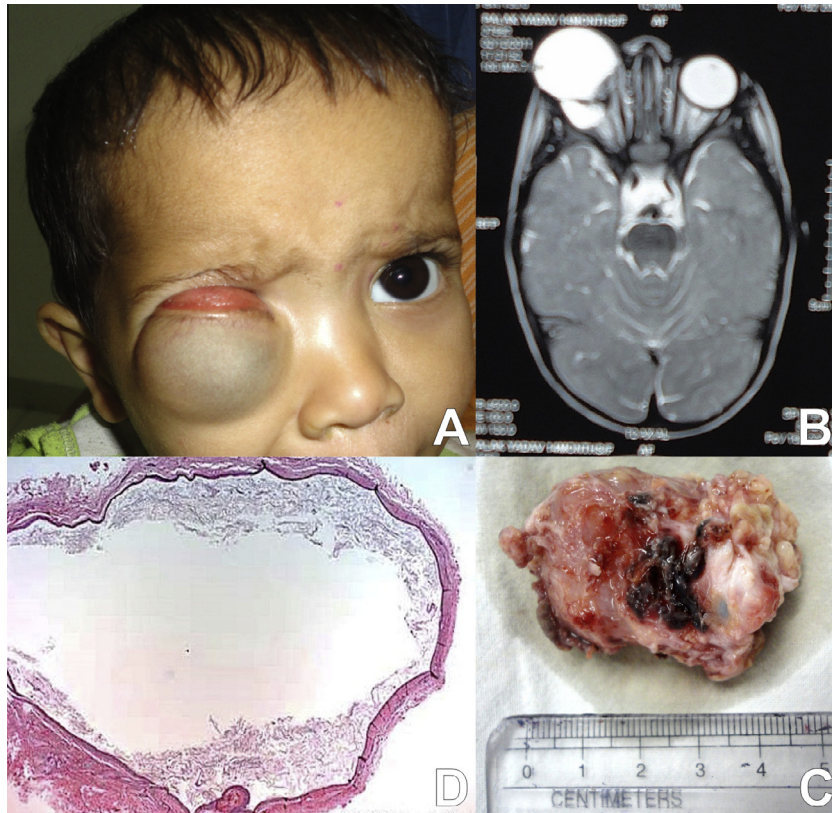


Figure 7. (A) Rudimentary eyeball with cyst. (B) Rudimentary eyeball with cyst MRI. (C) Rudimentary eyeball with cyst (excised). (D) Rudimentary eyeball with cyst histopathology (a unilocular cyst with neural tissue in the wall).

Two cases of conjunctival cysts were diagnosed as lymphatic cysts in the present study, both patients presented with foreign body sensations in the affected eye. The larger cyst was excised while resection of entire affected subconjunctival tissue was done for smaller, multiple cysts. There was no recurrence till one year of follow up. Conjunctival lymphangiectasia are presumably caused by obstruction of the lymphatic channels, but the actual cause often remains unknown. They often resolve but sometimes swell and cause symptoms like foreign body sensation, irritation and dryness.²² They can present either as cystic lesions of the conjunctiva which mimic allergic chemosis or as beaded dilatation of lymphatic vessels with a string of pearl appearance. Treatment modalities for conjunctival lymphangiectasia are surgical resection, marsupialization^{23,24} and obliteration of abnormal lymphatics by liquid nitrogen cryotherapy. A study done on 7 conjunctival lymphangiectasia showed surgical resection to be easy and effective with no recurrences.²⁵ In another study 5 eyes of biopsy proven lymphangiectasia underwent liquid nitrogen cryotherapy. The study showed quick resolution of symptoms following cryotherapy, however there were 2 recurrences and average time for recurrence was found to be 18 months.²⁶

One patient was presented with an orbital cyst with anophthalmos, also known as congenital cystic eye. Congenital cystic eye results from failure of invagination of the optic vesicle, a cyst of neuroectoderm remains which becomes clothed with fibrous tissue. The lining of the cyst may remain as a single layer of neural tissue but more commonly shows some differentiation into the retinal tissue with an ill-defined retina anteriorly while posteriorly the cells contain pigment

and represent the pigment epithelium.²⁷ Surgical excision is the most preferred method, aspiration of cysts is associated with high rate of recurrence, sclerosing therapy has also been tried with satisfactory results.²⁸ We managed our case by surgical excision, however intact cyst removal was not possible due to adherence of the cyst at base of the orbit.

To summarise, the present study is a clinico-histological study of 40 cases of conjunctival cysts, all the patients were managed by surgical excision. An intact removal of the cyst is very important to prevent recurrence. Majority of the cysts can be excised with intact walls by careful dissection and adopting minor modifications. Small cysts like the lymphatic cyst can be managed by excision of adjoining subconjunctival tissue. Similarly cysts within the pterygium are managed by excision of the pterygium along with it, histo-pathologically all cysts were proved to be conjunctival cysts as they were lined by stratified squamous epithelium and filled with either amorphous or proteinaceous material or embedded parasites and in a few cases surrounded by inflammatory cells or with neural tissue.

Conclusion

This is a clinico-histological study of 40 cases of different varieties of conjunctival cysts which were histologically confirmed. All the cases were managed by surgical excision. Minor modifications helped us to excise the majority of the cysts with intact walls which is very important to prevent recurrence.

Conflict of interest

The authors declared that there is no conflict of interest.

References

- Nath K, Gogi R, Zaidi Nahid. Cystic lesions of conjunctiva. *IJO* 1983;**31**:1–4.
- Boynton JR, Searl SS, Ferry AP, Kaltreider SA, Rodenhouse TG. Primary non-keratinised epithelial (conjunctival) orbital cyst. *Arch Ophthalmol* 1992;**110**:1238–42.
- Soll SM, Lisman RD, Harrison W, Weiner M. Conjunctival orbital cyst. *Ophthalm Plast Reconstr Surg* 1994;**10**:216–9.
- Imaizumi M, Nagata M, Matsumoto CS, Nakalruka K, Kachima K. Primary conjunctival epithelial cyst of orbit. *Int Ophthalmol* 2007;**27**:269–71.
- Gujario-Orio FJ, Mencia-Gutierrez E, Gutierrez-Diaz E, Lopez-Tizon E. Orbital giant conjunctival epithelial primary cyst. *Arch Soc Esp Ophthalmol* 2013.
- Song Jean J, Finger Paul T. Giant secondary conjunctival inclusion cysts: a late complication of strabismus surgery. *Eye* 2002;**17**:273–6.
- Barishak Robert Y, Barrak E, Lazar M. Episcleral traumatic conjunctival inclusion cyst. *BJO* 1977;**61**:29–301.
- Vishwanath MR, Jain A. Inclusion cyst after subtenon. *Br J Anaesthesia* 2005;**95**:825–6.
- Shylajanarayanappa, Dayananda S, Dakshayini M, Babu Suresh, Prabhakaran Venkatesh G. Conjunctiva inclusion cyst following small incision cataract surgery. *Indian J Ophthalmol* 2010;**58**(5):423–5.
- Thatte Shreya, Gupta Lalita. Excision of post small incision cataract surgery conjunctival inclusion cyst. *Indian J Ophthalmol* 2011;**59**(3):257–259.
- Lee Seung-Won, Lee Seung-Chan, Jin Kyung-Hyun. Conjunctival inclusion cysts in long standing chronic vernal keratoconjunctivitis. *Korean J Ophthalmol* 2007;**21**(4).
- Kapoor Shashi, Soor GC, Aurora AC. Cystic degeneration of pterygium. *Indian J Ophthalmol* 1977;**25**:37–8.
- Pushker N, Baja MS, Chandra M. Ocular and orbital cysticercosis. *Acta Ophthalmol Scand* 2001;**79**(4):408–13.
- Bansal RK, Gupta A, Grewal SP, Mohan K. Spontaneous extrusion of cysticercosis: report of 3 cases. *Indian J Ophthalmol* 1992;**40**(2):59–60.
- Reddy CCM, Gupta VP, Sarada P, Prabhakar V, Reddy DL, Anjaneyulu C. Ocular cysticercosis. *Indian J Ophthalmol* 1980;**28**:68–72.
- Singh RY. Subconjunctival cysticercus cellulosae. *Indian J Ophthalmol* 1993;**41**:188–9.
- Gomez Morales A, Craxatto JO, Cravetto L, Ebner R. Hydatid cyst of orbit. A review of 35 cases. *Ophthalmology* 1998;**95**:1027–32.
- Saini A, Achori M, Harouch M, et al. Intraorbital hydatid cyst. 10 cases. *Neurochirurgie* 1995;**4**:398–402.
- Jain IS, Rangbulla Ved. Hydatid cyst of orbit. *IJO* 1967;**15**(3):120–2.
- Jimenez-Mejios ME, Alarcon-Cruz JC, Marquez-Rivas FJ, Palamino-Micas J, Montero JM, Pachon J. Orbital hydatid cyst: treatment and prevention of recurrences with albendazole plus praziquantel. *J Infect* 2000;**41**:105–7.
- Gurea AV, Guisepppe G, Machinis TG, Coman TC, Fountas KN. Orbital hydatid cyst in childhood: a report of 2 cases. *South Med J* 2006;**99**(6):620–4.
- Perry HD, Cossari AJ. Chronic lymphangiectasia in Turner syndrome. *Br J Ophthalmol* 1985;**70**:396–9.
- Spraul CW, Buchwald HJ, Lang GK. Idiopathic conjunctival lymphangiectasia. *Klin Monatsbl Augenheilkd* 1997;**201**:398–9.
- Meisler DM, Eiferman RA, Ratliff NB, Burns CD. Surgical management of conjunctival lymphangiectasia by conjunctival resection. *Am J Ophthalmol* 2003;**136**:735–6.
- Song Jing, Yu Ji-Feng, Du Gai-Ping, Huang Yi-Fei. New surgical therapy for conjunctival lymphangiectasia. *Int J Ophthalmol* 2010;**3**(4):365–7.
- Fraunfelder Frederick W. Liquid nitrogen cryotherapy for conjunctival lymphangiectasia: a case series. *Trans Am Ophthalmol Soc* 2009;**107**:229–33.
- Rice NSC. Case of congenitally cystic eye and accessory limbs of lower eye lid. *Br J Ophthalmol* 1966;**50**:409.
- Naik Milind N, Murthy Ramesh K, Raizada Kuldeep, Honavar Santosh G. Ethanolamine oleate sclerotherapy in management of orbito-palpebral cyst associated with congenital microphthalmos. *Am J Ophthalmol* 2005;**139**:939–41.