

Unsuccessful Cyclosporine plus Prednisolone Therapy for Autoimmune Meningoencephalitis in Three Dogs

Dong-In JUNG¹⁾, Hee-Chun LEE¹⁾, Jeongim HA¹⁾, Hae-Won JUNG¹⁾, Joon-Hyeok JEON¹⁾, Jong-Hyun MOON¹⁾, Jae-Hoon LEE¹⁾, Na-Hyun KIM²⁾, Jung-Hyang SUR²⁾, Byeong-Teck KANG³⁾ and Kyu-Woan CHO^{1)*}

¹⁾Research Institute of Life Sciences, College of Veterinary Medicine, Gyeongsang National University, Jinju 660–701, South Korea

²⁾Department of Pathobiology, Small Animal Tumor Diagnostic Center, College of Veterinary Medicine, Konkuk University, Seoul 143–701, South Korea

³⁾Laboratory of Veterinary Dermatology and Neurology, College of Veterinary Medicine, Chungbuk National University, Cheongju, Chungbuk 361–763, South Korea

(Received 15 November 2012/Accepted 30 July 2013/Published online in J-STAGE 13 August 2013)

ABSTRACT. A 4-year-old female Maltese (case 1), a 9-year-old castrated male shih tzu (case 2) and 2-year-old female Pomeranian (case 3) presented with neurological signs, such as head tilt, ataxia, circling and paresis. The three cases were tentatively diagnosed as having meningoencephalitis of unknown etiology based on computed tomography scan and cerebrospinal fluid analysis. All patients were managed with cyclosporine plus prednisolone therapy. The survival times of the three patients were 170, 70 and 21 days, respectively. After the cases died, we performed necropsy and histopathological examination for definitive diagnosis. Based on the necropsy, histopathological and immunohistochemical examinations, cases 1, 2 and 3 were definitely diagnosed as having necrotizing meningoencephalitis, necrotizing leukoencephalitis and granulomatous meningoencephalitis, respectively. This case report demonstrated the clinical findings, brain CT characteristics and histopathological and immunohistochemical features of NME, NLE and GME in dogs and discussed the reason for the relatively short survival times under cyclosporine plus prednisolone therapy.

KEY WORDS: canine, cyclosporine, granulomatous meningoencephalitis (GME), necrotizing leukoencephalitis (NLE), necrotizing meningoencephalitis (NME).

doi: 10.1292/jvms.12-0503; *J. Vet. Med. Sci.* 75(12): 1661–1665, 2013

Granulomatous meningoencephalitis (GME), necrotizing meningoencephalitis (NME) and necrotizing leukoencephalitis (NLE) are common idiopathic autoimmune inflammatory disorders of the central nervous system (CNS) in canine patients [2, 7, 10, 12, 18, 20, 21]. In most cases, a hypothetic antemortem diagnosis is achieved via a diverse examination that includes assessment of clinical signs, cerebrospinal fluid (CSF) analysis, cross-sectional imaging of the CNS via computed tomography (CT) scan or magnetic resonance imaging (MRI) and infectious disease testing [1, 2, 7, 10, 11]. However, all CNS autoimmune inflammation cases could be definitively diagnosed based on the results of histopathological examination [7, 10, 11, 20].

Previous reports [10, 13, 14, 18] have suggested that NME, NLE and GME are autoimmune CNS disorders and that suppressing the immune reaction is the best management method for patients. Therefore, several immunosuppressive drugs have been used for NME, NLE and GME cases [1, 2, 6, 9–11, 23]. Recently, several reports suggested that cyclosporine showed beneficial effects for autoimmune CNS inflammatory cases [1, 2, 9–11].

This case report demonstrates the clinical findings, brain

CT characteristics and histopathological and immunohistochemical features of NME, NLE and GME in dogs. It also focuses on the discussion about the reason for the relatively short survival times under cyclosporine plus prednisolone therapy in the present 3 cases.

A 4-year-old female Maltese (case 1), a 9-year-old castrated male shih tzu (case 2) and 2-year-old female Pomeranian (case 3) presented with neurological signs, such as head tilt, ataxia, circling and paresis. Case 1 showed acute progression of neurological defects, such as left side head tilt, circling to the left side, blindness and ataxia. On physical and neurological examination of case 1, open fontanelle; bilateral delayed postural reaction with the left side being more severely affected than the right side; absence of menace response; ventrolateral strabismus; left side head tilt; and left side circling were observed. Case 2 showed a 1 week history of neurological defect progression, such as tetraparesis (ataxia and right side hemiparesis were initial signs) and head tilt. Prednisolone (1 mg/kg, PO, q 12 hr) was administered for 7 days at a local animal hospital before presentation to us, but clinical signs were not improved in case 2. On physical and neurological examination of case 2, left side facial palsy, bilateral delayed postural reaction, absence of menace response and right side head tilt were observed in the patient. Ataxia, right side facial palsy and right side hemiparesis signs occurred 1 day before presentation in case 3. On physical and neurological examination of case 3, right side facial palsy and delayed right side postural reactions were observed. There were no remarkable findings

*CORRESPONDENCE TO: CHO, K.-W., Research Institute of Life Sciences, College of Veterinary Medicine, Gyeongsang National University, Jinju 660–701, South Korea.
e-mail: chokw@gnu.ac.kr

with regard to blood tests (including complete blood counts, serum biochemistry profiles, canine distemper virus RT-PCR in blood and toxoplasma antigen detection by ELISA) and skull and thoracic radiography in all 3 cases.

In case 1, moderate bilateral ventriculomegaly was found according to brain ultrasonography via open fontanelle. We suggested brain CT examination to rule out encephalopathy, such as congenital defects, CNS inflammation or brain tumor. However, the client refused brain CT examination, because of the cost and anesthesia. Then, we prescribed prednisolone (1 mg/kg, PO, q 12 hr) and furosemide (2 mg/kg, PO, q 12 hr) to case 1 and strongly recommended a brain CT scan, if there was no response to the initial medication. The clinical signs gradually improved after medication for 30 days. However, they were not eliminated and slowly worsened after steroid tapering, because of severely increased hepatic enzyme levels (ALT, AST and ALP; 5–6 times higher than the normal ranges) and severe polyuria/polydipsia/polyphagia (tapered to 0.5 mg/kg, PO, q 12 hr). About 70 days after initial presentation, the dog's clinical signs were worse than at initial presentation, and the client decided to allow a brain CT examination. In the CT findings, hypo-attenuated multifocal lesions were found in the right cerebral cortex, and the lesions were not enhanced after contrast study (Fig. 1A). The results of CSF analysis showed an increased nucleated cell count of 10 cells/ μ l (reference range, 0–5 cells/ μ l). Cytologic examination of the CSF revealed monocytic pleocytosis. The volume of CSF was not enough to perform other tests, such as bacterial and fungal cultures, CDV RT-PCR and Toxoplasma ELISA, so we could not proceed with other examinations of the CSF. Based on the examination results, we tentatively diagnosed this case as meningoencephalitis of unknown etiology (MUE). Management with prednisolone (Prednisolone, Korea Pharm., Seoul, Korea; 0.5 mg/kg, PO, q 12 hr) and cyclosporine microemulsion (CYPOL-N[®], Chong Kun Dang Pharm., Seoul, Korea; 6 mg/kg, PO, q 24 hr) was initiated, and clinical signs improved gradually compared with the previous therapy (sole prednisolone therapy). Three weeks after cyclosporine administration, ataxia and proprioceptive deficits had mildly progressed, and we prescribed a higher dose of cyclosporine (10 mg/kg, PO, q 24 hr). Neurological signs were not improved, but had not progressed. The clinical status of case 1 was maintained, but the dog suddenly died at home 100 days after cyclosporine administration (about 170 days after initial presentation).

In cases 2 and 3, we could perform a brain CT examination at initial presentation. The CT findings of case 2 showed hypo-attenuated lesions that were suspected to be necrotizing lesions in both sides of cerebral cortex parts (Fig. 2A). The CT findings of case 3 indicated that the falx cerebri had shifted to the right side due to edematous changes of the left side cerebral parenchyma. Some parts of the left cerebral cortex were enhanced after contrast study (Fig. 3A). The results of CSF analysis showed an increased nucleated cell count of 20 cells/ μ l (both cases 2 and 3; reference range, 0–5 cells/ μ l). Cytologic examination of the CSF revealed monocytic pleocytosis (case 2) and lymphocytic pleocytosis (case 3). The volume of CSF was not enough to perform other

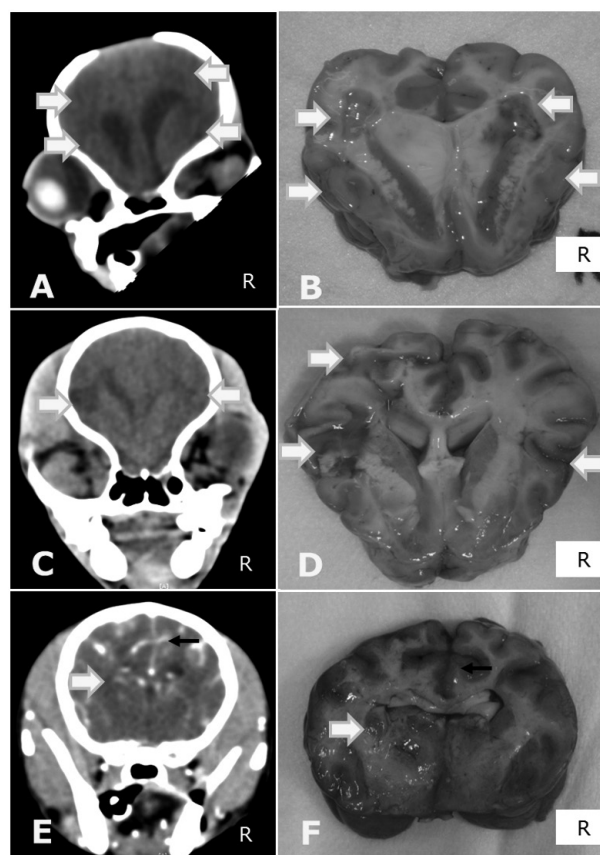


Fig. 1. Brain CT scan images (A, C, E) and necropsy findings (B, D, F) of the present cases. Multifocal necrotic inflammatory lesions (arrows) are seen on CT and necropsy images from case 1 (A & B) and case 2 (C & D). Edematous and inflammatory changes (arrow) and falx cerebri deviation (small arrow) are seen on CT and necropsy images from case 3 (E & F).

tests, such as bacterial and fungal cultures, CDV RT-PCR and Toxoplasma ELISA, so we could not proceed with other examinations of CSF. Based on the examination results, we tentatively diagnosed cases 2 and 3 as meningoencephalitis of unknown etiology (MUE). Then, we started a combination therapy of prednisolone (1 mg/kg, PO, q 12 hr) and cyclosporine (6 mg/kg, PO, q 24 hr) for them. The clinical signs of both cases improved gradually after medication, but were not eliminated. The clients of both cases had trouble with cyclosporine administration at home and sometimes failed to give the medications. Cases 2 and 3 were suddenly died at home 70 and 21 days after cyclosporine administration, respectively.

In all 3 cases, necropsy and histopathological examination were performed after obtaining consent from the owners. The findings of case 1 showed multifocal necrotic lesions in the cerebral cortex, which was consistent with the CT findings (Fig. 1B). The necropsy findings of case 2 also showed multifocal necrotic lesions in the cerebral cortex (Fig. 2B). Furthermore, an inflammatory lesion on the brainstem was noticed that had not been found on the CT scan. The necrop-

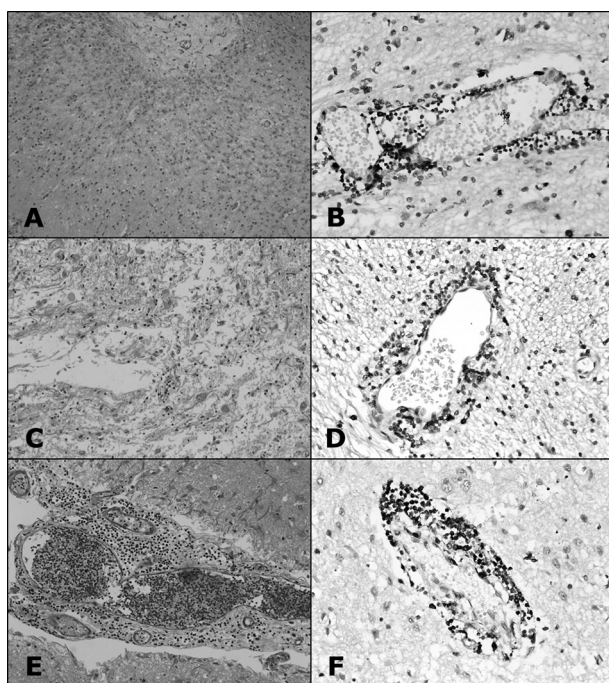


Fig. 2. Histopathological (HE stain; A, C, E) and immunohistochemical (anti CD 3 stain; B, D, F) results of the present cases. A & B: case 1; C & D: case 2; E & F: case 3. All cases represent T-cell-positive results around perivascular areas. Case 1, case 2 and case 3 were ultimately diagnosed as NME, NLE and GME, respectively.

sy findings of case 3 revealed edematous changes of the left cerebral parenchyma and lesions on the left cerebral cortex (Fig. 1C). The histopathological examination results of cases 1 and 2 revealed neuronal necrosis, vacuolation and perivascular cuffing with lymphocyte infiltration in the cerebral cortex, macrophage infiltration and necrosis in the white matter (Fig. 2A and 2C). The lesion on the brainstem in case 2 also showed necrotic inflammatory changes. The histopathological examination results of case 3 demonstrated perivascular cuffing with lymphocyte infiltration in the cerebral cortex, but no necrotic changes were found (Fig. 2E).

The immunohistochemistry results for T cells (anti CD3) in all 3 cases showed that positive cells had infiltrated around vessels (Fig. 2B, 2D and 2F). According to the histopathological and immunohistochemical findings, we definitively diagnosed cases 1, 2 and 3 as NME, NLE and GME, respectively.

GME, NME and NLE are common idiopathic CNS inflammation disorders in dogs [1, 5, 7, 11, 13, 14, 17, 18, 20]. GME is also thought to be an autoimmune disorder and characterized histologically by perivascular cuffing with mononuclear cells in the CNS [7, 14, 17, 20]. Necrotizing CNS inflammation includes two pathologically distinct diseases referred to as NME and NLE [7]. Both diseases are thought to be autoimmune disorders and have similar characteristic features, such as multiple cavitory necrotic nonsuppurative inflammatory brain lesions in gray and white matters [7, 20].

Most small breed dogs could be predisposed to GME [7]. NME and NLE have been reported mainly in the pug, Maltese, Pomeranian, Chihuahua, Yorkshire terrier, shih tzu, Pekingese, West Highland white terrier, Boston terrier and miniature pinscher [7, 10–13, 18, 22].

To date, the general treatment for autoimmune CNS inflammation in dogs has been immunosuppressive doses of glucocorticoid [7, 11]. However, the response to therapy with glucocorticoid only varies, and clinical signs often relapse during the tapering of glucocorticoid therapy [7, 10, 11]. Various immunosuppressive drugs in autoimmune CNS inflammation cases have been reported previously, but limited [1, 2, 6, 9–11, 23]. According to several recent reports [1, 2, 9–11], cyclosporine and prednisolone combination therapy allowed for a decrease in the dose of prednisolone and showed synergic effects on autoimmune CNS inflammation. One study [2] demonstrated that the median survival time after cyclosporine combination therapy in CNS inflammation was 930 days. Another study [15] reported that the median survival time of 15 GME dogs with sole prednisolone therapy was 41 days. In one previous report [11], moreover, the mean survival time of histopathologically confirmed NME dogs with cyclosporine plus prednisolone therapy was 305.7 ± 94.7 days, and the mean survival time of histopathologically confirmed NME dogs with sole prednisolone therapy was 58.3 ± 30.5 days. Furthermore, one other report [10] described survival for 1,096 days after cyclosporine plus prednisolone therapy in a histopathologically confirmed NME case. Although there were no histopathologic confirmations, several reports [1, 9] described cyclosporine therapy as showing beneficial effects in autoimmune CNS inflammation suspected dogs.

In this study, we administered cyclosporine plus prednisolone in three dogs with autoimmune CNS inflammation. However, the survival times of the 3 dogs were relatively shorter than in previous studies [1, 2, 9–11]. Just one case survived for 170 days, and the other two cases survived less than 100 days after cyclosporine plus prednisolone therapy in this study.

There are several possible reasons for the shorter survival times in this study. 1) In case 1, the client refused a brain CT on the initial presentation day, and we just prescribed prednisolone (1 mg/kg, PO, q 12 hr) plus furosemide (2 mg/kg, PO, q 12 hr) for 70 days. According to our experiences, the timing of administration of immunosuppressants (as early as possible) is very important to extend survival time in autoimmune CNS inflammation cases. Prednisolone could cause improvement of inflammatory and edematous changes in almost all autoimmune CNS inflammation cases, but it could not delay autoimmune disease progression at a lower dose. Adverse effects, such as polyuria/polydipsia/polyphagia, hepatotoxicity, weight gain, iatrogenic Cushing's disease and depression, are frequently seen during long-term prednisolone therapy. According to a previous report [10], immunosuppressants, such as cyclosporine, could decrease the speed of disease progression when used with an appropriate method and timing. We suspected that case 1 missed the appropriate timing for administration of cyclosporine.

Therefore, late cyclosporine administration might not show an extremely beneficial effect like previous reports [1, 2, 9–11]. Although case 1 showed a relatively short survival time, we should focus on improvement of clinical signs after cyclosporine administration compared with the status when using prednisolone only therapy. 2) Because cyclosporine is capsular emulsion form, it may be difficult to administer it by an appropriate method. Moreover, one previous report [19] described that administration of cyclosporine with food could decrease the bioavailability by 22% and increase the individual variability of drug absorption. The owners of the cases 2 and 3 dogs had serious trouble with cyclosporine administration at home and sometimes failed to give the medications. Cyclosporine was administered less than 3 times in a week in both cases. Although we used cyclosporine plus prednisolone initially for cases 2 and 3, both cases were acute forms, and inconsistent administration of cyclosporine could not delay the disease progression. Acute form autoimmune CNS inflammation progresses rapidly and shows high mortality even in the early stage. According to a previous report [10], cyclosporine could not stop the progress of the disease but could improve inflammatory and edematous changes initially and then decrease the speed of disease progression. 3) We did not measure the cyclosporine concentration in the 3 cases, so we could not show the exact therapeutic concentration after therapy.

A limitation of this study is that we demonstrated our opinion based on previously published clinical papers. However, it is necessary to provide a logical discussion, and more randomized, controlled, blinded or large-scale studies are essential parts of this. None of the previous clinical studies matched up with these concepts perfectly. More clinical trials to compare the efficacy in autoimmune CNS inflammation are necessary to prove the better effects of cyclosporine. However, it is also true that actually performing a clinical study that perfectly fulfills the above needs is very difficult. Although each study consisted of a small number of cases, collection of data from previous reports should not be ignored. It is not entirely enough, but it could be somewhat presumptive evidence.

Another limitation is the limited number of cases in this study. Several previous reports [3, 4, 8, 16, 19] described the pharmacodynamics, pharmacokinetics and clinical efficacy of cyclosporine in dogs. It is true that cyclosporine is the one of the beneficial options for treating autoimmune CNS inflammations in dogs [1, 2, 9–11]. However, cyclosporine therapy can sometimes fail in clinical practice. In other words, autoimmune CNS inflammation cases do not always show a good response to cyclosporine therapy. This was the starting point of this study. In this study, we discussed about the reason for the relatively short survival times of the three autoimmune CNS inflammation cases under cyclosporine therapy. Unfortunately, the small number of cases in this study presents a problem. This study could have provided more logical clinical data, if a large cohort of cases had been utilized. More clinical trials and a large number of cases are needed.

In summary, we suggested that drug administration tim-

ing, frequency and therapeutic concentration measurement are very important to extend survival times and improve the life quality in autoimmune CNS inflammation cases treated with cyclosporine. Thus, aggressive initial cyclosporine therapy is needed in suspected cases of autoimmune CNS inflammation.

ACKNOWLEDGMENT. This research was supported by the Basic Science Research Program through the National Research Foundation of Korea (NRF) funded by the Ministry of Education, Science and Technology (2011-0008358).

REFERENCES

1. Adamo, F. P. and O'Brien, R. T. 2004. Use of cyclosporine to treat granulomatous meningoencephalitis in three dogs. *J. Am. Vet. Med. Assoc.* **225**: 1211–1216. [Medline] [CrossRef]
2. Adamo, P. F., Rylander, H. and Adams, W. M. 2007. Cyclosporin use in multi-drug therapy for meningoencephalomyelitis of unknown aetiology in dogs. *J. Small Anim. Pract.* **48**: 486–496. [Medline] [CrossRef]
3. Allenspach, K., Rüfenacht, S., Sauter, S., Gröne, A., Steffan, J., Strehlau, G. and Gaschen, F. 2006. Pharmacokinetics and clinical efficacy of cyclosporine treatment of dogs with steroid-refractory inflammatory bowel disease. *J. Vet. Intern. Med.* **20**: 239–244. [Medline] [CrossRef]
4. Archer, T. M., Fellman, C. L., Stokes, J. V., Pinchuk, L. M., Lunsford, K. V., Pruett, S. B., Langston, V. C. and Mackin, A. J. 2011. Pharmacodynamic monitoring of canine T-cell cytokine responses to oral cyclosporine. *J. Vet. Intern. Med.* **25**: 1391–1397. [Medline] [CrossRef]
5. Braund, K. G., Vandavelde, M., Walker, T. L. and Redding, R. W. 1978. Granulomatous meningoencephalitis in six dogs. *J. Am. Vet. Med. Assoc.* **172**: 1195–1200. [Medline]
6. Coates, J. R., Barone, G., Dewey, C. W., Vitale, C. L., Holloway-Azene, N. M. and Sessions, J. K. 2007. Procarbazine as adjunctive therapy for treatment of dogs with presumptive antemortem diagnosis of granulomatous meningoencephalomyelitis: 21 cases (1988–2004). *J. Vet. Intern. Med.* **21**: 100–106. [Medline]
7. Dewey, C. W. 2008. Encephalopathies: Disorders of the brain. pp. 190–191. *In: A Practical Guide to Canine and Feline Neurology*, 2nd ed. (Dewey, C. W., eds.), Wiley-Blackwell, Iowa.
8. Fellman, C. L., Stokes, J. V., Archer, T. M., Pinchuk, L. M., Lunsford, K. V. and Mackin, A. J. 2011. Cyclosporine A affects the *in vitro* expression of T cell activation-related molecules and cytokines in dogs. *Vet. Immunol. Immunopathol.* **140**: 175–180. [Medline] [CrossRef]
9. Gnirs, K. 2006. Cyclosporin treatment of suspected granulomatous meningoencephalomyelitis in three dogs. *J. Small Anim. Pract.* **47**: 201–206. [Medline] [CrossRef]
10. Jung, D. I., Kim, J. W. and Park, H. M. 2012. Long-term immunosuppressive therapy with cyclosporine plus prednisolone for necrotizing meningoencephalitis in a pekingese dog. *J. Vet. Med. Sci.* **74**: 765–769. [Medline] [CrossRef]
11. Jung, D. I., Kang, B. T., Park, C., Yoo, J. H., Gu, S. H., Jeon, H. W., Kim, J. W., Heo, R. Y., Sung, H. J., Eom, K. D., Lee, J. H., Woo, E. J. and Park, H. M. 2007. A comparison of combination therapy (cyclosporine plus prednisolone) with sole prednisolone therapy in 7 dogs with necrotizing meningoencephalitis. *J. Vet. Med. Sci.* **69**: 1303–1306. [Medline] [CrossRef]
12. Kitagawa, M., Okada, M., Kanayama, K., Sato, T. and Sakai, T. 2007. A canine case of necrotizing meningoencephalitis for

- long-term observation: clinical and MRI findings. *J. Vet. Med. Sci.* **69**: 1195–1198. [[Medline](#)] [[CrossRef](#)]
13. Matsuki, N., Takahashi, M., Yaegashi, M., Tamahara, S. and Ono, K. 2009. Serial examinations of anti-GFAP autoantibodies in cerebrospinal fluids in canine necrotizing meningoencephalitis. *J. Vet. Med. Sci.* **71**: 99–100. [[Medline](#)] [[CrossRef](#)]
 14. Matsuki, N., Fujiwara, K., Tamahara, S., Uchida, K., Matsunaga, S., Nakayama, H., Doi, K., Ogawa, H. and Ono, K. 2004. Prevalence of autoantibody in cerebrospinal fluids from dogs with various CNS diseases. *J. Vet. Med. Sci.* **66**: 295–297. [[Medline](#)] [[CrossRef](#)]
 15. Munana, K. R. and Luttmgen, P. J. 1998. Prognostic factors for dogs with granulomatous meningoencephalomyelitis: 42 cases (1982–1996). *J. Am. Vet. Med. Assoc.* **212**: 1902–1906. [[Medline](#)]
 16. Robson, D. 2003. Review of the pharmacokinetics, interactions and adverse reactions of cyclosporine in people, dogs and cats. *Vet. Rec.* **152**: 739–748. [[Medline](#)] [[CrossRef](#)]
 17. Sarfaty, D., Carrillo, J. M. and Greenlee, P. G. 1986. Differential diagnosis of granulomatous meningoencephalomyelitis, distemper, and suppurative meningoencephalitis in the dog. *J. Am. Vet. Med. Assoc.* **188**: 387–392. [[Medline](#)]
 18. Shibuya, M., Matsuki, N., Fujiwara, K., Imajoh-ohmi, S., Fukuda, H., Tpham, N., Tamahara, S. and Ono, K. 2007. Autoantibodies against glial fibrillary acidic protein (GFAP) in cerebrospinal fluids from Pug dogs with necrotizing meningoencephalitis. *J. Vet. Med. Sci.* **69**: 241–245. [[Medline](#)] [[CrossRef](#)]
 19. Steffan, J., Strehlau, G., Maurer, M. and Rohlf, A. 2004. Cyclosporin A pharmacokinetics and efficacy in the treatment of atopic dermatitis in dogs. *J. Vet. Pharmacol. Ther.* **27**: 231–238. [[Medline](#)] [[CrossRef](#)]
 20. Suzuki, M., Uchida, K., Morozumi, M., Hasegawa, T., Yanai, T., Nakayama, H. and Tateyama, S. 2003. A comparative pathology study on canine necrotizing meningoencephalitis and granulomatous meningoencephalomyelitis. *J. Vet. Med. Sci.* **65**: 1233–1239. [[Medline](#)] [[CrossRef](#)]
 21. Thomas, W. B. 1998. Inflammatory diseases of the central nervous system in dogs. *Clin. Tech. Small Anim. Pract.* **13**: 167–178. [[Medline](#)] [[CrossRef](#)]
 22. Thomas, W. B. 1999. Nonneoplastic disorders of the brain. *Clin. Tech. Small Anim. Pract.* **14**: 125–147. [[Medline](#)] [[CrossRef](#)]
 23. Zarfoss, M., Schatzberg, S., Venator, K., Cutter-Schatzberg, K., Cuddon, P., Pintar, J., Weinkle, T., Scarlett, J. and DeLahunta, A. 2006. Combined cytosine arabinoside and prednisolone therapy for meningoencephalitis of unknown aetiology in 10 dogs. *J. Small Anim. Pract.* **47**: 588–595. [[Medline](#)] [[CrossRef](#)]