

## Rehabilitation of Maxillary Bilateral Regional Odontodysplasia in a 7-Year-Old Child Using Modified Essix Retainer

### Abstract

Regional odontodysplasia (RO), also called ghost teeth, is a rare nonhereditary developmental dental anomaly affecting the epidermal and mesenchymal tissues associated with the development of tooth which can affect both primary and permanent dentition. It can affect the child's overall quality of life and sometimes may lead to skeletal malocclusion. Management of such patients requires a multidisciplinary approach. Essix retainers are being widely used as retention appliances. Various modifications of this appliance are also being attempted. Thus, this article aims to focus on the use of Essix retainer as an interim prosthesis by modifying it with the incorporation of pontics to manage partial edentulousness and mild orthodontic corrections in a 7-year-old child diagnosed with bilateral RO.

**Keywords:** *Dysplasia, Essix retainer, ghost teeth, missing teeth, permanent dentition, primary dentition, regional odontodysplasia*

### Introduction

Regional odontodysplasia (RO) is an uncommon nonhereditary developmental dental anomaly that affects the epidermal and mesenchymal tissues associated with the development of the tooth.<sup>[1]</sup> The prevalence is <1/10,00,000.<sup>[2]</sup>

RO can cause atrophy of the alveolar bone and skeletal and dental malocclusion ultimately affecting the overall psychology of the child. Conventional removable partial dentures are commonly used treatment. The Essix appliance is an esthetic removable appliance.<sup>[3]</sup> Its modifications are also emerging as an option for temporary prosthetic rehabilitation of missing teeth, developing crossbite, and habit-breaking appliances.

This article reports a case of rehabilitation of bilateral RO affecting maxilla in a 7-year-old child using Essix retainer.

### Case Report

A 7-year-old male child reported to the department of pediatric and preventive dentistry with a chief complaint of unerupted upper front teeth. He had a history of fall and lost his deciduous

maxillary incisors. The parent mentioned that the lost deciduous teeth were different than the remaining teeth with yellowish discoloration. No abnormality was detected during general and extraoral examination.

Intraoral examination revealed unerupted 21, 22, and 23 and proximal caries in 65. Intra-oral Periapical Radiograph was done followed by OPG which showed ghost teeth in relation to 11, 21, 22, and 23 [Figure 1]. Hence, the diagnosis was made as bilateral RO affecting 11, 21, 22, and 23. Prosthesis was planned for the patient in relation to 21, 22, and 23 along with regular follow-ups. Prosthesis could not be delivered to the patient due to the lockdown during COVID-19.

A year later, during follow-up, he had an obtuse nasolabial angle [Figure 2a and c]. Intraoral examination showed unerupted 11, 21, 22, and 23 [Figure 3a and b], hypoplastic anterior maxilla, and developing crossbite in relation to 52 and 42. The treatment plan included the provision of a removable prosthesis to improve the esthetics and phonetics, correct the crossbite, and limit the maxillary bone resorption. Hence, initial wax try-in was done which improved the patient profile, personality, and psychology. Restorations of carious teeth, oral prophylaxis, and fluoride application

**M. Divya Banu,  
V. Krishna Priya,  
Shilpa Gaddam,  
Santosh Kumar  
Challa**

*Department of Pediatric and Preventive Dentistry, Army College of Dental Sciences, Secunderabad, Telangana, India*

**Submitted :** 03-Jun-2021

**Revised :** 07-Jun-2021

**Accepted :** 26-Jun-2021

**Published :** 24-Sep-2022

#### Address for correspondence:

*Dr. M. Divya Banu,  
Department of Pediatric and Preventive Dentistry, Army College of Dental Sciences, Secunderabad - 500 087, Telangana, India.  
E-mail: dbanu06@gmail.com*

#### Access this article online

##### Website:

[www.contempclindent.org](http://www.contempclindent.org)

**DOI:** 10.4103/ccd.ccd\_434\_21

##### Quick Response Code:



**How to cite this article:** Banu MD, Priya VK, Gaddam S, Challa SK. Rehabilitation of maxillary bilateral regional odontodysplasia in a 7-year-old child using modified essix retainer. *Contemp Clin Dent* 2022;13:292-4.

This is an open access journal, and articles are distributed under the terms of the Creative Commons Attribution-NonCommercial-ShareAlike 4.0 License, which allows others to remix, tweak, and build upon the work non-commercially, as long as appropriate credit is given and the new creations are licensed under the identical terms.

For reprints contact: WKHLRPMedknow\_reprints@wolterskluwer.com

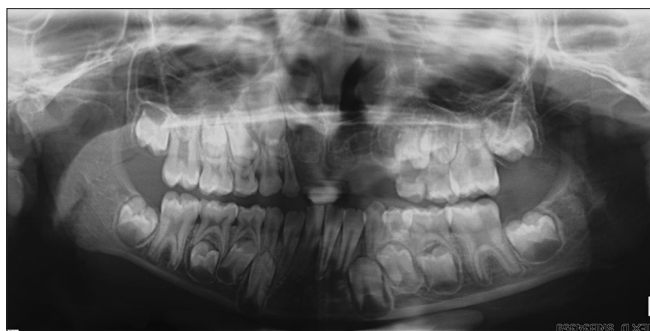

Figure 1: Panoramic radiograph showing ghost teeth in relation to 11, 21, 22, and 23

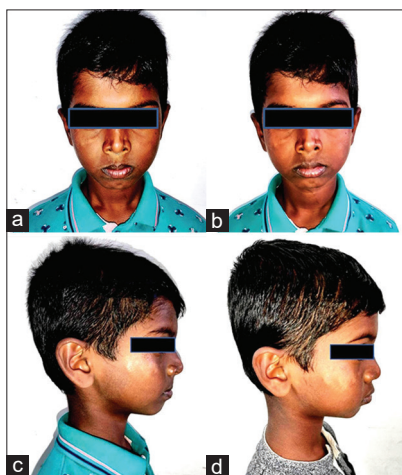


Figure 2: (a) Preoperative frontal profile. (b) Postoperative frontal profile. (c) Preoperative lateral profile. (d) Postoperative lateral profile

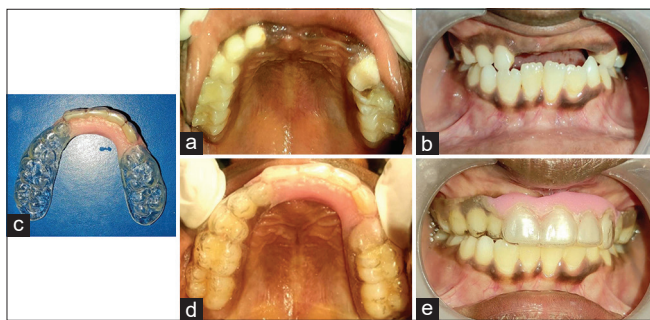


Figure 3: (a and b) Preoperative intraoral image. (c) Modified Essix retainer with pontics in relation to 11, 21, 22, and 23. (d and e) Postoperative intraoral image

were done followed by insertion of final prosthesis of Essix retainer incorporated with pontics in relation to 11, 21, 22, and 23 [Figures 2b, d and 3c-e]. The patient was comfortable with speech, usage, and retention, and it brought a positive attitude in the child. During follow-up, there were no intraoral lesions, retention was better, masticatory function and speech were not affected, and a positive change in the personality of the child was noticed.

## Discussion

RO is a rare, localized, nonhereditary developmental anomaly that affects tooth morphogenesis. Hitchin

described it first in 1934. However, most authors credit McCall and Wald for first reporting this condition in 1947.<sup>[4]</sup> Later, Crawford and Aldred described complete bibliography of this condition.<sup>[5]</sup> It has a predilection for maxilla over mandible (2:1), the central and lateral incisors, and commonly, it is unilateral but bilateral involvement can also be seen. Both primary and permanent dentition can be affected. If primary teeth are affected, permanent teeth will also be affected. More common anterior region is affected and the affected teeth most often occur as a continuous series.<sup>[6]</sup>

In this case, anterior maxillary permanent dentition is affected bilaterally which is visible radiographically. The exact etiology is unknown but can be associated with various factors such as metabolic disorders, Rh incompatibility, viral infections, local trauma, vascular defects, irradiation, and medications during pregnancy. Hence, the associated cause in this patient could be local trauma.

Clinically, affected teeth have an abnormal shape and superficial pits and grooves and yellow or yellowish-brown discoloration and appear to be hypoplastic or hypocalcified. There is either delayed eruption of the teeth or the teeth might not even erupt at all. Gingival swelling, periapical infections, and abscesses even in the absence of caries can be observed in these patients. Defective mineralization in the affected teeth makes them more susceptible to dental caries.<sup>[1]</sup> Radiographically, there is a classical “ghost-like” appearance.<sup>[5,7]</sup>

Factors to be considered before deciding the treatment are patient’s age, medical history, previous dental experience, child’s and parent’s attitude regarding dental treatment, and the number of affected teeth.<sup>[1]</sup> The goals of the treatment are to maintain esthetics and masticatory function, avoid overeruption of opposing teeth, maintain the normal vertical dimensions, space maintenance, prevent the development of deleterious habits, allow for the growth of alveolar ridge for favorable future prosthetic rehabilitation. Since the maxillary alveolar ridge growth was compromised leading to development of crossbite, minor orthodontic correction and prosthetic rehabilitation were planned using Essix retainer.

The Essix retainer or appliance is a removable esthetic appliance thermoformed from plastic copolyester material and retained with the use of natural undercuts of the contact points.<sup>[3]</sup> It has anterior flexibility with maintenance of posterior stability, thus making it both light and strong without interfering with speech.

The Essix appliance was made by Sheridan for long-term retention<sup>[8,9]</sup> and replacing spring retainers for minor tooth movements. Various other uses include use as a temporary bridge, for habit correction, incorporation of pontic for a single missing anterior tooth, molar uprighting appliance,

space maintenance, a palatal expansion retainer, and a bite plane. Modified Essix retainers have been utilized in anchorage reinforcement in the correction of crowding in mandible, anterior crossbite, posterior crossbite, ectopic canines, and Class II malocclusion and for attachment of elastic traction.<sup>[3]</sup>

An acrylic plate removable prosthesis was ruled out because of the compromised retention when pontics were placed favoring crossbite correction. The Essix retainers can serve as an interim prosthesis for maintaining alveolar ridge before placement of permanent prosthesis, correction of crossbite and enhancing esthetics. It provides better retention without affecting the speech or function, and also, the modifications are easy depending on the eruption of teeth and growth of the child.

### Conclusion

Treatment of a child with RO requires a multidisciplinary approach and should be based on the degree of involvement as well as functional and esthetic needs in individual cases. Modified Essix retainers can be used as a promising alternative in managing this condition in children before permanent prosthesis.

### Declaration of patient consent

The authors certify that they have obtained all appropriate patient consent forms. In the form the patient(s) has/have given his/her/their consent for his/her/their images and other clinical information to be reported in the journal. The patients understand that their names and initials will not

be published and due efforts will be made to conceal their identity, but anonymity cannot be guaranteed.

### Financial support and sponsorship

Nil.

### Conflicts of interest

There are no conflicts of interest.

### References

1. Murthy PS, Deshmukh S. Regional odontodysplasia and its treatment maneuver. *Int J Health Allied Sci* 2013;2:153-8.
2. Rashidian A, Afsharian Zadeh M, Azarshab M, Zarrabian T. Regional Odontodysplasia: Report of a case. *J Dent (Shiraz)* 2013;14:197-200.
3. Giancotti A, Romanini G, Docimo R. Early treatment of anterior crossbite with an Essix-based appliance. *J Clin Orthod* 2004;38:161-4.
4. Magalhães AC, Pessan JP, Cunha RF, Delbem AC. Regional odontodysplasia: Case report. *J Appl Oral Sci* 2007;15:465-9.
5. Crawford PJ, Aldred MJ. Regional odontodysplasia: A bibliography. *J Oral Pathol Med* 1989;18:251-63.
6. Malhotra R, Singla S, Shashikiran ND, Verma A. Regional odontodysplasia: A classical case report. *SRM J Res Dent Sci* 2013;4:86-9.
7. Melamed Y, Harnik J, Becker A, Shapira J. Conservative multidisciplinary treatment approach in an unusual odontodysplasia. *ASDC J Dent Child* 1994;61:119-24.
8. Lindauer SJ, Shoff RC. Comparison of essix and hawley retainers. *J Clin Orthod* 1998;32:95-7.
9. Sheridan JJ, LeDoux W, McMinn R. Essix retainers: Fabrication and supervision for permanent retention. *J Clin Orthod* 1993;27:37-45.