



Case report

Spontaneous uterine rupture revealing vascular Ehlers-Danlos syndrome: An uncommon case report

Aziz Slaoui^{a,b,*}, Mariam Mahtate^a, Hanaa Lazhar^a, Amina Lakhdar^a, Aziz Baydada^b, Aicha Kharbach^a

^a Gynaecology-Obstetrics and Endocrinology Department, Maternity Souissi, University Hospital Center IBN SINA, University Mohammed V, Rabat, Morocco

^b Gynaecology-Obstetrics and Endoscopy Department, Maternity Souissi, University Hospital Center IBN SINA, University Mohammed V, Rabat, Morocco

ARTICLE INFO

Keywords:

Uterine rupture

Pregnancy

Vascular Ehlers-Danlos syndrome

ABSTRACT

Introduction and importance: Vascular Ehlers-Danlos syndrome also referred to as Ehlers-Danlos Type IV is an uncommon autosomal dominant genetic disorder linked to connective tissue abnormality. Its evolution is marked by the occurrence of severe vascular, digestive and obstetrical complications. The current case highlights the importance of early diagnosis and physician awareness about this disorder as it can improve the patient's prognosis.

Case presentation: We present the case of a 34-year-old woman, who presented at 36 weeks of amenorrhea with labor pain. The labor evolution was marked by an increased fluctuating abdominal pain, a sudden loss of the fetal station detected during cervical examination and decelerations to 60 beats per min, leading to an emergency caesarean section. During the laparotomy, the patient presented a spontaneous bilateral extension of the cutaneous incision requiring the realization of stopping stitches. The fetus and placenta had been expelled via a 9 cm long uterine wall rupture also known as an open book uterine rupture. A live male infant weighting 2890 g was promptly delivered and transported to NICU for respiratory distress. Physical features typical of EDS-IV allowed us to suspect this disorder and genetic analysis identified the presence of COL3A1 gene mutation, confirming the diagnosis.

Clinical discussion and conclusions: Early recognition of Vascular Ehlers-Danlos syndrome is of paramount importance to improve the prognosis of affected patients, who often present themselves with life-threatening situations. Clinicians should maintain a high index of suspicion for the clinical signs of this inherited connective tissue disorder that is characterized by distinctive features.

1. Introduction and importance

Ehlers-Danlos syndrome is an autosomal dominant pathology affecting approximately 1 in 20,000 subjects, with no ethnic predisposition [1]. It was first described by Tschernogubow in 1891, then by Ehlers in 1901 and Danlos in 1908, but it was not until the 1930s that this syndrome gained the interest of the scientific community [1,2]. During the 1950s, it was reported the existence of a congenital deficiency in lysyl-hydroxylase, which is involved in the metabolism of collagen fibrils with different genetic mutations concerning type I, III and V collagen [2–4]. A first classification was proposed by Berlin et al. [1] classifying 11 forms and has been replaced by that of Villefranche et al. [2] which distinguishes 6 forms according to the clinical

expression, the mode of transmission and the incriminated gene [5,6]. Therefore, EDS forms a heterogeneous group involving several genetic diseases of the connective tissue, the most hazardous of which is type IV - the vascular type - that is caused by heterozygous mutations of the COL3A1 gene affecting type III collagen [2–7].

We hereby present a unique case of type IV Ehlers-Danlos syndrome remained undiagnosed until the onset of a complication related to this disease. This case underlines the importance of early diagnosis for optimal outcomes of affected patients, and characterizes the nature and magnitude of pregnancy risks in women with vascular Ehlers-Danlos syndrome.

* Corresponding author at: University Hospital Center IBN SINA of Rabat, Gynaecology-Obstetrics and Endocrinology Department, Mohammed V of Rabat, Morocco.

E-mail address: azizslaoui27@gmail.com (A. Slaoui).

<https://doi.org/10.1016/j.ijscr.2022.106840>

Received 26 January 2022; Received in revised form 10 February 2022; Accepted 13 February 2022

Available online 18 February 2022

2210-2612/© 2022 Published by Elsevier Ltd on behalf of IJS Publishing Group Ltd. This is an open access article under the CC BY-NC-ND license

(<http://creativecommons.org/licenses/by-nc-nd/4.0/>).

2. Case presentation

We hereby report an uncommon case of a 34-year-old woman, gravida 1, para 0, who presented to our labor ward at 36 weeks of amenorrhea with labor pain. Examination findings indicated her active labor and therefore she was admitted to the hospital. Her cervix was 5 cm dilated with full effacement. The fetus presented as cephalic with a vertex presentation at the +1 station. She was reassessed approximately every hour after admission. Fetal Heart Rate tracing revealed a category 1 tracing with a baseline of 140 beats per minute. Labor progressed smoothly until the sudden appearance of an acute abdominal pain following a hard uterine contraction, a sudden loss of the fetal station was detected during cervical examination as well as fetal decelerations to 60 beats per min. Uterine rupture was suspected. It was then quickly decided to do an emergency caesarean section. During the laparotomy performed by the on-call obstetrician according to the Joël-Cohen surgical technique, the patient presented a spontaneous bilateral extension of the cutaneous incision requiring the realization of stopping stitches. A large hemoperitoneum was noted and the fetus as well as the placenta had been expelled via a 9 cm long uterine wall rupture also known as an open book uterine rupture (Fig. 1). Active bleeding was noted at the laceration wound. A live male infant weighting 2890 g was promptly delivered and transported to NICU for respiratory distress. APGAR score being at 4, 6 and 8 at respectively 1,5,10 min. He was discharged on day 5 of life.

Closing of the different tissue layers was very difficult because of extreme tissue fragility. Uterine repair was done in two layers using No.1 vicryl. First with running lock sutures and the second layer was done with separate mattress sutures. The uterine serosa was also sutured continuously. Surrounding structures such as the bladder, broad ligament and nearby bowel were inspected and found to be unscathed. An abdominal toileting was done with warm normal saline. Then, a temporary abdominal drain was secured. Non-absorbable sutures were used without tension for skin closure with numerous and close stitches that has been left in place for 20 days. Their removal was gradual (1 out of 2 stitches) and healing was monitored. The total estimated blood loss was about 2100 mL. The patient received 6 units of whole blood and 2 units of fresh frozen plasma intraoperatively. She remained under general anaesthesia and was transferred to the intensive care unit for further monitoring and stabilization. She was discharged on the fifth post-

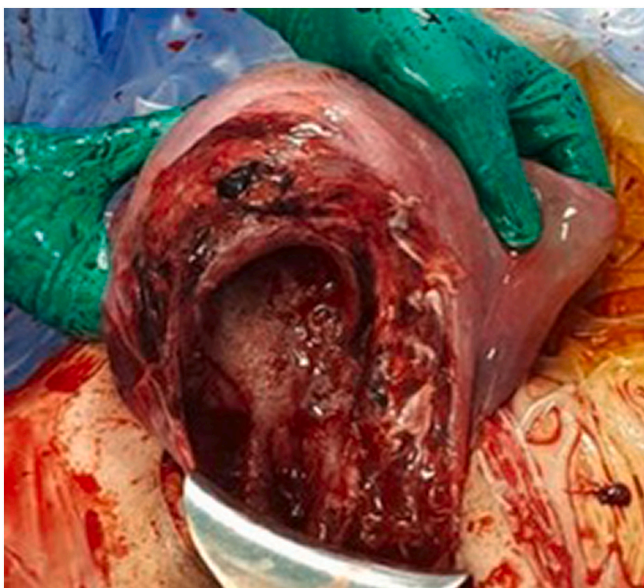


Fig. 1. Horizontal uterine rupture at the level of the lower segment, opening the uterus like a book also known as the open book uterine rupture.

operative day in a stable condition.

The patient fulfilled the criteria of type IV Ehlers-Danlos syndrome. The diagnostic suspicion was based, in addition to the uterine rupture, on other clinical features: a particular facial morphotype (narrow nose, thin lips, protruding cheekbones and sunken eyes). The other physical signs found are an excessive cutaneous transparency with visualization of the venous network, a cutaneous fragility with numerous spontaneous hematomas, difficult healing with the appearance of dystrophic scars and an hyperlaxity predominant on the small joints. The patient's family history was also explored, revealing the sudden death of her mother at the age of 39 and which etiology was not investigated, and the death of her sister of an abdominal aorta rupture at the age of 35. She was then referred to the regional genetics clinic where she was confirmed to have Ehlers-Danlos syndrome. Worried about the process, the patient was pleased to have been able to put a name to her condition. She was strongly advised not to get pregnant again. In the case of a new pregnancy, careful monitoring and an elective caesarean section were advised.

3. Clinical discussion

There are several different types of Ehlers-Danlos syndrome, each with its own set of features and complications. Vascular Ehlers-Danlos syndrome is the most serious form of the condition, involving potentially life-threatening complications. It represents 5–10% of all cases of EDS [6–9]. Vascular Ehlers-Danlos syndrome also referred to as Ehlers-Danlos Type IV and Sack-Barabas syndrome, is a rare genetic disease (1 patient of 150.000), caused by heterozygous mutations in the COL3A1 gene affecting type III collagen. Its transmission is autosomal dominant, not linked to sex since the COL3A1 gene is located on chromosome 2. Type III collagen is particularly present in the vessels (arteries and veins), intestines, skin, and uterus, but also in the lungs, liver, spleen and joint capsules [5–10].

The diagnosis is essentially clinical, based in particular on a characteristic face appearance, thin and transparent skin, abnormally visible veins, a tendency to hematoma and vascular, digestive and obstetrical complications. Other signs, such as fatigability and skin fragility, a prematurely aged appearance of the hands, subluxation of the temporomandibular joint, varicose veins, early alopecia can be observed [5,6]. The diagnosis is therefore based on a range of clinical arguments with major and minor criteria (Villefranche criteria enacted in 1997 and updated in 2017) [7]. In the presence of at least two major criteria, the diagnosis is strongly suspected and the search for COL3A1 gene mutation is justified [11]. Our patient had thin translucent skin with visible veins and characteristic facial feature. She mentioned the appearance of skin wounds for minor trauma, difficult healing with the appearance of dystrophic scars, the frequent development of hematomas and also the presence of joint hyperlaxity with frequent dislocations of certain joints during non-traumatic solicitations. Sudden unexplained death(s) in close relative(s) are highly suggestive of the disease, familiar with an autosomal dominant transmission pattern [12]. Therefore family history and sudden deaths should be investigated among relatives. [12,13] In the present case, the patient's mother had a sudden death of which the etiology was not investigated and her sister died from an abdominal aorta rupture. The clinical diagnosis can be confirmed by fibroblast culture from a skin biopsy allowing the detection of an abnormal type III collagen or by the detection of a COL3A1 gene mutation [12].

Patients with vascular EDS are at increased risk of complications during pregnancy and postpartum [13]. The first trimester is marked by an increase miscarriages number while in the third trimester the risks are postpartum hemorrhages, perineal tears, arterial ruptures (abdominal aorta, iliac arteries) during expulsive efforts and of course uterine ruptures [14,15]. Reported maternal mortality rate per pregnancy in EDS type IV varies between 11.5% and 38.5% depending on the series [13–19]. Fetal complications are also reported, occupying in first place the 50% risk of transmission of the disease but also the risk of

prematurity by premature rupture of the membranes or cervical incompetence and intrauterine growth retardation [13–17].

Several authors recommend informing patients of these risks and contraindicating or strongly advising against pregnancy [13–19]. If the patient wishes to lead a pregnancy, it must be managed in a multidisciplinary manner in a center with the best available interventional radiology, vascular surgery and pediatric and adult resuscitation services [20,21]. Follow-up is then coordinated with the referral center [20]. This pregnancy is scheduled after a lesion assessment: ultrasound of the supra-aortic trunks and distal portions of limb arteries, transthoracic echocardiography and injected CT scan to explore the aorta and its branches [21]. There is no recommendation as to the need to repeat the examinations during pregnancy and the follow-up is therefore mainly clinical. It seems preferable to use a drug prevention of arterial accidents by a long-term treatment with celiprolol at maximum tolerated doses (ideally 400 mg/day) with monitoring of fetal tolerance (growth and utero-placental blood flow) to allow a better control of these complications [21,22]. The mode of action is incompletely known but it is probably mixed: on one hand the vasodilating properties of the drug would make it possible to reduce the vascular parietal constraint and limit the hemodynamic variations in particular with effort and on the other hand, it's related to the inhibition of the renin-angiotensin-aldosterone system thus decreasing TGF β activation [21,23].

Concerning the incidence of occurrence of pregnancy-related complications of the disease, few data are available in the literature. A retrospective series by Dubruc et al. [16], studied the course of pregnancies in 13 patients with vascular EDS (27 pregnancies). In this series, most deliveries took place vaginally (78.3% with 18 deliveries) and 33% of patients who delivered vaginally had complications such as perineal tears. Only two patients presented a major complication (8.7% of patients) with rupture of a pillar of the mitral valve after vaginal delivery and rupture of the cecum after prophylactic caesarean section. No patient had died.

In a general series by Pépin et al. [5] published in 2000 involving 220 patients with vascular EDS, including 81 obstetrical patients and 167 deliveries: maternal mortality rate was 11.5%, 5 patients having presented with uterine rupture during labor, 2 patients with vascular rupture during labor and 5 patients with vascular rupture within two weeks of postpartum. The other complications were not detailed in this study. Lurie et al. [17] presented in 1998 a review of obstetrical cases. In this study, 50 pregnancies in 26 patients were analyzed. The reported mortality rate was 38.5% (2 uterine ruptures, 2 per-partum vascular ruptures, 5 post-partum vascular ruptures and 1 whose cause had not been identified). In addition, 23% of patients had presented with postpartum hemorrhage.

There is currently no consensus regarding the delivery route for these patients. Several authors recommend performing a prophylactic caesarean section because of the high risk of severe perineal lesions, uterine rupture and vascular ruptures during vaginal deliveries, despite a possible increase in the risk of hemorrhage and wound healing difficulties associated with performing a caesarean section [27]. The delivery route decision should be made based on the risk/benefit balance [23–27]. The risks of vaginal delivery being uterine rupture, tearing of the vaginal wall, perineal lesion difficult to suture and healing difficulty. Caesarean section is not without risk either: this delivery route seems to increase the risk of occurrence of vascular or digestive complications, the risk of postpartum hemorrhage, fragile uterine tissue that is difficult to suture and large uterine scar. Regardless of the decision taken, delivery must be scheduled in a specialized care structure with adult and neonatal resuscitation, a blood product delivery unit, an interventional radiology unit and obstetrical and surgical teams trained in the management of this pathology [28]. Our patient underwent an emergency caesarian section for suspected uterine rupture. This latter was complicated by excessive bleeding which made surgery laborious and closing of the different layers was very difficult due to extreme tissue fragility. The diagnosis of EDS type IV was made afterwards through clinical findings

and genetic analysis.

The healing rate in women with vascular EDS is slower than in a healthy subject and due to the fragility of the tissues it is necessary to perform wide sutures without tension, held in place two to three times longer than in the general population [26–28]. Our patient presented a spontaneous bilateral extension of the cutaneous incision requiring the realization of stopping stitches. Myometrium was repaired in two layers (first layer with running lock sutures and the second with separate mattress sutures). The uterine serosa was also sutured continuously. Non-absorbable sutures were used without tension for skin closure, with numerous and close stitches that has been left in place for 20 days. Their removal was gradual (1 out of 2 stitches) and healing was monitored. The postpartum period is a period at risk of complications and requires increased monitoring: hemorrhage by cervix tearing, tearing of the perineum, dehiscence of the episiotomy, healing disorders, uterine bleeding and infections [25–28].

Thromboembolic prevention (enoxaparin sodium at 40 mg per day for 4–6 weeks and compression stockings for 6–8 weeks) should be implemented in the event of a thromboembolic risk. Perineal rehabilitation is also highly recommended to reduce the risk of subsequent vaginal prolapse [25–28].

4. Conclusions

Vascular EDS is an uncommon disease with a poor prognosis. Mortality is mainly related to arterial ruptures, gastrointestinal perforations and uterine ruptures. Suspicious attitude should be adopted in front of characteristic clinical features and confirmation is based on the detection of a mutation in the gene encoding type III collagen. Clinicians should be prepared to deal with EDS IV-related hazards encountered during pregnancy and take special prophylactic and therapeutic measures.

This work has been reported in line with the SCARE 2020 criteria [29].

Abbreviations

EDS	Ehlers-Danlos Syndrome
NICU	Neonatal Intensive Care Unit
CT	computed tomography
TGF β	transforming growth factors β

Sources of funding

There are no funding sources to be declared.

Ethical approval

Ethics approval has been obtained to proceed with the current study.

Consent

Written informed consent was obtained from the patient for publication of this case report and any accompanying images. A copy of the written consent is available for review by the Editor-in-Chief of this journal.

Author contribution

AS: study concept and design, data collection, data analysis and interpretation, writing the paper. MM: study concept, data collection, data analysis, writing the paper. HL: study concept, data collection, data analysis, writing the paper. AL: study design, data collection, data interpretation, writing the paper. AK: study design, data collection, data interpretation, writing the paper. AB: study concept, data collection, data analysis, writing the paper.

Guarantor

The corresponding author is the guarantor of submission.

Declaration of competing interest

The authors declare that they have no competing interests.

Acknowledgements

None.

Availability of data and materials

Supporting material is available if further analysis is needed.

Provenance and peer review

Not commissioned, externally peer-reviewed.

References

- [1] P. Beighton, A. De Paepe, B. Steinmann, P. Tsipouras, R.J. Wenstrup, Ehlers-Danlos syndromes: revised nosology, Villefranche, 1997. Ehlers-Danlos National Foundation (USA) and Ehlers-Danlos Support Group (UK), *Am. J. Med. Genet.* 77 (1) (1998 Apr 28) 31–37.
- [2] P. Beighton, A. De Paepe, D. Danks, et al., International nosology of heritable disorders of connective tissue, Berlin, 1986, *Am. J. Med. Genet.* 29 (1988) 581–594.
- [3] D.J. Taylor, I. Wilcox, J.K. Russell, Ehlers-danlos syndrome during pregnancy: a case report and review of the literature, *Obstet. Gynecol. Surv.* 36 (1981) 277.
- [4] D.P. Germain, Ehlers-danlos syndrome type IV, *Orphanet J. Rare Dis.* 2 (2007) 32.
- [5] M. Pepin, U. Schwarze, A. Superti-Furga, P.H. Byers, Clinical and genetic features of ehlers-danlos syndrome type IV, the vascular type, *N. Engl. J. Med.* 342 (2000) 673.
- [6] N.P. Burrows, The molecular genetics of the ehlers-danlos syndrome, *Clin. Exp. Dermatol.* 24 (1999) 99–106.
- [7] J.-L. Yen, S.-P. Lin, M.-R. Chen, D.-M. Niu, Clinical features of ehlers-danlos syndrome, *J. Formos. Med. Assoc. Taiwan Yi Z.* 105 (6) (2006 Jun) 475–480.
- [8] D. Bergqvist, M. Bjorck, A. Wanhainen, Treatment of vascular ehlers-danlos syndrome: a systematic review, *Ann. Surg.* 258 (2) (2013) 257–261.
- [9] H. Skirton, L. Goldsmith, L. Jackson, et al., Quality in genetic counselling for presymptomatic testing – clinical guidelines for practice across the range of genetic conditions, *Eur. J. Hum. Genet.* 21 (3) (2013) 256–260.
- [10] A. Watanabe, T. Kosho, T. Wada, et al., Genetic aspects of the vascular type of ehlers-danlos syndrome (vEDS, EDSIV) in Japan, *Circ. J.* 71 (2) (2007) 261–265.
- [11] J. Ross, R. Grahame, Joint hypermobility syndrome, *BMJ* 342 (2011), c7167.
- [12] J.K. Park, Ehlers-danlos syndrome type IV and the management of its vascular complication, *Korean J. Vasc. Endovasc. Surg.* 27 (2011) 47–51.
- [13] M.G. Pepin, U. Schwarze, K.M. Rice, M. Liu, D. Leistriz, P.H. Byers, Survival is affected by mutation type and molecular mechanism in vascular ehlers-danlos syndrome (EDS type IV), *Genet. Med.* 16 (2014) 881–888.
- [14] P.H. Byers, J. Belmont, J. Black, J. De Backer, M. Frank, X. Jeunemaitre, et al., Diagnosis, natural history, and management in vascular ehlers-danlos syndrome, *Am. J. Med. Genet. C: Semin. Med. Genet.* 175 (2017) 40–47.
- [15] M. Frank, J. Albuissou, B. Ranque, L. Golmard, J.M. Mazzella, L. Bal-Theoleyre, A. L. Fauret, T. Mirault, N. Denarié, E. Mousseaux, P. Boutouyrie, J.N. Fiessinger, J. Emmerich, E. Messas, Jeunemaitre X. Eur, J. Hum, The type of variants at the COL3A1 gene associates with the phenotype and severity of vascular ehlers-danlos syndrome, *Genet.* 23 (12) (2015 Dec) 1657–1664.
- [16] E. Dubruc, S. Dupuis-Girod, P. Khau Van Kien, E. Denis-Belicard, C. Chirossel, S. Fokstuen, et al., Pregnancy and ehlers-danlos vascular syndrome: patients' care and complications, *J. Gynecol. Obstet. Biol. Reprod.* 42 (2) (2013 Apr) 159–165.
- [17] S. Lurie, M. Manor, Z.J. Hagay, The threat of type IV ehlers-danlos syndrome on maternal well-being during pregnancy: early delivery may make the difference, *J. Obstet. Gynaecol.* 18 (3) (1998 May) 245–248.
- [18] K.T. Ong, J. Perdu, J. De Backer, E. Zozec, P. Collignon, J. Emmerich, A.L. Fauret, J.N. Fiessinger, D.P. Germain, G. Georgesco, J.S. Hulot, A. De Paepe, H. Plauchu, X. Jeunemaitre, S. Laurent, P. Boutouyrie, Effect of celiprolol on prevention of cardiovascular events in vascular Ehlers-Danlos syndrome: a prospective randomised, open, blinded-endpoints trial, *Lancet* 376 (9751) (2010 Oct 30) 1476–1484.
- [19] R. Hammond, N. Oligbo, Ehlers-danlos syndrome type IV and pregnancy, *Arch. Gynecol. Obstet.* 285 (1) (2012) 51–54.
- [20] G.M. Cooper, J.H. McClure, Maternal deaths from anaesthesia. An extract from why mothers die 2000-2002, the confidential enquiries into maternal deaths in the United Kingdom: Chapter 9: Anaesthesia, *Br. J. Anaesth.* 94 (4) (2005 Apr) 417–423.
- [21] M.-Y. Liang, E. Hanko, M.S. Dhamee, Ehlers-danlos syndrome type IV: anesthetic considerations—case report, *Middle East J. Anesthesiol.* 18 (6) (2006 Oct) 1185–1189.
- [22] F. Malfait, C. Francomano, P. Byers, J. Belmont, B. Berglund, J. Black, The 2017 international classification of the Ehlers-Danlos syndromes, *Am. J. Med. Genet. C: Semin. Med. Genet.* 175C (2017) 8–26.
- [23] P.R. Blackburn, Z. Xu, K.E. Tumelty, R.W. Zhao, W.J. Monis, K.G. Harris, et al., Biallelic alterations in AEBP1 lead to defective collagen assembly and connective tissue structure resulting in a variant of ehlers-danlos syndrome, *Am. J. Hum. Genet.* 102 (4) (2018) 696–705.
- [24] J. Kang, M. Hanif, E. Mirza, S. Jaleel, Ehlers-Danlos syndrome in pregnancy: a review, *Eur. J. Obstet. Gynecol. Reprod. Biol.* 255 (2020) 118–123.
- [25] N. Chiarelli, G. Carini, N. Zoppi, M. Ritelli, M. Colombi, Transcriptome analysis of skin fibroblasts with dominant negative COL3A1 mutation provides molecular insights into the eQopathology of vascular ehlers-danlos syndrome, *PLoS ONE* 13 (1) (2018), e0191220.
- [26] J.M. Bowen, G.J. Sobey, N.P. Burrows, M. Colombi, M.E. Lavalley, F. Malfait, et al., Ehlers-danlos syndrome, classical type, *Am. J. Med. Genet. C: Semin. Med. Genet.* 175 (1) (2017) 27–39.
- [27] Benistan, in: Les syndromes d'Ehlers Danlos : classification, diagnostics différentiels et traitements Douleurs 19, 2018, pp. 161–165.
- [28] A.F. Baas, W. Spiering, F.L. Moll, L. Page-Christiaens, I.C. Beenackers, D. Dooijes, et al., Six uneventful pregnancy outcomes in an extended vascular ehlers-danlos syndrome family, *Am. J. Med. Genet. A* 173 (2017) 519–523.
- [29] R.A. Agha, T. Franchi, C. Sohrabi, G. Mathew, for the SCARE Group, The SCARE 2020 guideline: updating consensus Surgical CASE REport (SCARE) guidelines, *Int. J. Surg.* 84 (2020) 226–230.