

# Hypertension without renovascular stenosis: a rare case of abdominal aorta coarctation treated with percutaneous transluminal angioplasty

Weiwei Ding, Wuxing Jiang, Ning Li, Jieshou Li

Research Institute of General Surgery, Jinling Hospital, Nanjing University School of Medicine, Jiangsu Province, China

**Submitted:** 24 August 2010

**Accepted:** 11 November 2010

Arch Med Sci 2012; 8, 1: 168-171

DOI: 10.5114/aoms.2012.27298

Copyright © 2012 Termedia & Banach

**Corresponding author:**

Wuxing Jiang MD, PhD  
Research Institute  
of General Surgery  
Jinling Hospital  
Nanjing University School  
of Medicine, Jian  
210002 Nanjing, China  
Phone: 86-25-345123213  
E-mail: dingwei\_nju@  
hotmail.com

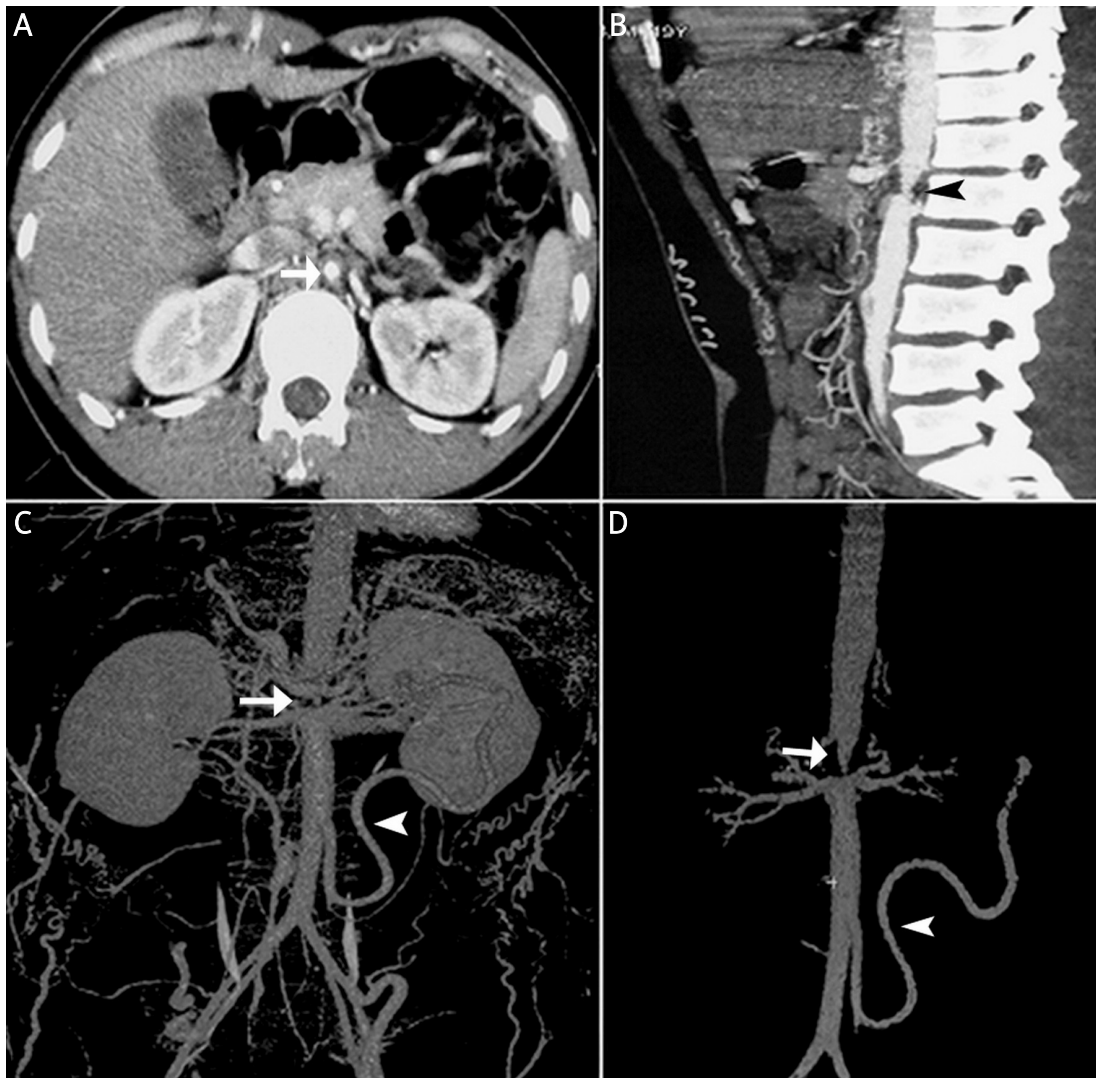
We describe a patient with a focal abdominal aortic stenosis without renovascular stenosis manifested as severe hypertension. Although hypertension and unilateral or bilateral renal artery stenosis are common in abdominal aortic stenosis, patients presenting with hypertension as the sole clinical feature without renal artery stenosis are rare.

A 12-year-old boy was admitted to our department for severe hypertension (190/110 mmHg). The hypertension was found during a scheduled physical examination. His blood pressure control was poor despite taking 3 different antihypertensive agents (indapamide, amlodipine and telmisartan for over 2 months). He did not have any clinical manifestations other than hypertension and felt healthy with no constitutional symptoms such as fatigue, malaise, dizziness, myalgia, arthralgia, headache, claudication, weight loss or fever. There was no past history of a prolonged fever of unknown origin suggesting a diagnosis of Takayasu arteritis. The family history was negative for primary hypertension, cardiovascular, vasculitis or other familial diseases.

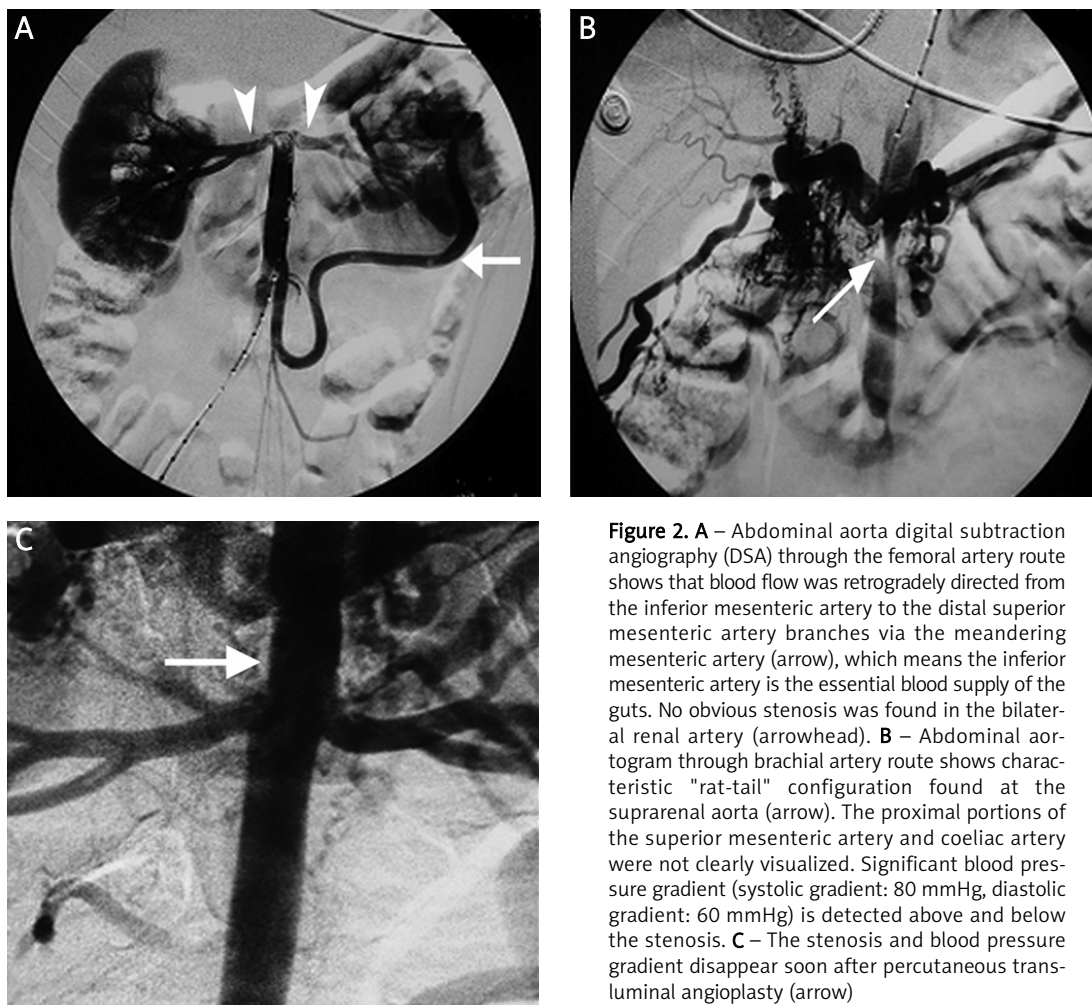
The physical examination demonstrated that the patient was in good condition with a body weight and height in the normal range. Blood pressure in the right arm was 190/110 mmHg and in the left arm 185/90 mmHg. Bruit was audible on auscultation over the abdominal aorta. The bilateral femoral artery was non-palpable and blood pressure of both legs was undetectable. The patient's erythrocyte sedimentation rate and C-reactive protein (CRP) were 2 mm/h (normal: 0-9 mm/h) and 0.8 mg/dl (normal: 0-0.36 mg/l). Serum Ig A, Ig E, Ig G, Ig M and complement C3 and C4 were normal. Antinuclear antibody (ANA) and antineutrophil cytoplasmic antibody (ANCA) were negative. The laboratory data revealed normal plasma renin activity (140 pg/ml), normal serum aldosterone levels and a normal glomerular filtration rate. Tests of infectious disease, such as hepatitis B, C, tuberculosis and HIV, were negative. An electrocardiogram (ECG) revealed a sinus rhythm, rate of 80 beats/min, and no ST changes. Echocardiography showed left ventricular hypertrophy with good systolic function. He received an abdominal angio-computed tomographic scan with volumetric reconstruction, which showed a focal stenosis at the suprarenal aorta with a minimum diameter of less than 2 mm and extensive collateral circulations (Figures 1 A-D). Echo-Doppler examination of the lower limbs demonstrated pulselessness of the bilateral femoral, popliteal and foot dorsal artery. Abdominal echo-Doppler revealed 60% obstruction of the aor-

ta lumen with significant increased peak flow velocity. Echo-Doppler of the carotid, subclavian arteries and heart was normal. Abdominal aorta angiography was performed through the right femoral artery under general anaesthesia (Figure 2 A), which demonstrated that afferent blood flow was found under the infrarenal aorta and the contrast medium could not pass through it, and the inferior mesenteric artery was compensatorily enlarged. As the stenosis could not be crossed with a guidewire, another angiography was performed through the left brachial artery until the suprarenal aorta, which revealed that there was severe stenosis (> 90%) of the coeliac artery and occlusion of the superior mesenteric artery (SMA) with a prominent inferior mesenteric artery (IMA) meandering mesenteric collateral (Figure 2 B). Blood pressure, which was

monitored through the artery catheter, showed distal stenosis of 70/40 mmHg and proximal of 150/100 mmHg. Percutaneous transluminal angioplasty was performed at the level of the suprarenal aorta using a 4.0/12 mm balloon catheter (Figure 2 C). The angiographic guide wires were hydrophilic (M. Radifocus, Engled Type, Terumo, Tokyo, Japan). The saline used for flushing the catheters was heparinized (2,000 units/250 ml). The diagnostic catheter was replaced with a dilating catheter with a 4.5 F shaft and a balloon, which would permit a maximum inflation pressure of 10 atm (Usci Bard, Bilerica, Mass., USA). The balloon was inflated to working pressure for approximately 30 s using a 50% solution of saline and ioxaglate 320. The entire dilatation procedure was monitored fluoroscopically. After this procedure, the blood pressure



**Figure 1.** Axial (A) and sagittal (B) thin MIP CT angiography images after intravenous contrast administration show thickening in the aortic wall and severe stenosis in the lumen above the level of the renal artery (arrow). Associated thickening is seen in the sagittal image in the abdominal aortic wall (black arrowhead). Double detector volume rendered CT angiography (C and D) shows severe stenosis at the suprarenal aorta with a maximum diameter of less than 8 mm (arrow) and extensive collateral circulations formed between the proximal and distal stenosis. The inferior mesenteric artery was compensatorily enlarged (arrowhead)



**Figure 2.** **A** – Abdominal aorta digital subtraction angiography (DSA) through the femoral artery route shows that blood flow was retrogradely directed from the inferior mesenteric artery to the distal superior mesenteric artery branches via the meandering mesenteric artery (arrow), which means the inferior mesenteric artery is the essential blood supply of the guts. No obvious stenosis was found in the bilateral renal artery (arrowhead). **B** – Abdominal aortogram through brachial artery route shows characteristic "rat-tail" configuration found at the suprarenal aorta (arrow). The proximal portions of the superior mesenteric artery and coeliac artery were not clearly visualized. Significant blood pressure gradient (systolic gradient: 80 mmHg, diastolic gradient: 60 mmHg) is detected above and below the stenosis. **C** – The stenosis and blood pressure gradient disappear soon after percutaneous transluminal angioplasty (arrow)

decreased by 20% (120/95 mmHg) in the proximal part and increased by 64% (115/90 mmHg) in the distal part of the aorta, and remained steady during the 7 days after the procedure.

He has been followed up at 2 weeks, 4 weeks and then monthly until 50 months after treatment, and maintains the normal arm blood pressure without medications. Duplex scanning of the abdominal aorta showed normal blood flow patterns without evidence of residual stenosis.

Abdominal aorta coarctation is often called "middle aortic syndrome" or "mid-aortic dysplastic syndrome." It is a diffuse narrowing of the abdominal aorta that commonly involves the visceral and renal arteries. This condition typically presents as severe hypertension in young patients who have weak or absent femoral pulses. The aetiology of abdominal aorta coarctation is controversial. It may be secondary to an intimal or medial fibrosis, intraluminal thrombosis, fibromuscular dysplasia, congenital anomaly, neurofibromatosis, Williams syndrome, Alagille syndrome, or rubella syndrome [1]. These vascular lesions have been attributed to proliferation of Schwann cells within the arterial walls fol-

lowed by secondary degenerative changes and fibrosis. Congenital abdominal aortic stenosis, another common cause of abdominal aorta coarctation, is thought to be the result of a primary underdeveloped aortic segment that also commonly affects the renal arteries. Aortic tissue from affected areas usually exhibits marked subendothelial fibroplasia but with no evidence of acute or chronic inflammation.

On the basis of the American College of Rheumatology criteria [2] and Sharma's diagnostic criteria [3], the patient was originally diagnosed with Takayasu arteritis (TA). However, American College of Rheumatology (ACR) criteria do not include signs and symptoms of inflammation and therefore their application in the case of children without signs of inflammation has been recently criticised [4]. In our patient, typical focal stenosis of the aorta and well-developed collateral circulation depicted on radiograms further enhanced the possibility of a congenital anomaly.

Hypertension was the most common presenting feature, seen in 90% of abdominal aorta coarctation patients with renal artery stenosis [5].

Although the narrowed aortic segment typically is focal, diffuse hypoplasia of the abdominal aorta involving the branch arteries may occur. The renal arteries were mostly stenosed, hypoplastic, or thrombosed, resulting in hypertension. However, in this patient, severe hypertension was developed without signs of renovascular stenosis. The underlying aetiology was unclear.

Abdominal aorta coarctation remains a therapeutic challenge. Most authors agree that these patients should undergo revascularization whenever feasible. Aorto-aortic bypass, patch aortoplasty, and percutaneous techniques are the most frequent approaches used for the treatment of patients with middle aortic syndrome [6, 7]. However, the complexity of the disease often makes revascularization surgery difficult because diffuse collateral circulations were formed in the abdominal wall and viscera, resulting in a high rate of restenosis. Moreover, it is difficult to operate in weak tissues and the incidence of bleeding increases. Conventional stents may be associated with a high rate of failure, as suggested by studies with long-term follow-up. Many reports have described the usefulness of PTA in renovascular hypertension with renal artery stenosis [8], but few have concerned the type of abdominal coarctation with severe hypertension without dominant renovascular stenosis. In this case, collateral circulation was mainly formed between the stenosed superior mesenteric artery and inferior mesenteric artery, termed the "wandering artery of Drummond", and no symptoms of limb or viscera ischaemia occurred even when more than 60% of the abdominal aorta was stenosed. Therefore, we preferred PTA through the transbrachial route without stents in our patient.

In conclusion, abdominal aorta coarctation should be considered in the differential diagnosis of secondary hypertension in young people, even though they do not have associated symptoms of multiple arterial involvements. Percutaneous transluminal angioplasty may be used to correct the aortic stenosis with good long-term outcomes and no severe complications.

## References

1. Ishii K, Isono M, Kasai N, et al. Midaortic syndrome in childhood associated with a ruptured cerebral aneurysm: a case report. *Surg Neurol* 2001; 55: 209-12.
2. Arend WP, Michel BA, Bloch DA, et al. The American College of Rheumatology 1990 criteria for the classification of Takayasu arteritis. *Arthritis Rheum* 1990; 33: 1129-34.
3. Sharma S, Saxena A, Talwar KK, Kaul U, Mehta SN, Rajani M. Renal artery stenosis caused by nonspecific arteritis (Takayasu disease): results of treatment with percutaneous transluminal angioplasty. *AJR Am J Roentgenol* 1992; 158: 417-22.
4. Marks SD, Tullus K. Do classification criteria of Takayasu arteritis misdiagnose children with fibromuscular dysplasia? *Pediatr Nephrol* 2010; 25: 989-90.
5. Trojnarowska O, Bręborowicz P, Gwizdała A, et al. B-type natriuretic peptide level in adult patients after successful repair of coarctation of the aorta. *Arch Med Sci* 2008; 4: 274-7.
6. Mickley V, Fleiter T. Coarctations of descending and abdominal aorta: long-term results of surgical therapy. *J Vasc Surg* 1998; 28: 206-14.
7. Gonzalez-Ferrer JJ, Balbacid E, Vilacosta I. Middle aortic syndrome, severe hypertension, and endovascular repair. *Eur Heart J* 2009; 30: 1553.
8. Tyagi S, Singh B, Kaul UA, Sethi KK, Arora R, Khalilullah M. Balloon angioplasty for renovascular hypertension in Takayasu's arteritis. *Am Heart J* 1993; 125: 1386-93.