

Magnetic Resonance Imaging for the Assessment of Long Bone Tumors

Tao Jin, Zhi-Ping Deng, Wei-Feng Liu, Hai-Rong Xu, Yuan Li, Xiao-Hui Niu

Department of Orthopaedic Oncology Surgery, Beijing Jishuitan Hospital, Peking University, Beijing 100035, China

Abstract

Background: Wide resection margins of osseous tumors are associated with a low incidence of local recurrence, making accurate measurement of the intraosseous extent of primary malignant long bone tumors is crucial. We compared the intraosseous tumor extent assessed by magnetic resonance imaging (MRI) with the gross specimen to evaluate the accuracy of MRI.

Methods: A total of 255 patients with primary malignant tumors in the long bones were included. Using MRI, we defined the length of tumor as the distance from the articular surface to the boundary between abnormal and normal marrow signal. The extent of the abnormal intraosseous signal was measured on unenhanced T1-weighted (T1WI) magnetic resonance images after chemotherapy. All gross surgical specimens were sectioned, and tumor extent was measured. Wilcoxon signed-rank test was used to test the differences between MRI and gross specimen findings. Spearman's correlation analysis was used to test the correlation between groups.

Results: Median tumor length by gross specimen (112 mm; range, 45–300 mm) was longer than that by MRI (108 mm; range, 45–304 mm; $Z = -6.916, P < 0.001$). Of 255 images, tumor length was accurately represented on 27 T1WI magnetic resonance images, overestimated on 79 images, and underestimated on 149 images. The median difference between imaging and gross specimen measurements was 2.0 mm (range: 1.0–15.0 mm) for the 79 cases where tumor length was overestimated, and 5.0 mm (range: 1.0–18.0 mm) for the 149 cases where tumor length was underestimated. The Spearman correlation demonstrated a high correlation of tumor length on gross specimen with the tumor length on MRI ($R = 0.99, P < 0.01$).

Conclusions: We conclude that preoperative MRI could be a useful method in determining intramedullary malignant bone tumor boundaries and may serve as an accepted assessment method of long bone tumors before limb-sparing surgery.

Key words: Bone Tumor; Gross Specimen; Long Bone; Magnetic Resonance Imaging; Tumor Length

INTRODUCTION

Surgical excision is one of the most important approaches to the treatment of primary malignant bone tumors, and complete excision of the tumor margins is key to prevention of local recurrence. Unenhanced T1-weighted magnetic resonance imaging (T1WI MRI) is an important preoperative examination used to visualize the intramedullary extent of malignant long bone tumors. Early reports stated that MRI, especially T1WI MRI in patients with primary bone tumors, were reliable;^[1-4] however, the reported case numbers were small, and most studies were focused on osteosarcoma. We evaluated the validity of T1WI in determining the extent of intramedullary tumor in patients with primary malignant tumors, including osteosarcoma and some other primary malignant tumors in long bones, in a large number of patients.

METHODS

Ethical approval

The study was conducted in accordance with the *Declaration of Helsinki* and approved by the Ethics Committee of Beijing Jishuitan Hospital (Beijing Jishuitan Hospital Research Ethics; No. 20170601). Informed consent was exempted by the Ethics Committee of Beijing Jishuitan Hospital.

Address for correspondence: Prof. Xiao-Hui Niu,
Department of Orthopaedic Oncology Surgery, Beijing Jishuitan Hospital,
Peking University, Beijing 100035, China
E-Mail: niuxiaohui@263.net

This is an open access article distributed under the terms of the Creative Commons Attribution-NonCommercial-ShareAlike 3.0 License, which allows others to remix, tweak, and build upon the work non-commercially, as long as the author is credited and the new creations are licensed under the identical terms.

For reprints contact: reprints@medknow.com

© 2017 Chinese Medical Journal | Produced by Wolters Kluwer - Medknow

Received: 06-05-2017 **Edited by:** Qiang Shi
How to cite this article: Jin T, Deng ZP, Liu WF, Xu HR, Li Y, Niu XH. Magnetic Resonance Imaging for the Assessment of Long Bone Tumors. Chin Med J 2017;130:2547-50.

Access this article online

Quick Response Code:



Website:
www.cmj.org

DOI:
10.4103/0366-6999.217087

Patients

The study involved 255 patients (mean age, 20.8 ± 12.7 years old; range, 6–71 years old) with newly diagnosed long bone tumors between January 2012 and December 2015.

Inclusion criteria were (1) previously untreated patients with confirmed diagnosis of primary long bone tumor through a preoperative biopsy; (2) MRI examination performed at our hospital before the operation; (3) underwent limb salvage surgery with the resected specimen available. Patients with metastatic tumors or hematopoietic tumors were excluded. Patients with pathological fractures were excluded because of concern over unclear tumor margins. Patients with lesions on the fibula, ulna, or radius were also excluded, because of these bones' narrow marrow cavity, which is difficult to visualize.

A total of 255 cases were investigated, including 167 (65.5%) male patients and 88 (34.5%) female patients. There were 223 (87.5%) cases of osteosarcoma, 10 (4.0%) cases of chondrosarcoma, 7 (2.7%) cases of malignant spindle cell tumor, 6 (2.4%) cases of Ewing sarcoma, and 9 (3.5%) cases of other primary malignant bone tumors. There were 126 tumors in the distal femur, 20 in the proximal femur, 85 in the proximal tibia, and 24 in the proximal humerus.

All patients received treatment at our hospital. After the diagnostic and staging studies, patients with osteosarcoma and Ewing sarcoma received neoadjuvant chemotherapy and subsequent limb-sparing surgery were conducted in all patients. Resection margins were 3–5 cm distal from the tumor margins estimated by preoperative MRI.

Imaging studies and examination

MRI was obtained at diagnosis and a mean of 10 days before surgery. All MR examinations were done on a 1.5 T System (Magnetom Espree, Siemens, Germany). T1WIs were (repetition time range/echo time range) 455–520 ms/15–22 ms, section thickness: 3–4 mm. Coronal T1WI magnetic resonance images were acquired using a body coil. The patients were positioned to include the entire tumor length and the nearest articular surface. The longitudinal extent of the intraosseous portion of the tumor was measured on a workstation (PACS, Carestream Health, Inc., Canada). The length of tumors was measured from the articular surface to the point at which marrow signal intensity changed from abnormal to normal (yellow marrow). All the measurements were made by Zhi-Ping Deng and Tao Jin.

Gross specimen measurements

An electric band saw was used to bisect the gross specimens. All specimens were sectioned in the coronal plane. Tumor length was measured by mm using a millimeter scale (1 mm) from the articular surface to the tumor boundary on gross specimen by the same surgeons. Examples of measurements are shown in Figures 1 and 2.

Statistical analysis

All statistical analyses were performed using SPSS version 20.0 statistical package (IBM, Armonk NY, USA).

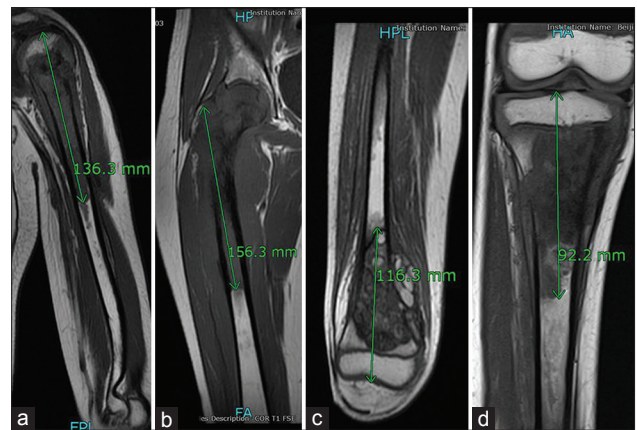


Figure 1: Representative images of magnetic resonance imaging measurements for patients with tumors located in the proximal humerus (a), proximal femur (b), distal femur (c), and proximal tibia (d).

Continuous variables are reported as median (range) or mean \pm standard deviation (SD). Wilcoxon signed-rank test was used to test the difference between measurements on preoperative MRI and gross specimens. Spearman correlation analysis was used to test the correlation between groups. The statistical significance level was set at $P < 0.05$.

RESULTS

Estimates of intraosseous tumor length based on T1WI magnetic resonance images and the corresponding measurements determined by examination of the gross specimens are given in Table 1. Median tumor length by gross specimen (112.0 mm; range, 45.0–300.0 mm) was longer than that by MRI (108.0 mm; range, 45.0–304.0 mm; $Z = -6.916$, $P < 0.001$). The mean length of MRI extent estimation was 2.7 mm shorter than specimens. Tumor length was accurately represented on 27 T1WI magnetic resonance images (mean difference < 1 mm). In 79 patients, the tumor length on the MRI was longer than those measured by MRI (median difference 2.0 mm [1.0–15.0 mm]). In 149 patients, tumor length was underestimated (median difference 5.0 mm [1.0–18.0 mm]). In 25 patients, tumor length by MRI was overestimated or underestimated > 10 mm, but ≤ 18 mm. For the 223 osteosarcoma patients, median tumor length by MRI was 1.0 mm shorter than that on the gross specimen. For the remaining 32 patients, the median tumor length measured by MRI was 4.0 mm shorter. The Spearman correlation analysis showed a high correlation of tumor length on gross specimens with the tumor length on MRI for all patients ($R = 0.99$, $P < 0.01$).

DISCUSSION

Adequate surgical margins are vital to a low local recurrence rate. Factors that affect the surgical margins comprise the preoperative excision plan and surgical technique. Excision margins comprise the soft-tissue margin and osteotomy margin. At present, the validity of MRI in the measurement of intramedullary range of bone tumor has been verified in many

Table 1: Magnetic resonance imaging and the gross specimen measurements of the intraosseous tumor lengths

Method	Tumor length (mm), median (range)				
	Proximal humerus (n = 24)	Proximal femur (n = 20)	Distal femur (n = 126)	Proximal tibia (n = 85)	Total (N = 255)
T1-weighted MRI	118.0 (57.0–174.0)	97.5 (49.0–279.0)	113.5 (54.0–304.0)	98.0 (45.0–242.0)	108.0 (45.0–304.0)
Gross specimen	121.5 (63.0–180.0)	101.5 (49.0–297.0)	118.5 (51.0–300.0)	97.0 (45.0–245.0)	112.0 (45.0–300.0)

MRI: Magnetic resonance imaging.

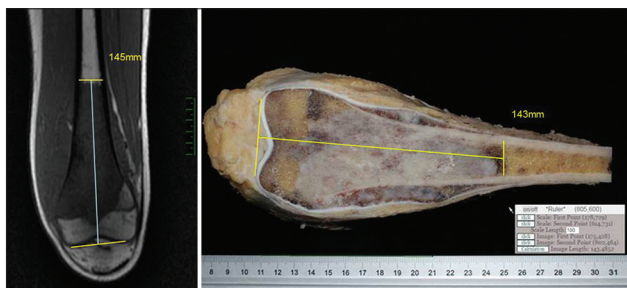


Figure 2: Representative images of tumor length measurements on preoperative T1-weighted magnetic resonance images (left) and gross specimen (right).

reports.^[2,3] Studies conducted by O’Flanagan *et al.*^[1] and Onikul *et al.*^[5] showed the consistency between T1WI MRI estimates and postoperative gross specimen measurements, with a mean difference in Onikul *et al.*’s study within 2 cm. Bloem *et al.*^[6] conducted correlation analysis of MRI intramedullary length and gross specimen measurements and found a correlation coefficient of 0.99. Gillespy *et al.*^[7] studied 17 cases and found that the difference between MRI intramedullary length and pathological measurements was 4.9 ± 4.3 mm. Furthermore, in a subgroup of five specimens with an identical plane of section, tumor length was reliably visualized within 1.8 ± 1.6 mm, which was confirmed by comparison with pathological measurements. These studies demonstrated MRI’s accuracy in the measurement of intramedullary infiltration of bone tumor. In limb salvage treatment, a surgical margin 3–5 cm^[8,9] distal to the tumor edge is deemed acceptable, so it is safe to evaluate the preoperative intramedullary infiltration according to MRI and design the length of osteotomy. In our study, the sample size was relatively large, and we measured the locations where primary bone tumor frequently occurred. Among all cases, the difference between preoperative T1WI magnetic resonance images and postoperative specimens was ≤ 20 mm, which was consistent with the results reported previously.

In our study, there were 25 cases in which the measuring difference was >10 mm. In these 25 cases, we found that inconsistency between MRI coronal plane and postoperative specimen coronal plane existed in 24 cases. This is due to inexact correspondence between the section generated by MRI and the slice generated by gross pathology and also has been shown in the previous studies. As shown in studies conducted by Gillespy *et al.*,^[7] when highly-selective cases were applied in the comparison of MRI estimate and

specimen measurements, the differences measured were smaller.

The findings of O’Flanagan *et al.*^[1] showed that flexional deformity may influence the accuracy of computed tomography (CT) and MRI measurement. However, no statistical analysis has ever been conducted with respect to their studies. The findings of Deng *et al.*^[4] showed that flexional deformity $>20^\circ$ may lead to increased CT measurement error, yet had no dramatic influence on MRI measurement. In this study, there was only one case with severe knee flexion deformity, with a measurement difference within 10–20 mm.

Although significant differences existed between MRI measurement and gross specimen measurement, high correlation of pathological tumor length with the tumor length on MRI was observed. The mean differences (2.7 mm) in our study with a sample number of 255 are similar to Deng *et al.*’s results with a sample number of 35 (3.2 mm) and Gillespy *et al.*’s results with a sample number of 17 (4.9 mm), and better than Onikul *et al.*’s results with a sample number of 20 (1.5 cm). Underestimation of tumor length occurred on MRI in 24 patients, but translesional resection would happen only if the underestimation was greater than the minimum 3–5 cm of tumor-free bone necessary for resection with wide margins. In our study, the largest underestimation was 18 mm, which is smaller than Deng *et al.*’s results (27 mm) and Onikul *et al.*’s results (2 cm). Therefore, these results confirm that MRI is an acceptably accurate method in assessing the intraosseous extent of primary malignant tumors involving long bones.

In our study, the common sites of bone tumors were included, and the reliability of MRI was measured in all these regions. However, long bones with narrower medullary cavities including the fibula, radius, and ulna were not included. In addition, because pathological fractures may make tumor boundaries unclear, patients with pathological fractures were excluded.

There are some limitations in our study that should be noted. First, the measurement of tumors was performed on gross specimens only; this may result in inaccuracies. We expect to continue our study to assess histologic specimens. Second, we defined the length of tumor as the distance from the articular surface to the tumor boundary; this length cannot reveal the tumor volume. In addition, we found statistical inconsistencies between MRI coronal plane and

gross specimen coronal plane measurements; however, the differences are acceptable in clinical settings.

In summary, the results in the present study indicate that although T1WI MRI might occasionally underestimate or overestimate tumor length, they are generally accurate for assessing intraosseous tumor extent before limb-sparing surgery.

Acknowledgments

We sincerely thank Dr. Yan-Wei Lyu for providing guidance through the analysis and interpretation of the study results.

Financial support and sponsorship

Nil.

Conflicts of interest

There are no conflicts of interest.

REFERENCES

1. O'Flanagan SJ, Stack JP, McGee HM, Dervan P, Hurson B. Imaging of intramedullary tumour spread in osteosarcoma. A comparison of techniques. *J Bone Joint Surg Br* 1991;73:998-1001.
2. Ahmad S, Stevenson J, Mangham C, Cribb G, Cool P. Accuracy of magnetic resonance imaging in planning the osseous resection margins of bony tumours in the proximal femur: Based on coronal T1-weighted versus STIR images. *Skeletal Radiol* 2014;43:1679-86. doi: 10.1007/s00256-014-1979-2.
3. Putta T, Gibikote S, Madhuri V, Walter N. Accuracy of various MRI sequences in determining the tumour margin in musculoskeletal tumours. *Pol J Radiol* 2016;81:540-8. doi: 10.12659/PJR.898108.
4. Deng Z, Li Y, Shan H, Niu X. Staging of intraosseous extent of primary appendicular malignant bone tumors: Correlation of preoperative X-ray, CT and MR imaging with pathologic macroslides (in Chinese). *Chin J Orthop* 2008;28:127-31. doi: 10.3321/j.issn:0253-2352.2008.02.008.
5. Onikul E, Fletcher BD, Parham DM, Chen G. Accuracy of MR imaging for estimating intraosseous extent of osteosarcoma. *AJR Am J Roentgenol* 1996;167:1211-5. doi: 10.2214/ajr.167.5.8911182.
6. Bloem JL, Taminiau AH, Eulderink F, Hermans J, Pauwels EK. Radiologic staging of primary bone sarcoma: MR imaging, scintigraphy, angiography, and CT correlated with pathologic examination. *Radiology* 1988;169:805-10. doi: 10.1148/radiology.169.3.3055041.
7. Gillespy T 3rd, Manfrini M, Ruggieri P, Spanier SS, Pettersson H, Springfield DS. Staging of intraosseous extent of osteosarcoma: Correlation of preoperative CT and MR imaging with pathologic macroslides. *Radiology* 1988;167:765-7. doi: 10.1148/radiology.167.3.3163153.
8. Rao BN, Champion JE, Pratt CB, Carnesale P, Dilawari R, Fleming I, *et al.* Limb salvage procedures for children with osteosarcoma: An alternative to amputation. *J Pediatr Surg* 1983;18:901-8. doi: 10.1016/S0022-3468(83)80044-X.
9. McDonald DJ. Limb-salvage surgery for treatment of sarcomas of the extremities. *AJR Am J Roentgenol* 1994;163:509-13. doi: 10.2214/ajr.163.3.8079835.