

Avascular necrosis as a part of 'long COVID-19'

Sanjay R Agarwala,¹ Mayank Vijayvargiya,² Prashant Pandey²

¹Orthopaedics, PD Hinduja National Hospital, Mumbai, Maharashtra, India

²Orthopaedics, PD Hinduja National Hospital and Medical Research Centre, Mumbai, Maharashtra, India

Correspondence to
Dr Sanjay R Agarwala;
drsa2011@gmail.com

Accepted 23 May 2021

SUMMARY

'Long COVID-19' can affect different body systems. At present, avascular necrosis (AVN) as a sequelae of 'long COVID-19' has yet not been documented. By large-scale use of life-saving corticosteroids in COVID-19 cases, we anticipate that there will be a resurgence of AVN cases. We report a series of three cases in which patients developed AVN of the femoral head after being treated for COVID-19 infection. The mean dose of prednisolone used in these cases was 758 mg (400–1250 mg), which is less than the mean cumulative dose of around 2000 mg steroid, documented in the literature as causative for AVN. Patients were symptomatic and developed early AVN presentation at a mean of 58 days after COVID-19 diagnosis as compared with the literature which shows that it generally takes 6 months to 1 year to develop AVN post steroid exposure.

BACKGROUND

A novel coronavirus named 'COVID-19' by the WHO is the cause of the current pandemic that began in December 2019 in Wuhan city, Hubei province, China. By 28 January 2021, more than 100 200 107 individuals had been infected with COVID-19, of which 2 158 761 were fatal.¹

Emerging evidence suggests that COVID-19 adversely affects different human body systems as a part of 'long COVID-19', such as Guillain-Barré syndrome, lung fibrosis, pulmonary thromboembolism, cardiomyopathy, sensory dysfunction and stroke.² Long COVID-19 is a term used to describe the long-term effects of COVID-19 infection that continue for weeks or months after the patient has recovered from COVID-19.³ National Institute for Health and Care Excellence defines 'long COVID-19' as lasting for more than 12 weeks. Symptoms of long COVID-19 can include fatigue, breathlessness, anxiety and depression, palpitations, chest pains, joint or muscle pain and not being able to think straight or focus ('brain fog').³ Since the outbreak, many agents that could have efficacy against COVID-19 have been used including various antivirals; angiotensin receptor blockers; chloroquine phosphate and corticosteroids. The efficacy of angiotensin receptor blockers and chloroquine phosphate has not been well established.^{4,5} Corticosteroids are life-saving in the management of COVID-19, however it is a predisposing factor for the development of avascular necrosis (AVN).⁶

Based on this premise, in view of the large-scale use of life-saving corticosteroids, there could be a resurgence in the number of AVN cases. An early diagnosis of AVN is important to arrest the disease's progress and prevent subsequent femoral head collapse.⁷ If diagnosed early in Ficat-Arlet stage

I or II, 92%–97% of the patients do not require surgery and can be managed with bisphosphonate therapy. Hence, it is crucial to diagnose AVN early to decrease the morbidity and the requirement of surgery.

Here, we report three cases of symptomatic AVN of the femoral head after being treated for COVID-19. This is the first case report of AVN as sequelae of 'long COVID-19'.

CASE PRESENTATION

Case 1

A 36-year-old male patient was diagnosed with COVID-19 on 6 September 2020, for which the patient was admitted in intensive care at another hospital because of dropping saturation. During his hospitalisation, the patient was administered intravenous methylprednisolone 80 mg per day for 9 days (totalling—720 mg of methylprednisolone equivalent to 900 mg prednisolone) and intravenous remdesivir and intravenous tocilizumab. The patient was discharged on oral prednisolone in tapering dose over 28 days (total—350 mg). Total steroid received by the patient was 1250 mg of prednisolone equivalent.

Forty-five days after the COVID-19 diagnosis, the patient developed pain in the right groin. The patient had no history of hip pain prior to this. Radiograph and MRI of hip done (67 days since COVID-19 diagnosis) showed bilateral hip AVN (Ficat-Arlet stage II on both hips) ([figure 1](#)).

Case 2

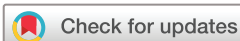A 39-year-old male patient was diagnosed with COVID-19 on 8 September 2020, the patient was given oral dexamethasone in tapering dose over 10 days (total—60 mg equivalent to 400 mg of prednisolone) along with oral favipiravir 200mg. Fifty-seven days later, the patient developed pain in the left groin region. Radiograph and MRI of the hip done showed left hip AVN (Ficat-Arlet stage II) ([figure 2](#)).

Case 3

A 37-year-old male patient was diagnosed with COVID-19 on 15 November 2020, for which intravenous methylprednisolone (500mg) was given equivalent to 625mg prednisolone. Forty-five days post COVID-19 detection, the patient developed pain in the bilateral groin. The patient had no history of hip pain in the past. Radiographs and MRI were done 55 days post COVID-19 detection that showed bilateral hip AVN (Ficat-Arlet stage II) ([figure 3](#)).

OUTCOME AND FOLLOW-UP

The mean dose of prednisolone equivalent steroid taken by the patient in our series was 758 mg (400



© BMJ Publishing Group Limited 2021. No commercial re-use. See rights and permissions. Published by BMJ.

To cite: Agarwala SR, Vijayvargiya M, Pandey P. *BMJ Case Rep* 2021;**14**:e242101. doi:10.1136/bcr-2021-242101

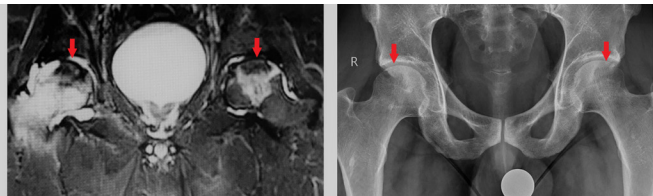


Figure 1 MRI and anteroposterior radiograph of the 36-year-old male patient confirming bilateral avascular necrosis of the femoral head (Ficat-Arlet stage II).

mg–1250 mg). The time duration for the development of AVN post COVID-19 diagnosis in our series was 62 days in the first case, 67 days in the second case and 45 days in the third case, with a mean duration of 58 days (range 45–67 days). All the three patients were started on oral alendronate 70 mg weekly dosages along with intravenous zoledronic acid 5 mg annually.⁸ At the last mean follow-up of 70.7 days (30–84 days), none of the patients required surgery and were comfortable painwise. Mean Visual Analogue Score for pain reduced from 8 (6–9) to 2.7 (1–4) at the mean follow-up of 70.7 days.

DISCUSSION

Corticosteroid use is considered to be one of the most common cause for the development of AVN. The pathogenesis of steroid-induced AVN is not well established, but postulated mechanisms include fat emboli, fat hypertrophy, hypercoagulable condition, vascular endothelial dysfunction and abnormality of the bone marrow stem cell.⁹

There is a lack of consensus about the dosage and duration of steroids required to develop AVN. Some authors have reported that a cumulative dose of 2000 mg prednisone (or its equivalent) was required for AVN development.¹⁰ Some studies have shown that 700 mg is the minimum dose required to develop AVN.¹¹ However, McKee *et al* have shown that in their series of 15 patients who developed AVN, mean steroid dose in prednisone equivalents was 850 mg with a range of 290 mg–3300 mg.¹² The mean dose of prednisolone equivalent steroid taken in our series was 758 mg (range 400–1250 mg).

Controversy exists about the time after the steroid administration to the development of AVN symptoms. In a case report of a 23-year-old male patient who developed shoulder AVN after receiving oral dexamethasone (equivalent to 700 mg of prednisolone), the authors have reported that the patient developed symptoms 2 years after the administration of steroids.¹¹ McKee *et al*, in their study, have reported a mean time of 16.6 months (range 6–33 months) from the administration of corticosteroids to the development of AVN.¹² Literature review shows that the interval between corticosteroid intake and development of symptomatic AVN is usually 6 months to 1 year.^{13 14} The mean time

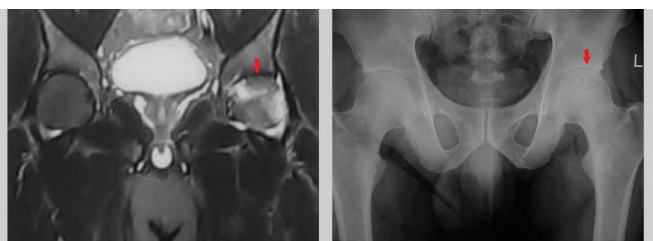


Figure 2 MRI and anteroposterior radiograph of the 39-year-old male patient confirming bilateral avascular necrosis of the femoral head (Ficat-Arlet stage II).

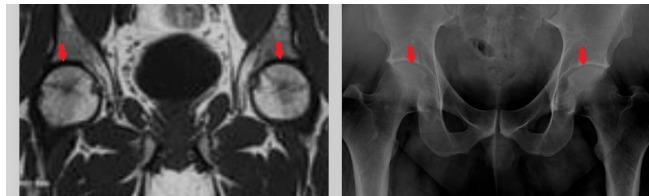


Figure 3 MRI and anteroposterior radiograph of the 37-year-old male patient confirming avascular necrosis of the femoral head of the bilateral hip (Ficat-Arlet stage II).

duration for the development of AVN post COVID-19 diagnosis in our series was 58 days (range 45–67 days).

Treatment objective in AVN is to obtain pain relief, retard disease progression, prevent collapse and restore joint function. Multitude treatment options are available for managing AVN ranging from conservative, medical to surgical modalities, however no standardised protocol exists. Various medical therapies tried in the past including iloprost, nifedipine and hyperbaric oxygen therapy have not shown significant benefits.⁷ Therefore, arthroplasty remains the mainstay of treatment. Although it provides good outcome but when performed at a young age will necessitate at least one revision in the future. Successful use of bisphosphonates for the treatment of AVN in adults was first reported by Agarwala *et al*.⁸ The authors have shown that bisphosphonates not only give good clinical outcome but also retard progression of the disease and the need for a surgery. Subsequently, various authors have published the role of bisphosphonates in management of AVN and it is now considered to be as one of the standard options of treatment of AVN.

In our case series, AVN occurred with a low mean steroid dosage of 758 mg with a minimum dose of 400 mg compared with the literature which shows that a mean cumulative dose of 2000 mg steroid is required for the development of AVN. Further, the patient developed AVN very early with a mean range of 58 days after COVID-19 diagnosis compared with the literature which shows that it generally takes 6 months to 1 year to develop AVN post steroid exposure.

Post COVID-19, there is a greater propensity to develop AVN, mainly if the patient has been on steroids. The literature suggests the mean dose of steroid in prednisone equivalents of 2000 mg is required to cause AVN, but we feel that due to the COVID-19 virus, the sensitivity to develop AVN is higher and to a smaller cumulative dose of steroids.

Steroids are life-saving and have to be administered. However, AVN, being picked up early, may decrease the patient's morbidity by bisphosphonate combination therapy. The most sensitive and least invasive test to diagnose early AVN is an MRI of the hips. Hence, it is recommended that on early suspicion, early MRI should be advised.

Learning points

- ▶ Corticosteroids are life-saving in the management of COVID-19.
- ▶ Patients who had COVID-19 infection are more susceptible to avascular necrosis (AVN) development at (a) lower threshold dose of steroid and (b) earlier onset of presentation.
- ▶ Hence, on early suspicion, on complaints of hip and thigh pain, diagnosis can be established by early MRI of the hips.
- ▶ Patients with early AVN (Ficat-Arlet stages I and II) can be successfully treated with bisphosphonate therapy.

Contributors All authors have equally contributed towards the planning, conduct, reporting, conception and design, acquisition of data or analysis and interpretation of data.

Funding The authors have not declared a specific grant for this research from any funding agency in the public, commercial or not-for-profit sectors.

Competing interests None declared.

Patient consent for publication Obtained.

Provenance and peer review Not commissioned; externally peer reviewed.

REFERENCES

- 1 WHO coronavirus disease (COVID-19) Dashboard.
- 2 Leung TYM, Chan AYL, Chan EW, *et al*. Short- and potential long-term adverse health outcomes of COVID-19: a rapid review. *Emerg Microbes Infect* 2020;9:2190–9.
- 3 Mahase E. Covid-19: What do we know about "long covid"? *BMJ* 2020;370:m2815.
- 4 Ferrari F, Martins VM, Fuchs FD. Renin-Angiotensin-Aldosterone system inhibitors in COVID-19: a review. *Clinics* 2021;9:e2342:76. doi:10.6061/clinics/2021/e2342
- 5 Ip A, Ahn J, Zhou Y, *et al*. Hydroxychloroquine in the treatment of outpatients with mildly symptomatic COVID-19: a multi-center observational study. *BMC Infect Dis* 2021;21:72.
- 6 Powell C, Chang C, Naguwa SM, *et al*. Steroid induced osteonecrosis: an analysis of steroid dosing risk. *Autoimmun Rev* 2010;9:721–43.
- 7 Agarwala S, Shah S, Joshi VR. The use of alendronate in the treatment of avascular necrosis of the femoral head: follow-up to eight years. *J Bone Joint Surg Br* 2009;91:1013–8.
- 8 Agarwala S, Banavali SD, Vijayvargiya M. Bisphosphonate combination therapy in the management of Postchemotherapy avascular necrosis of the femoral head in adolescents and young adults: a retrospective study from India. *J Glob Oncol* 2018;4:1–11.
- 9 Chan KL, Mok CC. Glucocorticoid-Induced avascular bone necrosis: diagnosis and management. *Open Orthop J* 2012;6:449–57.
- 10 Jones JP. Osteonecrosis. In: Koopman WJ, ed. *Arthritis and allied conditions: a textbook of rheumatology*. 14th edn. Philadelphia, Pa: Lippincott Williams & Wilkins, 2001: 2143–64.
- 11 Anderton JM, Helm R. Multiple joint osteonecrosis following short-term steroid therapy. Case report. *J Bone Joint Surg Am* 1982;64:139–41.
- 12 McKee MD, Waddell JP, Kudo PA, *et al*. Osteonecrosis of the femoral head in men following short-course corticosteroid therapy: a report of 15 cases. *CMAJ* 2001;164:205–6.
- 13 Mirzai R, Chang C, Greenspan A, *et al*. The pathogenesis of osteonecrosis and the relationships to corticosteroids. *J Asthma* 1999;36:77–95.
- 14 Assouline-Dayana Y, Chang C, Greenspan A, *et al*. Pathogenesis and natural history of osteonecrosis. *Semin Arthritis Rheum* 2002;32:94–124.

Copyright 2021 BMJ Publishing Group. All rights reserved. For permission to reuse any of this content visit <https://www.bmj.com/company/products-services/rights-and-licensing/permissions/>
BMJ Case Report Fellows may re-use this article for personal use and teaching without any further permission.

Become a Fellow of BMJ Case Reports today and you can:

- ▶ Submit as many cases as you like
- ▶ Enjoy fast sympathetic peer review and rapid publication of accepted articles
- ▶ Access all the published articles
- ▶ Re-use any of the published material for personal use and teaching without further permission

Customer Service

If you have any further queries about your subscription, please contact our customer services team on +44 (0) 207111 1105 or via email at support@bmj.com.

Visit casereports.bmj.com for more articles like this and to become a Fellow