

Role of steroidal anti-inflammatory agent prior to intracorporeal lithotripsy under local anesthesia for ureterovesical junction calculus: A prospective randomized controlled study

Bijit Lodh, Kaku Akoijam Singh, Rajendra Singh Sinam

Department of Urology, Regional Institute of Medical Sciences, Imphal, Manipur, India

Abstract

Objective: The objective of the following study is to assess the effect of steroidal anti-inflammatory agent on the outcome of ureterorenoscopic lithotripsy (URSL) for ureterovesical junction (UVJ) calculus.

Settings and Design: This was a prospective randomized controlled study conducted at the Department of Urology, Regional Institute of Medical Sciences, Imphal.

Subjects and Methods: One hundred and twenty-six patients requiring ureteroscopic lithotripsy for UVJ calculus were randomly assigned into two groups. The study group received tablet deflazacort 30 mg once a day for 10 days prior to the procedure, whereas the control group did not receive such treatment. Parameters with respect to the outcome of the procedure were recorded for all patients in both groups.

Statistical Analysis Used: Fisher's exact and independent *t*-test was used to compare the outcome between the groups where $P < 0.05$ was considered to be statistically significant.

Results: There was significant statistical difference ($P = 0.016$) on the endoscopic appearance of the region of ureteric orifice in patients receiving steroidal anti-inflammatory agent compared with control. Severe procedure related pain and mean operative time was less in the study group compared to control ($P = 0.020$ and 0.031 , respectively). Re-treatment rates in the study group were lower than the control group (4.76% vs. 17.46%) and found to be statistically significant ($P = 0.044$). It is found that computed tomography (CT) appearance ($r = 0.399$) and stone size ($r = 0.410$) strongly correlate with the endoscopic findings of the region of UVJ ($P = 0.001$).

Conclusions: Inflamed and or obliterated ureteric orifice is the major constraints for stone clearance at ureterovesical junction. The present study showed the administration of tablet deflazacort (a steroidal anti-inflammatory agent) significantly improves the outcome of URSL under local anesthesia. We strongly recommend its use prior to URSL for UVJ calculus, especially for stone size ≥ 10.24 mm and on CT evidence of prominent soft tissue swelling at the UVJ.

Key Words: Deflazacort, ureterorenoscopic lithotripsy, ureterovesical junction

Address for correspondence:

Dr. Bijit Lodh, Department of Urology, Regional Institute of Medical Sciences, Lamphelpat, Imphal - 795 004, Manipur, India. E-mail: drblodh@yahoo.co.in

Received: 02.08.2013, Accepted: 01.03.2014

Access this article online	
Quick Response Code:	Website: www.urologyannals.com
	DOI: 10.4103/0974-7796.150477

INTRODUCTION

Ureterovesical junction (UVJ) is the narrowest part of the human ureter that provides a gateway for stone lodgment and impaction. According to Peremans,^[1] three zones can be distinguished in the ureterovesical junction namely the extravascular ureter at ureteral hiatus, intramural and submucosal

part of the intravesical ureter [Figure 1]. Not surprisingly, in the era of minimally invasive surgery where ureteroscopic retrieval is the mainstay of treatment for lower ureteric calculus, difficulties are faced in dealing with UVJ calculus. This is largely because of complete or partial obliteration of the ureteric orifice following severe inflammation secondary to a calculus. Again, ongoing inflammation has been linked with an infection that perpetuate as a vicious cycle. Thus, it is not uncommon to view an obscure ureteric orifice during endoscopy in patients with radiological evidence of UVJ calculus [Figure 2]. In difficult cases, an exit strategy that allows return at a later date is the most appropriate decision from surgeons' standpoint, but it is associated with poor patient compliance and overall increase in operating cost. There are no well-established pre-operative factors that can predict the success of stone clearance at ureterovesical junction. Therefore, our study was aimed to determine the role of steroidal anti-inflammatory agent on the outcome of ureteroscopic lithotripsy under local anesthesia for UVJ calculus and if so which subset of patients are likely to be benefited.

SUBJECTS AND METHODS

Study design

This was a prospective randomized controlled study, conducted at Urology Department, Regional Institute of Medical Sciences from August 2011 to June 2013. Ethical approval was obtained from the Research and Ethics Committee of the Institute.

Inclusion and exclusion criteria

A total number of 126 patients with ureterovesical junction calculus requiring ureteroscopic lithotripsy under local anesthesia were included in this study. Informed written consent was taken and occurrence of minor procedure related pain was explained to all participants. Exclusion criteria were: patients younger than 18 years, stone size ≤ 10 mm

except those with failed medical expulsion therapy (MET), presence of symptomatic bacteriuria, history of urinary tract reconstruction, bleeding diathesis, patient's unwillingness, orthopedic or spinal deformity that restricts proper positioning, severely comorbid patients. We routinely practice MET for stones ≤ 10 mm where an alpha blocker (tamsulosin 0.4 mg) is administered for duration of 30 days.

Perioperative details

Patients with initial sonographic or radiological evidence of UVJ calculus were subjected to nonenhanced computed tomography (CT) kidneys, ureters and bladder (KUB) for further confirmation of the stone location and its size. A single radiologist has evaluated the CT findings. All eligible patients were randomly assigned into two groups, each consisting of 63 patients. Study group received an anti-inflammatory molecule (tablet deflazacort 30 mg) daily for 10 days prior to the procedure, whereas the control group did not receive such treatment. Both groups of patients were allowed to use tablet drotaverine 80 mg on demand. All patients received injection diclofenac sodium 75 mg and injection netilmicin 300 mg half-an-hour prior to the procedure. Pre-operative topical urethral anesthesia was achieved with 2% lignocaine hydrochloride gel. We have used an 8 Fr. 6° and 43 cm Karl Storz semi-rigid ureterorenoscope (URS) and Storz Calculusplit Intracorporeal pneumatic lithotripter for disintegration of stones. We have kept a safety guide wire during the procedure, except those cases where it was not possible to maneuver through the UVJ. Double J stents were inserted in a liberal manner. Post-operatively, all patients received alpha blockers (tablet tamsulosin 0.4 mg) for 14 days, antibiotics (tablet levofloxacin 500 mg) once a day for 3-5 days and tablet diclofenac 50 mg on demand. In general, patients were followed with digital X-ray KUB after 2 weeks for assessment of stone clearance and subsequent stent removal. Retreatment was considered for patients with failed procedure or incomplete clearance.

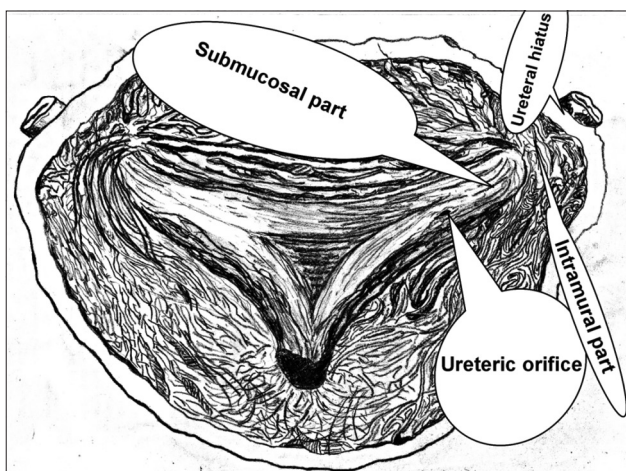


Figure 1: Pictorial presentation of uretero vesical junction anatomy

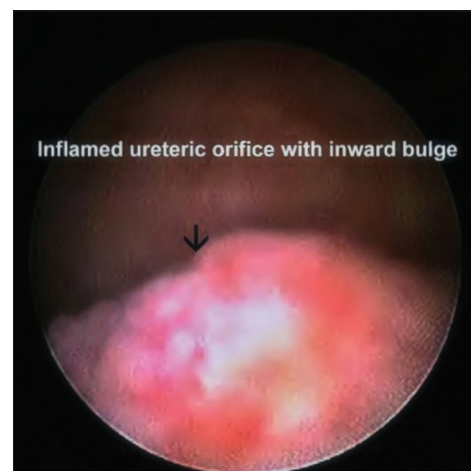


Figure 2: Intensely inflamed ureteric orifice on endoscopy

Data collection and statistical analysis

Pre-procedural, intra-procedural, and post-procedural parameters with respect to the outcome of stone clearance at UVJ were recorded for all patients in both groups. Statistical analyses were performed using the Statistical Package for the Social Sciences (SPSS 16.0) for windows. Fisher's exact and independent *t*-test was used to compare differences between the two groups where $P < 0.05$ was considered as statistically significant. The Revised Clavien-Dindo Classification System was adopted to categorize surgical complications. In view to identify which subset of patients are likely to be benefited from pharmacotherapy, the correlation between endoscopic characteristics of ureteric orifice and pre-procedural parameters in the control group was carried out by Pearson's rank correlation coefficient. Receiver operating characteristics curve was constructed using cut-off values of any identifiable correlating factor.

RESULTS

Pre-procedural characteristics of patients in both groups are shown in Table 1. There were no significant pre-treatment group differences in the CT appearance of the region of ureteric orifice ($P = 0.789$). Although, the number of patients with multiple calculi was more in the study group compared to control (25.40% vs. 11.11%), but it was not statistically significant ($P = 0.063$). Table 2 shows the intra-procedural parameters in both groups. Intra-operatively, patients with inflamed and or obliterated ureteric orifice were higher in the control group ($P = 0.016$). An exit strategy was considered in 7.94% of cases in the control group for failing negotiation of URS, but found to be not statistically significant ($P = 0.057$). Severe procedure related pain and mean operative time was less in the study group compared to control ($P = 0.020$ and 0.031 , respectively). Post-operative

Table 1: Pre-procedural parameters

Parameters	Number of patients (%) (N-63)		P value
	Study group	Control group	
Sex (%)			
Male	39 (61.90)	32 (50.80)	0.281
Female	24 (38.10)	31 (49.20)	
Age (years)	34.96±11.47	36.22±10.57	0.493
Mean±SD (range)	(19-65)	(21-61)	
CT appearance of the region of ureteric orifice (%)			
Absence of soft tissue prominence	56 (88.89)	54 (85.71)	0.789
Presence of soft tissue prominence	7 (11.11)	9 (14.29)	
Number of stones (%)			
Solitary	47 (74.60)	56 (88.89)	0.063
Multiple	16 (25.40)	7 (11.11)	
Stone size (mm)	9.73±1.27	9.98±1.16	0.274
Mean±SD (range)	(7.12-13.50)	(7.70-14.20)	

CT: Computed tomography, N: Number

characteristics are shown in Table 3. Stone free rate in the study group was higher than the control group (95.24% vs. 82.54%) and found to be statistically significant ($P = 0.044$). According to the Revised Clavien-Dindo classification, there were grade I and II complications in 17 patients (26.98%) and 12 (19.04%) patients among the study group, whereas 10 patients (15.87%), 15 patients (23.81%) and I patients (1.59%) in the control group had grade I, grade II, and grade IIIa complications respectively. However, none of them developed grades IV and V complications. Table 4 shows the correlation between pre-operative parameters and endoscopic characteristics of

Table 2: Intra-procedural parameters

Parameters	Number of patients (%) (N-63)		P value
	Study group	Control group	
Endoscopic characteristics of ureteric orifice (%)			
Normal in appearance	61 (96.83)	52 (82.54)	0.016
Inflamed and or obliterated	2 (3.17)	11 (17.46)	
Negotiation of URS through the ureteric orifice (%)			
Successful	63 (100.00)	58 (92.06)	0.057
Unsuccessful	0 (0.00)	5 (7.94)	
Procedure related pain (%)			
Mild-moderate pain (VAS score 0-7)	59 (93.65)	49 (77.78)	0.020
Severe pain (VAS score 8-10)	4 (6.35)	14 (22.22)	
Operative time	30.80±7.85	38.79±13.50	0.031
Mean±SD (range)	(15-47)	(17-85)	
Peroperative complications (Ureteric and trigonal false passage) (%)	4 (6.35)	8 (12.69)	

URS: Ureterorenoscope, VAS: Visual analogue scale, N: Number

Table 3: Post-procedural parameters

Parameters	Number of patients (%) (N-63)		P value
	Study group	Control group	
Stone status			
Stone-free rate	60 (95.24)	52 (82.54)	0.044
Retreatment rate	3 (4.76)	11 (17.46)	
Incidence of gross haematuria (hours)			
For<24	29 (46.03)	20 (31.75)	0.029
For>24	5 (7.94)	13 (20.63)	
Patients requiring hospital stay	2 (3.18)	5 (7.94)	
Patients requiring PUC	6 (11.11)	4 (6.35)	
Incidence of symptomatic bacteriuria	4 (6.35)	3 (4.76)	

DJ: Double J stent, PUC: Per urethral catheterization, N: Number

Table 4: Correlation between endoscopic characteristics of ureteric orifice and pre-procedural parameters in control group

Parameters	Correlation coefficient (r)	P value
Sex	0.124	0.333
Age	0.060	0.643
CT appearance	0.399	0.001
Number of stones	0.011	0.929
Stone size	0.410	0.001

CT: Computed tomography

ureteric orifice. We found that CT appearance ($r = 0.399$) and stone size ($r = 0.410$) strongly correlate with the endoscopic findings ($P = 0.001$). A cut-off value of 10.24 mm for UVJ calculus showed sensitivity and specificity of 66.70% and 80.40%, respectively for prediction of inflamed and or obliterated ureteric orifice [Figure 3].

DISCUSSION

The incidence of urolithiasis in Manipur (a north east state of India) is alarmingly high as observed by Singh *et al.*^[2] and Marak *et al.*^[3] Therefore, it is not uncommon for us to evident a ureteric and UVJ calculus undergoing ureterorenoscopic lithotripsy (URSL) under local anesthesia. However, occasionally we face difficulties, while dealing UVJ calculus and it is mostly due to inflamed and or obliterated ureteric orifice that resulted in an adverse outcome. In such situation, negotiation of URS through the ureteric orifice is the key predictor of outcome of URSL with respect to UVJ calculus. We prefer to use hydrophilic guidewire 0.035 inches during ureteroscopy. Guidewire access is of paramount importance during difficult cases because it enables the surgeon to negotiate a troublesome spot either to find back the ureter and continue with the ureteroscopy or to deploy a stent and return at a later date.^[4] However not surprisingly due to intense inflammation at UVJ secondary to calculus, it is often impossible to access the ureter even with guide wire. Our study was aimed to identify effects of pharmacotherapy on forthcoming events related to URSL for UVJ calculus. In the present study, we have used tablet deflazacort (a glucocorticoid) because of its faster and potent anti-inflammatory effect that is achieved at a low dose compared to nonsteroidal anti-inflammatory drugs. We have avoided the pre-operative use of Diclofenac except for analgesia single shot half-an-hour prior to the procedure, to prevent potential bias that may arise due to its anti-inflammatory effect. Investigators have shown that larger

stones tend to cause more intense inflammatory reactions leading to edema.^[5] Corticosteroids stabilize neutrophil lysosomes, therefore, decreasing inflammation and edema related to mechanical irritation.^[6,7] Here, we have administered 30 mg of deflazacort for 10 days. The majority of the authors recommended not to use for more than 10 days to prevent the side effects of prolonged use.^[5,8-10] In our clinical practice, we are not routinely using deflazacort for MET because of its high cost and also as it limit the duration of MET. In the present study, we observed that the inflamed ureteric orifice appears as prominent soft tissue swelling on CT scan [Figure 4]. Normally there is slight or absent soft tissue prominence at this region. As a result, a stone impacted at the UVJ might be expected to be displaced slightly anteriorly from the posterior bladder wall on axial CT images.^[11] Mean operative time of patients in the study group was lower than controlled and it was found to be statistically significant ($P = 0.031$). We also noticed a high incidence (12.69%) of ureteric and trigonal false passage in the controlled group. False passage mostly developed, while entering through inflamed ureteric orifice and may necessitating termination of the procedure.^[12] Al-Awadi *et al.*,^[13] in their series of iatrogenic ureteric injury following URSL, documented 15 false passages (18.3%), making it one of the most common complications in their series. Statistically significant re-treatment rate in the control group was because of higher incidence of failed URS negotiation accompanied with severe procedure related pain and poor field visibility secondary to repeated trauma to the inflamed UVJ area. This was there as on why 20.63% of patients in the control group had gross hematuria for more than 24 h and it was found to be significant ($P = 0.029$) compared to study group. In our study, hospital stay was mostly due to severe procedure related pain and gross hematuria. One patient in the control group developed clot retention and was managed with clot evacuation and irrigation. No higher incidence of symptomatic bacteriuria was noticed in the controlled group. We found that pre-operative identification of prominent soft tissue swelling in the region of UVJ strongly correlate with

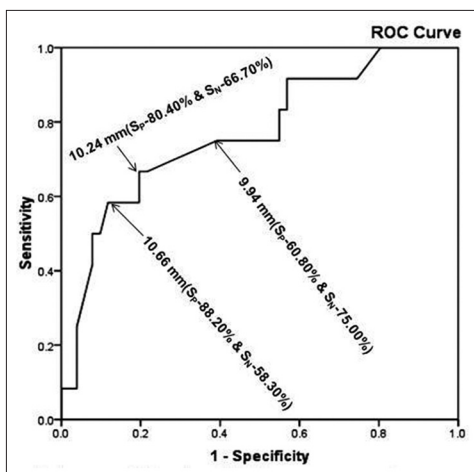


Figure 3: Receiver operating characteristics curve constructed using cut off values for stone size

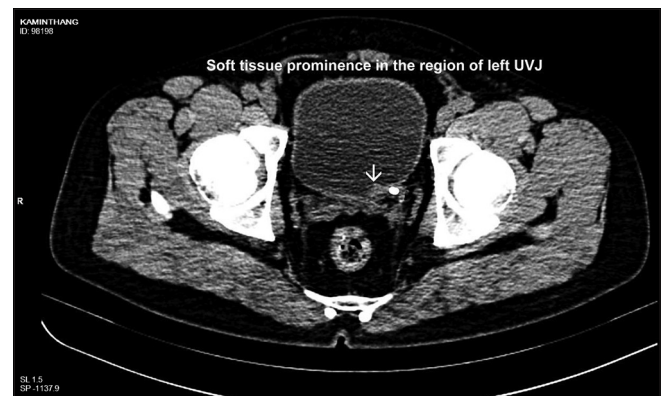


Figure 4: Nonenhance computed tomography scans showing soft tissue eprominence in the region of left uretero vesical junction

the intra-operative findings. We also observed that stone size significantly correlate with the endoscopic appearance of inflamed and or obliterated ureteric orifice. A cut-off value of 10.24 mm showed sensitivity and specificity of 66.70% and 80.40%, respectively for prediction of inflamed and or obliterated ureteric orifice. The CONSORT diagram of the present study is depicted in Figure 5.

CONCLUSION

Inflamed and or obliterated ureteric orifice is the major constraints for stone clearance at ureterovesical junction. The present study showed that administration of steroidal anti-inflammatory agent (tablet deflazacort 30 mg) significantly improves the outcome of URSL under local anesthesia. We recommend its use prior to URSL for UVJ calculus especially

for stone size ≥ 10.24 mm and on CT evidence of soft tissue prominence at the UVJ.

REFERENCES

1. Peremans J. Micro-anatomy of the ureterovesical junction in urinary reflux. *Acta Neurol Scand* 1966;42:Suppl 20:53-60.
2. Singh PP, Singh LB, Prasad SN, Singh MG. Urolithiasis in Manipur (north eastern region of India). Incidence and chemical composition of stones. *Am J Clin Nutr* 1978;31:1519-25.
3. Marak A, Shantibala K, Singh TA, Singh RN, Singh LS. Urolithiasis prevalence and related factors in a rural area of Manipur. *Int J Med Sci Public Health* 2013;2:956-9.
4. Delvecchio FC. Access to the ureter: Rigid ureteroscopy. In: Smith AD, editor. *Smith's Text book of Endourology*. 3rd ed. United States: Wiley-Blackwell; 2012. p. 421.
5. Liu M, Henderson SO. Myth: Nephrolithiasis and medical expulsive therapy. *CJEM* 2007;9:463-5.
6. Saita A, Bonaccorsi A, Marchese F, Condorelli SV, Motta M. Our experience with nifedipine and prednisolone as expulsive therapy for ureteral stones. *Urol Int* 2004;72 Suppl 1:43-5.
7. Porpiglia F, Destefanis P, Fiori C, Fontana D. Effectiveness of nifedipine and deflazacort in the management of distal ureter stones. *Urology* 2000;56:579-82.
8. Porpiglia F, Fiori C, Ghignone G, Vaccino D, Billia M, Morra I, et al. A second cycle of tamsulosin in patients with distal ureteric stones: A prospective randomized trial. *BJU Int* 2009;103:1700-3.
9. Porpiglia F, Vaccino D, Billia M, Renard J, Cracco C, Ghignone G, et al. Corticosteroids and tamsulosin in the medical expulsive therapy for symptomatic distal ureter stones: Single drug or association? *Eur Urol* 2006;50:339-44.
10. Lipkin M, Shah O. The use of alpha-blockers for the treatment of nephrolithiasis. *Rev Urol* 2006;8 Suppl 4:S35-42.
11. Smith RC, Levine J, Rosenfeld AT. Advances in emergency radiology II. *Radiol Clin North Am* 1999;37:911-52.
12. Johnson DB, Pearle MS. Complications of ureteroscopy. *Urol Clin North Am* 2004;31:157-71.
13. Al-Awadi K, Kehinde EO, Al-Hunayan A, Al-Khayat A. Iatrogenic ureteric injuries: Incidence, aetiological factors and the effect of early management on subsequent outcome. *Int Urol Nephrol* 2005;37:235-41

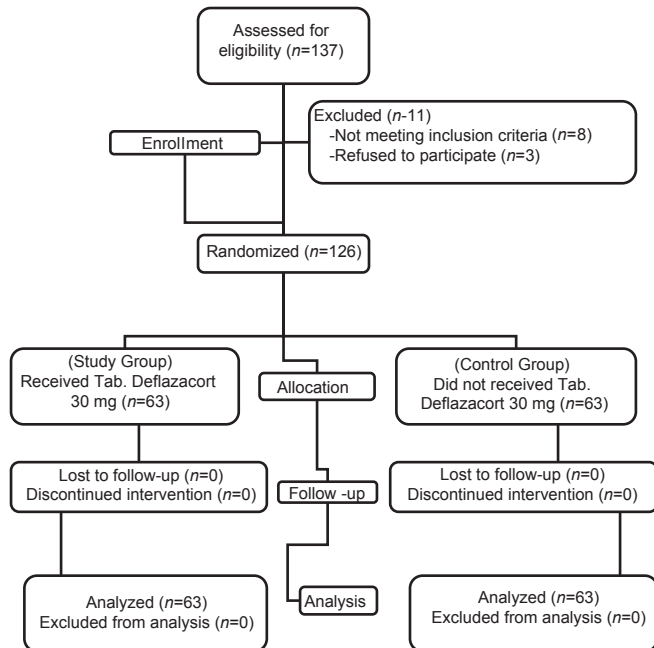


Figure 5: A CONSORT flow diagram depicting patient recruitment and randomization

How to cite this article: Lodh B, Singh KA, Sinam RS. Role of steroidal anti-inflammatory agent prior to intracorporeal lithotripsy under local anesthesia for ureterovesical junction calculus: A prospective randomized controlled study. *Urol Ann* 2015;7:188-92.

Source of Support: Nil, **Conflict of Interest:** None.