

Coexistent anti-GFAP and anti-MOG antibodies presenting with isolated meningitis and papillitis: more support for overlapping pathophysiology

Andrew J Martin , James Strathdee, Nigel Wolfe

To cite: Martin AJ, Strathdee J, Wolfe N. Coexistent anti-GFAP and anti-MOG antibodies presenting with isolated meningitis and papillitis: more support for overlapping pathophysiology. *BMJ Neurology Open* 2022;4:e000236. doi:10.1136/bmjno-2021-000236

Accepted 07 March 2022

ABSTRACT

Background Anti-myelin oligodendrocyte glycoprotein (MOG)-associated disorders are heterogeneous and associated predominantly with central nervous system demyelination. Anti-gliar fibrillar acidic protein (GFAP) conditions are much rarer and involve meningoencephalomyelitis with papillitis in addition to characteristic imaging findings and are generally a severe condition. Multiple autoantibodies can exist in patients and may support overlapping pathophysiological mechanisms. The co-occurrence of MOG and GFAP antibodies, however, is rare, with only two cases previously reported.

Case A 53-year-old man presented with headache and fevers, with quick resolution, though with the later development of asymptomatic papillitis. He had a full recovery without the need for immunotherapy. He underwent extensive investigations and was found to have both anti-GFAP and anti-MOG antibodies in the cerebrospinal fluid. Extensive other immunological and infectious investigations were negative. Imaging was largely unremarkable.

Conclusions This is the third case of overlapping anti-GFAP and anti-MOG antibody-associated syndrome of self-limited lymphocytic meningitis, serving to expand the phenotype. Clinicians should consider testing for GFAP and MOG antibodies in otherwise unexplained meningitis, particularly with associated papillitis. This case may also help provide future insights into the pathophysiology of each condition.

INTRODUCTION

Autoimmune glial fibrillar acidic protein (GFAP) astrocytopathy is a recently described autoimmune disorder characterised by a severe meningoencephalomyelitis associated with papillitis and which tends to follow a relapsing course. Anti-myelin oligodendrocyte glycoprotein (MOG) antibody-associated diseases are a heterogeneous group of conditions associated predominantly with central nervous system (CNS) demyelination. The coexistence of anti-GFAP and anti-MOG antibodies is extremely rare, with only two cases previously reported. We present here a patient who presented initially with isolated

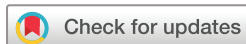meningitis, only later developing asymptomatic papillitis and following a benign course without a need for immunotherapy, and who was found to have both anti-GFAP and MOG antibodies. This may further help illustrate common pathophysiological links between the two conditions.

CASE PRESENTATION

A 53-year-old man presented with a 1-week history of headaches, new-onset insomnia, anxiety and fevers but without other neurological or systemic symptoms. There was no infectious prodrome or medical history of note. Initial neurological examination, including funduscopy, was normal. Cerebrospinal fluid (CSF) analysis showed normal glucose of 2.7 mmol/L, with elevated protein at 1.33 g/L. There were 798 leucocytes, with 776 monocytes and 22 polymorphs. Extensive infectious studies were negative, including PCR and culture of viral, bacterial and mycobacterial organisms. Fevers resolved quickly, though headaches continued for some weeks.

Repeat CSF was done on several occasions. Opening pressure was always normal, as was glucose. There was a persistently elevated protein and a reducing mononuclear-predominant pleocytosis. Extensive antibody tests, including anti-NMDA and AQP4, were all negative. CSF oligoclonal bands were positive. Metagenomic next generation sequencing testing for infectious organisms (at UCSF) was negative. Imaging of the brain and spinal cord with contrast on several occasions was unremarkable, though with questionable perivascular radial enhancement. There was no leptomeningeal enhancement (figure 1).

Flow cytometry, however, showed a persistent small monoclonal B cell population (0.3% of lymphocytes), expressing CD19,



© Author(s) (or their employer(s)) 2022. Re-use permitted under CC BY-NC. No commercial re-use. See rights and permissions. Published by BMJ.

Neurology Department, Blacktown Hospital, Blacktown, New South Wales, Australia

Correspondence to

Dr Andrew J Martin; amar6353@alumni.sydney.edu.au

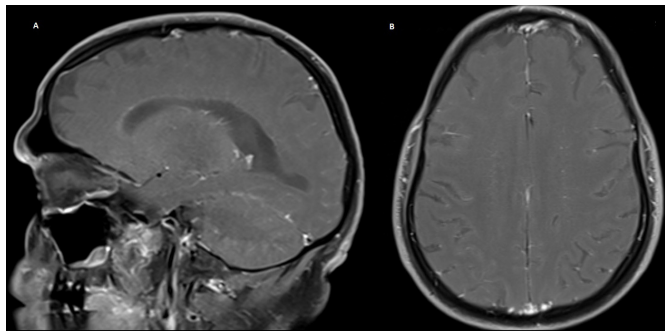


Figure 1 (A) Sagittal post-contrast T1 MRI of the brain after 1 month of illness showing equivocal periventricular radial enhancement. (B) Axial post-contrast T1 MRI of the brain again showing possible periventricular radial enhancement.

CD20 and kappa light chains, though the most recent CSF analysis did not show this and cytology was always normal. Peripheral blood flow cytometry, moreover, was normal. CT imaging of the body was normal. Bone marrow biopsy was not performed. This was thought not to be significant given low number and resolution.

The patient's headaches resolved, although there was some persistent insomnia. An examination 1 month later showed asymptomatic optic disc swelling and haemorrhages. CSF pressure at this time remained normal, as was repeat imaging of the brain and orbits. For this reason, anti-MOG (flow cytometry live cell-based assay, Children's Hospital Westmead, Sydney, Australia) and anti-GFAP antibodies (alpha cell-based assay, Mayo Clinic) were tested and found to be positive in CSF. They were not tested in serum. The titre was not available. The patient had made a full recovery, with resolution of papillitis, and therefore no immunotherapy was commenced. He remains well 5 months later.

DISCUSSION

Anti-GFAP astrocytopathy is a rare condition and most commonly presents with a severe meningoencephalomyelitis with associated characteristic imaging features of perivascular radial enhancement. The course is typically chronic and most require immunotherapy.¹ Anti-MOG-associated disease is more heterogeneous though commonly presents with CNS demyelinating syndromes.

Anti-GFAP or anti-MOG antibodies may coexist with a variety of other antibodies in up to 40% of cases, mostly commonly anti-NMDA and AQP4.^{2–4} A link with diverse cancer types and, more rarely, infections, has also been reported.⁴ There have been only two reports of coexistent anti-GFAP and anti-MOG antibodies, one case also having AQP4 antibodies, and both with a more severe phenotype.^{5,6} MOG is located on the cell surface, while GFAP is in the cytoplasm, and it may be that MOG antibodies may lead to secondary anti-GFAP autoimmunity, though the two diseases may share different pathophysiology.^{1,5} This, however, remains speculative given so few cases described to date. MOG antibodies are recommended to be tested

on serum rather than CSF, as titres in the CSF are generally lower, although the significance if detected in the CSF likely remains the same.⁷

Our patient had a much milder phenotype, with headache and asymptomatic papillitis, but no other deficits. He also had new-onset insomnia and anxiety, as has been reported in GFAP astrocytopathy, and likely to relate to hypothalamic involvement.⁸ Normal brain and spine imaging, as in our patient, is reported in up to one-third of those with GFAP astrocytopathy.¹ Monophasic illness can occur in both, though up to 50% of GFAP astrocytopathy cases may need long-term immunotherapy.¹

Our patient had no clear associated infections or malignancy. There was a small, isolated and transient CSF monoclonal B cell population, the significance of which is unclear, but unlikely to represent a haematological malignancy. The exact role and pathogenicity of the antibodies in this patient is unclear, particularly given the improvement without immunotherapy and the relatively mild clinical picture, though while the phenotype was mild, has features reported in patients with either anti-GFAP or anti-MOG-associated disorder. We cannot completely discount the possibility that the MOG antibodies in particular represent an epiphenomenon, however.

Clinicians should be aware as to the possibility of multiple overlapping antibody-associated conditions, even with a relatively mild phenotype, and should consider testing for such antibodies in otherwise unexplained lymphocytic meningitis, particularly with associated papillitis.

Acknowledgements We wish to thank the patient.

Contributors AJM—study design, collection of data, writing first draft and final version of the manuscript. JS—study design, collection of data, writing first draft and final version of the manuscript. NW—study design, collection of data, writing first draft and final version of the manuscript.

Funding The authors have not declared a specific grant for this research from any funding agency in the public, commercial or not-for-profit sectors.

Competing interests None declared.

Patient consent for publication Obtained.

Ethics approval Not applicable.

Provenance and peer review Not commissioned; externally peer reviewed.

Data availability statement No data are available.

Open access This is an open access article distributed in accordance with the Creative Commons Attribution Non Commercial (CC BY-NC 4.0) license, which permits others to distribute, remix, adapt, build upon this work non-commercially, and license their derivative works on different terms, provided the original work is properly cited, appropriate credit is given, any changes made indicated, and the use is non-commercial. See: <http://creativecommons.org/licenses/by-nc/4.0/>.

ORCID iD

Andrew J Martin <http://orcid.org/0000-0002-9198-7511>

REFERENCES

- 1 Kunchok A, Zekeridou A, McKeon A. Autoimmune glial fibrillary acidic protein astrocytopathy. *Curr Opin Neurol* 2019;32:452–8.
- 2 Liu T, Chen B, Yang H, et al. Screening for autoantibodies in inflammatory neurological syndrome using fluorescence pattern in a tissue-based assay: cerebrospinal fluid findings from 793 patients. *Mult Scler Relat Disord* 2019;28:177–83.

- 3 Titulaer MJ, Höftberger R, Iizuka T, *et al.* Overlapping demyelinating syndromes and anti-N-methyl-D-aspartate receptor encephalitis. *Ann Neurol* 2014;75:411–28.
- 4 Flanagan EP, Hinson SR, Lennon VA, *et al.* Glial fibrillary acidic protein immunoglobulin G as biomarker of autoimmune astrocytopathy: analysis of 102 patients. *Ann Neurol* 2017;81:298–309.
- 5 Ding J, Ren K, Wu J, *et al.* Overlapping syndrome of MOG-IgG-associated disease and autoimmune GFAP astrocytopathy. *J Neurol* 2020;267:2589–93.
- 6 Yang X, Xu H, Ding M, *et al.* Overlapping autoimmune syndromes in patients with glial fibrillary acidic protein antibodies. *Front Neurol* 2018;9:251.
- 7 Jarius S, Ruprecht K, Kleiter I, *et al.* MOG-IgG in NMO and related disorders: a multicenter study of 50 patients. Part 1: frequency, syndrome specificity, influence of disease activity, long-term course, association with AQP4-IgG, and origin. *J Neuroinflammation* 2016;13:279.
- 8 Long Y, Liang J, Xu H, *et al.* Autoimmune glial fibrillary acidic protein astrocytopathy in Chinese patients: a retrospective study. *Eur J Neurol* 2018;25:477–83.