

## Case Report

# High-voltage electrocution-induced pulmonary injury and cerebellar hemorrhage with fractures in atlas

Lutfun Nahar Nizhu<sup>a</sup>, Md Jahidul Hasan<sup>b,\*</sup>, Raihan Rabbani<sup>c</sup>

<sup>a</sup>ICU, Medical Services, Square Hospitals Ltd., Dhaka, Bangladesh

<sup>b</sup>Clinical Pharmacy Services, Department of Pharmacy, Square Hospitals Ltd., Dhaka, Bangladesh

<sup>c</sup>Internal Medicine and ICU, Medical Services, Square Hospitals Ltd., Dhaka, Bangladesh

## ARTICLE INFO

## Keywords:

High-voltage  
Electrocution  
Cerebellar hemorrhage  
Pulmonary injury

## ABSTRACT

**Background:** Electrocution is a common cause of mild to severe multisystem injuries leading to high rate of mortality and morbidity. Low to high-voltage injury may be clinically manifested from a simple unpleasant sensation to multiple soft tissue injury which may cause instant death. The severity of injury depends on intensity of the electrical current, voltage of the source, resistance in the victims' body and the duration of the contact.

**Case presentation:** A 20-year-old young male experienced with an accidental high-voltage electrocution injury from a blasted electrical transformer while passing across the road. He lost his consciousness and immediately hospitalized. Bilateral pulmonary infiltrates and right cerebellar hemorrhage with fractures in anterior and posterior arch of the first cervical vertebrae (C1) were diagnosed, and there was no history of electrical burn. He stayed in hospital for three days and completely treated with initial oxygen supplementation and immobilization of his head and neck with a Philadelphia collar for 6 weeks. Electrocution is a serious public health concern and reported worldwide with few fatal ending. Accidental high-voltage electrocution injury is a serious type of unfortunate accidental injuries which in most of times, ends with immediate or delayed sequelae or even death. In this case, the victim with high-voltage-associated electrical injuries in his lungs and brain was completely recovered because of early hospitalization.

**Conclusions:** Electrocution injury is an accidental event with high mortality and morbidity rate. Mild to severe electrical current-induced injuries including burn can be treated successfully in most of the cases, but early hospitalization is highly required.

## Background

Electrocution is a mechanical trauma and can be defined as death or severe one or more injuries a living organ from an accidental contact with a low to high-voltage electrical source. An accidental electrocution injury may be occurred either with high-voltage (> 1000 V) or with low-voltage (< 1000 V). High-voltage injury is relatively associated with high rate of mortality and morbidity [1]. Electrocution injury may results in mild to severe skin burn, musculoskeletal injury, myoglobinuria, acute renal failure, neuropsychiatric symptoms and ventricular fibrillation [2]. Here, we had a case of high-voltage-associated lung injury and right cerebellar hemorrhage with multiple fractures in the arch of the atlas, and complete recovery in that patient attained without any permanent damage.

\* Corresponding author at: Clinical Pharmacy Services, Department of Pharmacy, Square Hospitals Ltd., 18/F Bir Uttam Qazi Nuruzzaman Sarak, West Panthapath, Dhaka 1205, Bangladesh.

E-mail addresses: [oporajita84@gmail.com](mailto:oporajita84@gmail.com) (L.N. Nizhu), [jahidul@squarehospital.com](mailto:jahidul@squarehospital.com) (M.J. Hasan), [dr Raihan@squarehospital.com](mailto:dr Raihan@squarehospital.com) (R. Rabbani).

<https://doi.org/10.1016/j.tcr.2019.100267>

Accepted 6 November 2019

2352-6440/ © 2019 Published by Elsevier Ltd. This is an open access article under the CC BY-NC-ND license (<http://creativecommons.org/licenses/by-nc-nd/4.0/>).

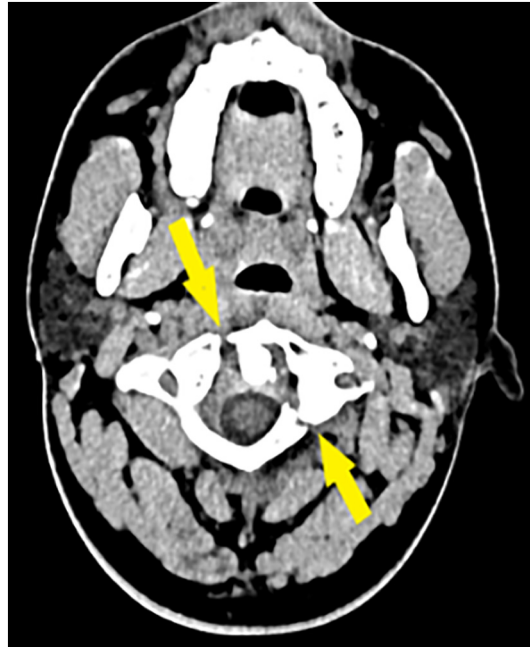


Fig. 1. First vertebral fracture.

### Case presentation

A 20-year-old male came to emergency room of our hospital with a history of an accidental multiorgan electrocution injury while passing across the road. According to the statements of eyewitness, accidentally he was contacted with a blasted high-voltage electrical transformer while he was passing across the road, lost his consciousness, felt on ground and immediately, immediately admitted in hospital. After shifting to ICU, his consciousness returned to normal level, pulse rate was 88 beats/min, blood pressure was 90/60 mmHg, temperature was 99 °F, Glasgow coma scale (GCS) score was E<sub>3</sub> V<sub>5</sub> M<sub>6</sub> and SpO<sub>2</sub> was 94% with 2 L of supplemental oxygen. There was no sign of burn. Entry and exit point of electrocution in the body was absent. He complained his neck pain and his neck movement was restricted in all directions. No focal neurological deficit was found. Computed tomography (CT) scan of cervical vertebrae revealed two fractures (one fracture in the anterior arch and another fracture in the posterior arch) in the arches of atlas also called, first cervical vertebrae (C1) (Fig. 1). CT scan of brain showed right cerebellar hemorrhage (Fig. 2). Immobilization of neck was done with Philadelphia collar. CT scan of chest revealed focal consolidation with pulmonary infiltrates in both lungs (Fig. 3). His troponin I was 1.12 ng/mL and echo cardiogram showed no regional wall motion abnormality and ejection fraction was 55%. After three days of treatment in ICU, his physical conditions improved and discharged to home with Philadelphia collar, and after 6 weeks,

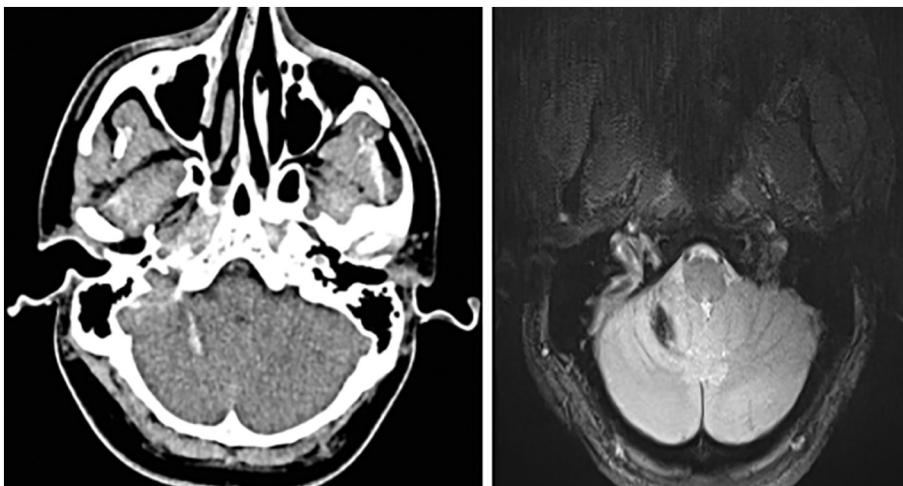


Fig. 2. Right cerebellar hemorrhage.

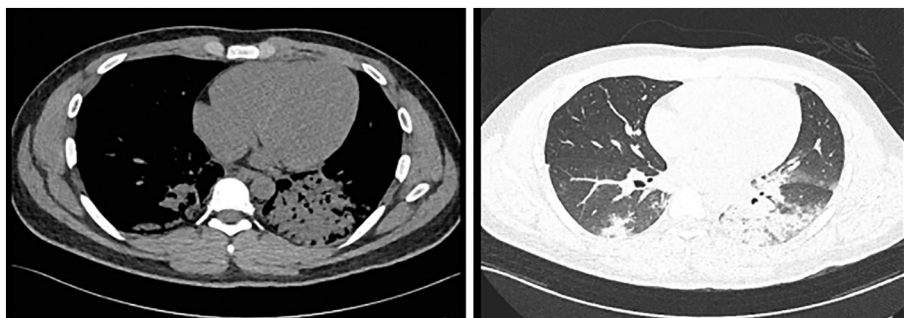


Fig. 3. Chest CT scan demonstrates bilateral pulmonary infiltrates.

his fractures in C1 were completely healed.

### Discussion and conclusions

Electrocution is the electric shock-mediated mild to severe injuries in a living organ and is associated with high rate of mortality and morbidity [1]. The severity of injury depends on intensity of the electrical current determined by the voltage of the source and the resistance in the victim's body; pathway it follows through the victim's body; and duration of the contact with the source of the current [2]. Accidental high-voltage-associated electrocution injuries may result in immediate death mostly due to high-voltage electric shock-induced ventricular fibrillation or acute respiratory arrest as a result of paralysis of the central respiratory control center or fulminant respiratory muscles paralysis [1]. Severe high-voltage-associated electrical injuries include first to third-degree burns, myocardial dysfunctions, brain injury and permanent loss of organ function [1,2]. Electrical energy-induced direct tissue damage, massive tissue destruction or necrosis due to the conversion of electrical energy into thermal energy and mechanical injury as a result of sudden falls or massive muscle contraction- are the basic mechanisms behind the electrocution injuries [2]. In our case, the patient developed focal consolidation in both lungs and two fractures in the arches of C1 vertebrae.

High-voltage electric current-induced bleeding in left parietal area of the cerebrum, acute cardiogenic pulmonary edema, lung tissue injury and burn [1,3–6]. In our case, the patient had bleeding into right cerebellum. Two cases of electrical workers reported focal consolidation with lung infarction due to high-voltage electric current ( $\geq 1000$  V) and underwent surgical resection [4,5]. Focal lung injury was reported in an electrical worker after a low-voltage shock (380 V) complicated by respiratory arrest and subsequent cerebral edema [6]. Multiple previous cases reported electrical burn injury in different parts of the victims caused by direct contact to high-voltage electric current without having any fracture in cervical vertebrae [1,6,7]. In our patient, there was no sign of electrical burn injury found in his body during hospital admission but, couple of fractures in C1 vertebrae were clearly detected which is very rare. Additionally, the patient had focal consolidation in both lungs but, comparatively larger consolidated area was found in the left lung.

Both joule heating and irreversible denaturation of cellular macromolecules are considered as the primary mechanisms of electrical current-induced internal injuries, and force of current causes electroporation throughout the cell that results in disorientation of polar amino acids of the channel proteins which makes the channel proteins dysfunctional as a result of their conformational changes. These cellular mechanisms finally lead to tissue necrosis and injury [8]. The severity of injury is associated with the characteristics of electric current including its magnitude, type, direction, contact interval, resistance of the entrance point and personal susceptibility [5,6,8]. High-voltage-associated severe injuries in most of the cases persisted with permanent damage or even ended in death [3,5]. Immediate hospitalization and treatment initiation after an electrocution injury may reduce the rate of mortality in the victims [6]. In our case, the victim was hospitalized immediately after the accident and cured completely within couple of weeks.

High-voltage electrocution injury is a serious type of accidents with potential risk of multi organ damage and death. Early diagnosis of the related injuries and immediate management enhances the expectancy of complete recovery.

### Funding statement

None of the authors received any specific funding for this work.

### Consent for publication

The patient and his relatives gave written and verbal consent to submission of this case report for publication. Written consent can be presented on request.

## Declaration of competing interest

None of the authors state any conflicts of interest.

## References

- [1] G.A. Axayacalt, C.E. Alejandro, R.A. Marcos, R.F. Inocencio, H.G. Alfredo, Brain hemorrhage after electrical burn injury: case report and probable mechanism, *Surg. Neurol. Int.* 7 (Suppl. 28) (2016) S759–S762.
- [2] R. Teodoreanu, S.A. Popescu, I. Lascar, Electrical injuries. Biological values measurements as a prediction factor of local evolution in electrocutions lesions, *J Med Life* 7 (2) (2014) 226–236.
- [3] R.M. Schein, D.H. Kett, E.J. De Marchena, C.L. Sprung, Pulmonary edema associated with electrical injury, *Chest* 97 (5) (1990) 1248–1250.
- [4] M.A. Cooper, Electrical and lightning injuries, *Emerg. Med. Clin. North Am.* 2 (3) (1984) 489–501.
- [5] M.J. Masanès, E. Gourbière, J. Prudent, N. Lioret, M. Febvre, S. Prévot, B. Lebeau, A high voltage electrical burn of lung parenchyma, *Burns* 26 (7) (2000) 659–663.
- [6] A.R. Schleich, H. Schweiger, A. Becsey, C.W. Cruse, Survival after severe intrathoracic electrical injury, *Burns* 36 (5) (2010) e61–e64.
- [7] T.J. Huei, S.J. Mohd Yussof, H.T.C. Lip, I. Salina, Case report of a high voltage electrical injury and review of the indications for early fasciotomy in limb salvage of an electrically injured limb, *Ann Burns Fire Disasters* 30 (2) (2017) 150–153.
- [8] H. Karamanli, R. Akgedik, Lung damage due to low-voltage electrical injury, *Acta Clin. Belg.* 72 (5) (2017) 349–351.