

Arthroscopic, Needle-Based, Transosseous Rotator Cuff Repair



Ehud Atoun, M.D., Liam T. Kane, B.S., and Joseph A. Abboud, M.D.

Abstract: Although open transosseous repair was historically used as a gold-standard surgical solution for rotator cuff tears, this procedure was largely replaced by anchor-based techniques because of the advancement of arthroscopic surgery. However, the ability of anchor-based repair to achieve similar biomechanical fixation remains uncertain. Despite the proposals of numerous methods over the last decade, there remains demand for a standard, reliable technique that integrates the biomechanical advantages of transosseous fixation within the realm of arthroscopy. We describe a technique for transosseous rotator cuff repair using the Omnicuff, a needle-based transosseous suture-passing device that minimizes the risk of failure of suture passage between the bone tunnels. With potential advantages of this design including automated-assisted suture passage, improved bone-tendon healing, and anchorless fixation, surgeons may be inclined to consider these biomechanical and cost-saving benefits. Future studies are warranted to determine clinical outcomes of this technique and its suitability for tears of varying degrees and patterns.

Rotator cuff injury is a common cause of shoulder pain in people of all age groups, and its prevalence in cadaveric studies ranges from 5% to 40% of the population.¹ In 1944, McLaughlin² was the first to describe a transosseous rotator cuff repair, and this technique was considered the gold standard for repair of rotator cuff lesions until the end of the last century. The transosseous technique provided good clinical and biomechanical results but, for a long time, was feasible only with the open approach and, with the evolution of arthroscopic techniques, was replaced with arthroscopic suture anchor repair³

Suture anchor repair techniques have evolved from single-row to double-row to transosseous-equivalent

repair in an attempt to improve the biomechanical properties of the repair.⁴ Nevertheless, a systematic review of 40 cadaveric studies evaluating the biomechanical properties of rotator cuff repairs in various constructs found no significant differences among single-row anchored, double-row anchored, transosseous equivalent, and transosseous repairs.⁵

Recently, new methods for arthroscopic transosseous repair have been developed.^{6,7} These techniques have been found to offer several potential advantages on anchor repair, including broad footprint coverage with no foreign body at the footprint area, lower risk of rotator cuff failure at the musculotendinous junction (type 2

From the Barzilai Medical Center, Department of Orthopaedic Surgery, Ben Gurion University (E.A.), Beer Sheva, Israel; and the Rothman Orthopaedic Institute, Department of Orthopaedic Surgery, Thomas Jefferson University Hospitals (L.T.K., J.A.A.), Philadelphia, PA

The authors report the following potential conflicts of interest or sources of funding: E.A. is a board member and consultant and receives royalties for Mininvasive Ltd. J.A.A. is a board member and consultant and receives royalties for Mininvasive Ltd. Full ICMJE author disclosure forms are available for this article online, as [supplementary material](#).

Received July 4, 2019; accepted September 2, 2019.

Address correspondence to Joseph A. Abboud, M.D., 925 Chestnut Street, 5th Floor, Philadelphia, PA 19107. E-mail: Joseph.abboud@rothmanortho.com

© 2019 by the Arthroscopy Association of North America. Published by Elsevier. This is an open access article under the CC BY-NC-ND license (<http://creativecommons.org/licenses/by-nc-nd/4.0/>).

2212-6287/19849

<https://doi.org/10.1016/j.eats.2019.09.004>

Table 1. Pearls and Pitfalls

Pearls

The lateral portal should be placed 4 cm inferior to the lateral aspect of the acromion, 1-2 cm inferior to the commonly used lateral portal. Perform adequate bursal debridement lateral to the greater tuberosity to allow visualization of the lateral cortex entry point.

Externally and internally rotate the arm in order to allow adequate space between bone tunnels.

Attach the sutures exiting the lateral cortex to the drapes to avoid suture unloading from tunnel during suture passage.

Pitfalls

Make sure the edge of the needle is in the prepunctured hole while drilling the lateral tunnel.

In case of severely osteoporotic bone, it is recommended to use suture tapes.

Use different color sutures to ease suture management.

If performing an X-box configuration, part of the knots can be made extra-articularly.

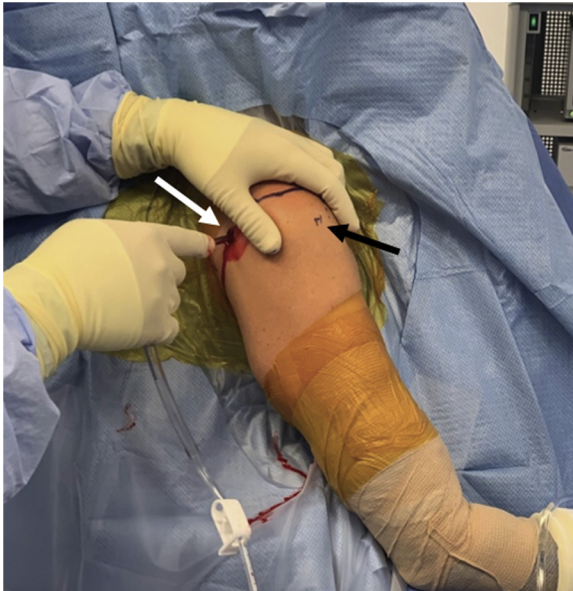

Fig 1. Clinical image of a right shoulder fully prepared and draped for an arthroscopic procedure. Patient is seated in a beach-chair position, and the shoulder is marked appropriately. The surgeon is creating a standard posterior viewing portal (*white arrow*), and a lower lateral portal for the use of the omnicroff is marked (*black arrow*).

failure),⁵ lower risk of type III Sugaya magnetic resonance imaging readings (insufficient thickness after repair),⁸ improved blood flow at the bone-tendon interface,⁹ and decreased pain with similar functional outcomes.¹⁰

Because arthroscopic transosseous technique usually requires manual passage of suture through intersecting bone tunnels, it can be more technically challenging than anchor-based repair.¹¹ We describe a technique for transosseous rotator cuff repair using the Omnicuff (Minvasive Ltd., Magal, Israel), a needle-based transosseous suture-passing device that minimizes the risk of failure of suture passage between the bone tunnels (*Table 1*).

Surgical Technique

The procedure can be performed with patients in both beach chair and lateral decubitus positions. A standard

diagnostic arthroscopy of the glenohumeral joint is performed by use of a posterior viewing portal and an anterior portal through the rotator cuff interval lateral to the coracoid process. Once all glenohumeral joint pathology is evaluated and addressed, the arthroscope is introduced into the subacromial space. A 6-mm-long lateral portal is placed 4 cm inferior to the lateral aspect of the acromion, 1-2 cm inferior to the commonly used lateral portal (*Fig 1*). A thorough debridement of the subacromial bursa is performed. Subacromial decompression and lateral clavicular excision are performed if there is a clinical indication or intraoperative signs of impingement. The rotator cuff tear is identified, and soft tissue release is carried out as necessary for tissue mobilization. The rotator cuff footprint is then debrided.

At this stage the surgeon decides whether to use 1, 2, or 3 tunnels to repair the cuff according to the tear size and pattern. An accessory lateral portal is created off the anterolateral edge of the acromion, through which a dedicated punch is introduced to the shoulder, and the entry point of the transosseous tunnel location is marked on the medial aspect of the footprint. To create a pilot hole, use a mallet to tap the punch through the bone surface to the laser line on the punch (*Fig 2*). A drill bit adapter is attached to a surgical power drill, locking the adapter within the drill chuck. A drill bit is introduced into the working channel port in the Omnicuff device until a palpable indication of drill bit retention is felt.

The Omnicuff device is introduced through the lateral portal and approximated to the lateral cortex of the superior aspect of the greater tuberosity (*Video 1*). The lever of the device handle is squeezed twice to expose 6 mm of the needle from within the shaft. The exposed needle is introduced into the pilot hole, and the handle is lowered until the curved aspect of the shaft is nestled against the lateral cortex of the greater tuberosity. At this stage abduction and internal or external rotation might be needed to optimize the approximation of the device to the bone (*Fig 3*).

While maintaining the needle in the pilot hole, a lateral bone tunnel is created using a surgical power drill by advancing the drill bit through the device. The drill bit is retracted from within the handle leaving a

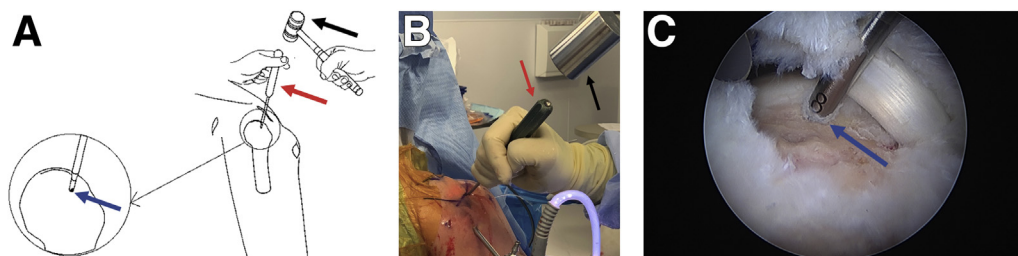


Fig 2. Diagram (A), clinical image (B), and intra-articular image viewed through a posterior portal (C) of a right shoulder of patient in beach chair position. The figure shows a mallet (*black arrow*) being applied to tap a punch tool (*red arrow*) through the bone surface to create a pilot hole (*blue arrow*).

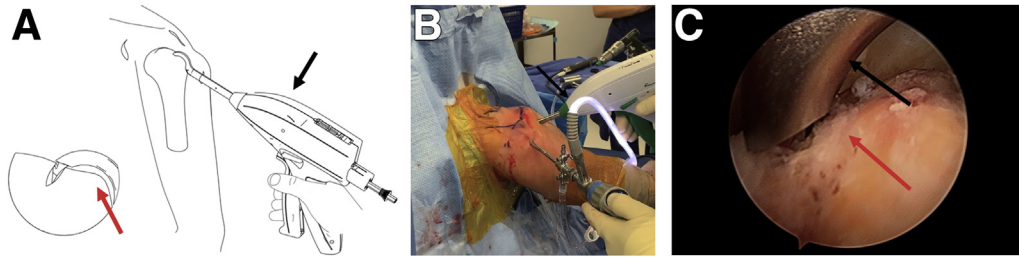


Fig 3. Diagram (A), clinical image (B) and intra-articular image viewed through a posterior portal (C) of a right shoulder of patient in a beach chair position. The Omnicuff device (*black arrow*) is introduced through the lateral portal and approximated to the lateral cortex of the superior aspect of the greater tuberosity (*red arrow*) following shoulder manipulation.

metal sleeve in the bone that creates a stable construct that prevents movements that might cause mismatch of the tunnels and failure of suture passing. A dedicated cartridge with a protected nitinol loop at its tip is introduced through the working channel (Fig 4).

The lever is slowly and repeatedly squeezed until the state Indicator on the top of the device's handle reaches its forward-most mark and the cartridge releases. When the cartridge releases, the nitinol wire at the end of the cartridge has been caught by the needle (Fig 5).

The handle's direction is switched to the "down" position, and the lever arm is slowly and repeatedly squeezed until the state indicator on the top of the handle returns all the way to its initial position. The device is then withdrawn from the shoulder, leaving a nitinol wire loop that passed through the bone tunnel (Fig 6) that is used to shuttle up to five no. 2 sutures or three no. 2 suture tapes (Fig 7). Additional tunnels can be created in a similar fashion at this stage according to clinical need.

Sutures from the medial aspect of the tunnel are now passed through the cuff with dedicated devices (Figs 8 and 9) before tying the sutures to approximate the

tendon to bone (Fig 10). The rotator cuff repair can be completed in various configurations (Fig 11), according to the tear pattern, size, and surgeon's preference.

Discussion

We present a technique for transosseous arthroscopic rotator cuff repair using the Omnicuff, a device that

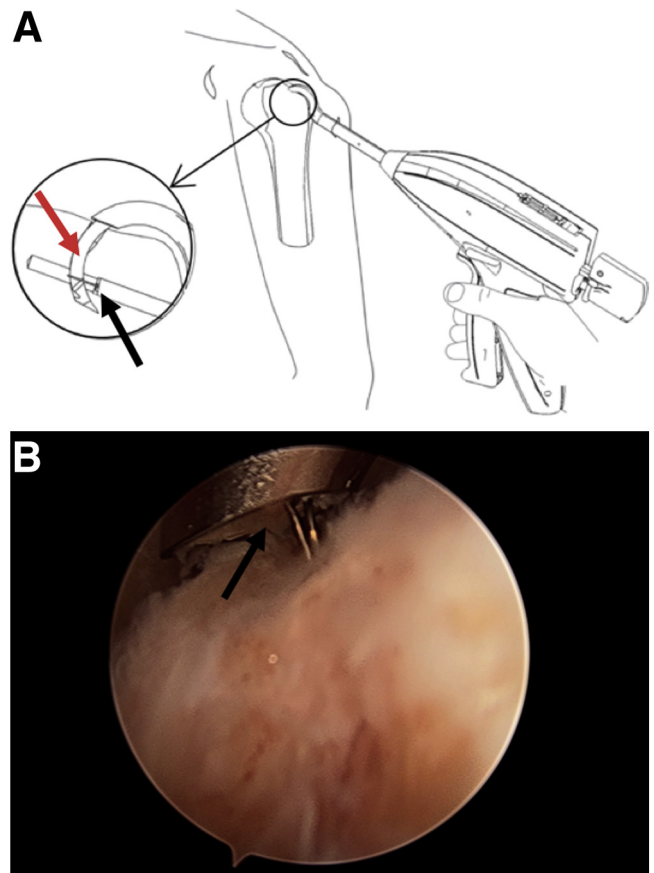


Fig 5. Diagram (A) and intra-articular image viewed through a posterior portal (B) of a right shoulder of a patient in beach chair position. The images show the nitinol wire (*black arrow*) at the end of the cartridge being caught by the needle (*red arrow*) in preparation of being pulled all the way through the bone tunnel and out through the anterior portal.

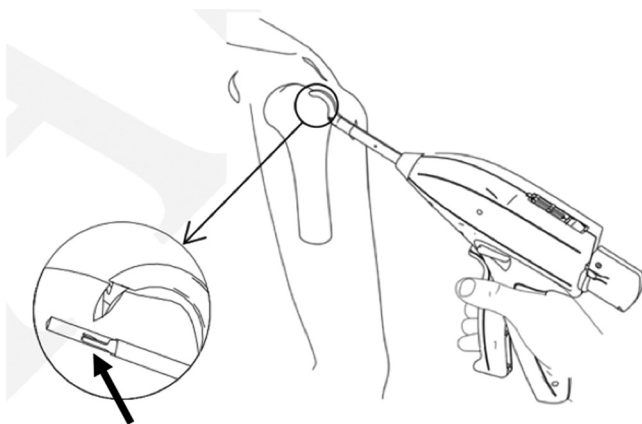


Fig 4. Diagram a right shoulder of a patient in a beach chair position, showing nitinol loop at its tip (*black arrow*) as it is introduced through the working channel (i.e. lateral tunnel) that was created using a surgical power drill advanced through Omnicuff.

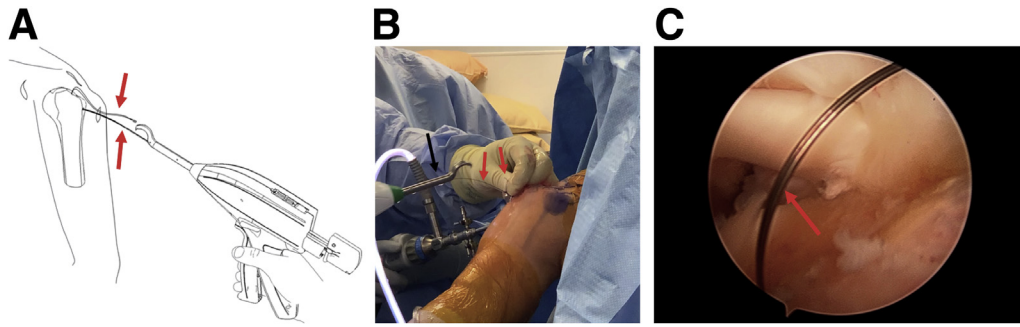


Fig 6. Diagram (A), clinical image (B), and intra-articular image viewed through a posterior portal (C) of a right shoulder of patient in a beach chair position. The Omnicuff device is being withdrawn from the shoulder leaving a nitinol wire loop (red arrows) that passed through the bone tunnel, with one end exiting the lateral portal and the other end exiting the anterior portal, now both accessible by hand once the Omnicuff has been removed.

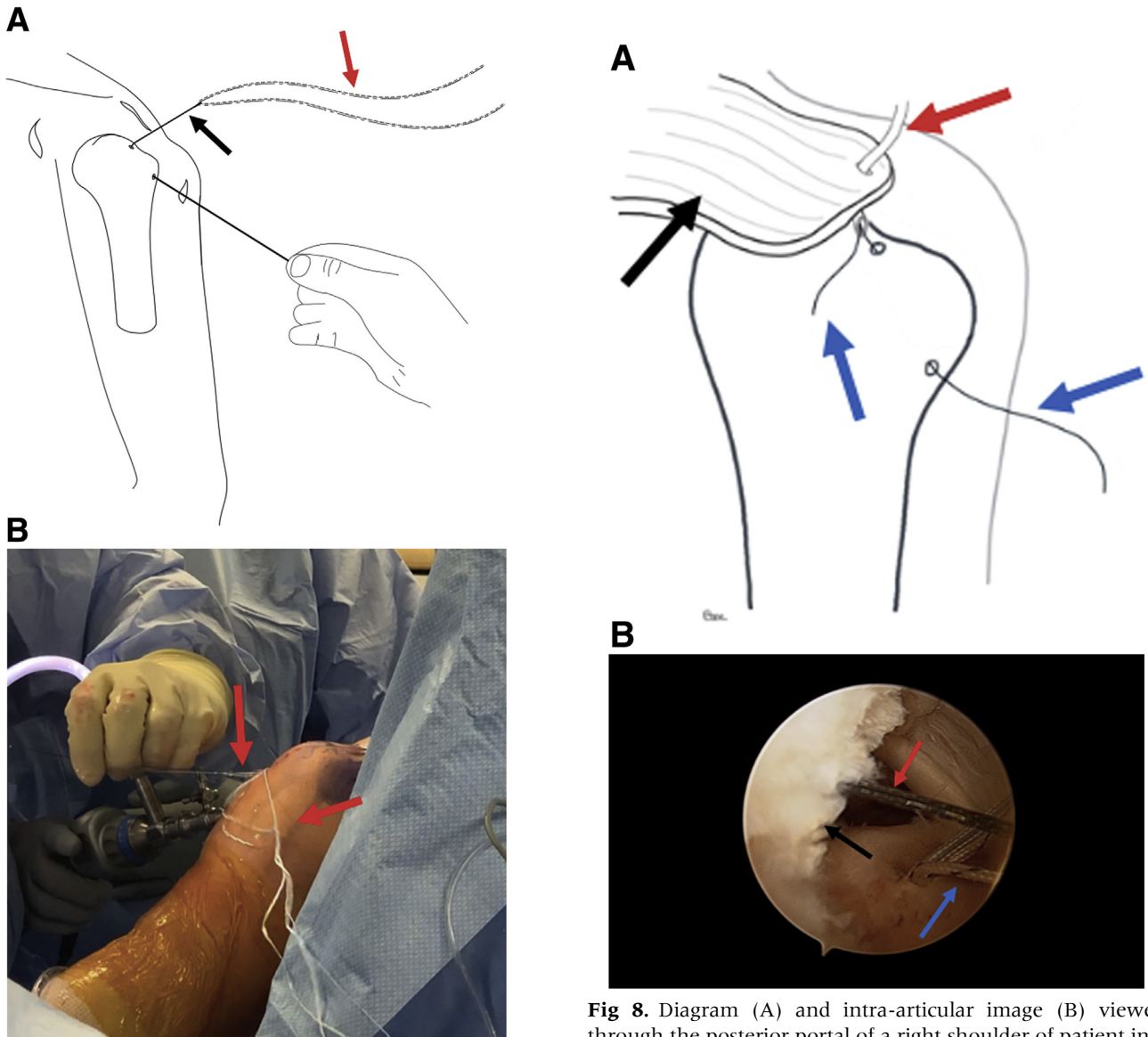


Fig 7. Diagram (A) and clinical image (B) of a right shoulder of patient in a beach chair position. The diagram shows sutures (red arrows) passed through the wire loop (black arrow) in preparation to be passed through the bone tunnels, and the clinical image shows the sutures being passed through the bone tunnels by pulling the nitinol wire loop.

Fig 8. Diagram (A) and intra-articular image (B) viewed through the posterior portal of a right shoulder of patient in a beach chair position. The diagram illustrates a transtendinous needle (red arrow) inserted through the rotator cuff (black arrow) to pass the suture (blue arrows) through the tendon. The arthroscopic image shows a lasso-loop (red arrow) inserted through the tendon to retrieve the suture. Either technique may be used for this procedure.

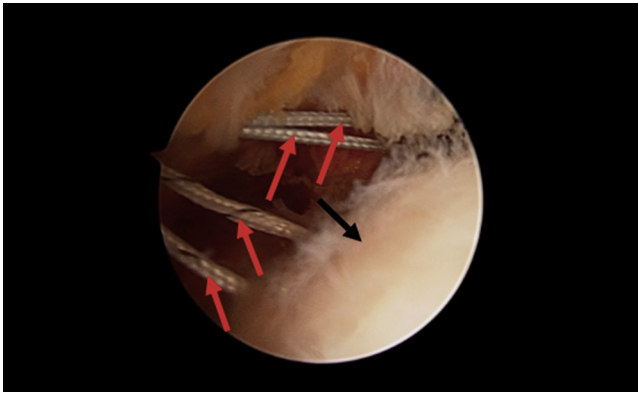


Fig 9. Intra-articular image viewed through the posterior portal of a right shoulder of patient in a beach chair position. The image shows all strands of suture (*red arrows*) that have been passed through the rotator cuff (*black arrow*) exiting through the secondary portal in preparation for suture tying.

uses a needle-retrieved wire loop to provide the surgeon with a more-efficient suture-passing method to set up the transosseous fixation. Although historically the gold standard for rotator cuff repair was performed as an open procedure with transosseous fixation by use of a needle or other curved device to pass the suture through the bone, anchor-based repair (i.e. single-row and double-row) grew in popularity with the expansion of arthroscopy. However, despite decades of strong clinical outcomes and a reproducible technique, anchor-based repair may still be limited in comparison to transosseous fixation. Biomechanical studies have demonstrated that arthroscopically placed anchors may be unable to replicate the same repair site integrity as the transosseous repair,^{4,5,9} and Randelli et al.¹⁰ showed in a prospective fashion that arthroscopic transosseous repair resulted in decreased postoperative pain. As a result, there is demand for standard, reliable, and practical arthroscopic transosseous techniques that enable surgeons to achieve better fixation and potentially better outcomes.

Multiple techniques have been described that aim to restore the biomechanical advantages of the transosseous technique in a completely arthroscopic fashion. Cicak et al.⁶ offered one of the first proposals in 2006, and since then several variations have attempted to create a standardized method. Garofalo et al.¹² described a novel technique involving a 2-step process to recreate intersecting tunnels followed by manual suture passage. Kuroda et al.¹³ reported good clinical outcomes of arthroscopic transosseous repair with a single tunnel, which increased the appeal of this technique. Murphy et al.¹⁴ more recently also described transosseous repair with intersecting tunnels, but with an anchor used for fixation. The technique we describe offers an alternative approach that reduces the anchor burden even further by achieving fixation without

implanted hardware while maintaining the surgical advantages of automated-assisted, needle-based suture passing through the bone.

There are several potential advantages of this technique to consider (Table 2). First, as mentioned, the suture-passing method is forgiving and versatile, which reduces the technical challenges traditionally associated with currently available arthroscopic transosseous devices. Additionally, the pure transosseous nature of the repair restores all of the biomechanical advantages associated with a more direct tendon-to-bone compression vector, leading to improved fixation and healing, broad footprint coverage with no foreign body at the footprint area, lower risk of rotator cuff failure at the musculotendinous junction (type 2 failure),⁵ lower

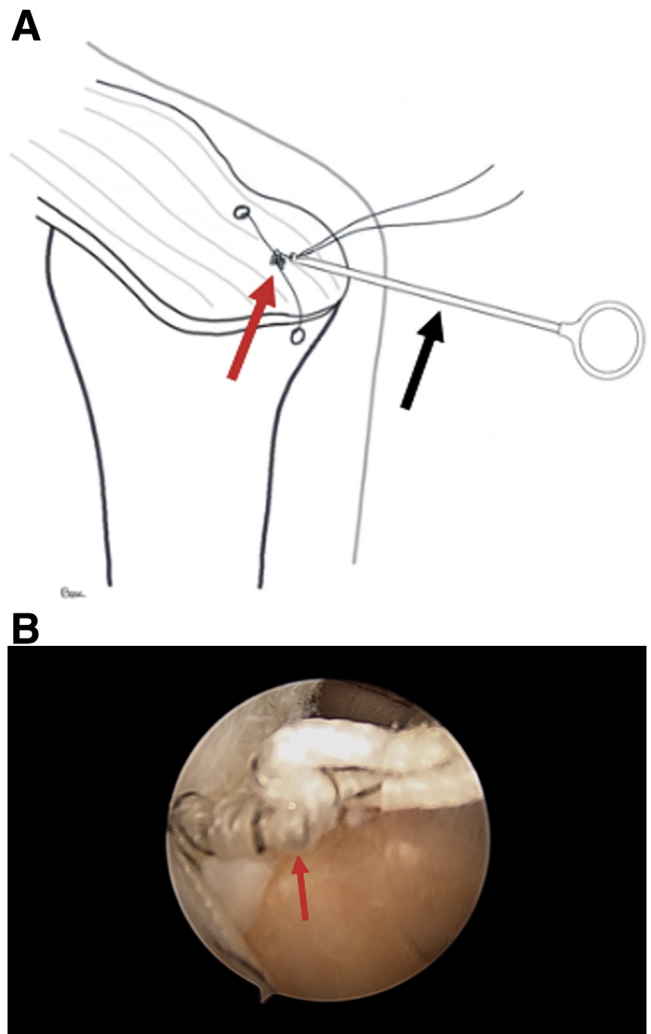


Fig 10. Diagram (A) and intra-articular image (B) viewed through the posterior portal of a right shoulder of patient in a beach chair position. The diagram shows a completed sliding knot followed by alternating half-hitches (*red arrow*) completed with application of the knot pusher (*black arrow*) to secure the tendon to its footprint. The intra-articular image shows the rotator cuff well-approximated with a secure knot.

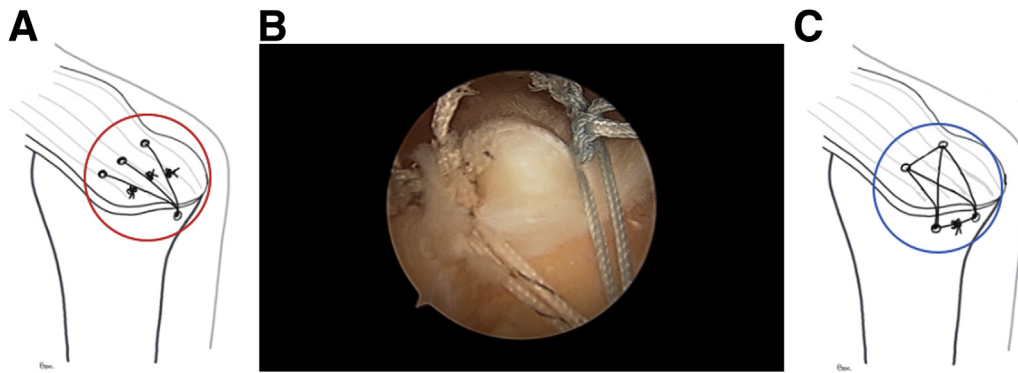


Fig 11. Diagram (A) and intra-articular image (B) of the completed repair viewed through the posterior portal of a right shoulder of patient in a beach chair position. The diagram shows the rotator cuff secured with three simple sutures (red circle) while the intra-articular image shows four simple sutures. An additional diagram (C) shows the tendon secured using an x-box technique (blue circle), which is also an appropriate method for fixation.

risk of type III Sugaya magnetic resonance imaging readings (insufficient thickness after repair),⁸ improved blood flow at the bone-tendon interface⁹ and decreased pain with similar functional outcomes¹⁰ while reducing the risk of anchor dislodgement and overstuffing of the tuberosity in revision cases.

Although this procedure is appealing in its ability to achieve transosseous rotator cuff repair, it is not without limitations. An important consideration is that, unlike transosseous-equivalent repair, a suture-bridging technique using the medial row is not recommended in transosseous repair. This medial row technique has been described as advantageous to prevent “medial cuff failure” but may also lead to strangulation and quick necrosis of the cuff tendon.¹⁵⁻¹⁷ Additionally, transosseous anchorless repair has had limited described use in osteoporotic bone because of the risk of suture pull-out through the tunnels.¹⁸ Recently, however, Shi et al.¹⁹ have shown that using 2-mm suture tape instead of no. 2 sutures may improve the feasibility of transosseous repairs in an aging osteoporotic population. As with any new procedure, there is also a learning curve to consider for new users, and so training, guided assistance, or both may be needed to

improve familiarity and comfort with the device, although the automated suture passage through the bone shortens the learning curve. Last, one of the main limitations is lack of reported clinical outcomes. Nevertheless transosseous repairs in general have demonstrated low re-tear rates, excellent function scores, and minimal complications.

In summary, this technique offers an anchorless alternative to achieve transosseous rotator cuff repair designed. Given the potential biomechanical and clinical benefits of transosseous fixation, it is an approach to consider for rotator cuff tears of all sizes and severity.

References

1. Tashjian RZ. Epidemiology, natural history, and indications for treatment of rotator cuff tears. *Clin Sports Med* 2012 Oct;31:589-604.
2. McLaughlin HL. Lesions of the musculotendinous cuff of the shoulder. The exposure and treatment of tears with retraction. *Clin Orthop Relat Res* 1944;(304):3-9. 1994 Jul.
3. Warner JJP, Tétreault P, Lehtinen J, Zurakowski D. Arthroscopic versus mini-open rotator cuff repair: A cohort comparison study. *Arthroscopy* 2005 Mar;21:328-332.
4. Cole BJ, ElAttrache NS, Anbari A. Arthroscopic rotator cuff repairs: An anatomic and biomechanical rationale for different suture-anchor repair configurations. *Arthroscopy* 2007 Jun;23:662-669.
5. Shi BY, Diaz M, Binkley M, McFarland EG, Srikumaran U. Biomechanical strength of rotator cuff repairs: A systematic review and Meta-regression Analysis of cadaveric studies. *Am J Sports Med* 2018 Jul 1;363546518780928.
6. Cicak N, Klobucar H, Bicanic G, Trsek D. Arthroscopic transosseous suture anchor technique for rotator cuff repairs. *Arthroscopy* 2006 May;22:565.e1-565.e6.
7. Steinitz A, Buxbaumer P, Hackl M, Buess E. Arthroscopic transosseous anchorless rotator cuff repair using the X-box technique. *Arthrosc Tech* 2019 Feb;8:e175-e181.
8. Garofalo R, Calbi R, Castagna A, Cesari E, Budeyri A, Krishnan SG. Is there a difference in clinical outcomes and repair integrity between arthroscopic single-row versus

Table 2. Advantages and Disadvantages

Advantages
Enhanced vascularity at footprint
Less postoperative pain
No implant in rotator cuff footprint in revision settings
No foreign body at the footprint area
Biomechanical advantages of transosseous repair
Less musculotendinous junction failure
Fewer MRI findings of insufficient thickness after repair
Disadvantages
Learning curve linked to new device
Clinical outcomes currently limited
Potentially limited use in osteoporotic bone
Suture tying the medial row not recommended

MRI, magnetic resonance imaging.

- transosseous (anchorless) fixation? A retrospective comparative study. *J Orthop Sci* 2018 Sep;23:770-776.
9. Urita A, Funakoshi T, Horie T, Nishida M, Iwasaki N. Difference in vascular patterns between transosseous-equivalent and transosseous rotator cuff repair. *J Shoulder Elbow Surg* 2017 Jan;26:149-156.
 10. Randelli P, Stoppani CA, Zaolino C, Menon A, Randelli F, Cabitza P. Advantages of arthroscopic rotator cuff repair with a transosseous suture technique: A prospective Randomized Controlled Trial. *Am J Sports Med* 2017 Jul;45(9):2000-9.
 11. Baudi P, Rasia Dani E, Campochiaro G, Rebutti M, Serafini F, Catani F. The rotator cuff tear repair with a new arthroscopic transosseous system: The Sharc-FT(®). *Musculoskelet Surg* 2013 Jun;97:57-61 (Suppl 1).
 12. Garofalo R, Castagna A, Borroni M, Krishnan SG. Arthroscopic transosseous (anchorless) rotator cuff repair. *Knee Surg Sports Traumatol Arthrosc* 2012 Jun;20:1031-1035.
 13. Kuroda S, Ishige N, Mikasa M. Advantages of arthroscopic transosseous suture repair of the rotator cuff without the Use of anchors. *Clin Orthop Relat Res* 2013 Nov;471:3514-3522.
 14. Murphy MM, Tashjian RZ, Burks RT. Rotator cuff repair technique with transosseous knotless anchor system. *Arthrosc Tech* 2018 Aug 20;7:e927-e937.
 15. Rhee YG, Cho NS, Parke CS. Arthroscopic rotator cuff repair using modified Mason-Allen medial row stitch: Knotless versus knot-tying suture bridge technique. *Am J Sports Med* 2012 Nov;40:2440-2447.
 16. Cho NS, Yi JW, Lee BG, Rhee YG. Retear patterns after arthroscopic rotator cuff repair: Single-row versus suture bridge technique. *Am J Sports Med* 2010 Apr;38:664-671.
 17. Cho NS, Lee BG, Rhee YG. Arthroscopic rotator cuff repair using a suture bridge technique: Is the repair integrity actually maintained? *Am J Sports Med* 2011 Oct;39:2108-2116.
 18. Bunker TD, Keenan J, Lee C. Arthroscopic transosseous rotator cuff repair: A cautionary tale. *Shoulder & Elbow* 2011;3:202-204.
 19. Shi BY, Diaz M, Belkoff SM, Srikumaran U. Pullout strength of cement-augmented and wide-suture transosseous fixation in the greater tuberosity. *Clin Biomech (Bristol, Avon)* 2017 Dec;50:154-159.