



## Original Article

### Corresponding Author

Hyeun-Sung Kim

<https://orcid.org/0000-0001-5361-5234>

Department of Neurosurgery, Nanoori Hospital, 731 Eonju-ro, Gangnam-gu, Seoul 06048, Korea  
Tel: +82-2-6003-9767  
Fax: +82-2-3445-9755  
E-mail: [neuros@hanmail.net](mailto:neuros@hanmail.net)

Received: February 18, 2018

Revised: May 7, 2018

Accepted: May 17, 2018

# Feasibility of Full Endoscopic Spine Surgery in Patients Over the Age of 70 Years With Degenerative Lumbar Spine Disease

Jeong Hoon Kim<sup>1</sup>, Hyeun Sung Kim<sup>2</sup>, Ankur Kapoor<sup>2</sup>, Nitin Adsul<sup>2</sup>, Ki Joon Kim<sup>1</sup>, Sung Ho Choi<sup>1</sup>, Jee-Soo Jang<sup>1</sup>, Il-Tae Jang<sup>2</sup>, Seong-Hoon Oh<sup>3</sup>

<sup>1</sup>Department of Neurosurgery, Nanoori Suwon Hospital, Suwon, Korea

<sup>2</sup>Department of Neurosurgery, Nanoori Hospital, Seoul, Korea

<sup>3</sup>Department of Neurosurgery, Nanoori Incheon Hospital, Incheon, Korea

**Objective:** Degenerative spine disease, encompassing disc prolapse and stenosis, is a common ailment in old age. This prospective study was undertaken to evaluate the role of endoscopic spine surgery in elderly patients (above 70 years of age) with clinical and radiological follow-up.

**Methods:** In this study, a retrospective analysis was conducted of 53 patients with lumbar disc prolapse or spinal stenosis who were treated with percutaneous endoscopic discectomy or decompression from November 2015 to June 2017. Clinical follow-up was done at 1 week, 3 months, and 1 year, and at yearly intervals thereafter. The outcomes were assessed using the modified Macnab criteria, a visual analogue scale, and the Oswestry Disability Index.

**Results:** Of the 53 patients, 21 were men and 32 were women. Their mean age was  $76 \pm 4$  years. The mean follow-up period was 17 months. Percutaneous endoscopic discectomy was performed in 24 patients and endoscopic decompression in 24 patients, while 5 patients underwent combined surgery. An excellent outcome in terms of the MacNab criteria was observed in 9 patients (16.98%), a good outcome in 38 patients (71.7%), and a poor outcome in 6 patients (11.3%). Of the 6 patients with a poor outcome, 5 (9.4%, 5 of 53) developed recurrent disc prolapse, and 1 developed hematoma with motor weakness. All 6 of these cases required revision surgery.

**Conclusion:** Managing degenerative spine disease in elderly patients with multiple comorbidities is a challenging task. Percutaneous endoscopic spine surgery is pivotal for addressing this concern. The authors have shown that optimal results can be achieved with various types of disc prolapse and stenosis with favorable long-term outcomes.

**Keywords:** Percutaneous endoscopic spine surgery, Old age, Disc prolapse, Stenosis, Decompression, Discectomy



This is an Open Access article distributed under the terms of the Creative Commons Attribution Non-Commercial License (<http://creativecommons.org/licenses/by-nc/4.0/>) which permits unrestricted non-commercial use, distribution, and reproduction in any medium, provided the original work is properly cited.

Copyright © 2018 by the Korean Spinal Neurosurgery Society

## INTRODUCTION

Lumbar degenerative spine disease affects the majority of the population in all societies with variable outcomes in old age. The multiple comorbidities that exist have an important bearing on the outcome of prolonged spine surgery.<sup>1-3</sup> At this age, the physical incapacities and comorbid illness make any inter-

vention in the form of surgery a challenging task. The rate of complication after spine surgery may be as high as 35%.<sup>1</sup> The overall quality of life frequently gets hampered after open spine surgery,<sup>4,5</sup> and with increasing longevity nowadays it is all the more a matter of concern.

There have been numerous reports on the benefit of endoscopic spine surgery for lumbar disc prolapse and spinal steno-

sis. Not only is the surgery performed with a small incision that helps early recovery, but overall hospital stay is significantly shorter and quality of life is improved.<sup>6-9</sup> So far, there has been no mention of the role of endoscopic spine surgery in old age patients, especially above 70 years of age. We undertook this prospective study on patients above 70 years of age who presented with various problems pertaining to spine and were offered surgical interventions in form of percutaneous endoscopic spine surgery (PESS). The clinical and radiological follow up along with the quality of life was assessed in all the patients. Endoscopic spine surgery has a definite role in old age patients by helping to improve quality of life with a minimal disability.

## MATERIALS AND METHODS

The study is based on retrospective analysis of 53 patients with lumbar degenerative spine disease, over 70 years of age that were managed at Nanoori Hospital from November 2015 to June 2017. This study was approved by the Institutional Review Board of Nanoori Hospital (approval number: 2018-006). X-ray imaging, computed tomography (CT), and magnetic resonance imaging (MRI) were done in all cases to confirm the diagnosis and to rule out other pathologies. The findings demonstrated on the CT and MRI scans were correlated with the neurologic examination. After proper diagnosis patients underwent surgery by endoscopic route-percutaneous endoscopic transforaminal lumbar discectomy (PETLD), percutaneous endoscopic interlaminar lumbar discectomy (PEILD), percutaneous endoscopic transforaminal lumbar foraminotomy (PETLF), and percutaneous endoscopic stenosis lumbar decompression (PESLD). We used local anesthesia for transforaminal procedures, epidural anesthesia for interlaminar procedures. When antithrombotic drugs are discontinued in the days before a surgical procedure, the risk for perioperative bleeding may decrease, whereas the risk of thromboembolic events rises. Therefore, we usually individualize this protocol for each patient after consulting with our cardiologist and anesthetist. In general, we stop aspirin for 5 days and clopidogrel for 7 days before surgery in patients without major risk factors like stent thrombosis.

The exclusion criteria were the presence of segmental instability and spondylolisthesis more than grade 1. A written informed consent was obtained from all the patients. PETLD and PETLF surgery were performed under local anesthesia, while epidural anesthesia was administered for PESLD and PEILD. PETLD and PETLF were performed for lumbar disc L1-2 to L4-5, PEILD for L5-S1 disc, PETLF for foraminal disc, and

PESLD for stenosis.

Considering thin and fragile epidural blood vessels and dura, decompression was performed with additional care. We tried to minimize the duration of surgery and all surgeries performed by our senior spine surgeon with 10 years of experience and have performed 3,000 endoscopic spine surgeries. MRI was done in all the patients on the day following surgical intervention.

Outcome was measured by visual analogue scale (VAS) leg pain score, Oswestry Disability Index (ODI), and the MacNab criteria. These were measured in the preoperative period and at follow up visit (1 week and 3 months and at last follow-up). The significance level was considered at 0.05. Statistical software used for the study was IBM SPSS Statistics ver. 20.0 (IBM Co., Armonk, NY, USA).

**Table 1.** Patient characteristics (n = 53)

Characteristic	Value
Age (yr)	76 ± 4.4 (70-88)
Sex ratio, male:female	2:1.3
Surgical procedure	
Discectomy (PETLD/PEILD)	24 (45.3)
Decompression (PESLD/PETLF)	24 (45.3)
Combined	5 (9.4)
Levels involved (n = 62)	
L1-2	1 (1.6)
L2-3	6 (9.7)
L3-4	15 (24.2)
L4-5	29 (46.8)
L5-S1	11 (17.7)
Follow-up (mo)	17.2 ± 5.3 (9-29)
MacNab criteria	
Excellent	9 (16.9)
Good	38 (71.7)
Poor	6 (11.3)
Complications (n = 6)	
Recurrent disc prolapse	5 (9.4)
Neurological deficit	1 (1.8)

Values are presented as mean ± standard deviation (range) or number (%).

PETLD, percutaneous endoscopic transforaminal lumbar discectomy; PEILD, percutaneous endoscopic interlaminar lumbar discectomy; PESLD, percutaneous endoscopic stenosis lumbar decompression; PETLF, percutaneous endoscopic transforaminal lumbar foraminotomy.

## RESULTS

PESS performed in 53 patients. Of 53 patients 21 were men and 32 were women. The mean age of the patients enrolled in the study was 76 years (range, 70–88 years) and male/female

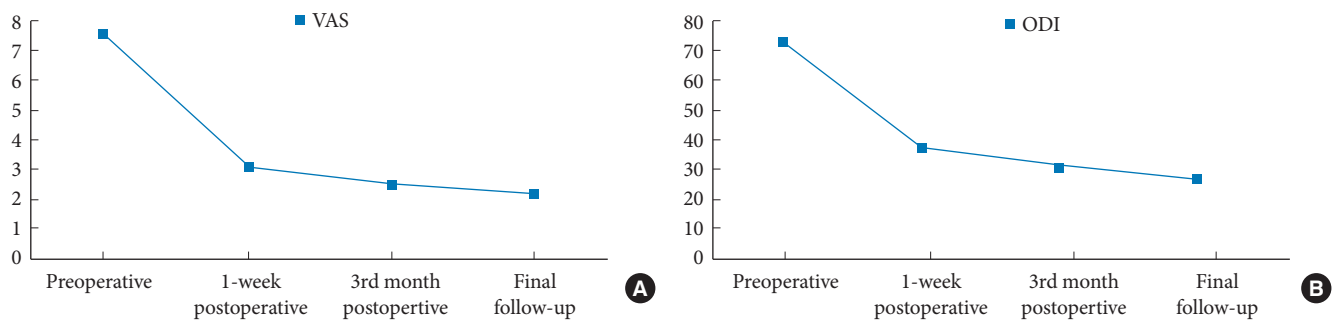
ratio was 2:1.3 (Table 1). The mean follow-up of enrolled patients was 17 months (range, 8–29 months). Percutaneous endoscopic discectomy by transforaminal or interlaminar route was performed in 24 patients, endoscopic decompression in 24 patients while 5 patients underwent combined discectomy and

**Table 2.** Clinical outcomes

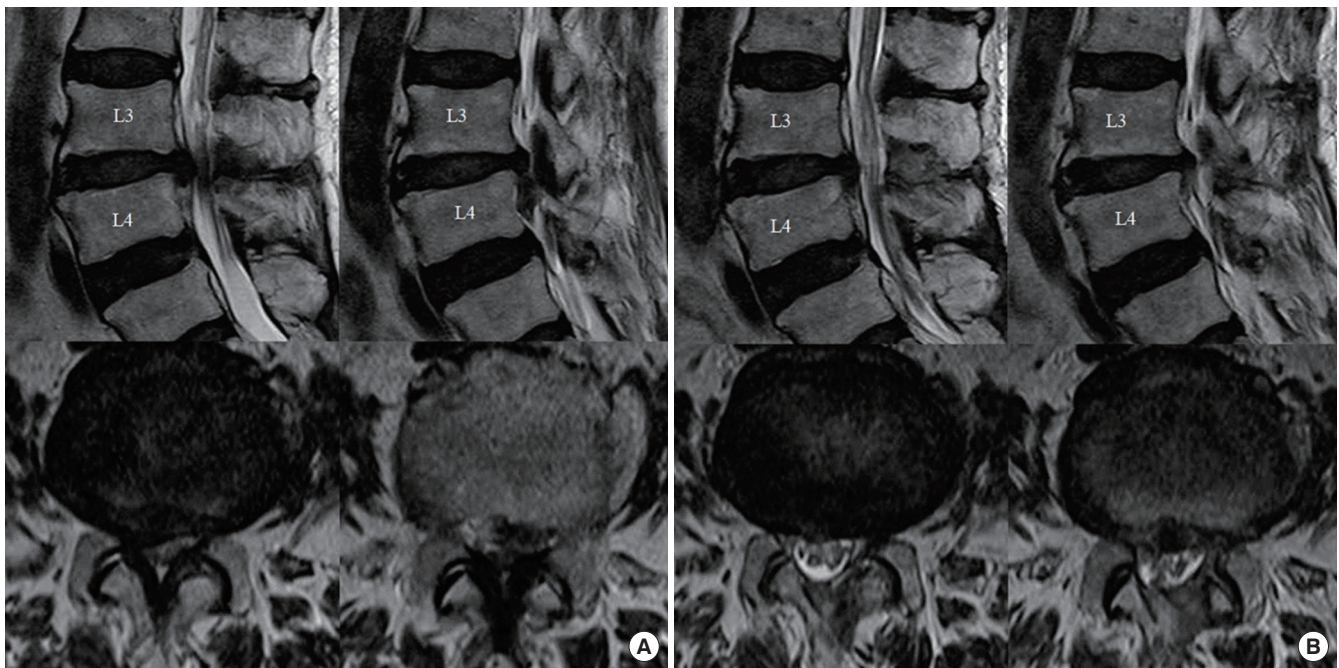
Score	Preoperative	Postoperative	p-value*	3 Months postoperative	p-value*	Final follow-up	p-value*
Visual analog scale leg score	7.58 ± 1.06	3.11 ± 0.85	<0.0001	2.51 ± 0.89	<0.0001	2.21 ± 0.91	<0.0001
Oswestry Disability Index Score	73.40 ± 7.44	37.51 ± 7.95	<0.0001	31.40 ± 8.25	<0.0001	26.85 ± 6.16	<0.0001

Values are presented as mean ± standard deviation.

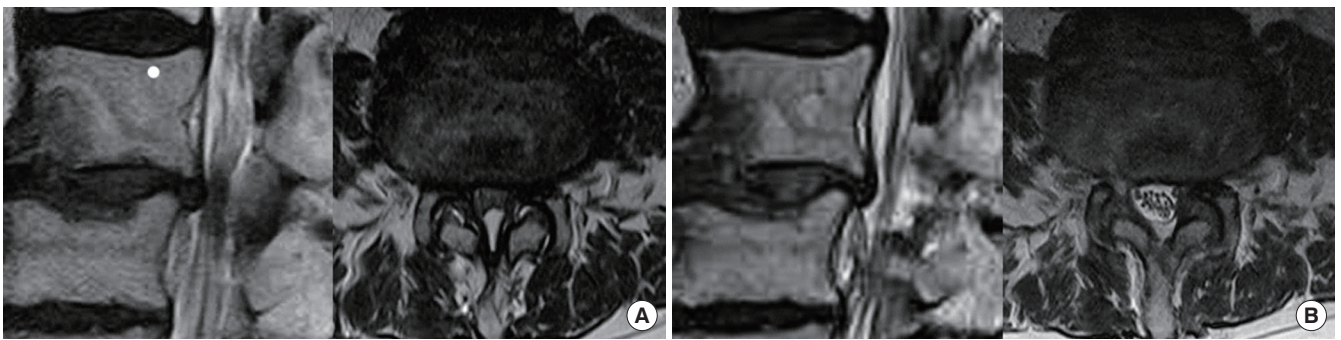
\*Paired t-test. p < 0.05, statistically significant differences.



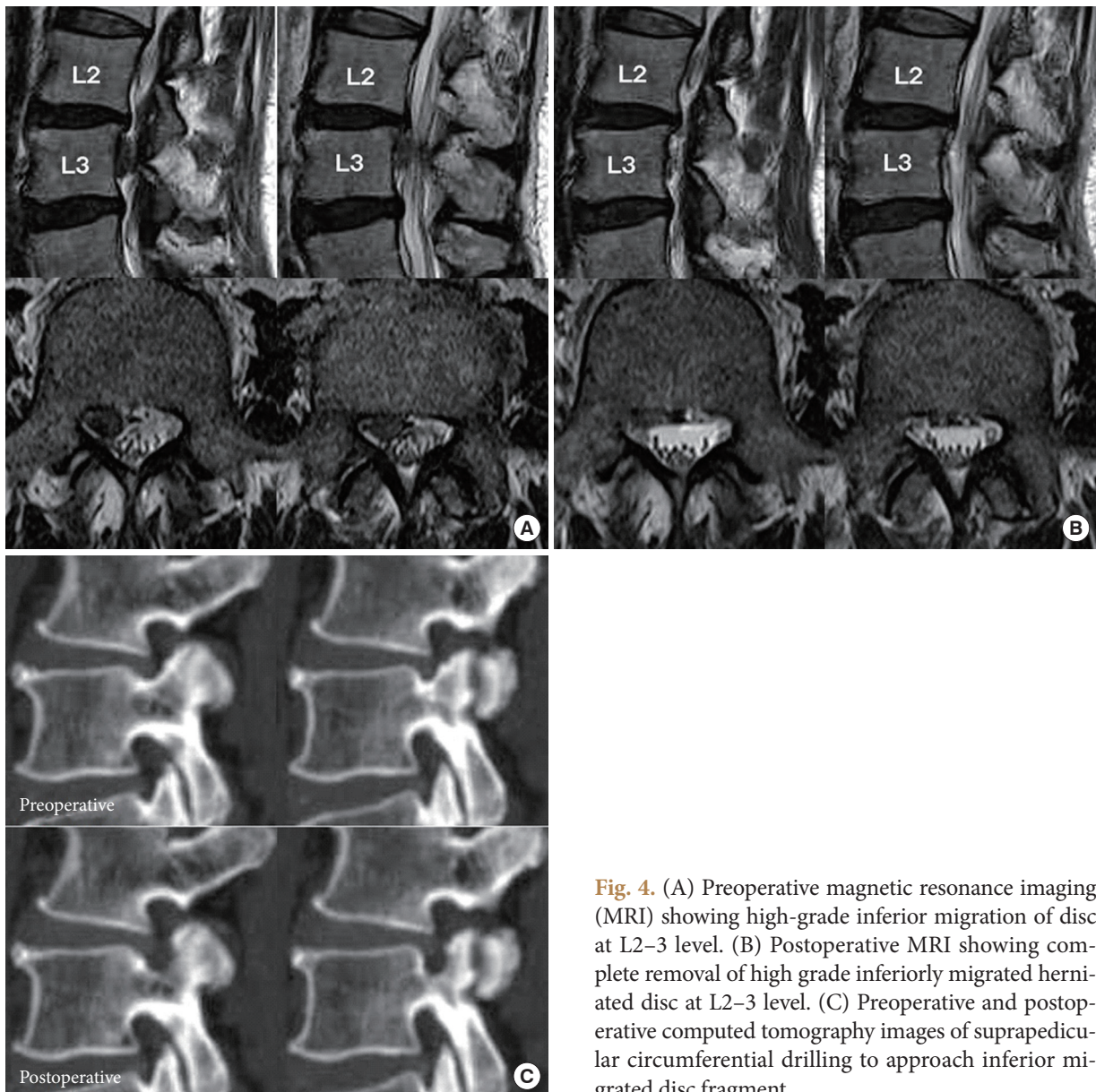
**Fig. 1.** Graphs showing changes in visual analogue scale (VAS; A) and Oswestry Disability Index (ODI; B).



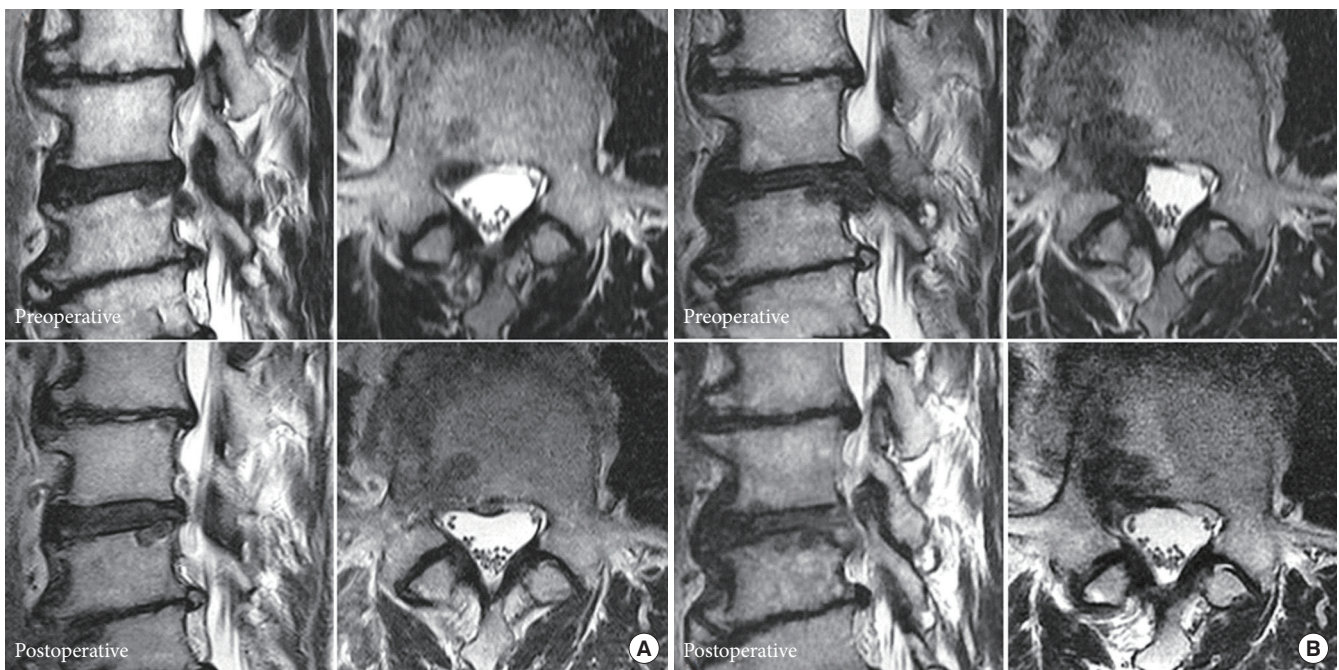
**Fig. 2.** (A) Preoperative magnetic resonance imaging (MRI) of a case with severe lumbar canal stenosis with inferior migration of disc fragment at L3–4 level. (B) Postoperative MRI showing complete removal of inferiorly migrated herniated disc with bilateral decompression without violation of facet joints or muscle damage after percutaneous endoscopic stenosis lumbar decompression.



**Fig. 3.** (A) Preoperative magnetic resonance imaging (MRI) of a case with severe lumbar canal stenosis at L4–5 level. (B) Postoperative MRI showing complete bilateral decompression without violation of facet joints or muscle damage after percutaneous endoscopic stenosis lumbar decompression.



**Fig. 4.** (A) Preoperative magnetic resonance imaging (MRI) showing high-grade inferior migration of disc at L2–3 level. (B) Postoperative MRI showing complete removal of high grade inferiorly migrated herniated disc at L2–3 level. (C) Preoperative and postoperative computed tomography images of suprapedicular circumferential drilling to approach inferior migrated disc fragment.



**Fig. 5.** (A) Preoperative magnetic resonance imaging (MRI) showing inferior migration of disc at L3–4 level and postoperative MRI showing complete removal of inferiorly migrated herniated disc at L3–4 level. (B) Recurrence after 2 years: Preoperative MRI showing inferior migration of disc at L3–4 level and postoperative MRI showing complete removal of inferiorly migrated herniated disc at L3–4 level.

decompression surgery. Total 62 levels were treated with 29 patients at L4–5 (46.8 %) level, 15 at L3–4 (4.2%), 11 at L5–S1 (17.7%), 6 at L2–3 (9.7%) and 1 at L1–2 (1.6%). Nine patients had undergone surgery at 2 levels (16.9%) whereas the remaining patients had undergone surgery at single level.

The preoperative VAS<sup>leg</sup> score on the affected side was  $7.6 \pm 1.1$  (range, 6–10) and the postoperative VAS<sup>leg</sup> score improved to  $3.1 \pm 0.9$  (range, 2–6). The improvement was significant at  $p < 0.0001$  (Table 2). Significant improvement was maintained at the third month and at final follow-up with VAS<sup>leg</sup> scores of  $2.5 \pm 0.9$  (range, 1–5;  $p < 0.0001$ ) and  $2.2 \pm 0.9$  (range, 1–5;  $p < 0.0001$ ), respectively (Fig. 1A). ODI scores change from  $73.4 \pm 7.4$  (range, 48–86) preoperatively to  $37.5 \pm 7.9$  (range, 25–68) postoperatively ( $p < 0.0001$ ). Significant improvement was maintained at the third month postoperatively and at final follow-up with ODI scores of  $31.4 \pm 8.2$  (range, 22–56;  $p < 0.0001$ ) and  $26.8 \pm 6.2$  (range, 16–44;  $p < 0.0001$ ), respectively (Fig. 1B). An excellent outcome on MacNab criteria was noted in 9 patients (16.98%, 9 of 53), a good outcome in 38 patients (71.7%, 38 of 53), poor results in 6 patients (11.3%, 6 of 53). Average duration of surgery was  $48 \pm 12$  minutes (range, 35–90 minutes).

Out of these 6 patients with poor results, 5 patients (9.4%, 5 of 53) developed recurrent disc prolapse, one patient (without

history of any antithrombotic drug) developed hematoma with motor weakness which required open irrigation. Out of the 5 patients with recurrent disc prolapse: 1 case converted to PESLD with a discectomy, 2 cases revision PETLD and 2 cases converted to TLIF. There was no injury to facet joint during index surgery in all these 5 patients and index surgery was discectomy, which less likely causes facet injury both in transforaminal and interlaminar approach in our technique.<sup>6–9</sup> The 2 patients in whom we performed fusion surgery had grade I spondylolisthesis before index surgery, which got aggravated in follow-up period.

Postoperative MRI showed adequate decompression of the pathologic segment in 46 patients (86.8%) with these endoscopic procedures (Figs. 2–5).

## DISCUSSION

The fields of spine surgery have experienced rapid growth over the past decade, yet little research has focused on the issues related to older age. Perioperative complications are frequently encountered in elderly patients owing to comorbid cardiovascular and renal disease, poor nutritional status and immobility. Concerns regarding perioperative complications may

be allayed by decreasing the invasiveness with which the spine is approached. Smith and Fessler<sup>10</sup> have mentioned without exaggeration about the paradigm change in spine surgery accompanying the evolution of Minimally Invasive Spine Surgery techniques. Ideal surgical approach to the spine is the one, which causes minimal approach related disruption of normal spinal anatomy and function.

Decision taking for operative intervention in old age spine disease is a formidable task. As the age increases so does the comorbidity.<sup>2,3</sup> Fragility, defined as increasing vulnerability due to stressors in old age, increases exponentially with age.<sup>11</sup> While major complications as wound infection, neurological deficit, renal shutdown, pneumonia and stroke may be seen in one out of five patients in old age, the frequency of minor complications as delirium, urinary tract infections, postoperative dysesthesia may be seen in upto 72% of patients.<sup>12,13</sup> Endoscopic spine surgery has come as a boom to cater the need of this precious patient population. While numerous studies have demonstrated the benefits of endoscopic spine surgery as compared to micro-lumbar discectomy or open surgery,<sup>6-9</sup> we could not find any study notably mentioning the role of endoscopic spine surgery in old age.

The multiple comorbid illnesses of old age, as cardiorespiratory diseases, renal insufficiency, diabetes, and immunocompromised state together make up the administration of general anesthesia an arduous task.<sup>14-17</sup> Moreover the prolonged duration in traditional open spine surgery itself becomes a risk factor for adverse outcome.<sup>18</sup> Blood transfusion is frequently needed in open spine surgery as the patient has a low reserve, and then transfusion has its own complications. While laminectomy alone carries risk of increasing subtle insufficiency<sup>19,20</sup> that already exists, posterior fixation in patients at 70 to 80 years of age is even not well tolerated. Moreover, the degenerative changes exist at more than one level at old age and so arises the need to address the spine disease in a minimally invasive way.

Advantages of full endoscopic spine surgeries are less soft tissue dissection, less blood loss, reduced hospital admission days, early functional recovery and enhancement in the quality of life.<sup>21</sup> With the increase in human longevity, the development of effective treatment for degenerative diseases is inevitable, and future endoscopic spine surgery will play a very important role in maintaining health of this 'super-aged' population.

The multiple level affection of disc disease in old age and co-existence of stenosis and disc disease merits special mention. Frequently, both are symptomatic and need intervention. PESS seems to be the treatment of choice in such patients. We man-

aged 5 patients in our study who needed intervention for both, the disc disease and stenosis. As can be seen in the results, the recovery is immediate and long-standing. Our study has shown that multiple options exist in percutaneous endoscopy spine surgery to address different diseases of spine in old age. Different endoscopic routes in our patients effectively managed the wide gamut of disc prolapse as central, paracentral, foraminal and superior and inferior migration. Stenosis in old age causes incapacitation and worsens the quality of life. Excellent postoperative results with long-term follow-up for endoscopic decompression establishes the latter as the need of hour. The improvement in VAS score for leg pain and ODI was phenomenal and was maintained on long-term follow-up. On MacNab criteria, 88.6% of patients had good to excellent outcome. The recurrence rate in our study on 53 patients was 9.4%, this is well within the range of 5%–18% rate of recurrence reported previously. While multiple pathological factors contribute to early and late recurrence in disc disease, little is known about recurrence at this old age. We believe, with ever-improving surgical techniques and availability of modern instruments, the recurrence rates will improve in the coming years.

While the overall number of patients in this study is limited, the authors believe this is a landmark article that knuckles down to unfold the complex panorama of spine disease in age above 70 years. It embarks upon the potential of endoscopic spine surgery to combat disc prolapse and stenosis in old age patients.

## CONCLUSION

Providing long-term optimum results in lumbar degenerative spine disease is a daunting task, especially in old age patients beyond 70 years. In spite of the recurrence as most common complication, PESS is pivotal to address old age degenerative spine disease without exposing patient to more extensive open surgery. The authors have shown that optimum results can be achieved in various types of disc prolapse and stenosis with the favorable long-term outcome.

## CONFLICT OF INTEREST

The authors have nothing to disclose.

## ACKNOWLEDGMENTS

We would like to acknowledge scientific team members Ms. Jae Eun Park and Mr. Kyeong-rae Kim for providing assistance

in acquiring full-text articles and managing digital works.

## REFERENCES

1. Choi JM, Choi MK, Kim SB. Perioperative results and complications after posterior lumbar interbody fusion for spinal stenosis in geriatric patients over than 70 years old. *J Korean Neurosurg Soc* 2017;60:684-90.
2. Cassinelli EH, Eubanks J, Vogt M, et al. Risk factors for the development of perioperative complications in elderly patients undergoing lumbar decompression and arthrodesis for spinal stenosis: an analysis of 166 patients. *Spine (Phila Pa 1976)* 2007;32:230-5.
3. Choma TJ, Rehtine GR, McGuire RA Jr, et al. Treating the aging spine. *J Am Acad Orthop Surg* 2015;23:e91-100.
4. Cloyd JM, Acosta FL Jr, Ames CP. Complications and outcomes of lumbar spine surgery in elderly people: a review of the literature. *J Am Geriatr Soc* 2008;56:1318-27.
5. Arinzon ZH, Fredman B, Zohar E, et al. Surgical management of spinal stenosis: a comparison of immediate and long term outcome in two geriatric patient populations. *Arch Gerontol Geriatr* 2003;36:273-9.
6. Kim HS, Paudel B, Jang JS, et al. Percutaneous full endoscopic bilateral lumbar decompression of spinal stenosis through uniportal-contralateral approach: techniques and preliminary results. *World Neurosurg* 2017;103:201-9.
7. Kim HS, Yudoyono F, Paudel B, et al. Analysis of clinical results of three different routes of percutaneous endoscopic transforaminal lumbar discectomy for lumbar herniated disk. *World Neurosurg* 2017;103:442-8.
8. Kim HS, Ju CI, Kim SW, et al. Endoscopic transforaminal suprapedicular approach in high grade inferior migrated lumbar disc herniation. *J Korean Neurosurg Soc* 2009;45:67-73.
9. Kim HS, Patel R, Paudel B, et al. Early outcomes of endoscopic contralateral foraminal and lateral recess decompression via an interlaminar approach in patients with unilateral radiculopathy from unilateral foraminal stenosis. *World Neurosurg* 2017;108:763-73.
10. Smith ZA, Fessler RG. Paradigm changes in spine surgery: evolution of minimally invasive techniques. *Nat Rev Neurol* 2012;8:443-50.
11. McIsaac DI, Jen T, Mookerji N, et al. Interventions to improve the outcomes of frail people having surgery: a systematic review. *PLoS One* 2017;12:e0190071.
12. Lee JY, Moon SH, Suh BK, et al. Outcome and complications in surgical treatment of lumbar stenosis or spondylolisthesis in geriatric patients. *Yonsei Med J* 2015;56:199-205.
13. Carreon LY, Puno RM, Dimar JR 2nd, et al. Perioperative complications of posterior lumbar decompression and arthrodesis in older adults. *J Bone Joint Surg Am* 2003;85-A:2089-92.
14. Glassman SD, Carreon LY, Dimar JR, et al. Clinical outcomes in older patients after posterolateral lumbar fusion. *Spine J* 2007;7:547-51.
15. Gruskay JA, Fu M, Bohl DD, et al. Factors affecting length of stay after elective posterior lumbar spine surgery: a multivariate analysis. *Spine J* 2015;15:1188-95.
16. Hudak EM, Perry MW. Outpatient minimally invasive spine surgery using endoscopy for the treatment of lumbar spinal stenosis among obese patients. *J Orthop* 2015;12:156-9.
17. Deyo RA, Cherkin DC, Loeser JD, et al. Morbidity and mortality in association with operations on the lumbar spine. The influence of age, diagnosis, and procedure. *J Bone Joint Surg Am* 1992;74:536-43.
18. Hino H, Karasaki T, Yoshida Y, et al. Risk factors for postoperative complications and long-term survival in lung cancer patients older than 80 years. *Eur J Cardiothorac Surg* 2018;53:980-6.
19. Fredman B, Arinzon Z, Zohar E, et al. Observations on the safety and efficacy of surgical decompression for lumbar spinal stenosis in geriatric patients. *Eur Spine J* 2002;11:571-4.
20. Tokuhashi Y, Ajiro Y, Umezawa N. Outcomes of posterior fusion using pedicle screw fixation in patients  $\geq 70$  years with lumbar spinal canal stenosis. *Orthopedics* 2008;31:1096.
21. Choi G, Pophale CS, Patel B, et al. Endoscopic spine surgery. *J Korean Neurosurg Soc* 2017;60:485-97.