



CASE REPORT

Case Report: Managing a giant, high-grade carotid body tumor in a resource-limited setting [version 1; referees: 3 approved, 1 approved with reservations]

Sunil Munakomi , Samrita Chaudhary, Iype Cherian


Department of Neurosurgery, Nobel Teaching Hospital, Biratnagar, Nepal

v1 First published: 04 Oct 2017, 6:1801 (doi: [10.12688/f1000research.12726.1](https://doi.org/10.12688/f1000research.12726.1))
 Latest published: 04 Oct 2017, 6:1801 (doi: [10.12688/f1000research.12726.1](https://doi.org/10.12688/f1000research.12726.1))




Abstract

Herein we report the management of a giant, high-grade and vascular carotid body tumor in a young woman. She presented with slowly progressive neck swelling. Vascular imaging revealed a left-sided, high-grade giant carotid body tumor (> 8cm). The tumor was completely excised by caudocranial subadventitial dissection. Histology of the tumor revealed a characteristic Zellballen pattern of the lesion, suggestive of a paraganglioma. The patient made an uneventful recovery. We also discuss newer insights regarding the management of such highly vascular lesions.

Open Peer Review

Referee Status: 

	Invited Referees			
	1	2	3	4
version 1				
published 04 Oct 2017	report	report	report	report

- Arif Hussian Sarmast** , Aligarh Muslim University, India
- Yi Guo**, Tsinghua Changgung Hospital, China
- Luis Rafael Moscote-Salazar** , RED LATINO (Latin American Trauma & Intensive Neurocare Organization), Colombia
University of Cartagena, Colombia
- Alexis Narvaez-Rojas** , Universidad Nacional Autónoma de Nicaragua, Nicaragua
- Guru Dutta Satyarthee**, All India Institute of Medical Sciences (AIIMS), Gamma Knife Centre, India

Discuss this article

Comments (0)

Corresponding author: Sunil Munakomi (sunilmunakomi@gmail.com)

Author roles: **Munakomi S:** Conceptualization, Formal Analysis, Writing – Original Draft Preparation; **Chaudhary S:** Investigation; **Cherian I:** Supervision, Writing – Review & Editing

Competing interests: No competing interests were disclosed.

How to cite this article: Munakomi S, Chaudhary S and Cherian I. **Case Report: Managing a giant, high-grade carotid body tumor in a resource-limited setting [version 1; referees: 3 approved, 1 approved with reservations]** *F1000Research* 2017, **6**:1801 (doi: [10.12688/f1000research.12726.1](https://doi.org/10.12688/f1000research.12726.1))

Copyright: © 2017 Munakomi S *et al.* This is an open access article distributed under the terms of the [Creative Commons Attribution Licence](https://creativecommons.org/licenses/by/4.0/), which permits unrestricted use, distribution, and reproduction in any medium, provided the original work is properly cited.

Grant information: The author(s) declared that no grants were involved in supporting this work.

First published: 04 Oct 2017, **6**:1801 (doi: [10.12688/f1000research.12726.1](https://doi.org/10.12688/f1000research.12726.1))

Introduction

Giant carotid body tumors are rare. Management of such highly vascular lesions, which completely encase the major carotid artery along with its branches, is even more challenging. We report the management strategy for a similar case, where caudocranial subadventitial dissection completely excised this tumor, one of the largest reported in the literature^{1,2}.

Case report

A 22-year-old woman presented to the Neurosurgery clinic in Nobel Teaching Hospital with a history of slow progressive but painless swelling over her left neck, ongoing for the last 6 months. She was also experiencing some difficulty while swallowing. She denied history of trauma, any episodes suggestive of transient ischemic attacks or paroxysmal episodes of severe headache, flushing or chest pain. She did not have major surgery or medical illnesses in the past, or any significant family history.

Local examination revealed a pulsatile swelling on her left neck. There was no audible bruit over the swelling. The patient then underwent a CT angiography, which revealed a well-defined large (> 8 cm) heterogeneous and hyperdense soft tissue lesion; showing intense arterial enhancement at the level of carotid bifurcation (Figure 1). It was causing significant compression and displacement of a long segment of the internal carotid artery (ICA) and external carotid artery (ECA), encasing a broad area of the ICA and ECA (Shamblin Grade 3) (Figure 2). The lesion was getting vascular supply from both the ICA and ECA branches (Figure 3). These findings were all highly suggestive of a carotid body tumor.

Ultrasound imaging of the abdomen to assess adrenal glands was normal. 24-hour urine vanillylmandelic acid (VMA) and plasma metanephrines were within normal range.

The patient was thoroughly counseled regarding her condition and the need for operative management. The risks associated with the surgery, including intra-operative uncontrolled bleeding, lower cranial nerve palsy, ischemic stroke and even death, were detailed.

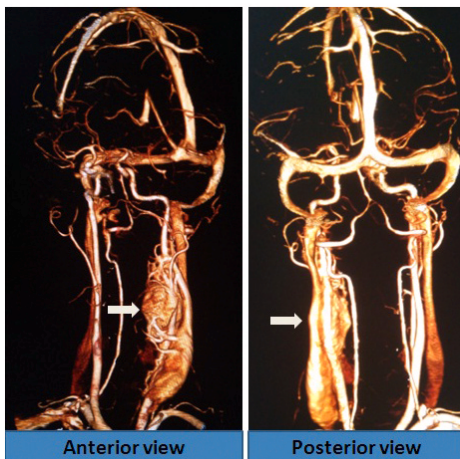


Figure 1. Carotid angiography image revealing a giant highly vascular, left-sided carotid body tumor.

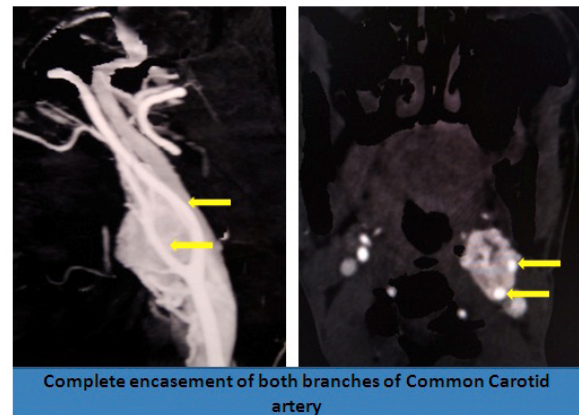


Figure 2. Angiographic image revealing encasement of the common carotid as well as both of its main branches by the tumor.

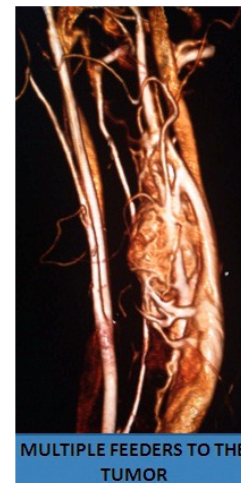

Figure 3. Tumor having vascular supply from both the external and internal carotid arteries.

Anaesthetic precautionary measures were implemented to reduce the risk of hypertensive crisis (during tumor manipulation) and hypotensive episodes (following tumor removal), by administering antihypertensive drugs and fluid support, respectively. After ensuring temporary carotid control with vascular loops, sub-adventitial dissection of the lesion was carried out starting from the common carotid caudally and then progressing cranially towards the bifurcation and its branches (Figure 4). The major vascular supplies were sequentially isolated, ligated and divided. A venous graft from the long saphenous vein was prepared for repair in case of inadvertent tears within the carotid or any of its branches. The internal jugular vein and the vagus nerve within the carotid sheath, and the hypoglossal nerve were all selectively isolated and well preserved. The lesion was completely excised and sent for histopathological analysis. There was only one instance of temporary bradycardia throughout the procedure. Patient made an uneventful recovery with no lower cranial nerve deficits or any vascular insults. The histology from the lesion revealed a characteristic Zellballen pattern, highly suggestive of a Paraganglioma (Figure 5). The patient

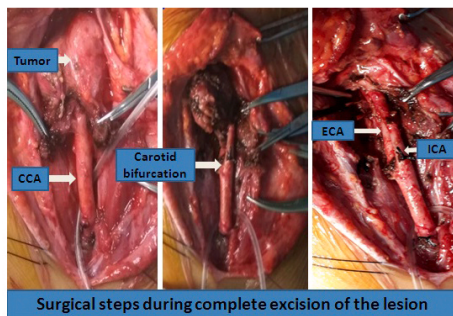


Figure 4. Surgical steps carried out during caudocranial subadventitial dissection.

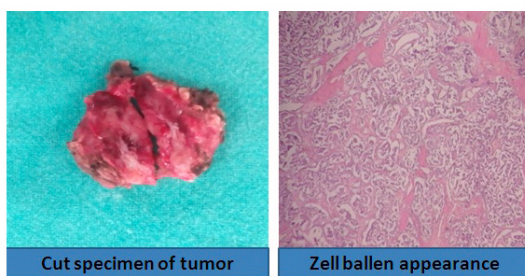


Figure 5. Cut specimen of the excised tumor, along with the characteristic Zellballen pattern in the histology.

has been for regular follow-ups in the last 4 months, with complete resolution of her previous symptoms. She has been advised for lifelong periodic visits.

Discussion

Carotid body tumors, first described by Von Haller in 1743, are of neuro-ectodermal origin³. They are the most common tumors of this origin to occur in the head and neck region⁴. Since the majority of cases seem to occur in people residing at high altitudes, chronic hypoxemia has been postulated to be a cause for such tumors⁵. Most patients present with features owing to compression of the lower cranial nerves by the lesion⁶. In few cases, paroxysmal symptoms resulting from excessive circulating catecholamine may be evident^{7,8}.

Examination should begin by assessing the pulsatility of the tumor. It has a characteristic mobility in the horizontal direction whereas it has restricted mobility in the vertical direction. This aspect is also referred to as the 'Fontaine sign'⁹.

Duplex ultrasound study of the carotid vessels is the first line diagnostic imaging modality¹⁰. It helps diagnose the lesion, determine its extent and the involvement of the major vessels. It also aids in simultaneous assessment of both the carotid vessels, to rule out bilateral involvement and carotid artery disease, especially in aged patient groups. In high-risk patients with positive family history or in active catecholamine secreting lesions, this type of imaging can

help rule out multiple infections by evaluating the adrenal glands. Shamblin *et al* classified these highly vascular lesions depending on how they are placed in relation to the carotid vessel, which helps plan their management strategy¹¹. Most high-grade lesions require an adjuvant protocol, either in the form of preoperative embolisation or intra-operative temporary or permanent interposition vascular grafts. Needle biopsy is contraindicated due to the risk of haemorrhage, thrombosis or pseudo-aneurysm¹². It is also advisable to rule out synchronous neural crest lesions by imaging the tympanic cavity and the adrenal glands, especially in patients with positive family history¹³. Although rare, active lesions (seen in around 5% of cases) should be ruled out by assessing the plasma catecholamine or the urinary VMA levels¹⁴.

The risk of intra-operative and post-operative neurological and the vascular complications increases with the grade of the lesions. The size, vascularity and thereby intra-operative blood loss is minimized with the use of embolisation¹⁵. However, there is an inadvertent risk of stroke and increased difficulty in excising the tumor, when it is glued with embolized particles intra-operatively¹⁶.

The first successful excision of a carotid body tumor was performed by Albert J Van Der Kogel in 1889¹⁷. Surgical excision is the management modality of choice, with embolisation and radiotherapy used as adjuncts in a few selected cases¹⁰. Cerebral protection from hypotensive insults during vascular clamping or bypass and management of arrhythmias (following vagal nerve stimulation) during tumor manipulation are some of the challenges faced during the intra-operative period^{18,19}. Surgery may be carried out under local, regional or general anesthesia. Local or cervical plexus block offers the advantage of a continuous neurological assessment to rule out cerebral hypo-perfusion^{20,21}. Blood loss can be minimized with meticulous sub-adventitial dissection of the lesion from the vessel walls. Intra-operative vascular control can be achieved by temporary carotid ligation, use of temporary arterial bypass or by use of vascular inter-position graft in cases of inadvertent tear within the vessels²². Hypotensive anesthesia is another valid option to maintain a bloodless field²³. A temporary clamp of less than 10 minutes is considered safe¹³. The IJV, vagus nerve and hypoglossal nerve should always be isolated and well protected throughout the procedure. The higher the grade of the lesion and the need for repair or reconstruction, the higher the risk of stroke^{24,25}.

Huge carotid body paragangliomas continue to cause a high incidence of pre- and postoperative complications^{17,26}, including peri-operative stroke and persistent nerve palsy²⁷.

Cranial nerve palsy is seen in as high as 40% of cases²⁸. The hypoglossal nerve is the most common nerve to be affected in the post-operative period, thereby undue stretching should be avoided. Mortality has been seen in 3% of cases, with tumors greater than 5 cm²⁹. In cases of transmural involvement of the vessel by the tumor, excision of the main vessel along with the tumor is justified. Internal carotid artery ligation with reconstruction requirements as well as permanent cranial nerve deficits have been observed in 23% of cases, all belonging to Shamblin grade 3 tumors³⁰.

A characteristic Zellballen pattern in the histology and positive staining with neuron-specific enolase (NSE) for Paraganglioma and S100 for sustentacular cells is definitive in diagnosing the tumor³¹.

There are no defined pathological criteria to differentiate benign tumors from their malignant counterpart. Distant metastasis and the involvement of the lymph nodes are the only definitive markers to determine its malignant behavior³².

Malignant transformation and local or distant metastasis is estimated to affect around 10% of cases³³. Follow-up with doppler and duplex ultrasound of the carotid vessels is currently advocated¹⁷.

Lifelong follow-ups are required³⁴. Succinate dehydrogenase (SDH) mutations are commonly seen in young patients, and testing for these may provide us with clues when assessing patients at high risk³⁵.

Conclusions

Large and complicated vascular tumors can be managed with proper planning and execution³⁶. With judicious anesthetic care and meticulous subadventitial dissection, such lesions can be managed even in a rural setup³⁷.

Consent

Written informed consent for publication of clinical data and clinical images was obtained from the patient.

Competing interests

No competing interests were disclosed.

Grant information

The author(s) declared that no grants were involved in supporting this work

References

- Spinelli F, Massara M, La Spada M, *et al.*: **A simple technique to achieve bloodless excision of carotid body tumors.** *J Vasc Surg.* 2014; **59**(5): 1462–1464.
[PubMed Abstract](#) | [Publisher Full Text](#)
- Hinojosa CA, Ortiz-Lopez LJ, Anaya-Ayala JE, *et al.*: **Comparison of retrocarotid and caudocranial dissection techniques for the surgical treatment of carotid body tumors.** *J Vasc Surg.* 2015; **62**(4): 958–964.
[PubMed Abstract](#) | [Publisher Full Text](#)
- Von Haller: Cited by Gratiot JH. **Carotid tumors: A collective review.** *Abstr Surg.* 1943; **7**: 117–186.
- Mathew BK, Bandgar T, Menon PS, *et al.*: **Carotid body tumours: three case reports.** *Singapore Med J.* 2009; **50**(2): e58–e60.
[PubMed Abstract](#)
- Yildiz BS, Sasmazel A, Baysal A, *et al.*: **Assessment of carotid body tumor and its association with tetralogy of fallot: effect of the chronic hypoxia.** *Heart Views.* 2014; **15**(3): 86–88.
[PubMed Abstract](#) | [Publisher Full Text](#) | [Free Full Text](#)
- Padberg FT Jr, Cady B, Persson AV: **Carotid body tumor: The Lahey Clinic experience.** *Am J Surg.* 1983; **145**(4): 526–528.
[PubMed Abstract](#) | [Publisher Full Text](#)
- Wright DJ, Pandya A, Noel F: **Anesthesia for carotid body tumour resection.** *Anaesthesia.* 1979; **34**: 806–808.
[Publisher Full Text](#)
- Knight TT Jr, Gonzalez JA, Rary JM, *et al.*: **Current concepts for the surgical management of carotid body tumor.** *Am J Surg.* 2006; **191**(1): 104–10.
[PubMed Abstract](#) | [Publisher Full Text](#)
- Wang SH, Chiu KM, Cheng PW: **Bilateral carotid body paragangliomas.** *CMAJ.* 2011; **183**(9): E606.
[PubMed Abstract](#) | [Publisher Full Text](#) | [Free Full Text](#)
- Tong Y: **Role of duplex ultrasound in the diagnosis and assessment of carotid body tumour: A literature review.** *Intractable Rare Dis Res.* 2012; **1**(3): 129–133.
[PubMed Abstract](#) | [Free Full Text](#)
- Shamblin WR, ReMine WH, Sheps SG, *et al.*: **Carotid body tumor (chemodectoma). Clinicopathologic analysis of ninety cases.** *Am J Surg.* 1971; **122**(6): 732–39.
[PubMed Abstract](#) | [Publisher Full Text](#)
- Staats EF, Brown RL, Smith RR: **Carotid body tumors, benign and malignant.** *Laryngoscope.* 1966; **76**(5): 907–916.
[Publisher Full Text](#)
- Patetsios P, Gable DR, Garrett WV, *et al.*: **Management of carotid body paragangliomas and review of a 30-year experience.** *Ann Vasc Surg.* 2002; **16**(3): 331–8.
[PubMed Abstract](#) | [Publisher Full Text](#)
- Pellitteri PK, Rinaldo A, Myssiorek D, *et al.*: **Paragangliomas of the head and neck.** *Oral Oncol.* 2004; **40**(6): 563–75.
[PubMed Abstract](#) | [Publisher Full Text](#)
- Thakkar R, Qazi U, Kim Y, *et al.*: **Technique and Role of Embolization using Ethylene Vinyl-Alcohol Copolymer before Carotid Body Tumor Resection.** *Clinics and Practice.* 2014; **4**(3): 661.
[Publisher Full Text](#)
- Krishnamoorthy T, Gupta AK, Rajan JE, *et al.*: **Stroke from delayed embolization of polymerized glue following percutaneous direct injection of a carotid body tumor.** *Korean J Radiol.* 2007; **8**(3): 249–253.
[PubMed Abstract](#) | [Publisher Full Text](#) | [Free Full Text](#)
- Sajid MS, Hamilton G, Baker DM, *et al.*: **A multicenter review of carotid body tumour excision: A case report and brief review.** *Anesth Essays Res.* 2014; **8**(2): 127–130.
[PubMed Abstract](#) | [Publisher Full Text](#)
- Karigar SL, Kunakeri S, Shetti AN: **Anesthetic management of carotid body tumor excision: A case report and brief review.** *Anesth Essays Res.* 2014; **8**(2): 259–262.
[PubMed Abstract](#) | [Publisher Full Text](#) | [Free Full Text](#)
- Kavakli AS, Ozturk NK: **Anesthetic approaches in carotid body tumor surgery.** *North Clin Istanb.* 2016; **3**(2): 97–103.
[PubMed Abstract](#) | [Publisher Full Text](#) | [Free Full Text](#)
- Tokta F, Yümün G, Gücü A, *et al.*: **Protective Surgical Procedures for Carotid Body Tumors: A Case Series.** *Erciyes Med J.* 2014; **36**(3): 133–5.
[Publisher Full Text](#)
- Jones HG, Stoneham MD: **Continuous cervical plexus block for carotid body tumour excision in a patient with Eisenmenger's syndrome.** *Anaesthesia.* 2006; **61**(12): 1214–8.
[PubMed Abstract](#) | [Publisher Full Text](#)
- Zeng G, Zhao J, Ma Y, *et al.*: **Use of an intraoperative shunt for easy resection of complicated carotid body tumors.** *Head Neck.* 2013; **35**(1): 61–4.
[PubMed Abstract](#) | [Publisher Full Text](#)
- O'Neill S, O'Donnell M, Harkin D, *et al.*: **A 22-year Northern Irish experience of carotid body tumours.** *Ulster Med J.* 2011; **80**(3): 133–140.
[PubMed Abstract](#) | [Publisher Full Text](#) | [Free Full Text](#)
- Gwon JG, Kwon TW, Kim H, *et al.*: **Risk factors for stroke during surgery for carotid body tumors.** *World J Surg.* 2011; **35**(9): 2154–8.
[PubMed Abstract](#) | [Publisher Full Text](#)
- Kakkos SK, Reddy DJ, Shepard AD, *et al.*: **Contemporary presentation and evolution of management of neck paragangliomas.** *J Vasc Surg.* 2009; **49**(6): 1365–73.e2.
[PubMed Abstract](#) | [Publisher Full Text](#)
- Elsharawy MA, Alsaif H, Elsaid A, *et al.*: **Management of sizeable carotid body**

- tumor: Case report and review of literature.** *Avicenna J Med.* 2013; **3**(4): 106–108.
[PubMed Abstract](#) | [Publisher Full Text](#) | [Free Full Text](#)
27. Sen I, Stephen E, Malepathi K, *et al.*: **Neurological complications in carotid body tumors: a 6-year single-center experience.** *J Vasc Surg.* 2013; **57**(2 Suppl): 64–8S.
[PubMed Abstract](#) | [Publisher Full Text](#)
28. Por YC, Lim DT, Teoh MK, *et al.*: **Surgical management and outcome of carotid body tumours.** *Ann Acad Med Singapore.* 2002; **31**(2): 141–4.
[PubMed Abstract](#)
29. Luna-Ortiz K, Rascon-Ortiz M, Villavicencio-Valencia V, *et al.*: **Does Shamblin's classification predict postoperative morbidity in carotid body tumors? A proposal to modify Shamblin's classification.** *Eur Arch Otorhinolaryngol.* 2006; **263**(2): 171–175.
[PubMed Abstract](#) | [Publisher Full Text](#)
30. Lim JY, Kim J, Kim SH, *et al.*: **Surgical treatment of carotid body paragangliomas: outcomes and complications according to the shamblin classification.** *Clin Exp Otorhinolaryngol.* 2010; **3**(2): 91–95.
[PubMed Abstract](#) | [Publisher Full Text](#) | [Free Full Text](#)
31. Wieneke JA, Smith A: **Paraganglioma: carotid body tumor.** *Head Neck Pathol.* 2009; **3**(4): 303–306.
[PubMed Abstract](#) | [Publisher Full Text](#) | [Free Full Text](#)
32. Mendenhall W, Werning J, Peister D: **Treatment of head and neck cancer (Paragangliomas).** In: Devia V, Lawrence T, Rosenberg S, eds. *Cancer: Principles and Practice of Oncology*, 9th ed. Philadelphia: Lippincott, 2011; 722–3.
33. Wang SJ, Wang MB, Barauskas TM, *et al.*: **Surgical management of carotid body tumors.** *Otolaryngol Head Neck Surg.* 2000; **123**(3): 202–206.
[PubMed Abstract](#) | [Publisher Full Text](#)
34. Kollert M, Minovi AA, Draf W, *et al.*: **Cervical paragangliomas-tumor control and long-term functional results after surgery.** *Skull Base.* 2006; **16**(4): 185–191.
[PubMed Abstract](#) | [Publisher Full Text](#) | [Free Full Text](#)
35. Davila VJ, Chang JM, Stone WM, *et al.*: **Current surgical management of carotid body tumors.** *J Vasc Surg.* 2016; **64**(6): 1703–1710.
[PubMed Abstract](#) | [Publisher Full Text](#)
36. Galyfos G, Stamatatos I, Kerasidis S, *et al.*: **Multidisciplinary Management of Carotid Body Tumors in a Tertiary Urban Institution.** *Int J Vasc Med.* 2015; **2015**: 969372.
[PubMed Abstract](#) | [Publisher Full Text](#) | [Free Full Text](#)
37. Wani B, Agni N, Rathod V, *et al.*: **Rural centre based management of the carotid body tumour.** *Indian J Otolaryngol Head Neck Surg.* 2011; **63**(Suppl 1): 107–109.
[PubMed Abstract](#) | [Publisher Full Text](#) | [Free Full Text](#)

Open Peer Review

Current Referee Status:



Version 1

Referee Report 11 December 2017

doi:10.5256/f1000research.13784.r28491



Guru Dutta Satyarthee

Department of Neurosurgery, Neurosciences Centre, All India Institute of Medical Sciences (AIIMS), Gamma Knife Centre, New Delhi, Delhi, India

Paragangliomas are neoplasms arising from extra-adrenal chromaffin tissue. It frequently cause symptoms by overproduction of catecholamines and carry risk of hypertension during surgery and post-excision, patient may develop hemodynamic instability [1]. Carotid body tumor is a slow-growing neoplasm, usually localized at the bifurcation of the common carotid artery represent most commonly encountered are head and neck paragangliomas, accounting for 60–78% [2]. It is usually benign and rarely malignant and accounts for about 0.5% of all head and neck tumors [2].

In 1971, Shamblin *et al.* classified carotid body tumor into three classes: in Class I tumor is small and surgically resectable, Class II includes adherent tumor, which surrounding the carotid vessels partially, resection is considered as technically more difficult, and class III, the size of the tumor is large ie more than 5 cm and usually completely encases the carotid vessels, resection is considered very difficult, and always carry risk of the cerebral circulation interruption always [3].

DSA is considered as important imaging modality of choice for diagnosis as clearly defines, epicentre of tumor, location, size and encasement of vessel branches in tumor and aid in aiding transarterial embolization therapy which reduces intraoperative blood loss. However, it carry limitation poor visualization of adherence of the tumor mass to the peripheral tissues, cerebral embolism causing ischemic stroke and vascular injury are also reported and even risk cardiac asystole with carotid body hypersensitivity. However DSA of cerebral vessels including cross circulation is essential if needed of cerebral vessel revascularization surgery is required [4]. So, currently, computed tomography scan, CT angiography and MRI are preferred routinely .

Surgery is preferred treatment modality and chief concern s include highly vascular mass, dense adherence to the vagus nerve. Hua *et al* observed microneurosurgical technique is said in dissection. And prevent vascular and cranial nerve injury [1]. Radiotherapy is an alternative management option for patients with co-morbid illness or who may not tolerate the surgery, presence of metastasis subsequent to surgery complications include otitis externa, otitis media, osteoradionecrosis, cranial nerve lesion and brain injury [5]. Munakomi and neuroanesthesia team should be commended for successful surgery, perioperative hemodynamic adequate control with good outcome.

References

1. Hua Q, Xu Z, Jiang Y: Diagnosis and surgical treatment of carotid body tumor: A retrospective analysis of 58 patients. *Oncol Lett.* 2017; **14** (3): 3628-3632 [PubMed Abstract](#) | [Publisher Full Text](#)

2. Kollert M, Minovi AA, Draf W, Bockmühl U: Cervical paragangliomas-tumor control and long-term functional results after surgery. *Skull Base*. 2006; **16** (4): 185-91 [PubMed Abstract](#) | [Publisher Full Text](#)
3. Shamblin WR, ReMine WH, Sheps SG, Harrison EG: Carotid body tumor (chemodectoma). Clinicopathologic analysis of ninety cases. *Am J Surg*. 1971; **122** (6): 732-9 [PubMed Abstract](#)
4. Power AH, Bower TC, Kasperbauer J, Link MJ, Oderich G, Cloft H, Young WF, Gloviczki P: Impact of preoperative embolization on outcomes of carotid body tumor resections. *J Vasc Surg*. 2012; **56** (4): 979-89 [PubMed Abstract](#) | [Publisher Full Text](#)
5. Künzel J, Koch M, Brase C, Fietkau R, Iro H, Zenk J: Treatment of cervical paragangliomas: is surgery the only way?. *Am J Otolaryngol*. **35** (2): 186-91 [PubMed Abstract](#) | [Publisher Full Text](#)

Is the background of the case's history and progression described in sufficient detail?

Yes

Are enough details provided of any physical examination and diagnostic tests, treatment given and outcomes?

Yes

Is sufficient discussion included of the importance of the findings and their relevance to future understanding of disease processes, diagnosis or treatment?

Yes

Is the case presented with sufficient detail to be useful for other practitioners?

Yes

Competing Interests: No competing interests were disclosed.

I have read this submission. I believe that I have an appropriate level of expertise to confirm that it is of an acceptable scientific standard.

Referee Report 01 December 2017

doi:10.5256/f1000research.13784.r28506



Luis Rafael Moscote-Salazar ^{1,2}, **Alexis Narvaez-Rojas** ³

¹ Department of Neurosurgery, RED LATINO (Latin American Trauma & Intensive Neurocare Organization), Bogotá, Colombia

² University of Cartagena, Cartagena, Colombia

³ Universidad Nacional Autónoma de Nicaragua, Managua, Nicaragua

Paragangliomas are a type of infrequent head and neck tumor originating in the paraganglionic brachymeric tissue involved in the development of the branchial arches. Five families of paragangliomas have been described:

Brachymeric, intravagal, sympathetic, viscerio-autonomic and adrenal. At the histopathological level, this type of tumors has an identical configuration regardless of its origin. Sporadic cases of this class of tumors are more frequent in females. A high frequency of this class of tumors has been established in patients who live at high altitudes and those suffering from the chronic obstructive disease. It has been suggested that chronic hypoxemia plays a role in the genesis of this class of tumors

Munakomi *et al.* presented a very well documented case and with successful resolution managed in a resource-limited setting.

The therapeutic choice depends fundamentally on the location of this kind of tumors, the size of the lesion, age, health status of the patient plus the experience of the surgeons. The use of various resources as angiography and preoperative embolization suggests that this type of tumors should be ideally managed in third-level care centers. The case managed by Munakomi *et al.* testifies that the preparation and expertise of the surgeon are fundamental for the successful resolution of this class of injuries.

Finally, it is important to mention that this type of tumors has a significant risk of urinary complications and several postoperative complications have been described, including cranial nerve lesions, cerebral infarction, hemorrhages among others.

Is the background of the case's history and progression described in sufficient detail?

Yes

Are enough details provided of any physical examination and diagnostic tests, treatment given and outcomes?

Yes

Is sufficient discussion included of the importance of the findings and their relevance to future understanding of disease processes, diagnosis or treatment?

Yes

Is the case presented with sufficient detail to be useful for other practitioners?

Yes

Competing Interests: No competing interests were disclosed.

We have read this submission. We believe that we have an appropriate level of expertise to confirm that it is of an acceptable scientific standard.

Referee Report 24 November 2017

doi:[10.5256/f1000research.13784.r27906](https://doi.org/10.5256/f1000research.13784.r27906)



Yi Guo

Department of Neurosurgery, Tsinghua Changgung Hospital, Beijing, China

This is a well-written case report about how to manage a Shamblin Grade 3 carotid body tumor (CBT). Though surgery is first-line treatment of CBT, it remains a challenge because it's highly vascular and adherent to the vagus nerve in high-grade CBT. The authors discussed the diagnosis and treatment of CBT in detail. In large tumors like this case, cerebral collateral circulation should be evaluated in case of vessel transplantation or ligation performed. HyperForm might be used for intra-operative distal vascular control if tumor is very large to reach the skull base. However, in a resource-limited setting it is difficult for detailed pre-operative evaluation and intra-operative vascular control.

Is the background of the case's history and progression described in sufficient detail?

Yes

Are enough details provided of any physical examination and diagnostic tests, treatment given and outcomes?

Yes

Is sufficient discussion included of the importance of the findings and their relevance to future understanding of disease processes, diagnosis or treatment?

Yes

Is the case presented with sufficient detail to be useful for other practitioners?

Yes

Competing Interests: No competing interests were disclosed.

I have read this submission. I believe that I have an appropriate level of expertise to confirm that it is of an acceptable scientific standard.

Referee Report 13 November 2017

doi:10.5256/f1000research.13784.r26639



Arif Hussian Sarmast 

Department of Neurosurgery, Jawaharlal Nehru Medical College, Aligarh Muslim University, Aligarh Uttar Pradesh, India

It is a very beautifully written case report, however I would like to clarify from the authors how a giant carotid body tumour is to be addressed in a normal setting, resource limitation does not change the management in a big chunk of cases like that. It needs a change in headline.

Is the background of the case's history and progression described in sufficient detail?

Yes

Are enough details provided of any physical examination and diagnostic tests, treatment given and outcomes?

Yes

Is sufficient discussion included of the importance of the findings and their relevance to future understanding of disease processes, diagnosis or treatment?

Yes

Is the case presented with sufficient detail to be useful for other practitioners?

Yes

Competing Interests: No competing interests were disclosed.

I have read this submission. I believe that I have an appropriate level of expertise to confirm that it is of an acceptable scientific standard, however I have significant reservations, as outlined above.

The benefits of publishing with F1000Research:

- Your article is published within days, with no editorial bias
- You can publish traditional articles, null/negative results, case reports, data notes and more
- The peer review process is transparent and collaborative
- Your article is indexed in PubMed after passing peer review
- Dedicated customer support at every stage

For pre-submission enquiries, contact research@f1000.com

F1000Research