

Pelvic Venous Thromboembolism Leading to Pulmonary Embolism in a Case of Chondroblastic Osteosarcoma Detected on FDG PET/CT

Abstract

Chondroblastic osteosarcoma is an uncommon subtype of osteosarcoma, constituting about 25% of all osteosarcoma cases. It has shown high propensity for developing tumor thrombi and thromboembolism, with poor overall survival rate. Differentiation between tumor thrombus and bland thrombus is an important factor in making treatment decisions. 18 F fluorodeoxyglucose positron emission tomography/computed tomography plays a very important role in detecting and differentiating bland thrombus from tumor thrombus.

Keywords: 18 F fluorodeoxyglucose positron emission tomography/computed tomography, chondroblastic osteosarcoma, inferior vena cava thrombus, pulmonary artery embolism, tumor embolus, tumor thrombus

Introduction

Osteosarcoma can be divided based on the tumor matrix into osteoblastic, chondroblastic, and fibroblastic subtypes. Chondroblastic is a rare subtype with heterogeneous chondroid and myxoid stroma.^[1] It constitutes about 25% of all osteosarcoma. It has poor 5-year overall survival of 38%.^[2] It usually presents as progressively worsening pain and swelling involving distal extremities. This subtype of osteosarcoma usually has the most deleterious course as it has resistance to most of the chemotherapy regimens and high propensity for developing thromboembolic events, with life-threatening consequences.^[3] The differentiation of tumor thrombus from bland thrombus is essential in therapeutic decision-making. Here, we are presenting a case of chondroblastic osteosarcoma of pelvis with tumor thromboembolism detected in 18 F fluorodeoxyglucose positron emission tomography/computed tomography (FDG PET/CT) scan.

Interesting Image

An 18-year-old female presented with a history of pain and swelling in the right hip region for 4 months, magnetic resonance imaging done outside showed abnormal

signal intensity involving right pelvic bone extending to sacrum with overlying cortical destruction. Fine-needle aspiration cytology was conclusive of chondroblastic osteosarcoma. 18 F FDG PET/CT was done for presurgical staging.

Maximum intensity projection images [Figure 1a] showed FDG-avid bulky lesion in the right hemipelvis, which was the site of primary. Adjacent to the primary mass linear vertical FDG uptake was noted in the abdominopelvic region. In addition, an FDG-avid branching pattern was seen in thoracic region extending to bilateral pulmonary regions.

Fused PET/contrast-enhanced computed tomography (CECT) and CECT images of abdominopelvis showed hypermetabolic primary right hemipelvic mass invading into pelvic vasculature with filling defect extending along right iliac vein to inferior vena cava (IVC) [Figure 1d and e]. Axial [Figure 1c] and sagittal fused PET/CT [Figure 1b] images of thorax showed FDG-avid contrast filling defect tracking along bilateral pulmonary arteries and extending superiorly and inferiorly along bilateral lobar, interlobar, and segmental branches.

These findings are suggestive of extensive thrombus in IVC, leading to bilateral

**Anjali Prakash,
Ameya D Puranik,
Nilendu C
Purandare, Archi
Agrawal, Sneha
Shah, Venkatesh
Rangarajan**

Department of Nuclear Medicine and Molecular Imaging, Tata Memorial Hospital, Homi Bhabha National Institute, Mumbai, Maharashtra, India

Address for correspondence:

*Dr. Ameya D. Puranik,
Department of Nuclear Medicine and Molecular Imaging, Tata Memorial Hospital, E. Borges Road, Parel, Mumbai - 400 012, Maharashtra, India.
E-mail: ameya2812@gmail.com*

Received: 22-12-2020

Accepted: 06-04-2021

Published: 21-06-2021

Access this article online

Website: www.ijnm.in

DOI: 10.4103/ijnm.ijnm_239_20

Quick Response Code:



How to cite this article: Prakash A, Puranik AD, Purandare NC, Agrawal A, Shah S, Rangarajan V. Pelvic venous thromboembolism leading to pulmonary embolism in a case of chondroblastic osteosarcoma detected on FDG PET/CT. Indian J Nucl Med 2021;36:231-2.

This is an open access journal, and articles are distributed under the terms of the Creative Commons Attribution-NonCommercial-ShareAlike 4.0 License, which allows others to remix, tweak, and build upon the work non-commercially, as long as appropriate credit is given and the new creations are licensed under the identical terms.

For reprints contact: WKHLRPMedknow_reprints@wolterskluwer.com

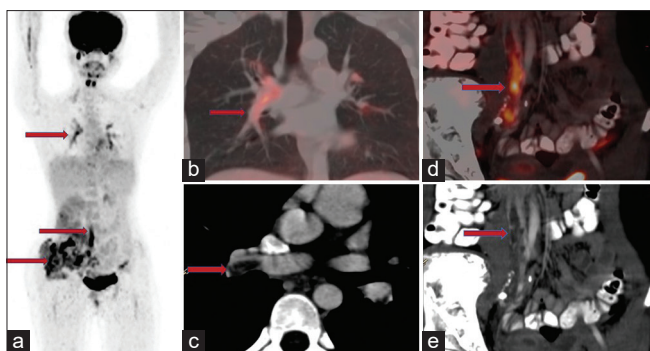


Figure 1: (a) Maximum intensity projection image showing FDG avid lesions in right hemipelvis, linear uptake along abdomino-pelvic region and branching uptake from bilateral lung hila (red arrows). (b) FDG PET/CECT fusion image sagittal section showing FDG avid filling defect in bilateral pulmonary artery tracking along lobar and interlobar branches (arrow), (c) CECT chest axial imaging showing contrast filling defect in bilateral pulmonary arteries, (d) FDG PET/CECT fusion image sagittal section showing FDG avid filling defect tracking from left iliac vein to IVC (arrow), seen as filling defect on CECT (e-arrow) image

pulmonary arterial embolism. The patient was immediately shifted to intensive care unit and treatment was initiated.

Discussion

Pulmonary embolism represents a potential life-threatening complication of venous thrombosis, which remains clinically occult in majority of cases. In addition to direct tumor thrombus formation, the incidence of thrombosis is significantly elevated in patients with malignancy due to a hypercoagulable state.^[4]

On CECT, embolus may be demonstrated as an intraluminal filling defect causing complete arterial occlusion with failure to opacify the entire lumen, with or without vascular enlargement, or as a central arterial filling defect surrounded by intravascular contrast enhancement.

Although regional CECT can show intravascular filling defects, the differentiation of tumor thrombus from bland thrombus is essential, because the former will not benefit from anticoagulation therapy, which cannot be concluded by conventional imaging. 18 F FDG PET/CT is more specific than conventional imaging to diagnose FDG-avid tumor thrombus arising from solid tumors. Fused PET-CT images can delineate involved blood vessels, distinguishing blood pool activity from active metabolism by the tumor

thrombus. There are reports on extensive thrombus formation in IVC and femoral vein, with embolization in cases of chondroblastic osteosarcoma, resulting in life-threatening consequences.^[5,6]

FDG PET provides whole body evaluation, as a result of which, the etiology of embolism can be picked up. As seen in our case, the pulmonary emboli originated from the venous thrombus caused by the locally invasive bone primary. Thus, FDG PET/CT proves to be a single sensitive modality which depicts the extent of primary tumor as well as the associated anticipated and unanticipated complications.

Declaration of patient consent

The authors certify that they have obtained all appropriate patient consent forms. In the form the patient (s) has/have given his/her/their consent for his/her/their images and other clinical information to be reported in the journal. The patients understand that their names and initials will not be published and due efforts will be made to conceal their identity, but anonymity cannot be guaranteed.

Financial support and sponsorship

Nil.

Conflicts of interest

There are no conflicts of interest.

References

1. Chen W, DiFrancesco LM. Chondroblastoma: An Update. *Arch Pathol Lab Med* 2017;141:867-71.
2. Mirabello L, Troisi RJ, Savage SA. Osteosarcoma incidence and survival rates from 1973 to 2004: Data from the Surveillance, Epidemiology, and End Results Program. *Cancer* 2009;115:1531-43.
3. Almeida E, Mascarenhas BA, Cerqueira A, Medrado AR. Chondroblastic osteosarcoma. *J Oral Maxillofac Pathol* 2014;18:464-8.
4. Marcoux C, Al Ghamdi S, Manos D, Keating M, Shivakumar S. Natural History of Tumor Thrombus: A Single-Centre Retrospective Study *Blood* 2019;134:2430-243.
5. Ahmed AA, Heller DS. Fatal pulmonary tumor embolism caused by chondroblastic osteosarcoma: Report of a case and review of the literature. *Arch Pathol Lab Med* 1999;123:437-40.
6. Purandare NC, Dua SG, Rangarajan V, Shah S, Sharma AR. Pulmonary artery and femoral vein tumour thromboembolism in a patient with osteogenic sarcoma demonstrated by FDG PET/CT. *Eur J Nucl Med Mol Imaging* 2010;37:653.