



## Educational Case

### Educational Case: Cranial hemorrhage and traumatic brain injury

Molly Stalons, BS<sup>a</sup>, David S. Priemer, MD<sup>a,b,c,\*</sup>, Barbara E.C. Knollmann-Ritschel, MD<sup>a</sup>

<sup>a</sup> Department of Pathology, Uniformed Services University School of Medicine, Bethesda, MD, USA

<sup>b</sup> Department of Defense/Uniformed Services University Brain Tissue Repository, Bethesda, MD, USA

<sup>c</sup> Henry M. Jackson Foundation for the Advancement of Military Medicine Inc, Bethesda, MD, USA

The following fictional case is intended as a learning tool within the Pathology Competencies for Medical Education (PCME), a set of national standards for teaching pathology. These are divided into three basic competencies: Disease Mechanisms and Processes, Organ System Pathology, and Diagnostic Medicine and Therapeutic Pathology. For additional information, and a full list of learning objectives for all three competencies, see <https://www.journals.elsevier.com/academic-pathology/news/pathology-competencies-for-medical-education-pcme>.<sup>1</sup>

**Keywords:** Pathology competencies, Organ system pathology, Central nervous system, Ischemia of the brain, Cranial hemorrhage, Epidural, Subdural, Traumatic brain injury

#### Primary objective

Objective NSC7.3: Cranial Hemorrhage. Compare and contrast the etiologies and clinical presentations of epidural, subdural, subarachnoid hemorrhages, basal ganglionic, and lobar hemorrhages.

Competency 2: Organ System Pathology; Topic NSC: Nervous System–Central Nervous System; Learning Goal 7: Ischemia of the Brain.

#### Secondary objective

Objective NSC7.2: Traumatic Brain Injury. Describe the pathologic findings seen in the most common causes of traumatic brain injury.

Competency 2: Organ System Pathology; Topic NSC: Nervous System - Central Nervous System; Learning Goal 7: Ischemia of the Brain.

#### Patient presentation, 1

A 24-year-old woman is brought to the Emergency Department (ED) following a motor vehicle accident in which her vehicle was broadsided by another vehicle causing her to be ejected from the front passenger seat. This is the first of two injured victims at the scene; the other was in the car that caused the accident, and that patient is still en route. Per the responding emergency medical technician report, the patient was responsive at the scene and answered questions despite having been ejected 15 m from the vehicle through the windshield. First responders report that the patient was not properly restrained by a seatbelt. En route to the ED, she complained of

having a severe headache and vomited. On arrival, she is unable to answer questions due to fluctuating levels of consciousness.

#### Diagnostic findings, Part 1

On physical examination, the vital signs include a blood pressure of 157/81 mmHg, a pulse of 50/min, respirations of 14/min with irregular breathing, and the patient is unable to communicate her pain level. On ophthalmologic examination, the patient is found to have right-sided pupil dilation. She is evaluated via the Glasgow Coma Scale (GCS) and has a score of 10 of 15 as she is only opening her eyes to painful stimuli (eye response: 2 out of 4); she responds to all questions by murmuring “my head hurts” and does not appear to know where she is (verbal response: 4 out of 5) and withdraws to pain but does not follow commands (motor response: 4 out of 6). She is found to have no other injuries on primary and secondary surveys apart from scattered ecchymosis forming on the right side of her head and abrasions on her right shoulder. A focused assessment with sonography in trauma (FAST) exam shows no peritoneal fluid. A stat computer tomography (CT) scan is ordered.

#### Questions/discussion points, Part 1

**What is the differential diagnosis based on the patient’s presentation, physical examination, and diagnostic findings?**

The differential diagnosis for this patient would be broad and include acute blood loss/hemorrhagic shock, skull fracture(s) from trauma,

\* Corresponding author. Department of Pathology, Uniformed Services University of the Health Sciences, 4301 Jones Bridge Rd., Bethesda, MD, 20814, USA.

E-mail address: [david.priemer.ctr@usuhs.edu](mailto:david.priemer.ctr@usuhs.edu) (D.S. Priemer).

<https://doi.org/10.1016/j.acpath.2022.100028>

Received 16 July 2021; Received in revised form 29 October 2021; Accepted 9 November 2021; Available online xxxx

eISSN2374-2895/© 2022 The Author(s). Published by Elsevier Inc. on behalf of Association of Pathology Chairs. This is an open access article under the CC BY-NC-ND license (<http://creativecommons.org/licenses/by-nc-nd/4.0/>).

traumatic brain injury (TBI) and/or intracranial hemorrhage, traumatic cervical spine injury, non-traumatic intracranial hemorrhage and/or stroke, and migraine headaches. Acute blood loss causing hemorrhagic or hypovolemic shock can present with loss of consciousness; however, tachycardia and a narrowed pulse pressure (decreased systolic blood pressure), with pale cold skin are more characteristic of hypovolemic shock. Skull fracture(s) and concussion may both present with headache and acute loss of consciousness due to brain injury or other secondary injury from the fracture(s). In a younger person, greater force is needed to fracture the skull due to higher bone density, relative to that found in an older person; nonetheless, a CT scan would be helpful to diagnose a fracture. In terms of brain injury itself, however, a CT scan may be negative in the setting of a concussion and/or mild and some moderate TBIs. Migraines and cluster headaches can also cause severe head pain; this would be a diagnosis of exclusion in this patient post-trauma from the car accident and ejection from the car. Traumatic cervical spine injury may present with irregular and/or decreased respirations, sometimes referred to as agonal breathing, due to the loss of innervation of the diaphragm and accessory muscles. Thromboembolic stroke is less likely in this patient's presentation due to her young age and the history of the car accident as a mechanism of injury. However, stroke should always remain on the differential as it could have precipitated the car accident, although this is seen more frequently in the elderly population. Increased intracranial pressure (ICP) could explain this patient's headache, and can occur in numerous circumstances, including skull fracture, brain trauma, vascular leakage, infection, or tumors. ICP needs to be emergently managed as it can progress to intracranial hypertension.

### **What is the most likely cause of this patient's presentation?**

The patient's presentation is most concerning for ICP progressing to intracranial hypertension (ICH) due to intracranial hemorrhage, ultimately secondary to trauma. Intracranial hypertension can be due to a variety of causes but essentially results from an increase of volume or mass inside the cranium, including increase in brain volume such as in cerebral swelling (i.e., edema), collection of cerebrospinal fluid (hydrocephalus), increase in blood volume (e.g., congestion or hemorrhage), or other mass effects such as that from a tumor.<sup>2</sup>

### **What are the etiologies of intracranial hemorrhages, and how are they classified?**

Intracranial hemorrhages are divided based on their location relative to the brain and the meninges surrounding the brain. The intracranial hemorrhage locations that are most often associated with trauma are epidural, subdural, subarachnoid, and intraparenchymal.<sup>3</sup> Hemorrhage into the epidural and subdural spaces most commonly occurs due to trauma, while clinically significant bleeding into the subarachnoid space is more often due to vascular abnormalities.<sup>3</sup> Intraparenchymal bleeding can be seen in a variety of different settings, including trauma, and non-traumatic instances such as including stroke, vascular abnormalities, or tumor.<sup>3</sup>

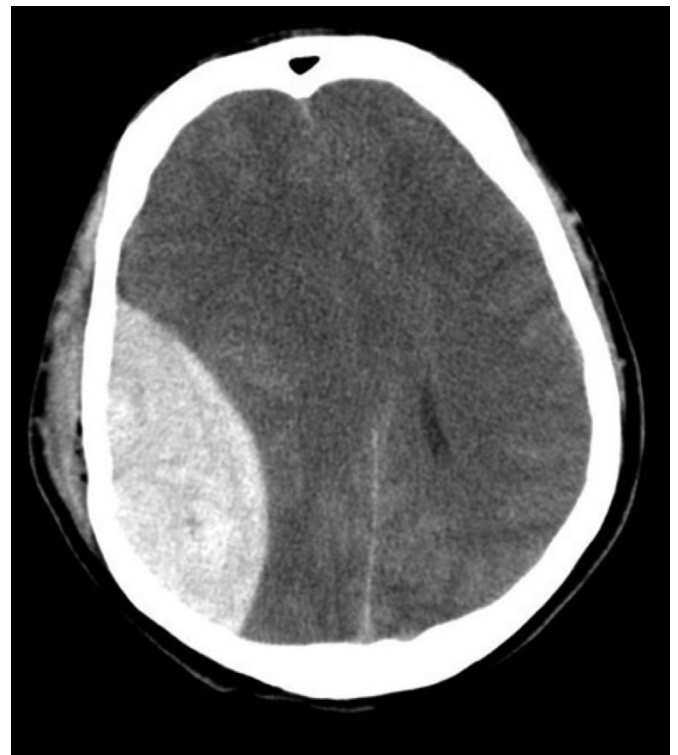
### **Diagnostic findings, Part 2**

Results of the head CT scan of the patient are returned (shown in Fig. 1). The patient is rushed to surgery to relieve the pressure from the hematoma. Intraoperative findings included a 100 ml hematoma superficial to the dura, and this was evacuated without complication. The patient does well with the surgery and has a resolution of her symptoms.

### **Questions/discussion, Part 2**

#### **What does the CT scan of the head show?**

The CT scan in Fig. 1 reveals a biconvex fluid collection associated with a fracture. This, combined with the patients' physical presentation, is



**Fig. 1.** Axial noncontrast CT scan of the brain, right-sided epidural hemorrhage. Source: Reproduced from [Radiopaedia.org](https://radiopaedia.org), rID: 4458, case courtesy of Dr. Sandeep Bhuta, under the Creative Commons Attribution BY-NC-SA 3.0.

strongly suggestive of a hematoma leading to intracranial hypertension.

### **What type of hematoma does the patient have based on her presentation, imaging, trauma, and time course?**

The patient most likely has an epidural—also known as an extradural—hematoma, which is characteristically seen on CT scan as a biconvex hyperdense area with a smooth contour, as seen in Fig. 1. This expanding hematoma causes increased intracranial hypertension due to mass effect within the fixed skull.<sup>2</sup> Epidural hemorrhages can be detected with a CT scan and/or magnetic resonance imaging (MRI).

### **What causes an epidural hematoma?**

Epidural hemorrhages are commonly associated with a fracture of the temporal bone.<sup>4</sup> The temporal bone overlies the middle meningeal artery, and fractures to this bone commonly cross the course of the vessel, disrupting the integrity of the vessel and causing a bleed.<sup>5</sup> Epidural hematomas are arterial bleeds with arterial pressure behind them. This pressure causes the outer layer of the dura mater, the endosteal layer, which is normally fused to the internal surface of the skull, to separate from the skull. Blood collects in the area superficial to the endosteal dura, hence the name epidural.<sup>3</sup> The hematoma appears biconvex due to the high pressure of the arterial blood and the cranial sutures, which typically limit the spread of the hematoma.

Due to the force required to fracture the temporal bone, epidural hematomas are more often associated with high-energy mechanisms of injury, such as motor vehicle accidents and severe blows to the head, as opposed to other types of cranial hemorrhages.<sup>5</sup>

Epidural hematomas tend to present in a younger population of patients, with a median age of 35 years.<sup>5</sup> This is younger than the population age associated with other types of intracranial hemorrhages due to trauma. Multiple factors likely contribute to this population shift,

including less adherent dural attachments in this younger age group and increased high risk-taking behavior resulting in an increased rate of motor vehicle accidents and falls from great heights.<sup>5</sup>

**What is the typical clinical presentation of epidural hematomas?**

After the initial trauma, patients with an epidural hematoma may have a brief period of unconsciousness followed by a “lucid interval,” which is a period in which they have no symptoms or improved symptoms, such as a headache only. This period may last for several hours and may be followed by rapid decompensation due to the mass effect of the expanding hematoma.<sup>3</sup>

**What is the treatment of epidural hematomas?**

If the hemorrhage is small, it can be managed conservatively. If signs of ICH are found, then treatment is to remove the pressure by evacuating the blood clot surgically.<sup>4</sup> Despite initial presentation, epidural hematoma has the second-lowest mortality and a higher percentage of patients making a full recovery as compared to other types of trauma-induced cranial hemorrhage.<sup>5</sup>

It is important to contrast the presentation and imaging findings of other types of cranial hemorrhages that commonly result from trauma. These are discussed below based on the location of the intracranial hemorrhage, and are summarized in Table 1.

**Subdural Hematoma**

**What are the findings seen in subdural hematomas on imaging?**

Acute subdural hematomas are venous bleeds. They appear as collected blood along the brain surface, often in a crescent or sickle shape that may cross suture lines. This type of bleed is most often easily distinguishable by a CT scan. The brain is slightly flattened, as seen in Fig. 2. Subdural hematomas are commonly seen over the lateral aspects of the cerebral hemispheres.<sup>3</sup> On imaging, subdural hematomas may present acutely or with evidence of a chronic bleed as discussed below.

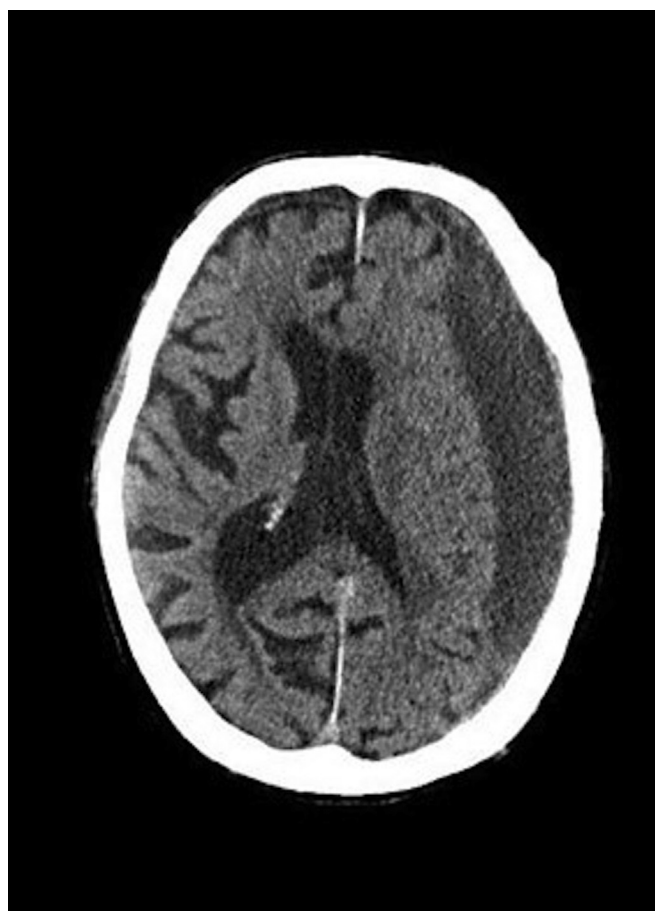

Fig. 2. Axial noncontrast CT scan of the brain, left-sided subdural hematoma. Source: Reproduced from Radiopaedia.org, rID:71635, courtesy of Dr. Adam Eid Ramsey, under the Creative Commons Attribution BY-NC-SA 3.0.

**Table 1**

Comparison of the major types of cerebral hemorrhage. The typical radiographic findings, location of the bleed, mechanism, blood source, and patient presentations are listed for comparison.

Type of Hemorrhage	Radiograph findings	Location of bleed:	Mechanism	Blood source:	Patient presentation:
Epidural/ Extradural Hemorrhage	Lens shaped biconvex hyperdensity with smooth contour, bound by suture lines	Between the endosteal layer of the dura and the skull, limited by cranial sutures	Average age: 35 years; due to high force blunt trauma often resulting in a skull fracture	Arterial blood, most often from the middle meningeal artery	Brief period of unconsciousness followed by headache or no symptoms with characteristic rapid decompensation within a few hours
Subdural Hemorrhage	Crescent/Sickle shape hyperdensity	Subdural space between the dura and the arachnoid mater crosses suture lines	Acute: commonly seen in infants and the elderly Chronic: often seen in the elderly due to multiple recurrent falls or other minor trauma	Venous blood from bridging veins that travel through the subdural space and enter the dura	Highly variable. Raised intracranial pressure associated with mass effect, may only see headache and confusion after fall with slowly progressive neurologic deterioration
Subarachnoid Hemorrhage	Hyperdensity filling the subarachnoid space	Blood collects in subarachnoid space	Trauma, vascular abnormalities to include saccular aneurysms	Arterial blood	Focal neurologic deficit and extreme headache “worst headache of life” +/- photophobia
Nonlobar Hemorrhage (ganglionic)	Hyperdensity seen in deep brain (e.g., globus pallidus, internal or external capsule, thalamus), cerebellum, and/or brainstem	Hemorrhage in globus pallidus, internal or external capsule, thalamus, cerebellum, and/or brainstem	Hemorrhagic stroke secondary to hypertension is most common; hemorrhage may also be secondary to reperfusion injury due to ischemia	Arterial blood	Patient with a history of improperly treated essential hypertension, cocaine toxicity, or other circumstances of hypertension
Lobar Hemorrhage	Hyperdensity anywhere that is not considered a nonlobar hemorrhage (see above), namely in the cerebral lobes	Hemorrhage in the cortex, subcortical white matter, and/or junction of the grey-white matter	Hemorrhagic stroke secondary to reperfusion injury or vascular disease such as cerebral amyloid angiopathy	Arterial blood	Most common in the elderly population, with or without co-existing Alzheimer’s disease(may have progressive cognitive impairment)

### What is the pathology of a subdural hematoma?

The dura mater is composed of two layers: an external collagenous layer (the periosteal layer) and an inner border cell layer with scant fibroblasts devoid of collagen (the leptomeningeal layer).<sup>3</sup> In a subdural hematoma, blood accumulates in the subdural space between the inner leptomeningeal layer of the dura mater and the arachnoid mater. The blood arises from bridging veins that travel across the subdural space, through the dura mater, and ultimately empty into the large dural sinuses (e.g., the superior sagittal sinus).<sup>3</sup> Although the brain is suspended in cerebrospinal fluid, the venous sinuses are fixed relative to the dura. When trauma occurs, the veins that travel through the dura may be torn where they enter the dura.

Subdural hematomas are usually self-limited and may lead to the formation of an organized hematoma. The organized hematoma is typically attached to the inner surface of the dura via newly formed fibrous tissue. After an initial subdural hematoma, there is a risk of recurrence of bleeding at the same site, which is thought to be due to the thin-walled vessels in the granulation tissue of the organized hematoma.<sup>3</sup> As such, subdural hematomas may occur in a chronic pattern with multiple recurrent episodes of subdural bleeding. Fig. 2 represents an acute-on-chronic hematoma of this nature. A representation of the locations of the different types of intracranial hemorrhage can be found in Fig. 3.

### What causes subdural hematomas?

Subdural hematomas are the most frequently occurring intracranial bleed.<sup>5</sup> As opposed to epidural hematomas, subdural hematomas most often occur in the elderly population, with falls as the most common mechanism. However, there is a bimodal distribution for this type of hemorrhage split between the elderly and infants. The brains of the elderly tend to show some degree of atrophy, whether associated with

normal aging or due to an underlying process. Atrophy causes the bridging veins to undergo stretching, which can result in hemorrhage following minor trauma such as a fall.<sup>3</sup> As a population, the elderly also have a higher prevalence of bleeding disorders and/or are more likely to be on anticoagulation medications, which may increase the risk of subdural hematoma from minor trauma.<sup>5</sup> Infants experience subdural hematomas because they have thin-walled bridging veins, so trauma is more likely to result in a subdural hemorrhage. For example, subdural hemorrhage is often unfortunately characteristic of abusive head trauma and the so-called “shaken baby syndrome.”<sup>3</sup>

### What is the typical clinical presentation of subdural hematomas?

Subdural hematomas have a less predictable pattern of physical presentation than epidural hematomas. Like epidural hematomas, the neurologic signs are largely due to intracranial hypertension from mass effect on the brain from the hematoma. Patients may present initially with signs of a mild TBI with GCS greater than or equal to 13 out of 15.<sup>5</sup> Clinically, the patient may only have mild symptoms (e.g., headache and confusion) after a fall with slowly progressive neurologic deterioration. Acute decompensation such as that which occurs more often in epidural hematomas can be seen, but is a rarer presentation.

### What is the treatment for subdural hematomas?

In patients found to have a subdural hematoma but no symptoms of ICH or mass effect, the subdural hematoma may be monitored without surgical intervention. If the patient is having significant symptoms of mass effect, then surgery is required to include debridement of the clot, usually via a craniotomy. There is a high rate of mortality in those requiring surgery for subdural hematoma.<sup>5</sup>

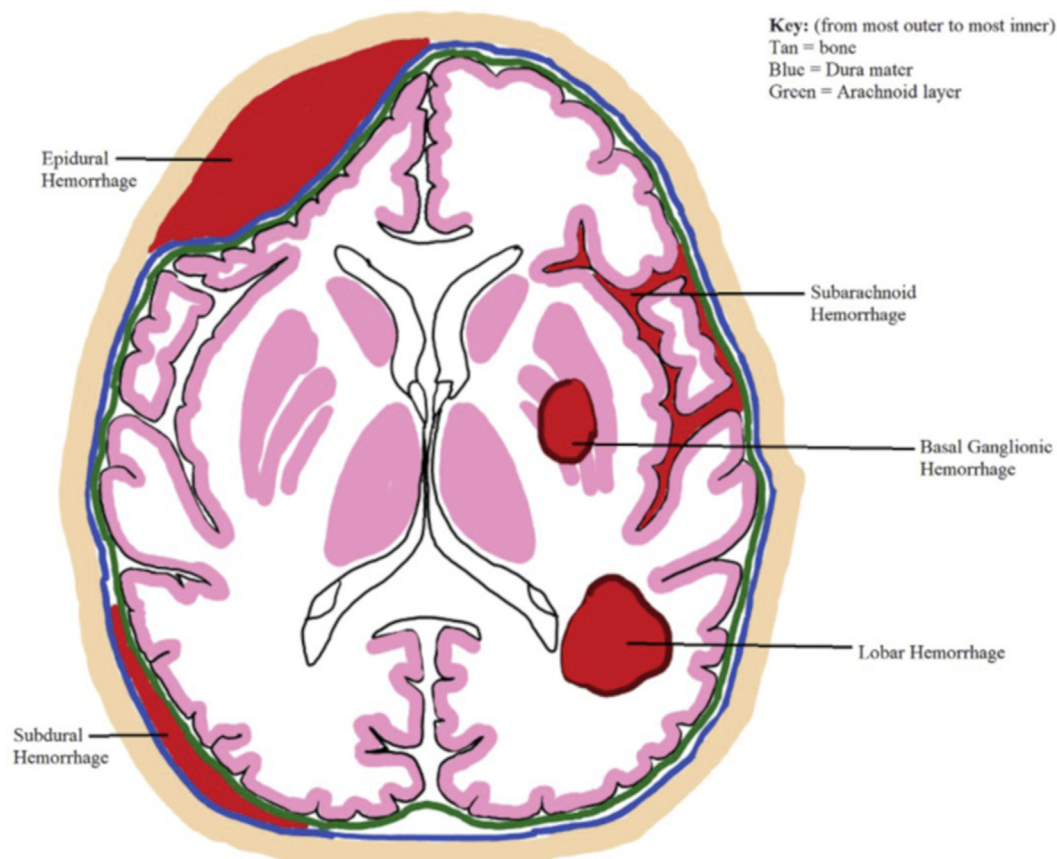


Fig. 3. Representation of the locations of the main types of cerebral hemorrhage.



## Subarachnoid Hemorrhage

### What may have caused the findings seen in the patient's CT scan?

Subarachnoid hemorrhages can be caused by trauma, saccular aneurysms or other vascular malformations, rupture/extension of intracerebral hemorrhage (e.g., from hypertension) into the ventricles, hematologic disorders, and neoplasms.<sup>3</sup> Clinically significant subarachnoid hemorrhages more frequently result from vascular abnormalities but are also seen in trauma, particularly by extension of other hemorrhages into the subarachnoid space<sup>3</sup> (see a more detailed description below).

### What is the typical clinical presentation of subarachnoid hematomas?

In this type of hemorrhage, arterial blood collects in the subarachnoid space (see Fig. 4). The typical physical presentation includes focal neurologic deficits and extreme headache. This headache is classically described as the "worst headache of my life," may be associated with photophobia, and patients often can indicate exactly when the headache started.<sup>3</sup>

### What is the typical presentation and treatment of subarachnoid hematomas?

Subarachnoid hemorrhage has been found to have the lowest mortality and is less likely to be associated with severe brain injury than other types of trauma-induced hemorrhage.<sup>5</sup> Small isolated subarachnoid hemorrhages have been shown to often resolve without long term neurological deficit and do not require intensive surgical intervention or ICU admission. However, severe subarachnoid hemorrhages may require intensive surgical management.<sup>5</sup>

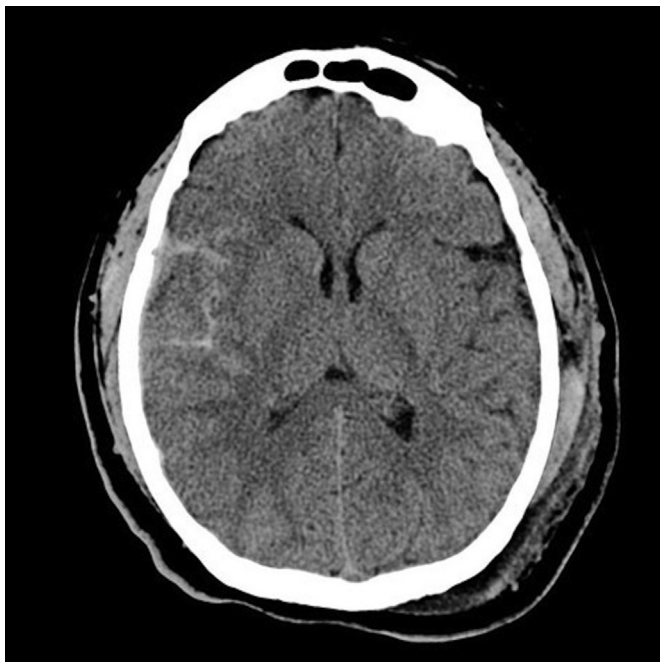


Fig. 4. Axial noncontrast head CT scan, traumatic subarachnoid hemorrhage within the right Sylvian fissure with a contusion. Source: Reproduced from Radiopaedia.org, rID:4852, case courtesy of Assoc Prof Frank Gaillard, under the Creative Commons Attribution BY-NC-SA 3.0.

## Patient presentation, 2

The driver of the car that caused the collision in the same motor vehicle accident described above is a 62-year-old male who also presents to the ED. From bystander reports there was no clear cause of the car crash. The patient's wife was in the back seat and was unharmed in the accident. She reports that the driver appeared to lose consciousness and subsequently lost control of the vehicle. On presentation, the patient is nonresponsive.

### Diagnostic findings, patient 2, Part 1

On presentation, the patient has various injuries due to the motor vehicle accident, including several facial lacerations from windshield glass, a right posterior hip dislocation, and abdominal pain from his seat belt. His vitals include a blood pressure of 190/105 mmHg, a heart rate of 110/min, a respiratory rate of 22/min, and SpO<sub>2</sub> of 96%. His GCS score is 7 out of 15 (eye response: 2 out of 4, verbal response: 2 out of 5, motor response: 3 out of 6). A review of the patients' medical history with his wife is performed, looking for a cause of his loss of consciousness (LOC) that might have resulted in the car accident. The patient has had a history of hypertension for which he has a prescription for amlodipine and benazepril (5mg/20 mg), but his wife mentions that he ran out a month ago and did not refill his medications because he felt well. This morning his blood pressure was 180/102 mmHg. A stat head CT scan is ordered.

### Questions/discussion, patient 2, Part 1

#### What is a the differential diagnosis for sudden LOC in a patient with a history of hypertension?

Cardiac causes of LOC include vaso-vagal syncope, arrhythmia, ischemic events (e.g., acute coronary syndrome, myocardial infarctions), or severe valvular disease. Neurologic causes include transient ischemic attack (TIA), stroke, seizure, delirium, or narcolepsy. Other causes include orthostatic, psychogenic, medication-related, metabolic, or idiopathic.<sup>6</sup>

#### What are the leading causes of non-traumatic intracranial hemorrhage?

Although they can be observed in settings of trauma, intraparenchymal hemorrhages, including lobar and nonlobar (e.g., basal ganglionic) hemorrhages, are often non-traumatic and associated with cerebrovascular disease. Hemorrhage in the brain (i.e., intraparenchymal hemorrhage) due to rupture of a small vessel is often associated with a hemorrhagic stroke or can be secondary to an ischemic stroke.<sup>7</sup> An expansile intraparenchymal hemorrhage can also lead to ischemia itself by compressing and occluding surrounding blood vessels as a result of mass effect from the initial hemorrhage. With that said, major causes of intraparenchymal hemorrhage are hypertensive cerebrovascular disease and cerebral amyloid angiopathy (CAA). Other causes of non-traumatic intraparenchymal hemorrhage include systemic coagulation disorders, neoplasms, vasculitis, and vascular malformations.<sup>3</sup>

#### What is the pathology of intraparenchymal hemorrhage?

Intraparenchymal hemorrhages, including lobar and nonlobar hemorrhages, are characterized by extravasation of blood into parenchyma, with compression and edema of adjacent parenchyma.<sup>3</sup> Old hemorrhages may form gliotic cavitary lesions in the brain. Hemosiderin and lipid-laden macrophages are found in pathologic samples of post-hemorrhagic parenchyma, and reactive astrocytes proliferate.<sup>3</sup>

### **What is the typical clinical presentation of non-traumatic intraparenchymal hemorrhage?**

The type of non-traumatic intracerebral hemorrhage often cannot be distinguished by presentation alone, as neurologic strokes can present similarly with nonspecific symptoms. Neurologic deficits depend on the location of hemorrhage. If the hemorrhage is large and sudden with great mass effect, then the patient is more likely to experience a prolonged loss of consciousness. If the hemorrhage is relatively small, then the patient is more likely to have transient side effects specific to the location of the hemorrhage. Headache and epileptic seizures are commonly seen in lobar hemorrhage due to cerebral amyloid angiopathy.<sup>8</sup>

Some signs and symptoms are more likely to be associated with causes of LOC other than hemorrhage. These include: a prodromal history such as dehydration, poor nutrition, viral illness, twitching or generalized shaking (more commonly associated with seizure), syncope, or delirium.<sup>6</sup> Seeing these symptoms should put hemorrhagic stroke lower on your differential, but because of the wide variety of presentations it should not be discounted.

Non-traumatic intraparenchymal hemorrhages occur most often in the middle-aged and the elderly, with a peak age of 60 years.<sup>3</sup>

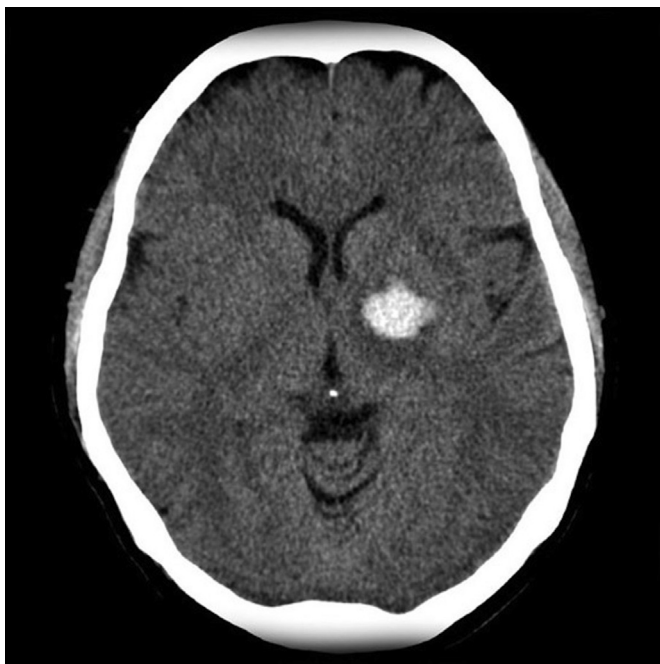### **Diagnostic findings, patient 2, Part 2**

The patient gets a stat head CT scan that is shown in Fig. 5. An emergency neurosurgical consultation is pursued; however, despite attempts to stabilize the patient he dies due to his injuries.

### **Questions/discussion points, patient 2, Part 2**

#### **What likely happened to the patient based on his presentation, imaging, and medical history?**

The hyperdensity seen on the CT scan in Fig. 5 indicates that the patient likely has a hemorrhagic stroke, more specifically a ganglionic hemorrhage or nonlobar hemorrhage, given its location in the deep brain



**Fig. 5.** Axial noncontrast head CT scan showing hyperdensity in the globus pallidus. Basal Ganglia bleed. Source: Reproduced from [Radiopaedia.org](https://radiopaedia.org/rID:2764), rID:2764, case courtesy of Assoc Prof Frank Gaillard, under the Creative Commons Attribution BY-NC-SA 3.0.

nuclei (basal ganglia). This hemorrhagic stroke is most likely caused by longstanding and improperly treated hypertension, as noted by the patient's past medical history.

Nonlobar hemorrhages include those in the basal ganglia, internal or external capsule, thalamus, cerebellum, and brainstem. A hemorrhage elsewhere (e.g., involving the cerebral cortex or centrum semiovale) in the brain is considered to be a lobar hemorrhage. Nonlobar hemorrhages are most often the result of poorly controlled longstanding hypertension leading to hypertensive vasculopathy.<sup>9</sup> Due to the location of nonlobar hemorrhages, it is also common for them to be complicated by intraventricular extension.

### **What is the pathology of hypertensive cerebrovascular disease, and how do the changes predispose to intraparenchymal hemorrhage?**

Chronic hypertension is a common etiology of intracerebral hemorrhage, including lobar and nonlobar hemorrhages. Hypertension leads to vessel wall changes throughout the body, including the vessels that supply the brain. For example, hypertension contributes to atherosclerosis, which is the formation of plaques in large arteries, as well as in arteriolosclerosis in the smaller vessels. Atherosclerotic disease can lead to thrombotic or thromboembolic ischemic injury, such as that which can be elicited by plaque rupture.<sup>7</sup> During ischemic injury, vessel wall damage and cell death occur. If reperfusion after infarct occurs, then hemorrhage within the infarcted region is more likely due to vessel damage resulting from ischemia. Another potential result of untreated hypertension is arteriolosclerosis or, more acutely and in severe hypertension, fibrinoid necrosis of small arteries and arterioles leading to so-called "lacunar" infarcts and hemorrhages.<sup>7</sup> The term arteriolosclerosis, applied to cerebrovascular disease, describes a variety of structural changes that small arteries and arterioles undergo most commonly in the setting of chronic systemic hypertension, including hyaline thickening (hyalinosis), muscular hyperplasia and/or hypertrophy, and lipohyalinosis (foamy macrophages in the wall of the vessel). Arteriolosclerosis leads to a narrowed lumen and decreased blood flow to the brain, increasing the risk of ischemic injury,<sup>7</sup> and may also weaken the vessels and predispose to hemorrhage.

Hypertension is also associated with the formation of Charcot-Bouchard aneurysms. These are microaneurysms that often occur in the small vessels of the basal ganglia and carry an increased risk of rupture.<sup>3</sup> They most often are encountered in the lenticulostriate branches of the middle cerebral artery.<sup>10</sup> These aneurysms form due to longstanding hypertension that has caused atrophy of the outer muscular layer of the blood vessel. Atrophy of the outer layer causes a loss of vessel wall integrity, which makes the blood vessel dilate and puts it at high risk of rupture.<sup>10</sup>

### **What is the treatment of intraparenchymal hematoma caused by hypertension?**

The net effect of hypertension is that it decreases the structural integrity of vessel walls, thereby increasing the risk of hemorrhage and ischemia. Treatment focuses on controlling the patient's hypertension with medications and preventing secondary cerebral injury. An intraparenchymal hematoma caused by hypertension may need to be surgically evacuated if the hemorrhage is large.

### **What are the causes, findings, and treatment of lobar hemorrhages in the brain?**

As with nonlobar hemorrhages, untreated hypertension is a common cause of lobar hemorrhages. However, lobar hemorrhages are more often associated with cerebral amyloid angiopathy (CAA)<sup>9</sup> compared to nonlobar hemorrhages. Other causes of lobar hemorrhages are vascular malformation or tumors.<sup>8</sup>

In lobar hemorrhages, a CT scan shows a hyperdense collection of blood from acute bleeding centered around the cerebral cortex and its junction with the subcortical white matter (as opposed to the deep brain structures such as the basal ganglia) as seen in Fig. 6. Hemorrhages can vary in size and may extend into the subdural, subarachnoid, or intraventricular space.

Lobar hemorrhage is most commonly observed in the elderly population due to the prevalence of CAA. As such, a CAA-associated lesion is usually suspected in patients older than 60 with a lobar hemorrhage.<sup>9</sup> Treatment depends on the size and location of the hematoma and the patient's presenting symptoms, age, and quality of life. With small lesions, medical management is aimed at preventing or decreasing the incidence of further hemorrhages. With large hematomas, surgical therapy may be required, or therapy may be palliative if the bleed is large or the damage of the bleed is irreversible.

### What is cerebral amyloid angiopathy?

CAA is associated with amyloidogenic peptides, specifically Beta-amyloid peptides, being deposited in the walls of small-to-medium-sized meningeal and cortical vessels. These deposits predispose to hemorrhage by weakening the vessel wall.<sup>3</sup> Most hemorrhages that occur are lobar and/or cerebellar in origin. CAA and Alzheimer's Disease often co-occur, as the same Beta-amyloid peptides are seen in and are thought to contribute to both disease states.<sup>8</sup>

Hemorrhages due to CAA range from asymptomatic to fatal. The hemorrhages are frequently recurrent, and with recurrent hemorrhages/microbleeds and microinfarctions, progressive cognitive impairment often occurs.<sup>8</sup> MRI scan is the best modality to diagnose CAA.<sup>8</sup>

### What is the nature and pathology of saccular or berry aneurysms, as a common cause of non-traumatic subarachnoid hemorrhage?

The most common non-traumatic cause of subarachnoid hemorrhages is a saccular or berry aneurysm. Subarachnoid hemorrhages resulting

from aneurysm rupture are most often seen in females in their 5th decade of life.<sup>3</sup> The exact pathology leading to the formation of saccular aneurysms is unknown. However, these aneurysms tend to have a characteristic lack of smooth muscle and lack of intimal elastic lamina that is thought to be due to a developmental/inborn defect.<sup>3</sup> The aneurysms are not thought to be present at birth but rather develop over the life of an individual due to this inborn defect in the media of the vessel. They are usually seen as thin-walled outpouchings, usually in the circle of Willis or a major cerebral vessel branching off of the circle, most commonly in vessels corresponding to the anterior circulation.<sup>3</sup> Both genetic factors and environmental factors, such as smoking and hypertension, are thought to contribute to aneurysm formation.

### What are the common findings from a traumatic brain injury?

TBIs occur as a result of traumatic head injury, which can be further classified as penetrating or blunt, open or closed, or by other designations. In these settings, they can occur as a result of skull fractures, parenchymal injury, and/or vascular injury.<sup>3</sup> TBI may exist in isolation or may coexist with other forms of intracranial traumatic injury such as a traumatic subdural hematoma.

Structural TBIs include contusions and penetrating injuries/lacerations (e.g., from a foreign body or skull fragment). Symptoms following these injuries can range depending on their severity but can include coma and death. Concussions and subconcussive injuries are the most common form of TBI and overlap with the term "mild traumatic brain injury." Unlike contusions and penetrating injuries/lacerations, there is no definite pathologic correlate to what is clinically described as a concussion. Clinically, concussions present as altered consciousness secondary to head injury. Patients experiencing a concussion may experience amnesia surrounding the event.<sup>3</sup> The pathogenesis of concussion is unknown but is suspected to involve dysregulation of the reticular activating system, among other circuits. Generally speaking, the pathophysiology of mild TBI is also still under much investigation and most likely includes both effects of vascular/microvascular injury and inflammation.

### Teaching points

- ICH and mass effect due to hemorrhage are the cause of most side effects seen with intracranial hemorrhage.
- On CT scan, epidural hematomas are seen as biconvex hyperdense areas with smooth contours, often associated with a skull fracture.
- Epidural hematomas are commonly caused by blunt trauma of great force, and usually in a younger patient population than other forms of traumatic intracranial hemorrhages.
- Acute subdural hematomas are venous bleeds, and appear as blood along the brain surface, often in a crescent or sickle shape that may cross suture lines.
- Subdural hematomas are commonly caused by relatively minor traumatic incidents in older patient populations and may form chronically with episodes of recurrent bleeding.
- The net effect of hypertension is decreased structural integrity of the vessel walls causing an increased risk of ischemic injury and/or hemorrhage.
- Nonlobar hemorrhages are most associated with longstanding hypertensive changes.
- Cerebral amyloid angiopathy is most associated with lobar hemorrhages and is due to the buildup of amyloidogenic peptides deposited in the small-to-medium-sized meningeal and cortical vessels, which weaken vessel walls and predispose to hemorrhage.
- Subarachnoid hemorrhages are most commonly due to trauma or vascular anomaly (saccular aneurysm rupture).
- Saccular aneurysms are thought to develop over the life of a patient due to an inborn defect in the media of the vessel.

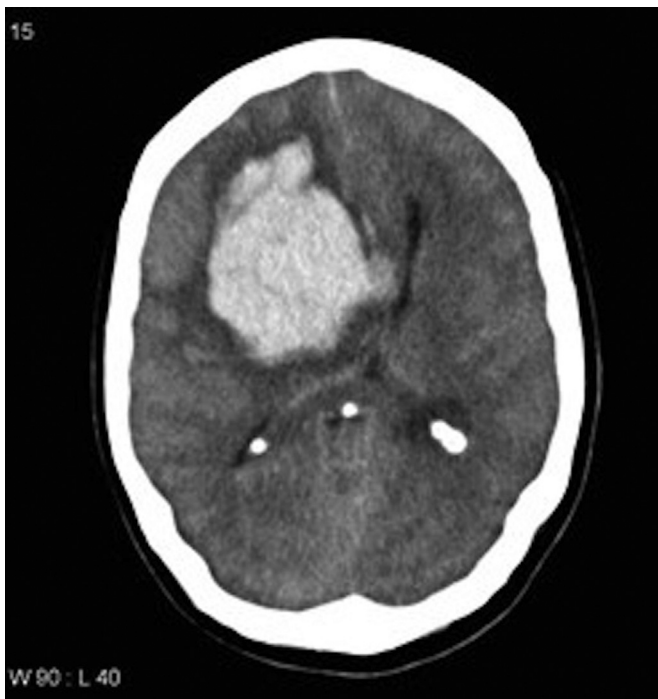

Fig. 6. Axial noncontrast head CT scan showing a large lobar hemorrhage in the frontal lobe extending into the ventricles. Source: Reproduced from [Radiopaedia.org](https://radiopaedia.org), rID:10678, case courtesy of Assoc Prof Frank Gaillard, under the Creative Commons Attribution BY-NC-SA 3.0.

- Traumatic brain injury (TBI) commonly results from a skull fracture, parenchymal injuries, and/or vascular injuries.
- The pathophysiology of mild TBI (including concussion) is still under investigation and likely includes vascular and inflammatory effects.

### Authors' note

The opinions expressed herein are those of the authors and are not necessarily representative of those of the Uniformed Services University of the Health Sciences (USUHS), the Department of Defense (DOD), or the United States Army, Navy, or Air Force, or the Henry M. Jackson Foundation.

### Funding

The author(s) received no financial support for the research, authorship, and/or publication of this article.

### Declaration of competing interests

The author(s) declared no potential conflicts of interest with respect to the research, authorship, and/or publication of this article.

### References

1. Knollmann-Ritschel BEC, Regula DP, Borowitz MJ, Conran R, Prystowsky MB. Pathology competencies for medical education and educational cases. *Acad Pathol.* 2017;4. doi:10.1177/2374289517715040
2. Pinto VL, Tadi P, Adeyinka A. *Increased Intracranial Pressure. [Updated 2021 Sep 29]. in: StatPearls [Internet].* Treasure Island (FL): StatPearls Publishing; 2021 Jan.
3. Mageta M, Perry A. The central nervous system. In: Kumar V, Abbas AK, Aster JC, eds. *Robbins and Cotran Pathologic Basis of Disease.* tenth ed. Elsevier; 2021:1249–1252.
4. Sullivan TP, Jarvik JG, Cohen WA. Follow-up of conservatively managed epidural hematomas: implications for timing of repeat CT. *AJNR Am J Neuroradiol.* 1999; 20(1):107–113. doi:10.1016/j.jocn.2018.10.149
5. Shpiner AC, Bugaev N, Riesenburger R, et al. The profile of blunt traumatic supratentorial cranial bleed types. *J Clin Neurosci.* 2019;59:79–83. doi:10.1016/j.jocn.2018.10.149
6. Khan T, Stecker M, Stecker M. Evaluating the patient with loss of consciousness. *Surg Neurol Int.* 2015;6(Suppl 6):S262–S265. doi:10.4103/2152-7806.157615
7. Ladecola C, Davissan RL. Hypertension and cerebrovascular dysfunction. *Cell Metabol.* 2008;7(6):476–484. doi:10.1016/j.cmet.2008.03.010
8. Fakan B, Reisz Z, Zadori D, Vecsei L, Klivenyi P, Szalardy L. Predictors of localization, outcome, and etiology of spontaneous intracerebral hemorrhages: focus on cerebral amyloid angiopathy [published correction appears in *J Neural Transm (Vienna)*. 2020 May 9. *J Neural Transm.* 2020;127(6):963–972. doi:10.1007/s00702-020-02174-2
9. Kremer PH, Jolink WM, Kappelle LJ, Algra A, Klijn CJ. SMART and ESPRIT study groups. Risk factors for lobar and non-lobar intracerebral hemorrhage in patients with vascular disease. *PLoS One.* 2015;10(11), e0142338. doi:10.1371/journal.pone.0142338
10. Gupta K, DasJ M. *Charcot Bouchard Aneurysm. [Updated: 2021 Jul 26]. in: StatPearls [Internet].* Treasure Island (FL): StatPearls Publishing; 2021 Jan.