



Received: 2016.04.24
Accepted: 2016.06.10
Published: 2017.05.22

Authors' Contribution:

- A** Study Design
- B** Data Collection
- C** Statistical Analysis
- D** Data Interpretation
- E** Manuscript Preparation
- F** Literature Search
- G** Funds Collection

Mid-Esophageal Diverticulum Mimicking an Aortic Aneurysm on Chest Radiography

Geena Benjamin^{1ADEF}, Shivaprakash Basavanthaiah Hiremath^{1ABCDEF},
Srikiran Thayille Kandy^{1ADEF}, Charamel Sankaran Kesavan^{2ADEF}

¹ Department of Radiodiagnosis, Pushpagiri Institute of Medical Sciences, Tiruvalla, Kerala, India

² Department of General Medicine, Pushpagiri Institute of Medical Sciences, Tiruvalla, Kerala, India

Author's address: Shivaprakash Basavanthaiah Hiremath, Department of Radiodiagnosis, Pushpagiri Institute of Medical Sciences, Tiruvalla, Kerala, India, e-mail: shivaprakashbh@gmail.com

Summary

Background:	Mid-esophageal region is an uncommon location of esophageal diverticula, a condition usually diagnosed in elderly individuals.
Case Report:	We report a case of an elderly male with incidental finding of mediastinal lesion, which was initially thought to be an aortic aneurysm. Further evaluation demonstrated a mid-esophageal diverticulum at the level of the carina. We present patient's medical history and imaging, followed by a discussion on symptoms and management.
Conclusions:	Knowledge of benign conditions that might mimic a mediastinal vascular pathology is important for therapeutic and prognostic reasons, as they are often managed conservatively.
MeSH Keywords:	Deglutition Disorders • Diverticulum, Esophageal • Esophageal Motility Disorders • Esophagectomy • Mediastinum
PDF file:	http://www.polradiol.com/abstract/index/idArt/899248

Background

Mediastinal lesions comprise a group of heterogeneous, asymptomatic or symptomatic conditions with varying manifestations in imaging studies. Diagnostic imaging aids in stating the preliminary diagnosis and deciding what type, if any, of confirmatory investigations should be performed. Exact localization and diagnosis of these lesions carry significant implications for further management and prognosis.

Esophageal pouches occur as a result of transient evagination of weaker areas of the esophageal wall, while persistent outpouchings form diverticula. The differential diagnoses of visceral space lesions in the chest include those arising from the esophagus or the aorta [1]. Such lesions pose a diagnostic dilemma and chest radiographs are often insufficient to differentiate between various pathologies that might require further investigation.

We report a case of incidentally found mid-esophageal diverticulum in an elderly male. The lesion was initially

misdiagnosed as an ascending aortic aneurysm on chest radiography. This report emphasizes the need for greater awareness of diverticula, which are usually asymptomatic and relatively uncommon, but may be potentially mistaken for an aortic aneurysm. Esophageal diverticula are generally managed conservatively, while aortic aneurysms mandate serial follow-up and operative management.

Case Report

A 71-year-old hypertensive male presented with right-sided weakness and slurred speech. There was no history of loss of consciousness, vomiting or blurring of vision. He denied complaints of difficulty in swallowing or regurgitation. CT scan of the brain showed hypodense area in the anterior limb of left internal capsule confirming the diagnosis of acute infarct. Chest radiograph revealed a prominence in the region of ascending aorta, mimicking an aneurysm, with well-defined margin on right side (Figure 1A). Left lateral radiograph demonstrated a lesion posterior to the trachea causing indentation and luminal narrowing (Figure 1B).

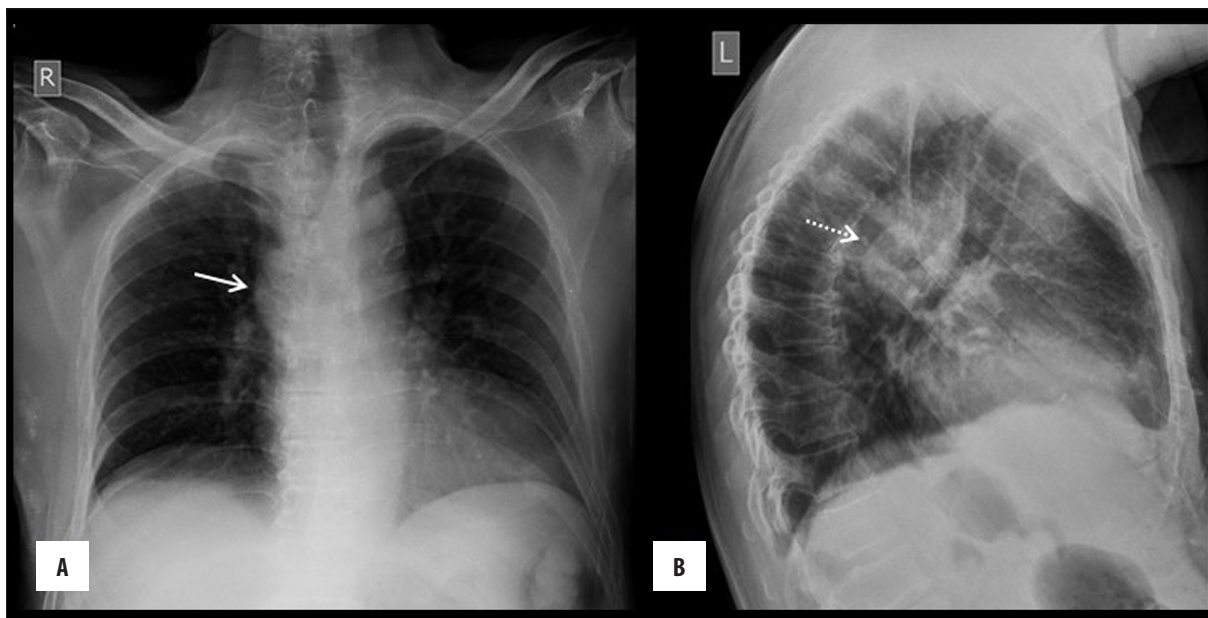


Figure 1. (A) Frontal chest radiograph showed prominence in the region of ascending aorta mimicking an aneurysm (solid arrow). (B) Left lateral radiograph showed radio dense lesion inferior to arch of aorta with mass effect on trachea (dotted arrow).

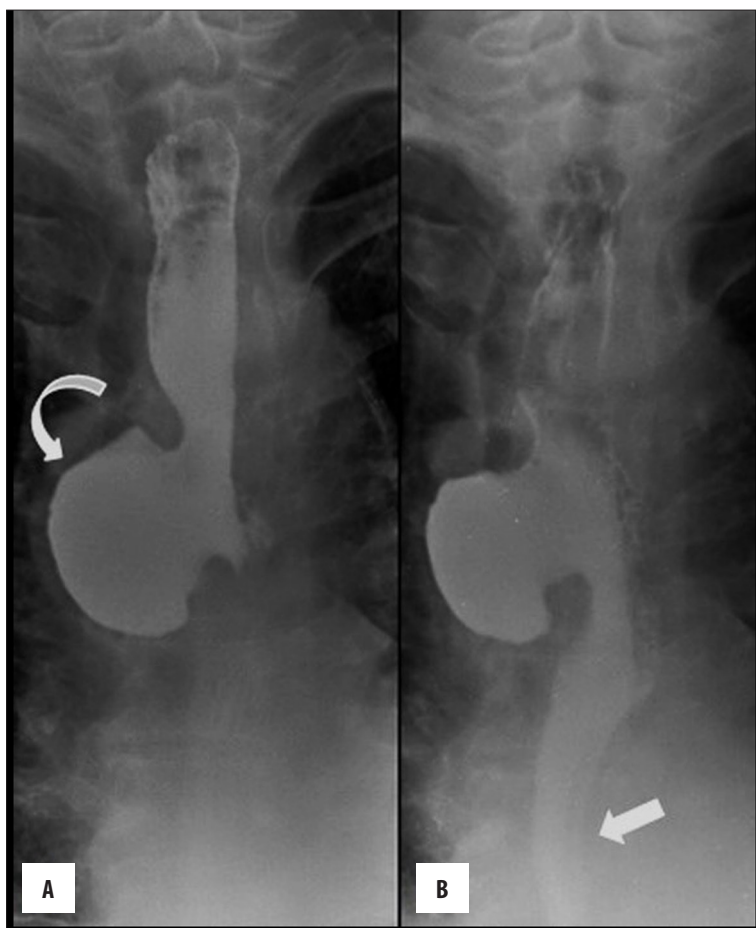

Figure 2. (A, B) Barium swallow showed large diverticulum arising from right lateral wall of mid esophagus (curved arrow) with normal appearing distal esophagus (solid arrow).

Mid-esophageal diverticulum with a large neck arising from the right lateral wall was visualized in upper GI contrast series (Figure 2A, 2B). Chest CT showed a diverticulum at the level of tracheal bifurcation with particulate

matter and mottled appearance, i.e. retained food particles (Figure 3A). Retention of oral contrast was seen in dependent location within the diverticulum (Figure 3B). Upper GI endoscopy confirmed the presence of mid-esophageal

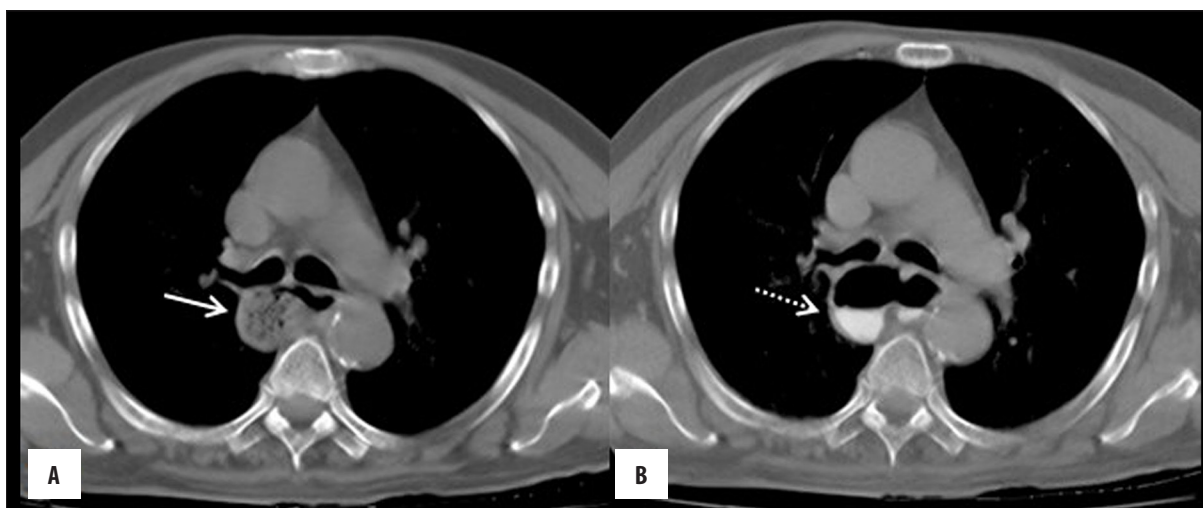


Figure 3. (A, B) Axial CT chest in mediastinal window showed retained food particles in the diverticulum (solid arrow) and retained oral contrast in the dependent location (dotted arrow).

diverticulum with a large neck. In the absence of symptoms patient was treated conservatively.

Discussion

Esophageal diverticula are classified into paraesophageal (Zenker's), mid-esophageal (tracheobronchial) and distal (epiphrenic) diverticula depending on the anatomical location [2]. They can form as a result of cicatrization (traction), may be due to inherent weakness of esophageal wall (pulsion diverticula) or altered esophageal motility [3].

Mid-esophageal diverticula are outpouchings formed within 5 cm of the carina [4]. They are uncommon, accounting for about 15% of all esophageal diverticula and usually affect patients in their sixth to seventh decade of life. They are currently thought to occur as a consequence of esophageal dysmotility when a peristaltic wave arising from the normal or hyperperistaltic upper esophagus encounters a spastic distal segment of the esophagus, which creates functional obstruction, resulting in formation of mid-thoracic diverticula [5]. Persistent congenital attachments between trachea and esophagus or fibrosis due to previous infections, such as tuberculosis or histoplasmosis, can cause traction and facilitate formation of diverticula at the level of the carina [6]. Nehra et al. [7] showed an association of primary esophageal motility disorder with esophageal diverticulum on manometry studies in 71% to 100% of patients.

Mid-thoracic diverticula are usually asymptomatic and may be detected incidentally on routine imaging. Symptomatic patients present with dysphagia, slow eating, coughing or aspiration during meals, or frequent chest infections [8]. Patients with large diverticula (usually

>5 cm) tend to be symptomatic and present with complications, such as obstruction and bezoar formation. Rare complications include massive gastrointestinal bleeding, aorto-esophageal fistula or development of carcinoma within the diverticulum [9,10].

Individuals with mid-esophageal diverticula undergo barium esophagogram, computed tomography and esophagogastroduodenoscopy (OGD) with manometry. The most important investigation for evaluation of esophageal diverticulum is radiography with oral contrast ingestion. Upper GI contrast series and CT not only allow the evaluation of symptoms, but also aid in surgical planning by demonstrating the location and size of the diverticulum. An OGD usually reveals a diverticulum and manometry shows associated motility disorders, which include nutcracker esophagus, diffuse esophageal spasm, achalasia and hypertensive lower esophageal sphincter [4].

Medical and endoscopic therapies are commonly directed against associated motility disorders and reflux disease. Surgery generally involves diverticulectomy and myotomy in symptomatic large diverticula, with esophagectomy performed in patients with nonfunctional esophagus or cases complicated by malignancy [11].

Conclusions

There are numerous possible differential diagnoses of visceral space lesions. Chest radiographs do not adequately differentiate between those lesions and further evaluation is necessary. Due to therapeutic and prognostic implications, it is important to be aware of benign disorders, which frequently require conservative treatment only, mimicking a serious vascular pathology.

References:

1. Thacker PG, Mahani MG, Heider A, Lee EY: Imaging evaluation of mediastinal masses in children and adults: practical diagnostic approach based on a new classification system. *J Thorac Imaging*, 2015; 30(4): 247-67
2. Gore RM, Levine MS: Textbook of gastrointestinal radiology. 3rd ed. Philadelphia: Saunders Elsevier, 2008; 475-77
3. Constantini M, Zaninotto G: Oesophageal diverticula. *Best Pract Res Clin Gastroenterol*, 2004; 18: 3-17

4. Thomas ML, Anthony AA, Fosh BG: Oesophageal diverticula. *Br J Surg*, 2001; 88: 629–42
5. Khan N, Ismail F, Van de Werke IE: Oesophageal pouches and diverticula: A pictorial review. *S Afr J Surg*, 2012; 50(3): 71–75
6. Rice TW, Baker ME: Mid-thoracic diverticula. *Semin Thorac Cardiovasc Surg*, 1999; 11: 352–57
7. Nehra D, Lord RV, DeMeester TR et al: Physiologic basis for the treatment of epiphrenic diverticulum. *Ann Surg*, 2002; 235: 346–54
8. Khan A, Carmona R, Traube M: Dysphagia in the elderly. *Clin Geriatr Med*, 2014; 30: 43–53
9. Guerra JM, Zuñil M, Garcia I et al: Epiphrenic diverticula, esophageal carcinoma and esophagopleural fistula. *Hepatogastroenterology*, 2001; 48: 718–19
10. Yasuda F, Shimono T, Tonouchi H et al: Successful repair of an aorto-esophageal fistula with aneurysm from esophageal diverticulum. *Ann Thorac Surg*, 2002; 73: 637–39
11. Michael H, Fisher RS: Treatment of epiphrenic and mid-esophageal diverticula. *Curr Treat Options Gastroenterol*, 2004; 7: 41–52