

	Mortality Yes 4	No 18	P value
Steroid total dose	396 (171, 429)	105 (22, 178)	<0.0001
Duration of steroid	31 (14, 45)	12 (6.50, 19.3)	<0.0001
O2	28 (9.50, 36.0)	7 (3.0, 14.50)	0.05
Age	60.3 ± 6.60	48.8 ± 13.7	0.128
Duration of Hospital stay	29.0 (17.5, 42.7)	13.0 (10.5, 20.5)	0.042
Severity of COVID			
Mild	0	1 (5.6)	0.876
Moderate	1 (25.0)	5 (27.8)	
Severe	3 (75.0)	12 (66.7)	
Serum GM	1.69 ± 0.71	0.74 ± 0.58	0.03
Sex			
Male	2 (50)	14 (77.8)	0.259
Female	2 (50)	4 (22.2)	
Comorbidities			
HTN	3 (75.0)	12 (66.7)	0.746
DM	1 (50)	6 (33.3)	0.531
CKD	1 (25.0)	2 (11.1)	0.464
CAD	0	1 (5.6)	0.529

P264

**Brain phaeohyphomycosis secondary to immunosuppressant therapy due to *Rhinocladiella mackenziei***

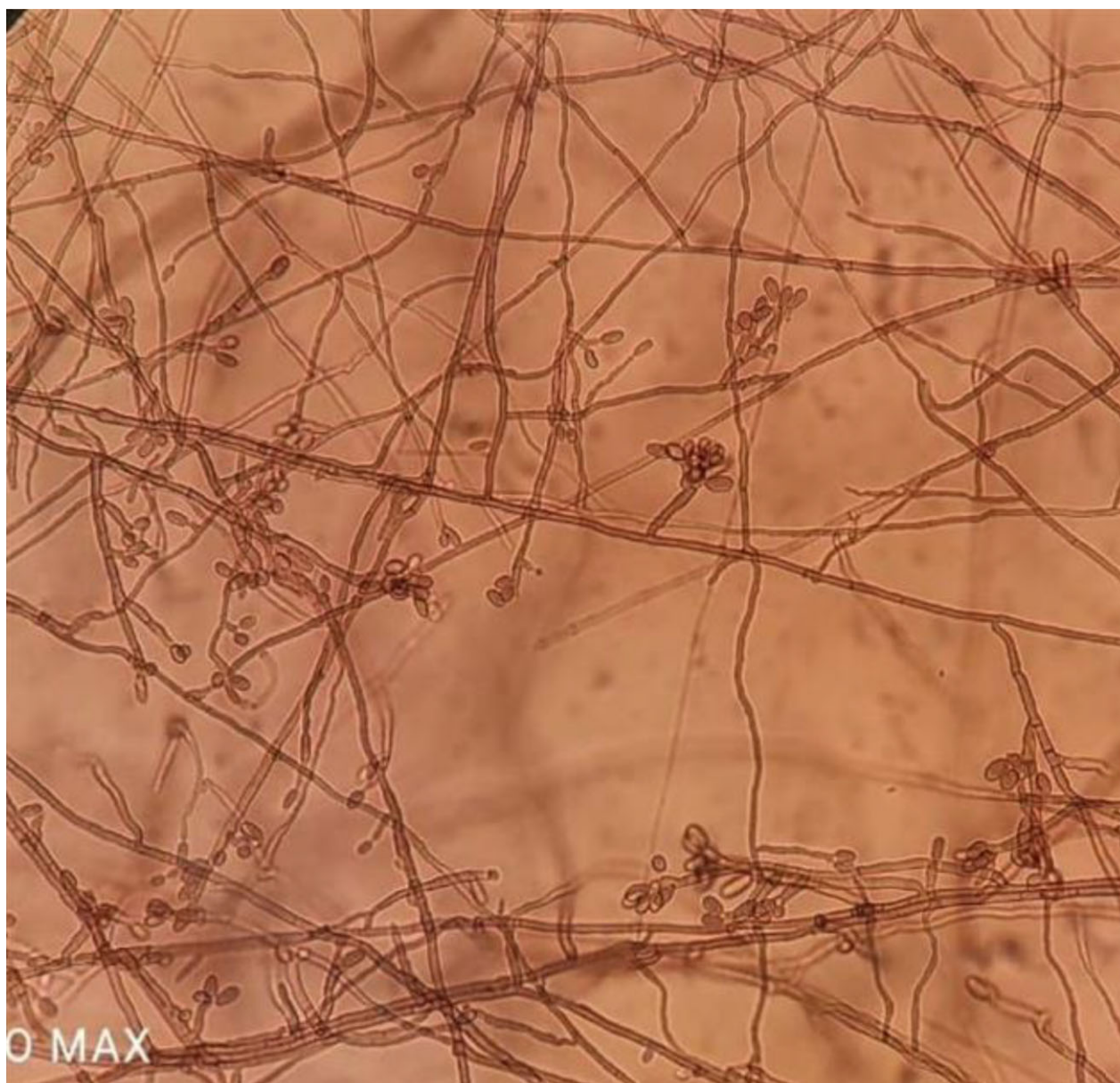
Madhu Rai, Medical Priyanka Patel, Camilla Rodriguez, Shaoli Basu, Asmita Salvi, Umang Agrawal, Ayesha Sunavala, Rajiv Soman, Anjali Shetty


<sup>1</sup>P.D. Hinduja Medical Hospital and Research Centre, Mahim Mumbai, India

Poster session 2, September 22, 2022, 12:30 PM - 1:30 PM

Two cases of *Rhinocladiella mackenziei* have been noted in our institute, the first case in 2015 (post-renal transplant) and the second case in 2021 (post-COVID infection). Both the patients had received immunosuppressants for varying dura-

tion. Both the cases presented to the hospital with neurological deficit secondary to brain abscess. On initial assessment, the melanized fungus was noted which was later identified as *Rhinocladiella* on culture and further confirmed with molecular methods. Both the cases were treated with injection of L AmB, voriconazole and SFC for a prolonged duration and later discharged when the condition improved. The renal transplant patient was advised lifelong voriconazole since he would continue to be on immunosuppressants. To our knowledge, the second patient diagnosed post-COVID could be the first case report of invasive dematiaceous fungal infection in an apparently immunocompetent individual. Both cases also highlight the challenges in management such as designing an appropriate regimen, deciding the optimum duration of antifungal therapy, and managing the toxicities associated with long-term antifungal use. *R. mackenziei* is a frequently fatal melanized neurotropic fungus known to carry almost 100% mortality despite the combination of antifungal agents and surgery. Central nervous system infections due to *R. mackenziei* have been exclusively reported from the Middle East, except for cases recently reported from India.





P265

**Phaeoophomycosis caused by *Rhinocladiella similis* mimicking Sporotrichosis**

Juhi Taneja<sup>1</sup>, Rahul Ranjan<sup>1</sup>, Kuhu Chatterjee<sup>1</sup>, V Ramesh<sup>1</sup>, Bhabatosh Das<sup>2</sup>  
<sup>1</sup>ESIC Medical College and Hospital, Faridabad, Faridabad, India  
<sup>2</sup>Translational Health Science and Technology Institute, Faridabad, India

Poster session 2, September 22, 2022, 12:30 PM - 1:30 PM

**Objective:** A case of phaeoophomycosis caused by *Rhinocladiella similis* with a clinical picture simulating sporotrichosis is described.

**Methods:** A 34-year-old male patient, employed in a textile factory presented with multiple subcutaneous nodules on the lateral aspect of the dorsum of the left hand and left forearm. There was a history of mechanical trauma 1 year back. On examination, three to four verrucous ulcerative nodules clustered on the dorsum of the left hand were observed. A preliminary diagnosis of sporotrichosis was made and a punch biopsy was performed from the lesion and subjected to KOH examination, fungal culture, and histopathological examination. ITS sequencing was done to confirm the identity of the isolate.

**Results:** The skin punch biopsy from the lesion on the dorsum of the hand showed marked hyperkeratosis, papillomatosis, parakeratosis, acanthosis, and irregular elongation of rete ridges. No fungal structures and neutrophils were seen. On examination with 40% Potassium hydroxide round yeast-like cells were seen. An initial diagnosis of sporotrichosis was established. After 5 days, white to grayish colonies with aerial hyphae were observed on Sabouraud's dextrose agar which eventually turned greenish black on further incubation. Lactophenol cotton blue (LPCB) mount of the slide culture showed thin, hyaline, septate hyphae with oval conidia arranged in a bottle brush pattern around erect conidiophores and also directly arising from the hyphae. The pathogen was confirmed by ITS sequencing as *R. similis*. Patient was started on itraconazole 200 mg twice daily for 12 weeks. The patient is on regular follow-up and has shown gradual regression of the lesions indicating response to therapy.

**Conclusion:** *Rhinocladiella similis* infections have been reported chiefly from Brazil causing chromoblastomycosis. There have been no reports of infections due to this pathogen from the Indian subcontinent. This report presents the first case of *R. similis* as an agent of phaeoophomycosis and calls for the need of a thorough evaluation of these cases so as to manage cases appropriately. It also underlines the need to study and redefine the ecological niche of this pathogen as well as its clinical spectrum.

P266

**A case of mixed fungal infection causing invasive fungal Rhinosinusitis in a post-COVID patient**

Ujjwayini Ray, Soma Dutta  
 Consultant, Kolkata, India

Poster session 2, September 22, 2022, 12:30 PM - 1:30 PM

**Objectives:** To identify the fungal etiology of invasive nasal sinusitis in a patient of post-COVID.

**Methods:** A 34-year-old non-diabetic man, who had mild coronavirus disease (COVID) infection 2 months back presented with left-sided nasal obstruction, headache accompanied by malodorous, thick, mucopurulent discharge for the last 2 weeks.

A CT scan of sinuses revealed opacification of left posterior ethmoid and sphenoid sinus without bony erosion or calcification.

The patient underwent unilateral functional endoscopic sinus surgery (FESS) and debridement of tissue from the affected sinuses.

**Results:** A KOH preparation of the debrided tissue showed thin septate hyphae. Gram-stained smear of the debrided material showed thin septate fungal hyphae with clamp-like connections (Fig. 1). Histopathological examination revealed features of the inflammatory polyp. In Sabouraud dextrose agar the fungal colony grew fast and its aerial mycelium is white and cotton-like. The fungus was phenotypically identified as *Schizopbyllum commune* (identification was confirmed at the National Reference Centre).

He continued to do well but about 2 months later he started experiencing headaches and pain behind the eyes. He also complained of nasal stuffiness (left greater than right) and yellowish nasal discharge. At this point, a CT scan revealed soft tissue density with interspersed hyperdensity in sphenoid sinus bilateral ethmoid, and bilateral maxillary sinuses with associated bony erosion and possible extension into the right cavernous sinus and extracanal compartment of right orbit suggestive of invasive fungal sinusitis (Fig. 2).

Bilateral FESS was done. Extensive fungal material was observed in the sphenoid sinus and thorough debridement was performed.

Mycological studies of the debrided tissue showed thin septate hyphae. *Schizopbyllum commune* was again isolated in culture.

Histopathological section showed inflammatory cells and several slender, branching septate fungal hyphae.

The invasive nature of the infection prompted reexamination of the histopathology slides and cultures for the presence of other fungi particularly of the Mucorales group but no other fungus could be identified.

The patient was started on liposomal amphotericin B and the tissue blocks were sent for fungal identification to the National Reference Centre through sequencing following DNA extraction from the paraffin blocks. Amplification of the 18 S rDNA region (coding for the 18 S RNA) using ZM primers followed by sequencing revealed the presence of *R. arrhizus*.