



Cardiac complications after laparoscopic large hiatal hernia repair. Is it related with staple fixation of the mesh? -Report of three cases



Maria del Carmen Fernandez ^a, María Diaz ^a, Fernando López ^{a, b, *}, Roberto Martí-Obiol ^a, J. Ortega ^{a, b}

^a Department of Surgery Clinic University Hospital, Valencia, Spain

^b Department of Surgery, University of Valencia, Spain

HIGHLIGHTS

- Three cases with different clinical expression of cardiac tamponade after laparoscopic large hiatal hernia repair.
- We review cardiac complications related to laparoscopic hiatal hernia repair.
- It is necessary to consider the risk of injury to the surrounding tissues during the anchorage of the mesh to the diaphragm.
- Cardiac complications must be considered in the postoperative period of mesh hiatoplasty.

ARTICLE INFO

Article history:

Received 21 May 2015

Received in revised form

14 September 2015

Accepted 15 September 2015

Keywords:

Giant hiatal hernia
Mesh hiatoplasty
Cardiac complications
Cardiac tamponade
Mesh fixation

ABSTRACT

Introduction: Laparoscopic Nissen operation with mesh reinforcement remains being the most popular operation for large hiatal hernia repair. Complications related to mesh placement have been widely described. Cardiac complications are rare, but have a fatal outcome if they are misdiagnosed.

Presentation of cases: We sought to outline our institutional experience of three patients who developed cardiac complications following a laparoscopic Nissen operation for large hiatal hernia repair.

Discussion: Laparoscopic hiatoplasty and Nissen fundoplication are safe and effective procedures for the hiatal hernia repair, but they are not exempt from complications. Fixation technique and material used must be taken into account. We have conducted a review of the literature on complications related to these procedures.

Conclusion: In the differential diagnosis of hemodynamic instability after laparoscopic hiatal hernia repair, cardiac tamponade and other cardiac complications should be considered.

© 2015 The Authors. Published by Elsevier Ltd on behalf of IJS Publishing Group Limited. This is an open access article under the CC BY-NC-ND license (<http://creativecommons.org/licenses/by-nc-nd/4.0/>).

1. Introduction

Laparoscopic mesh hiatoplasty for large hiatal hernias and antireflux surgery with prosthetic hiatal closure have been shown to be safe and effective procedures [1]. However, complications related to hiatal hernia repair with a mesh implant have been described [2]. Cardiac complications are rare and hardly reported in the literature.

We report our institutional experience in this surgery showing three different cases of cardiac complications after laparoscopic

hiatal hernia repair using a mesh implant and Nissen fundoplication.

2. Case report 1

A 46-year-old man was studied because of gastroesophageal reflux disease refractory to medical treatment. Endoscopic and contrast X-Ray studies were consistent with large hiatal hernia with most of the stomach bulging into the intrathoracic region.

He was eligible for surgery so a laparoscopic Nissen operation with mesh reinforcement was performed using Securestrap® (Ethicon, Norderstedt, Germany) for the mesh fixation. In the immediate postoperative period, the patient was doing well and remained hemodynamically stable. 48 h after surgery, patient developed hypotension, sweating and chest pain radiating to the

* Corresponding author. Department of Surgery Clinic University Hospital, Valencia Spain.

E-mail addresses: mcfm89@gmail.com (M.C. Fernandez), maria Diaz@uv.es (M. Diaz), ferlomo@gmail.com (F. López), romartob@gmail.com (R. Martí-Obiol), joaquin.ortega@uv.es (J. Ortega).

left shoulder blade. EKG showed a diffuse ST-segment elevation. The echocardiogram was significant for mild pericardial effusion. The patient was then taken to Intensive Care Unit (ICU) for hemodynamic management.

Blood tests showed a troponin elevation supporting the diagnosis of myopericarditis secondary to thoraco-abdominal surgery. The patient condition improved after medical treatment with *Lysine-acetylsalicylic acid* so he could be discharged from ICU.

Despite the improvement, the patient persisted with chest pain and dyspnea. Cardiac MRI showed a large pericardial effusion (Fig. 1). Pericardiocentesis was performed with removing 650 cc of bloody fluid. The pericardial drain could be removed two days later.

The patient course was uncomplicated with resolution of the pericardial effusion on successive echocardiograms. He was discharged on the 15th postoperative day without medical treatments.

At present, patient has no recurrence of the gastric volvulus nor the pericardial effusion.

3. Case report 2

A 62-year-old female patient with history of arterial hypertension and osteoporosis and past surgical history of double adnexectomy and appendectomy, presented to our outpatient clinic with anemia and gastroesophageal reflux symptoms. After the diagnosis of a large hiatal hernia she was proposed for surgery. A Laparoscopic mesh hiatoplasty was performed using Securestrap® associating a Nissen fundoplication.

At the fifth postoperative day the patient developed acute respiratory distress syndrome with hypotension and oliguria that required an ICU management with intubation, mechanical ventilation and high doses of Noradrenaline. The thoracic CT-scan showed a bilateral pleural effusion and a large pericardial effusion that caused the collapse of the right atrium and ventricle (Fig. 2). She was taken back to the operating room for urgent surgical pericardial drainage. Exploration of the hiatus revealed an hematoma volume of 2.500–3.000 cc without active bleeding.

Patient condition got better improving her ventilatory function and without needs of amine support. The echocardiogram revealed a mild residual pericardial effusion and patient could be discharged from ICU.

After that, postoperative course was uneventful. She was discharged on the 23rd postoperative day with no needs of medical treatment. Nowadays, she does not present recurrence of hiatal hernia or pericardial complications.

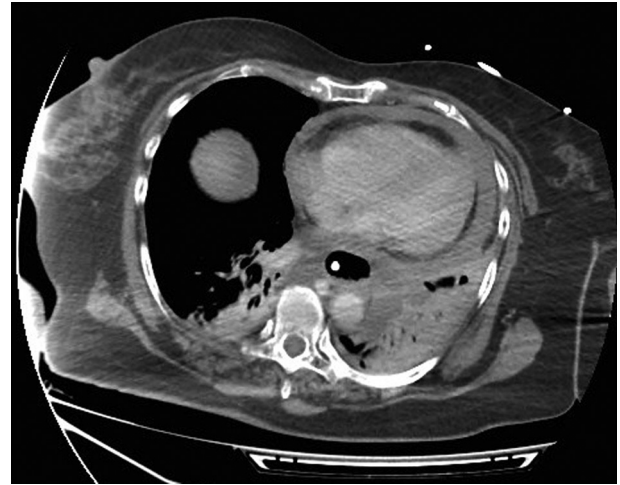

Fig. 2. CT-scan showing a bilateral pleural effusion and a large pericardial effusion causing the collapse of the right atrium and ventricle.

4. Case report 3

A 70-year-old woman with medical history of hypothyroidism referred suffering from chest pain and heartburn for months. She was studied with CT-scan and upper GI X-Ray series, which demonstrated a giant hiatal hernia with an intrathoracic stomach (Fig. 3). The patient underwent to laparoscopic surgery and a Nissen fundoplication with mesh reinforcement using Securestrap® was performed. At the second postoperative day the patient presented hypotension, tachycardia and irregular pulse. EKG showed an atrial fibrillation with rapid ventricular response. Treatment with anticoagulation and amiodarone was initiated. Thoracic X-Ray showed a bilateral pleural effusion that did not require drainage. However, the patient persisted with precordial pain and dyspnea at rest, reason why an urgent thoracic CT-scan was performed. The scan revealed an extrapericardial hematoma in the hernia sac with a mild left atrium compromise (Figs. 4 and 5).

Conservative treatment was decided and the patient condition improved until she became asymptomatic. She was discharged on the 15th postoperative day with medical treatment determined by the cardiologist.

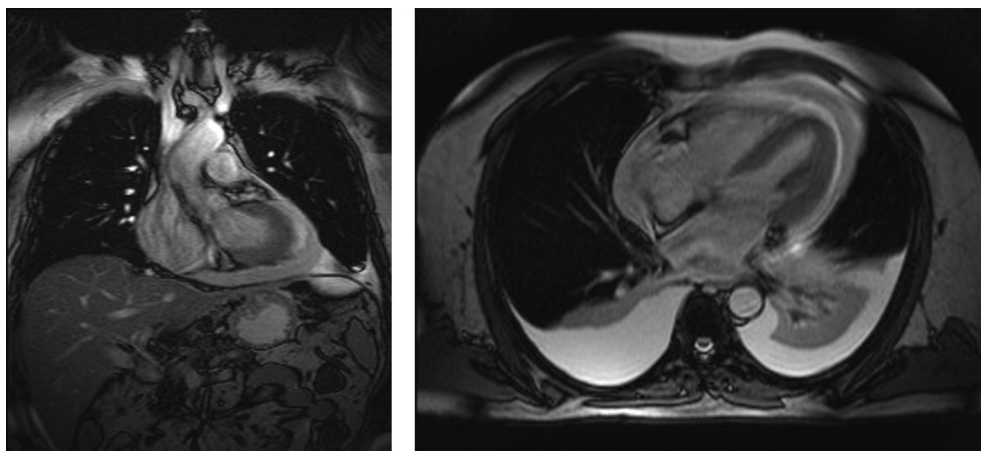


Fig. 1. Cardiac MRI showing a large pericardial effusion.

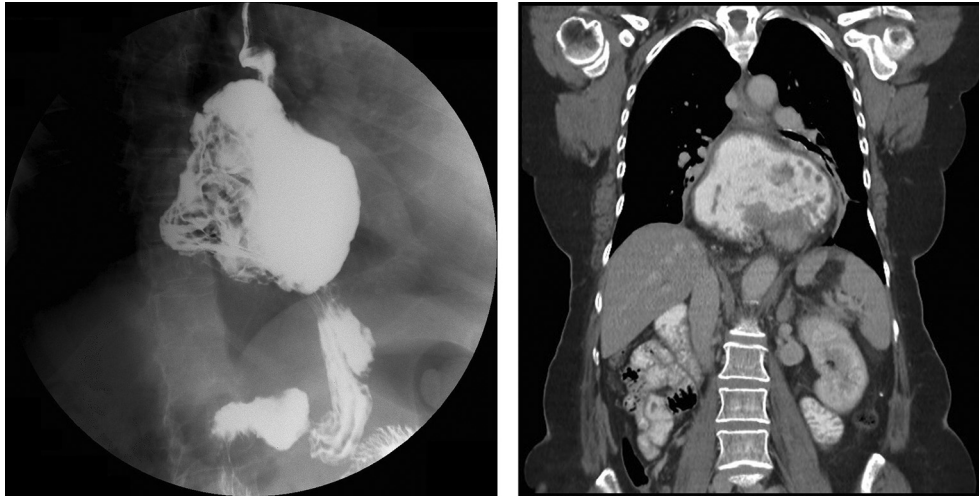


Fig. 3. A giant hiatal hernia with an intrathoracic stomach.

5. Discussion

Hiatal hernias occur in approximately 10% of the population. Paraesophageal hernia, or type II, represents 5–10% of all hiatal hernias. Type III (combined) and type IV (when an abdominal viscera different of the stomach is within the hernia sac) are progressive forms of these types of hernias. The term “giant paraesophageal hiatal hernia” refers to defects in which at least half of the stomach is located within the thorax on contrast radiography, the hernia measures at least 6 cm in length on preoperative endoscopy, or a distance between the crura is at least 5 cm noted in the intraoperative inspection [3].

Treatment of giant hiatal hernias is important because of their potentially complications such as gastric volvulus, anemia, obstruction, strangulation or perforation. Therefore, surgical treatment is recommended in all cases although some authors advocate for a conservative management in selected cases [4].

The minimally invasive approach for hiatal hernia repair has

become the standard of care in the surgical management of this problem. Laparoscopic hiatal hernia repair is also associated with a lower incidence of morbidity, a shorter recovery period and a shorter hospital stay compared to open repair [5].

Both laparoscopic and open repair report high recurrence rates [6]. Mesh hiatoplasty has shown to reduce the recurrence rate comparing with primary suture repair of the hiatus [7]. However, there are complications related to the use of prosthetic mesh. The possibility of migration of the mesh through the hiatus with breathing protruding into the esophagus, infection, mesh adhesions or the development of fibrotic strictures causing stenosis and dysphagia have been described [8]. Laparoscopic hiatal hernia repair has been associated with other complications like pneumothorax, pulmonary thromboembolism, postoperative leak or heart injury [9].

Cardiac complications related to laparoscopic fundoplication have been reported in the literature. Unusual cases of dysrhythmias and cardiac tamponade with intraoperative clinical expression have been described secondary to myocardial contusions after direct cardiac trauma [10,11]. Pericarditis tends to appear as a late complication [12] although there are cases with early presentation related to technical manouvers during the surgery [13]. When

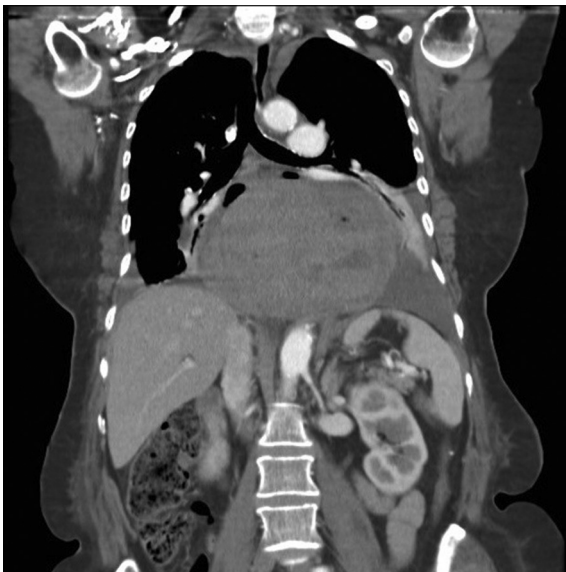

Fig. 4. Extrapericardial hematoma in the hernia sac with a mild left atrium compromise.

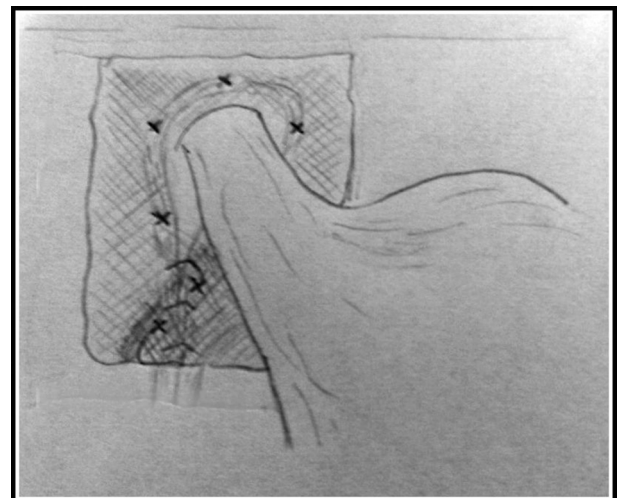


Fig. 5. Anatomical anchoring points of the mesh during the hiatal repair.

myopericarditis occurs [14], a pericardial effusion secondary to this inflammation of the pericardium is usually presented. When fluid (usually blood) accumulates rapidly, even small amounts, may cause tamponade, as in our first case.

Boccaro et al. evaluated the risk of cardiac injury during laparoscopic fundoplication without identifying an association between the laparoscopic technique and the incidence of cardiac complications [15].

Literature review reveals that cardiac complications may appear following fundoplication surgery, and more frequently if a diaphragmatic hernia repair has been performed. Among cardiac complications, tamponade is the most serious. There are severe cases reported in the literature associated to laparoscopic hiatal hernia repair, in which tamponade developed from the intraoperative period through the 14th postoperative days [16]. The etiology may be a consequence of anatomic constraints. Most cases of cardiac tamponade are due to direct injury of cardiac tissues or pericardium with the staples or sutures used during the fundoplication or during the placement of a mesh if a prosthetic reinforcement is performed [17,18]. There are different available anchorage devices. We have used Securestrap® which has a strap approximately 7.2 mm in length. Consequently, control over the depth of penetration becomes difficult and then, the surrounding tissues can be adversely affected. In contrast with other reports [17], we have no complications when helical strap were used. We propose that the mesh must be anchored only in the crura when using non-helical staples and not in the diaphragm to avoid cardiac injury.

Our cases illustrate a rare and hardly complication reported in the literature that can be life-threatening in the postoperative course. Diagnosis in cases of late bleeding can be delayed because the rhythm of hemorrhage is slow and the formation of an intrapericardial clot complicates the diagnosis and treatment, as occurred in our second case [19]. It is necessary to think about the possibility of an extrapericardial cause of cardiac tamponade following this surgery such as an hematoma located within the hernia sac, as occurred in the third case, or an immediate postoperative recurrence of the hiatal hernia [20]. Finally, cases reported illustrate the different options of management in case of cardiac tamponade: conservative treatment, percutaneous drainage and surgery.

6. Conclusion

During hiatal hernia repair it is important to take into account the technical aspects that can make possible the development of postoperative complications. Cardiac complications although rare, must be considered in any patient who develops signs of hemodynamic instability after a laparoscopic hernia repair, even if no cardiovascular risk factors or intraoperative incidences are presented. An early diagnosis and treatment result important to decrease the morbi-mortality associated.

Ethical approval

Ethical approval has been obtained by the.
Ethical Committee – Hospital Clínico Universitario de Valencia.

Sources of funding

None.

Author contribution

Dr. Fernandez and Dr. Diaz: Data collection.

Dr. Lopez, Dr. Martí and Dr. Ortega: Data analysis and writing.

Conflicts of interest

None.

Research registry

researchregistry80.

Guarantor

Dr. Fernando López Mozos.

Consent

Consent have been obtained from all three patients.

References

- [1] F.A. Ganderath, M.A. Carlson, J.K. Champion, A. Szold, N. Basso complication, R. Pointner, C.T. Frantzides, Prosthetic closure of the esophageal hiatus in large hiatal hernia repair and laparoscopic antireflux surgery, *Surg. Endosc.* 20 (2006) 367–379.
- [2] R.J. Stadlhuber, A.E. Sherif, S.K. Mittal, R.J. Fitzgibbons Jr., L. Michael Brunt, J.G. Hunter, T.R. Demeester, et al., Mesh complications after prosthetic reinforcement of hiatal closure: a 28-case series, *Surg. Endosc.* 23 (2009) 219–226.
- [3] Griffin, S.A. Raimes, J. Shenfine (Eds.), *Oesophagogastric Surgery: a Companion to Specialist Surgical Practice*, fifth ed., Saunders Elsevier, 2013.
- [4] N. Stylopoulos, G.S. Gazelle, D.W. Rattner, Paraesophageal Hernias: operation or observation? *Ann. Surg.* 236 (2002) 492–501.
- [5] G. Nilsson, J. Wenner, S. Larsson, F. Johnsson, Randomized clinical trial of laparoscopic versus open fundoplication for gastro-oesophageal reflux, *Br. J. Surg.* 91 (2004) 552–559.
- [6] P.R. Schauer, S. Ikramuddin, M.D. McLaughlin, T.O. Graham, A. Slivka, K.K. Lee, et al., Comparison of laparoscopic versus open repair of paraesophageal hernia, *Am. J. Surg.* 176 (1998) 659–665.
- [7] B.K. Oelschlager, C.A. Pellegrini, J. Hunter, N. Soper, M. Brunt, B. Sheppard, et al., Biologic prosthesis reduces recurrence after laparoscopic paraesophageal hernia repair, *Ann. Surg.* 244 (2006) 481–490.
- [8] J.M. Johnson, A.M. Carbonell, B.J. Carmody, M.K. Jamal, J.W. Maher, J.M. Kellum, et al., Laparoscopic mesh hiatoplasty for paraesophageal hernias and fundoplications: a critical analysis of the available literature, *Surg. Endosc.* 20 (2006) 362–366.
- [9] J.D. Luketich, K.S. Nason, N.A. Christie, A. Pennathur, B.A. Jobe, R.J. Landreneau, et al., Outcomes after a decade of laparoscopic giant paraesophageal hernia repair, *J. Thorac. Cardiovasc. Surg.* 139 (2010) 395–404.
- [10] C.E. Swide, P.F. Nyberg, Cardiac trauma: an unusual case of dysrhythmias and electrocardiographic changes during laparoscopic Nissen fundoplication, *Anesthesiology* 85 (1996) 209–211.
- [11] J. Farlo, D. Thawgahurai, M. Mikhail, K. Yaker, J. Sullivan, E. Morgan, Cardiac tamponade during laparoscopic Nissen fundoplication, *Eur. J. Anesthesiol.* 15 (1998) 46–247.
- [12] E.I. Sihvo, J.V. Räsänen, M. Hynninen, T.K. Rantanen, J.A. Salo, Gastropericardial fistula, purulent pericarditis, and cardiac tamponade after laparoscopic Nissen fundoplication, *Ann. Thorac. Surg.* 81 (2006) 356–358.
- [13] P. Alter, J.R. Schaefer, M. Herzum, R. Moosdorf, B. Maisch, Early occurrence of septic pericarditis after Nissen fundoplication, *Am. J. Med.* 115 (2003) 507–508.
- [14] G. Boccaro, S. Lopez, M. Hugué, C. Mann, P. Colson, Myopéricardite aiguë dans les suites d'une cure laparoscopique de reflux gastro-oesophagien, *Ann. Fr. Anesth. Réanim.* 17 (1998) 1148–1151.
- [15] G. Boccaro, Y. Pouzeratte, R. Troncin, A. Bonardet, A.M. Boullaran, P. Colson, et al., The risk of cardiac injury during laparoscopic fundoplication: cardiac troponin I and ECG study, *Acta Anaesthesiol. Scand.* 44 (2000) 398–402.
- [16] Y.E. Paz, J. Vazquez, M. Bessler, Cardiac tamponade as a complication of laparoscopic hiatal hernia repair: Case report and literature review, *Catheter. Cardiovasc. Interv.* 78 (2011) 819–821.
- [17] C.T. Frantzides, S.N. Welle, Cardiac tamponade as a life-threatening complication in hernia repair, *Surgery* 152 (2012) 133–135.
- [18] W. Makarewicz, L. Jaworski, M. Bobowicz, K. Roszak, K. Jaroszewicz, J. Rogowski, et al., Paraesophageal hernia repair followed by cardiac tamponade caused by ProTacks, *Ann. Thorac. Surg.* 94 (2012) 87–89.
- [19] E. García Vicente, A. Campos Nogué, Cardiac tamponade, *Med. Clin.* 130 (2008) 24–29.
- [20] J. Moore, J. Fraser, Outside the box: extra-pericardial tamponade due to acute recurrence of hiatus hernia, *Ann. Thorac. Surg.* 89 (2010) 1654–1656.