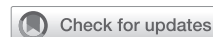

# Percutaneous decannulation reduces procedure length and rates of groin wound infection in patients on venoarterial extracorporeal membrane oxygenation



Sophia H. Roberts, MD,<sup>a</sup> Erin M. Schumer, MD,<sup>a</sup> Mary Sullivan, AGACNP-BC,<sup>a</sup> John Grotberg, MD,<sup>b</sup> Bianca Jenkins, BSN,<sup>a</sup> Irene Fischer, MPH,<sup>a</sup> Marci Damiano, BSN,<sup>a</sup> Matthew R. Schill, MD,<sup>a</sup> Muhammad F. Masood, MD,<sup>a</sup> Kunal Kotkar, MD,<sup>a</sup> and Amit Pawale, MD<sup>a</sup>

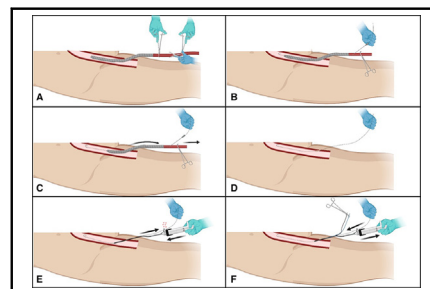
## ABSTRACT

**Objective:** Open decannulation from femoral venoarterial extracorporeal membrane oxygenation (VA-ECMO) carries high risk of morbidity, including groin wound infection. This study evaluated the impact of percutaneous decannulation on rates of groin wound infection in patients decannulated from femoral VA-ECMO.

**Methods:** Between January 1, 2022, and April 30, 2023, 47 consecutive patients received percutaneous femoral VA-ECMO and survived to decannulation. A percutaneous suture-mediated closure device was used for decannulation in patients with relatively smaller arterial cannulas. Patients with larger arterial cannulas or unsuccessful percutaneous closures underwent surgical cutdown and repair of the femoral artery. The primary outcome was arterial site wound infection following decannulation.

**Results:** Among the 47 patients who survived to decannulation from VA-ECMO, 21 underwent percutaneous decannulation and 27 underwent surgical cutdown. One patient underwent 2 VA-ECMO runs, one with percutaneous decannulation and one with surgical cutdown. Percutaneous decannulation was attempted in 22 patients, with 21 of 22 (95.5%) success rate. Decannulation procedure length was significantly shorter in the percutaneous group (79 minutes vs 148 minutes,  $P = .0001$ ). The percutaneous group had significantly reduced rates of groin wound complications (0% vs 40.7%,  $P = .001$ ) and groin wound infections (0% vs 22.2%,  $P = .03$ ) when compared with the surgical cutdown group. Three patients (14.3%) in the percutaneous group experienced vascular complications, including pseudoaneurysm at the distal perfusion catheter site and nonocclusive thrombus of the common femoral artery.

**Conclusions:** Percutaneous decannulation may reduce decannulation procedure length and rate of groin wound infection in patients who survive to decannulation from VA-ECMO. (JTCVS Open 2024;18:80-6)



Procedural steps for percutaneous decannulation from femoral VA-ECMO.

## CENTRAL MESSAGE

Percutaneous decannulation from femoral VA-ECMO with a suture-mediated closure device reduces procedure length and rates of groin wound infection.

## PERSPECTIVE

Open surgical cutdown and femoral artery repair during decannulation from VA-ECMO carries significant morbidity, with a 7% to 25% rate of groin wound infection. Percutaneous closure offers an attractive alternative to open cutdown. These results support the use of percutaneous decannulation to reduce groin wound infections in patients decannulated from femoral VA-ECMO.

In adult patients, percutaneous femoral venoarterial extracorporeal membrane oxygenation (VA-ECMO) cannulation involves placement of a 15-Fr to 21-Fr cannula in the common femoral artery (CFA). Due to the relatively large size of the arterial sheath, decannulation from VA-ECMO has

traditionally required open surgical cutdown of the groin with exposure and repair of the CFA to prevent CFA pseudoaneurysm and persistent bleeding.<sup>1</sup> Surgical cutdown of the groin for decannulation is associated with significant morbidity, as well as vascular and wound complications.<sup>2,3</sup>

From the <sup>a</sup>Division of Cardiac Surgery, Department of Surgery, and <sup>b</sup>Division of Pulmonary and Critical Care Medicine, Department of Medicine, Washington University in St Louis School of Medicine, St Louis, Mo.

Read at The American Association for Thoracic Surgery Mechanical Support and Thoracic Transplantation Summit, Toronto, Ontario, Canada, June 9-10, 2023.

Received for publication Sept 19, 2023; revisions received Dec 19, 2023; accepted for publication Jan 3, 2024; available ahead of print Feb 19, 2024.

Address for reprints: Amit Pawale, MD, Division of Cardiothoracic Surgery, Washington University School of Medicine, 660 South Euclid Ave Campus, Box 8234, St Louis, MO 63110 (E-mail: [amitp@wustl.edu](mailto:amitp@wustl.edu)).

2666-2736

Copyright © 2024 The Authors. Published by Elsevier Inc. on behalf of The American Association for Thoracic Surgery. This is an open access article under the CC BY-NC-ND license (<http://creativecommons.org/licenses/by-nc-nd/4.0/>).  
<https://doi.org/10.1016/j.xjon.2024.01.012>

### Abbreviations and Acronyms

CFA	= common femoral artery
DPC	= distal perfusion catheter
SFA	= superficial femoral artery
VA-ECMO	= venoarterial extracorporeal membrane oxygenation

Rates of groin wound infection after open decannulation from femoral VA-ECMO range between 7% and 25% and are associated with longer hospital lengths of stay.<sup>3-5</sup>

The rate of postdecanulation wound infection may be reduced by a percutaneous approach to CFA repair. The Perclose ProGlide (Abbott Vascular Inc) is a suture-based percutaneous closure device that deploys a suture on either side of the arterial wall, mimicking surgical closure for access sites created by large-bore catheters.<sup>6</sup> Although several reports have shown nonsignificant reduction in groin wound infection with percutaneous decannulation, these studies examined wound infection during the index hospital stay, within 30 days of cannulation, or within an undefined study period.<sup>7-9</sup> In order to further characterize the incidence of and factors contributing to postdecanulation wound infection, there is a need for further studies examining wound infection as the primary end point after percutaneous and open surgical decannulation from VA-ECMO. In this study, we examined the rates of groin wound infection following VA-ECMO decannulation by percutaneous CFA repair and open surgical cutdown.

## METHODS

### Study Population

This study (institutional review board #202303137, March 27, 2023) was approved by the Washington University School of Medicine Institutional Review Board. The approval included a waiver of informed consent. Patient data including preoperative characteristics, operative details, postoperative course, and longitudinal follow-up were obtained from our institutional Extracorporeal Life Support Organization database as well as manual review of the electronic medical records. From January 1, 2022, to April 30, 2023, 87 patients underwent VA-ECMO at our institution (Figure 1). Of these 87 patients, the following patients were excluded: 28 patients died on ECMO and were not decannulated, and 11 underwent central or nonfemoral peripheral cannulation. The remaining 47 patients survived to decannulation from femoral VA-ECMO and were included in this study.

### VA-ECMO Decannulation

Patients were divided into percutaneous closure and open cutdown groups based on the method of femoral arterial decannulation. Unless the patient was already receiving broad-spectrum antibiotics, patients received antibiotic prophylaxis with 2 g of intravenous cefazolin or 1 g of intravenous vancomycin before decannulation. The percutaneous technique was first performed by 1 attending surgeon at our institution and then adopted by 3 other surgeons during the study period. A Perclose ProGlide device (Abbott Vascular Inc), was used for decannulation in accordance with surgeon preference, the presence of relatively smaller arterial cannulas (15-17

Fr), and the absence of an existing vascular complication. Fluoroscopy was not used to visualize cannula placement during percutaneous decannulation because all cannulations at our institution are performed under ultrasound guidance to ensure cannulation of the CFA. All patients cannulated at outside hospitals and then transferred were decannulated by surgical cutdown only.

### Percutaneous Decannulation

The arterial cannula was accessed, and a 0.035-inch guidewire wire was advanced to the descending aorta under transesophageal echocardiogram (Figure 2, A and B). The arterial cannula was removed over the wire (Figure 2, C and D) and 2 percutaneous suture-mediated closure devices were applied at the 10- and 2-o'clock positions (Figure 2, E and F). It is routine at our institution to place a distal perfusion catheter (DPC) ipsilateral to the arterial cannula. If adequate hemostasis was achieved with a pedal pulse per Doppler, the procedure was completed by removing the DPC, holding manual pressure on the DPC site, and reversing heparin with protamine. In the event of significant bleeding or loss of pedal pulse, the decannulation approach was converted to surgical cutdown.

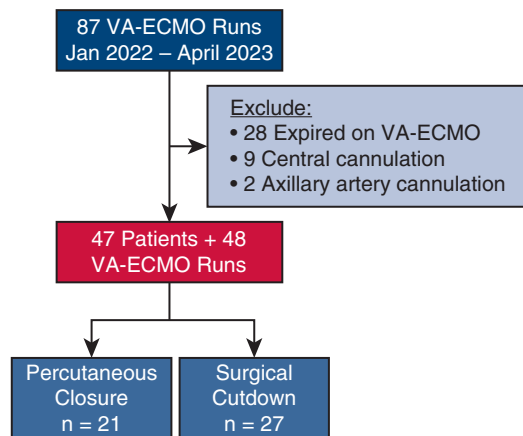
### Open Surgical Cutdown

This consisted a vertical incision over the femoral vessels. The CFA was dissected out and proximally and distally controlled with vessel loops. The CFA was then clamped proximally and distally as the arterial cannula was removed. The artery was debrided until healthy tissue was visualized. The clamps were briefly released to flush the artery, followed by repair with simple interrupted 5-0 PROLENE sutures (Ethicon). The DPC was removed from the superficial femoral artery (SFA), and the artery was also repaired primarily with simple interrupted 5-0 PROLENE sutures. Open groin wounds were closed in 3 layers. However, there was variability in closure of the final layer, as some surgeons used interrupted nylon sutures while others used staples.

Application of negative-pressure wound therapy at the time of decannulation is not routine for our program. Of the 27 patients in the surgical cutdown group, 5 had an incisional negative-pressure wound therapy placed at the time of decannulation. One patient underwent decannulation at the time of heart transplant. The remaining 4 patients underwent concomitant vascular repair by Vascular Surgery at the time of decannulation due to lower-limb ischemia requiring thrombectomy, patch angioplasty, and/or fasciotomies. Repeat imaging of the arterial cannula or DPC sites was not routinely performed before or following decannulation unless a clinical issue arose, including groin swelling or diminished distal pulses.

### Study End Points

The primary outcome was arterial-site wound infection at any point following decannulation, as defined by reopening of the groin incision, surgical debridement, or initiation of antibiotics for wound infection. Secondary outcomes included length of decannulation procedure time, hospital length of stay, and inpatient survival. Length of decannulation procedure time was calculated as the time between procedure start and end times recorded in the electronic medical record. Patients who underwent decannulation with concomitant procedures were excluded from this secondary procedure time analysis. Concomitant procedures included percutaneous ventricular assist device placement, reconfiguration to central ECMO, left ventricular assist device placement, heart transplant, ascending aortic repair, or mitral valve replacement, and coronary artery bypass grafting. These patients were excluded from the procedure time analysis, as the exact timing of decannulation could not be determined from the procedure record. Median length of follow-up was 184 days (range, 18-483 days).



**FIGURE 1.** Study flow diagram: patient cohort selection and relevant inclusion and exclusion criteria. VA-ECMO, Venoarterial extracorporeal membrane oxygenation.

### Statistical Analysis

All statistical analysis was performed using Stata software, version 17 (StataCorp). Characteristics of groups are presented as counts with percentages and compared using the Fisher exact test. Continuous variables are expressed as median (minimum, maximum) and compared using the Mann-Whitney *U* test.

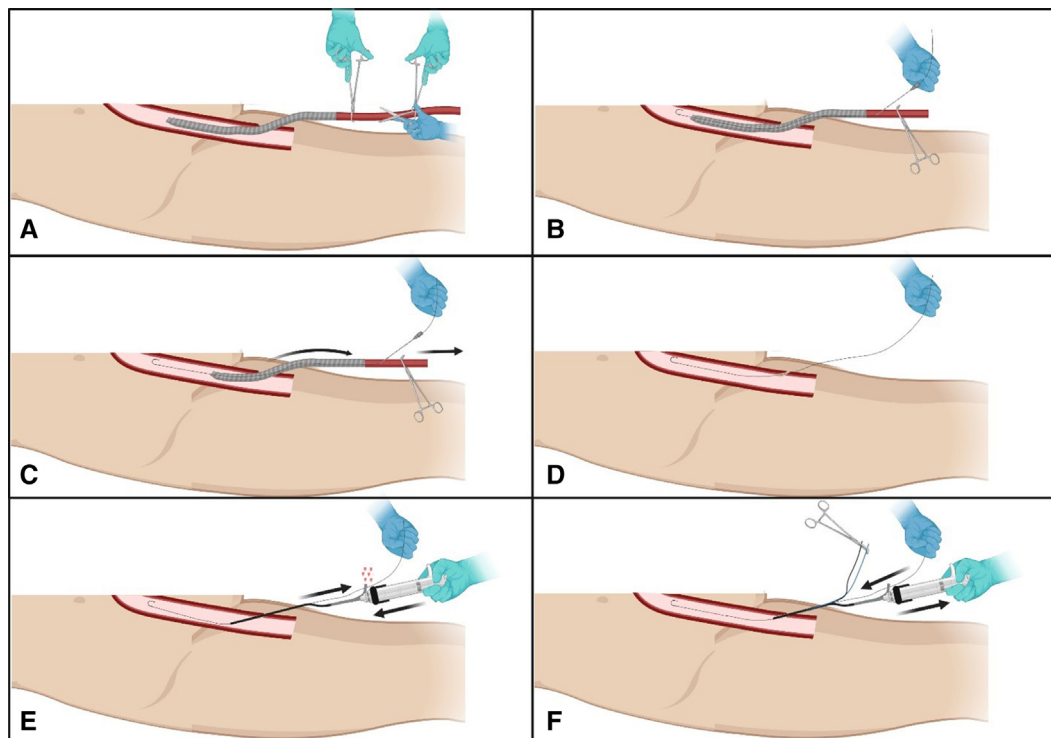
## RESULTS

### Study Population and Baseline Characteristics

Among the 47 patients who survived to decannulation from femoral VA-ECMO, 21 patients underwent percutaneous decannulation and 27 patients underwent surgical cutdown. One patient underwent left femoral cannulation and open decannulation, followed by a second VA-ECMO run with right femoral cannulation and percutaneous decannulation. Patients in both groups were primarily male and in their 50s, with no significant differences in baseline demographics between groups (Table 1). Indications for VA-ECMO included acute myocardial infarction, postcardiotomy cardiogenic shock, cardiac arrest, and refractory cardiogenic shock (Table 1).

### Periprocedural Characteristics

Percutaneous decannulation was attempted in 22 patients, with success obtained in 21 of 22 (95%). During the one failed percutaneous decannulation, inadequate hemostasis was obtained after deployment of 2 percutaneous suture-mediated devices. Decannulation was converted to an open approach, and a left groin cutdown was immediately performed with primary repair of the left external iliac



**FIGURE 2.** Technical steps for percutaneous decannulation of femoral arterial cannula using the ProGlide device (Abbott Vascular Inc). Figure created with Biorender.com. A, The arterial limb of VA ECMO is divided between clamps; B, An 18-gauge needle is inserted into the arterial cannula, and a 0.035-inch J wire is inserted through the needle in descending aorta; C, The arterial cannula is removed, keeping the wire in place; D, Wire in situ; E, The first ProGlide device is inserted the wire is removed before deployment of sutures; F, The wire is reinserted after the first ProGlide sutures are deployed, and the used ProGlide device is removed.

TABLE 1. Baseline demographics

Characteristic	Percutaneous closure (n = 21)	Open cutdown (n = 27)	P value
Age, y	52 (24-72)	53 (17-83)	.62
Female sex, n (%)	3 (14.3%)	9 (33.3%)	.19
Body mass index, kg/m <sup>2</sup>	30.0 (20.3-47.3)	28.7 (20.0-42.8)	.39
Hypertension, n (%)	16 (76.2%)	16 (59.3%)	.36
Hyperlipidemia, n (%)	17 (81.0%)	18 (66.7%)	.34
Type 2 diabetes, n (%)	7 (33.3%)	5 (18.5%)	.32
Peripheral artery disease, n (%)	1 (4.8%)	4 (14.8%)	.37
Cerebrovascular accident, n (%)	2 (9.5%)	0 (0%)	.19
Chronic kidney disease, n (%)	6 (28.6%)	3 (11.1%)	.15
Congestive heart failure, n (%)	4 (19.1%)	7 (25.9%)	.73
End-stage liver disease, n (%)	0 (0%)	1 (3.7%)	.99
Current smoker, n (%)	4 (19.1%)	6 (27.2%)	.99
Immunocompromised, n (%)	1 (4.8%)	5 (18.5%)	.21
Indication for VA-ECMO			
Acute myocardial infarction	5 (23.8%)	5 (18.5%)	.73
Postcardiotomy	4 (19.1%)	6 (22.2%)	.99
Cardiac arrest	4 (19.1%)	10 (37.0%)	.21
Refractory cardiogenic shock	8 (38.1%)	6 (22.2%)	.34

VA-ECMO, Venoarterial extracorporeal membrane oxygenation.

artery. There was no significant difference in median arterial cannula size between groups ( $P = .25$ ). Of the 21 patients in the percutaneous group, 19 had a 17-Fr arterial cannula, 1 had a 15-Fr arterial cannula, and 1 had a 19-Fr arterial cannula. In total, 91% of the entire cohort had a DPC placed during VA-ECMO support, with no significant differences between groups ( $P = .99$ ). Arterial cannulas were in place up to 14 days in the percutaneous group and up to 19 days in the surgical cutdown group (Table 2). Excluding patients who underwent concomitant aortic or

valve surgery, ventricular assist device placement, or heart transplant, we found that decannulation procedure length was significantly shorter in the percutaneous group (79 minutes vs 148 minutes,  $P = .0001$ ) (Table 2).

**Postoperative Outcomes and Complications**

There was a significant reduction in the rate of groin wound complications in the percutaneous group compared with the surgical cutdown group (0% vs 40.7%,  $P = .001$ ) (Table 3). Among the surgical cutdown group,

TABLE 2. Perioperative VA-ECMO characteristics

Characteristic	Percutaneous (n = 21)	Surgical cutdown (n = 27)	P value
Arterial cannula size, Fr	17 (15-19)	17 (15-21)	.25
Venous cannula size, Fr	25 (25-26)	25 (21-25)	.09
Ipsilateral arterial and venous catheters, n (%)	17 (81.0%)	20 (74.1%)	.73
Distal perfusion catheter, n (%)	19 (90.5%)	24 (88.9%)	.99
Additional MCS, n (%)	13 (61.9%)	15 (55.6%)	.77
CRRT during ECMO, n (%)	12 (57.1%)	18 (66.7%)	.56
Days to decannulation, d	5 (2-14)	6 (1-19)	.052
Decannulation procedure length, min	79 (24-170)	148 (49-248)	<b>.0001</b>
Negative-pressure wound therapy, n (%)	0 (0%)	6 (22.2%)	

P values in bold are statistically significant. MCS, Mechanical circulatory support; CRRT, continuous renal replacement therapy; ECMO, extracorporeal membrane oxygenation.

TABLE 3. Postoperative outcomes and complications of VA-ECMO

Characteristic	Percutaneous (n = 21)	Surgical cutdown (n = 27)	P value
Inpatient mortality	2 (11.8%)	9 (33.3%)	.16
Hospital length of stay, d	35 (6-87)	41 (12-144)	.49
Groin wound complications	0 (0%)	11 (40.7%)	<b>.001</b>
Wound infection	0 (0%)	6 (22.2%)	<b>.03</b>
Complete dehiscence	0 (0%)	3 (11.5%)	.24
Seroma	0 (0%)	1 (3.9%)	.99
Drain complication	0 (0%)	1 (3.9%)	.99
Vascular complications	3 (14.3%)	0 (0%)	.08
SFA pseudoaneurysm	2 (9.5%)	0 (0%)	.10
Nonocclusive thrombus	1 (4.8%)	0 (0%)	.19

P values in bold are statistically significant. SFA, Superficial femoral artery.

6 patients developed wound infections, 3 had wound dehiscence, and 1 had seroma requiring drainage. One patient in the surgical cutdown group required return to the operating room for a drain complication without signs of infection. One patient underwent left femoral cannulation and open decannulation, followed by a second VA-ECMO run with right femoral cannulation and percutaneous decannulation. This patient subsequently developed a wound infection at the surgical cutdown site but not the percutaneous decannulation site.

Three patients (14.3%) in the percutaneous group experienced vascular complications. These 3 patients were decannulated after 2 to 7 days. Two patients developed a pseudoaneurysm at the DPC site. Both patients were evaluated by interventional radiology, and one required thrombin injection. The third patient developed distal pulse discrepancies following percutaneous decannulation. Three days following decannulation, computed tomography angiography revealed a nonocclusive thrombus in the proximal left common femoral artery near the percutaneous suture-mediated closure device. A left groin cutdown was performed with left iliofemoral endarterectomy and patch angioplasty. There was no significant difference in inpatient mortality (11.8% vs 33.3%,  $P = .16$ ) or hospital length of stay (35 days vs 41 days,  $P = .49$ ) between percutaneous and surgical cutdown groups. The overall mortality rate was significantly reduced in the percutaneous group compared with the surgical cutdown group (9.5% vs 37.0%,  $P = .03$ ).

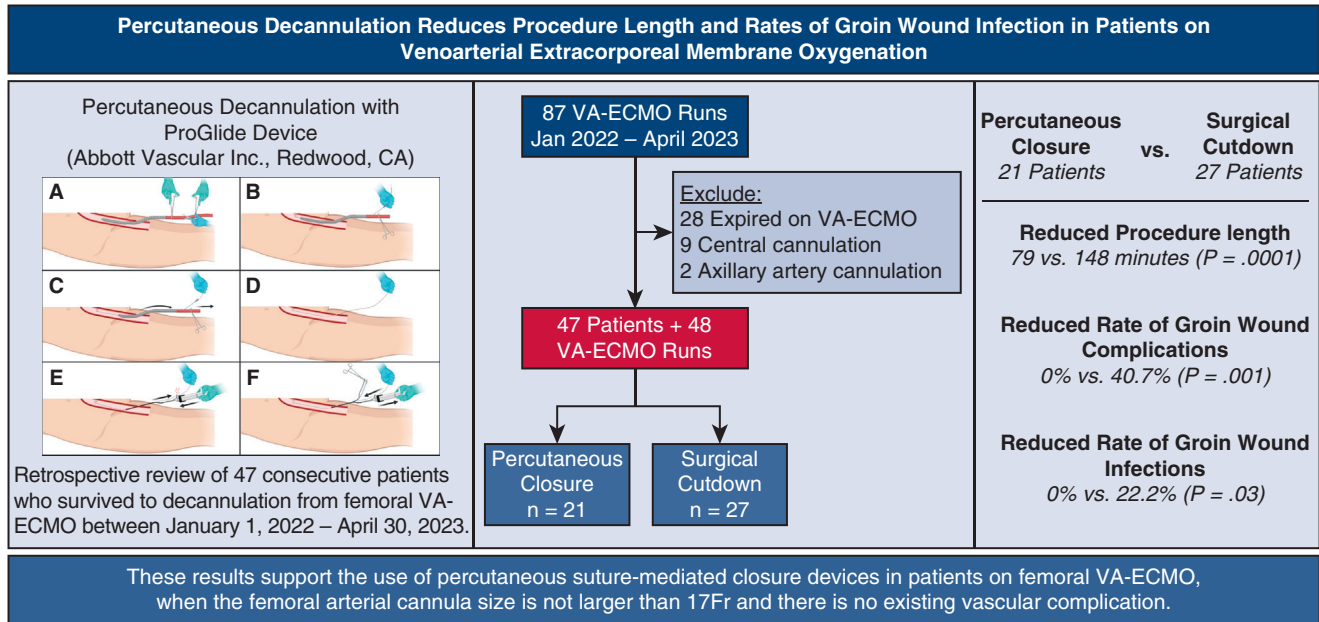
## DISCUSSION

This study examined the procedural outcomes of a percutaneous decannulation technique using a suture-mediated percutaneous closure device. In our cohort of 47 consecutive patients decannulated from femoral VA-ECMO, we observed a significant decrease in groin wound infections in patients who underwent percutaneous decannulation compared with those who underwent surgical cutdown. The percutaneous approach also substantially decreased

operative times when compared to surgical cutdown. See Figure 3 for a graphical abstract of the study.

Surgical cutdown of the femoral vessels is associated with high risk for wound complications, including infection, seroma, and lymphatic leakage.<sup>10</sup> By eliminating the groin cutdown and lymphatic disruption, percutaneous decannulation from femoral VA-ECMO may reduce these morbid complications. Percutaneous decannulation can be performed using suture-mediated closure devices, such as the ProGlide, or plug-based arterial closure devices, such as the Angio-Seal (Terumo) and MANTA (Teleflex). The Perclose ProGlide device can be deployed at the time of arterial cannulation in a “pre-closure” technique, which has been widely used during endovascular aortic repair and transcatheter aortic valve implantation.<sup>11,12</sup> The instructions for use of the Perclose ProGlide states that at least 2 devices and the preclosure technique must be used for arterial and venous sheath sizes greater than 8 Fr.<sup>13</sup> Preclosure of the CFA has been shown to significantly decrease the rate of groin wound infections in patients on VA-ECMO, including immunosuppressed patients supported on VA-ECMO during lung transplantation.<sup>14,15</sup> However, VA-ECMO is often initiated in an emergent fashion, where the time, materials, and team expertise needed for preclosure may not be available. To address this issue, there have been several other reports of total percutaneous “post-closure” for CFA repair with deployment of the ProGlide device at the time of decannulation.<sup>7,16-18</sup>

Previous studies have demonstrated that preclosure percutaneous decannulation technique using the Perclose ProGlide reduces rates of groin wound infection.<sup>9,14,15</sup> Our study demonstrates that postclosure percutaneous decannulation using the Perclose ProGlide significantly lowers the risk of groin wound infection after VA-ECMO. Multiple case reports and small case series similarly report a 0% rate of groin wound infection using this postclosure technique.<sup>17,18</sup> Hwang and colleagues<sup>7</sup> did not report a significant reduction in groin wound infections with percutaneous decannulation. However, the groin wound



**FIGURE 3.** Percutaneous decannulation of VA-ECMO reduces procedure length and groin wound infection. VA-ECMO, Venoarterial extracorporeal membrane oxygenation.

infection rates observed were exceptionally low in both the percutaneous and surgical cutdown groups (0% vs 3.4%,  $P = .50$ ). Of note, their study population also had a mean body mass index of 23, whereas the median body mass index of our percutaneous and surgical cutdown groups were 30.0 and 28.7, respectively.<sup>7</sup> Majunke and colleagues<sup>16</sup> reported 13% wound infection following percutaneous decannulation from VA-ECMO using the Perclose ProGlide; however, the authors note that decannulation was performed at the patient’s bedside in some instances. We perform all our percutaneous decannulations in the operating room to both optimize sterility and allow for immediate conversion to surgical cutdown if issues with hemostasis or limb ischemia are encountered.

Notably in our series, no patients in the percutaneous group developed groin wound complications. However, we observed a 14.3% rate of vascular complications among the percutaneous decannulation group. The 3 patients in the percutaneous group who developed vascular complications were decannulated after 2 to 7 days. Only 3 patients in the percutaneous group were decannulated after 7 days; however, none of these patients developed wound or vascular complications. Our institution does not routinely perform postdecanulation imaging unless a clinical issue arises, such as diminished distal pulses, hematoma, etc. The 2 pseudoaneurysms in our series were discovered in the postdecanulation period due to groin swelling and subsequent computed tomography angiography.

Vascular complications at the DPC site following percutaneous decannulation from VA-ECMO have been reported in other studies.<sup>19,20</sup> In a series of 10 patients who underwent percutaneous decannulation with the MANTA device (Teleflex), Shah and colleagues<sup>20</sup> describe their method for routine repair of the DPC site at the time of removal with an Angio-Seal VIP (Terumo Interventional Systems) or MYNX (Cardinal Health) vascular closure device. However, 2 of these patients subsequently developed a pseudoaneurysm at the SFA DPC site, one of which required thrombin injection whereas the other was observed. One patient did not undergo SFA repair with a closure device due to the presence of diffuse arterial disease and the second experienced a failure of the MYNX device.<sup>20</sup> These pseudoaneurysms were both identified on postdecanulation imaging, but the authors do not describe whether the patients were also symptomatic. It remains unclear whether there is a benefit to additional percutaneous repair of the DPC site at the time of decannulation, or whether there would be more complications due to the relatively smaller size of SFA. In addition, the instructions for use for the Perclose ProGlide states that device should not be used for puncture sites in the SFA due to risk of pseudoaneurysm, intimal dissection, or acute vessel thrombosis.<sup>13</sup>

This study has several limitations. First, this is a single-center retrospective study with relatively small numbers in both the percutaneous and open decannulation groups. Another major limitation of this study is that decannulation

technique was influenced by the inherent selection bias of the operating surgeon. The postclosure percutaneous decannulation technique was introduced to our institution by 1 surgeon and later adopted by 3 additional surgeons. Short-term survival (data not shown) was observed to be better in patients undergoing percutaneous decannulation, suggesting that some degree of selection bias was present at the time of decannulation. It is unclear how the possible selection bias of each surgeon may have changed during the study period, making it impossible to account for the confounding variables between these 2 relatively small groups. The length of follow-up was also relatively short, given that the percutaneously decannulation technique was only recently adopted at our institution. Only 1 patient in the percutaneous group had a 19-Fr arterial cannula, so we cannot make definitive conclusions regarding larger cannula sizes. Furthermore, only patients who underwent femoral arterial cannulation were included in this study. Therefore, our findings regarding arterial cannula-site wound infection cannot be generalized to patients who underwent central or axillary cannulation. Lastly, while our study demonstrates the safety of percutaneous postclosure decannulation, the superiority of this technique over open decannulation can only be proven with a larger, randomized study.

## CONCLUSIONS

Percutaneous decannulation is safe and may reduce both decannulation procedure length and the rate of groin wound infections in patients who survive to decannulation from percutaneous femoral VA-ECMO. These results support the use of percutaneous suture-mediated closure devices in these patients, when the femoral arterial cannula size is not larger than 17 Fr and there is no existing vascular complication.

## Conflict of Interest Statement

The authors reported no conflicts of interest.

The *Journal* policy requires editors and reviewers to disclose conflicts of interest and to decline handling or reviewing manuscripts for which they may have a conflict of interest. The editors and reviewers of this article have no conflicts of interest.

## References

- Danial P, Hajage D, Nguyen LS, et al. Percutaneous versus surgical femoro-femoral veno-arterial ECMO: a propensity score matched study. *Intensive Care Med*. 2018;44(12):2153-2161.
- Glorion M, Mercier O, Mitilian D, et al. Central versus peripheral cannulation of extracorporeal membrane oxygenation support during double lung transplant for pulmonary hypertension. *Eur J Cardiothorac Surg*. 2018;54(2):341-347.
- Haddad P, Chasin C, Xu J, Peden E, Rahimi M. Single-center surgical site infection rate after peripheral ECMO decannulation and surgical repair. *Ther Adv Infect Dis*. 2022;9:20499361221132148.
- Lamb KM, Hirose H. Vascular complications in extracorporeal membrane oxygenation. *Crit Care Clin*. 2017;33(4):813-824.
- Smood B, Fowler C, Rao SD, et al. Subacute groin complications related to ECMO cannulation are associated with longer hospitalizations. *J Artif Organs*. 2023;26(2):119-126.
- Del Prete A, Della Rocca DG, Calcagno S, et al. Perclose ProGlide for vascular closure. *Future Cardiol*. 2021;17(2):269-282.
- Hwang JW, Yang JH, Sung K, et al. Percutaneous removal using Perclose ProGlide closure devices versus surgical removal for weaning after percutaneous cannulation for venoarterial extracorporeal membrane oxygenation. *J Vasc Surg*. 2016;63(4):998-1003.e1.
- Liu Z, Xu Y, Xu X, et al. Comparison of success rate and complications of totally percutaneous decannulation in patients with veno-arterial extracorporeal membrane oxygenation and endovascular aneurysm repair. *Front Med (Lausanne)*. 2021;8:724427.
- Martin-Tuffreau AS, Bagate F, Boukantar M, et al. Complete percutaneous angio-guided approach using preclosing for venoarterial extracorporeal membrane oxygenation implantation and explantation in patients with refractory cardiogenic shock or cardiac arrest. *Crit Care*. 2021;25(1):93.
- Salma M, Takayama H, Garan AR, et al. Incidence and risk factors of groin lymphocele formation after venoarterial extracorporeal membrane oxygenation in cardiogenic shock patients. *J Vasc Surg*. 2018;67(2):542-548.
- Griese DP, Reents W, Diegeler A, Kerber S, Babin-Ebell J. Simple, effective and safe vascular access site closure with the double-ProGlide preclose technique in 162 patients receiving transfemoral transcatheter aortic valve implantation. *Catheter Cardiovasc Interv*. 2013;82(5):E734-E741.
- Lee WA, Brown MP, Nelson PR, Huber TS. Total percutaneous access for endovascular aortic aneurysm repair ("Preclose" technique). *J Vasc Surg*. 2007;45(6):1095-1101.
- Abbott Vascular. Perclose ProGlide® Suture-Mediated Closure (SMC) System. Accessed November 23, 2023. [https://www.accessdata.fda.gov/cdrh\\_docs/pdf/P960043S097D.pdf](https://www.accessdata.fda.gov/cdrh_docs/pdf/P960043S097D.pdf)
- Chandel A, Desai M, Ryan LP, Clevenger L, Speir AM, Singh R. Preclosure technique versus arterial cutdown after percutaneous cannulation for venoarterial extracorporeal membrane oxygenation. *J Thorac Cardiovas Surg Tech*. 2021;10:322-330.
- Pellenc Q, Girault A, Roussel A, et al. Preclosing of the femoral artery allows total percutaneous venoarterial extracorporeal membrane oxygenation and prevents groin wound infection after lung transplantation. *Eur J Cardiothorac Surg*. 2020;58(2):371-378.
- Majunke N, Mangner N, Linke A, et al. Comparison of percutaneous closure versus surgical femoral cutdown for decannulation of large-sized arterial and venous access sites in adults after successful weaning of veno-arterial extracorporeal membrane oxygenation. *J Invasive Cardiol*. 2016;28(10):415-419.
- Tian L, Zhang L, Zhang N, et al. Case report: total percutaneous post-closure of femoral arterial access sites after veno-arterial extracorporeal membrane oxygenation. *Front Med (Lausanne)*. 2022;9:980122.
- Xu X, Liu Z, Han P, et al. Feasibility and safety of total percutaneous closure of femoral arterial access sites after veno-arterial extracorporeal membrane oxygenation. *Medicine (Baltimore)*. 2019;98(45):e17910.
- Bemtgen X, Heidt T, Zotzmann V, et al. Venoarterial extracorporeal membrane oxygenation decannulation using the novel Manta vascular closure device. *Eur Heart J Acute Cardiovasc Care*. 2020;9(4):342-347.
- Shah A, Ghoreishi M, Taylor BS, Toursavadkoshi S, Kaczorowski DJ, University of Maryland Medical Center Extracorporeal Membrane Oxygenation Group. Complete percutaneous decannulation from femoral venoarterial extracorporeal membrane oxygenation. *J Thorac Cardiovas Surg Tech*. 2021;6:75-81.

**Key Words:** ECMO, percutaneous decannulation, suture-mediated closure device, groin wound infection