

## Surgical technique

## Antibiotic cement spacer for isolated medial wall acetabular deficiency in the setting of infected hip arthroplasty

Kevin S. Weiss, DO <sup>a</sup>, Kyle V. McGivern, DO <sup>b</sup>, Juan C. Suarez, MD <sup>c,\*</sup>, Jesus M. Villa, MD <sup>d</sup>, Preetesh D. Patel, MD <sup>d</sup>

<sup>a</sup> Broward Health Medical Center, Fort Lauderdale, FL, USA

<sup>b</sup> Southwest Orthopaedic and Reconstructive Specialists, Oklahoma City, OK, USA

<sup>c</sup> Miami Orthopedics and Sports Medicine Institute/Baptist Health South Florida, Kendall, FL, USA

<sup>d</sup> Cleveland Clinic Florida, Weston, FL, USA

## ARTICLE INFO

## Article history:

Received 4 January 2018

Received in revised form

5 February 2018

Accepted 14 February 2018

Available online 23 March 2018

## Keywords:

Periprosthetic joint infection

Antibiotic spacer

Total hip arthroplasty

Acetabular bone loss

## ABSTRACT

Periprosthetic joint infections remain challenging for orthopaedic surgeons. These are typically treated with 2-stage revision with an antibiotic spacer and arthroplasty reimplantation after infection eradication. We report a novel technique to create an antibiotic cement spacer construct in the setting of significant acetabular medial wall destruction due to osteolysis and infection. The medial wall of the acetabulum was reconstructed using antibiotic cement with 2 screws acting as a rebar. An acetabular liner was then cemented into place forming a cement construct similar to a reconstruction cage in function. This technique created a firm acetabular construct that allowed for the placement of a stable articulating spacer. The spacer allowed for infection eradication and was successfully converted into a revision total hip arthroplasty.

© 2018 The Authors. Published by Elsevier Inc. on behalf of The American Association of Hip and Knee Surgeons. This is an open access article under the CC BY-NC-ND license (<http://creativecommons.org/licenses/by-nc-nd/4.0/>).

## Introduction

Two-stage revision hip arthroplasty for the treatment of periprosthetic joint infection (PJI) is challenging. It is crucial not only to eradicate the infection, but also to reconstruct the joint once the infection has been treated. Static or articulating antibiotic cement spacers followed by revision arthroplasty is the most common approach in the management of PJI. In North America, 2-stage revision with placement of an antibiotic spacer has led to success rates in excess of 90% and has therefore become the standard of care for PJI [1,2]. The success of 2-stage revision with an antibiotic spacer may be affected by several clinical factors including the virulence of the organism and antibiotic resistance if antibiotic cement was used at the index operation [1,2]. In a study

by Leung et al. [3], a 21% recurrence rate was found in patients treated with 2-stage revision hip arthroplasty who were infected with methicillin-resistant *Staphylococcus aureus* or methicillin-resistant *Staphylococcus epidermidis*.

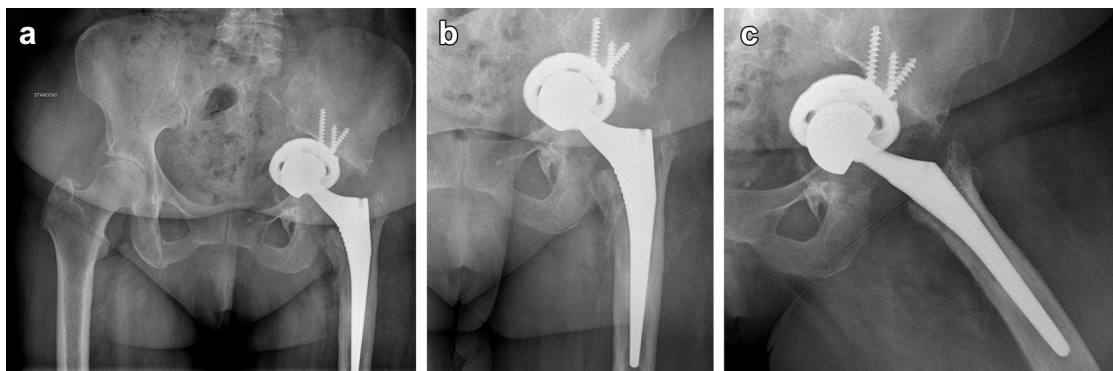
Bone loss, on either the femoral or acetabular side, represents a significant challenge when it comes to revision total hip arthroplasty. In the setting of infection, the challenge can be even greater due to the difficulty in implanting a stable cement spacer while keeping in mind the need for future surgery. Therefore, the goals of the first stage of a revision arthroplasty secondary to infection are not just the eradication of it, but also, to preserve bone stock for the second-stage revision (reimplantation).

There have been several techniques described in the literature on how to manage bone loss in the setting of periprosthetic hip infections. Many of these techniques describe the placement of a spacer when in face of supra-acetabular bone loss. Ben-Lulu et al. [4] did describe the use of reconstruction cages or roof-ring constructs on the acetabular side for reinforcement of medial wall defects. Baker et al. [5] presents a technique in which cancellous screws in the ileum followed by cement and a polyethylene liner are used to create a cement spacer in the setting of supra-acetabular osteolysis. Rogers et al. [6] demonstrate another technique in which screws in the ileum and antibiotic cement in the

One or more of the authors of this paper have disclosed potential or pertinent conflicts of interest, which may include receipt of payment, either direct or indirect, institutional support, or association with an entity in the biomedical field which may be perceived to have potential conflict of interest with this work. For full disclosure statements refer to <https://doi.org/10.1016/j.artd.2018.02.008>.

\* Corresponding author. 8940 North Kendall Dr, Suite 601E., Miami, FL 33176, USA. Tel.: +1 954 728 0762.

E-mail address: [juansu@baptisthealth.net](mailto:juansu@baptisthealth.net)



**Figure 1.** Anteroposterior view of the pelvis (a) and hip (b) in addition to a lateral hip view (c) demonstrating medial migration of the cup due to a large uncontained acetabular medial wall defect.

posterolateral aspect of the acetabulum are used to add additional support. Dexler et al. [7] evaluated the outcomes of the technique proposed by Rogers et al. [6] and found good results.

Concerning the reconstruction of the medial acetabular wall, most techniques described in the literature incorporate cage and/or ring constructs. Therefore, the purpose of the current investigation is to describe a novel technique for the placement of an antibiotic spacer in the setting of a large uncontained medial wall acetabular defect secondary to acetabular osteolysis due to PJI. The proposed technique involves the use of screws and cement.

### Surgical technique

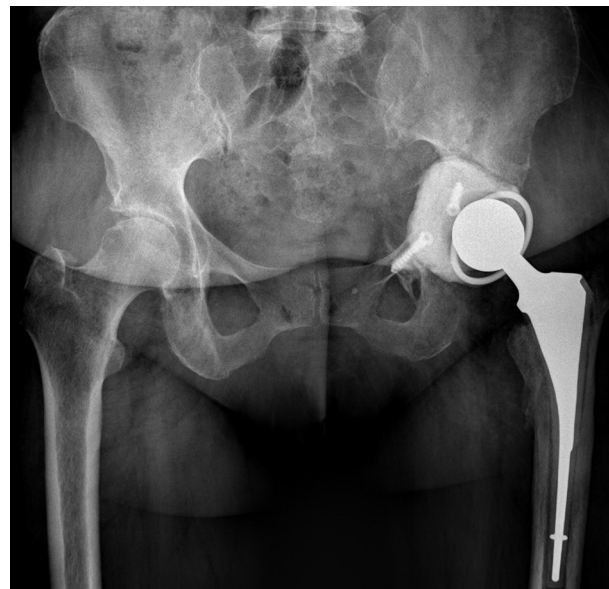After hip joint aspiration, a diagnosis of PJI was made on a 60-year-old female patient who previously underwent a left total hip arthroplasty. Based on prior records and the patient's recollection, the index procedure was performed approximately 4 years before the patient presented to our institution. The patient had 2 prior revisions and initially underwent a head and polyethylene liner exchange shortly after the index operation due to a suspected deep periprosthetic infection followed by an acetabular component revision due to persistent hip pain and suspected aseptic loosening. Intraoperative cultures grew *Corynebacterium striatum*, and as a result, the patient was subsequently treated with suppressive antibiotics. The cup migrated medial to the Kohler line due to a large uncontained medial wall defect (Fig. 1a-c). Prior radiographs were unavailable for review. According to the Paprosky classification for acetabular bone loss, the wall deficiency was classified as a type 2C defect [8]. The hip aspiration demonstrated growth of *Corynebacterium striatum* on 2 separate samples. The patient met major Musculoskeletal Infection Society criteria for the diagnosis of PJI [9].

A 2-stage revision arthroplasty procedure was planned to most effectively eradicate this chronic PJI. An articulating antibiotic spacer was chosen due to the benefits of reduced hospitalization, enhanced function, and ease of the second-stage reimplantation [1]. The following technique describes the creation of a cement spacer construct in the setting of significant acetabular medial wall destruction.

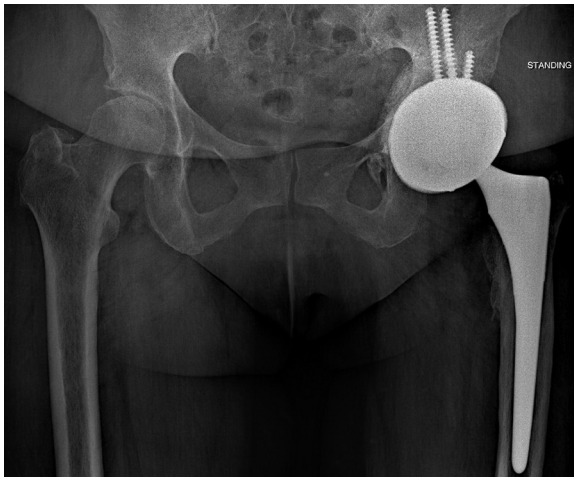
The patient was placed in the lateral decubitus position, and a standard posterior approach was used to access the hip. The short external rotators and piriformis tendon were released off the femur, and a bone hook was used to dislocate the prosthetic joint. A bone tamp and mallet were used to remove the femoral head, and an extractor device was used to backslap the femoral stem. The polyethylene liner, acetabular screws, and cup were removed after thorough soft-tissue debridement. Adequate circumferential bone stock was noted; however, there was a large uncontained medial acetabular wall deficiency consistent with a Paprosky type 2C

defect [8]. The acetabulum was reamed with a 61 size reamer. Owing to concerns of medial migration of the hip spacer, a decision was made to place 2 acetabular screws to serve as rebar to prevent medial displacement of the antibiotic spacer. One screw was placed in the pubis and the other in the ileum. Three batches of antibiotic cement with 3 g of vancomycin and 2.4 g of tobramycin were then prepared. One batch was formed into a disk and placed around the acetabular screws to recreate a medial wall. A poor cementing technique was purposely utilized to form the disk. This technique limited the interdigitation of the cement to facilitate the removal of the construct at the time of the second-stage revision. A second batch of cement was then used to cement the acetabular liner into the recreated medial wall. The third batch of cement was placed into a spacer mold to form the femoral stem. The appropriate size femoral head was placed after trialing to optimize stability. Intraoperative assessment demonstrated adequate stability of the prosthetic joint. Figure 2 shows the radiographic appearance of the spacer construct and the femoral stem.

The patient was treated with 6 weeks of intravenous antibiotics, followed by a 2-week antibiotic holiday at which time repeat serology and hip aspiration was performed. Cultures from the aspiration were negative with 5.3% neutrophils and a white blood



**Figure 2.** Anteroposterior view of the pelvis showing the spacer construct and the femoral stem.



**Figure 3.** A jumbo cup with dual mobility liner and a press-fit femoral stem were used to achieve optimal stability and fixation.

cell count of  $6.17 \times 10^9/L$ . C-reactive protein was 4.2 mg/L while the erythrocyte sedimentation rate was 13 mm/h. These results were consistent with clearance of infection.

Reimplantation was performed at 10 weeks. A standard posterior approach was again utilized. The prosthetic joint was dislocated, and the antibiotic femoral stem was easily removed. The cemented acetabular component was carefully removed with an osteotome and a mallet so as to prevent medial displacement of the cement disk. The limited interdigitation of the cement disk allowed the spacer to be removed with relative ease. A Paprosky type 2C acetabular bone defect was seen again [8]. A periosteal membrane was noted to have formed medial to the cement spacer and acted as a barrier to the pelvic cavity. Bone graft was then placed in the defect, and the acetabulum was sequentially reamed to a 67 mm size.

A 68-mm size acetabular cup was placed, and fixation was augmented with 3 cancellous screws. The femoral stem was placed after standard reaming and broaching, and the appropriate size head was placed to optimize stability. A jumbo cup with dual-mobility liner and a press-fit femoral stem were used for optimal stability and fixation. **Figure 3** shows the postoperative radiographic appearance of the arthroplasty reimplantation utilizing the jumbo cup.

## Discussion

The aforementioned technique illustrates a method to manage a large medial uncontained acetabular wall defect during the first stage of a 2-stage reconstruction for PJI. Using this method, we were able to recreate a medial wall to prevent protrusion and create a stable articulating antibiotic cement spacer. The construct, comprising antibiotic cement, was similar to a reconstruction cage in function as it helped restore the hip center of rotation and prevent protrusion. By forming the cement disk to recreate the medial wall purposely utilizing a poor cementing technique, the interdigitation of the cement was limited which allowed it to be easily removed during the second-stage revision. During the second stage, the surgeon should be prepared to face difficulty removing the spacer in the event that the cementing technique was better than expected. Instrumentation such as a high speed burr and explant osteotomes may be helpful in the setting of a difficult spacer removal. This procedure provided the patient with a stable

construct while being successfully treated with intravenous antibiotics for 6 weeks. Furthermore, the bone stock was adequately preserved which allowed the reimplantation of a jumbo acetabular cup during the second-stage revision.

The efficacy of 2-stage revision arthroplasty for PJI is well documented in the literature [1,7,10–12]. The advantages of an antibiotic spacer are that soft-tissue management, patient function, limb length, and antibiotic delivery are all optimized to allow for infection eradication and reimplantation. Acetabular and femoral bone loss makes the creation of antibiotic spacers significantly more difficult.

Multiple techniques have been described to create antibiotic cement spacers in the setting of acetabular bone loss. Most of the published techniques discuss supplementation and support of superior and posterolateral acetabular bone loss. The techniques described to address medial wall destruction and pelvic discontinuity involve the use of reconstruction cages and/or roof rings to their constructs [4]. To the best of our knowledge, the technique discussed in the current report represents a novel treatment for medial acetabular wall deficiency.

The combination of screws and cement is a well-documented technique frequently used in the setting of superior and posterolateral acetabular bone loss [4–6]. The role of the screws in the current technique was to support the cement construct and to prevent medial migration. The acetabular liner was then cemented into the cement construct.

## Summary

The described technique represents a unique method to create an antibiotic spacer in the setting of 2-stage revision for PJI with isolated medial acetabular wall destruction. This technique prevented the migration of the spacer through the medial wall, helped eradicate infection, and allowed for a successful total hip arthroplasty reimplantation.

## References

- [1] Jacobs C, Christensen C, Berend M. Static and mobile antibiotic impregnated cement spacers for the management of prosthetic joint infection. *J Am Acad Orthop Surg* 2009;17(6):356.
- [2] Cui Q, Mihalko WM, Shields JS, Ries M, Saleh KJ. Antibiotic-impregnated cement spacers for the treatment of infection associated with total hip or knee arthroplasty. *J Bone Joint Surg Am* 2007;89(4):871.
- [3] Leung F, Richards CJ, Garbuz DS, Masri BA, Duncan CP. Two-stage total hip arthroplasty: how often does it control methicillin-resistant infection? *Clin Orthop Relat Res* 2011;469(4):1009.
- [4] Ben-Lulu O, Farno A, Gross AE, Backstein DJ, Kosashvili Y, Safir OA. A modified cement spacer technique for infected total hip arthroplasties with significant bone loss. *J Arthroplasty* 2012;27(4):613.
- [5] Baker RP, Duncan CP. Acyclic acetabular roof reconstruction for severe segmental bone loss in 2-stage surgery for infected hip arthroplasty. *J Arthroplasty* 2011;26(8):1567.
- [6] Rogers BA, Kuchinad R, Garbedian S, Backstein D, Gross AE, Safir OA. Cement augmentation of the acetabulum for revision total hip arthroplasty for infection. *J Arthroplasty* 2015;30(2):270.
- [7] Dexler M, Kuzlyk PR, Koo K, et al. The use of a supra-acetabular antibiotic-loaded cement shelf to improve hip stability in first-stage infected total hip arthroplasty. *J Arthroplasty* 2016;31(11):2574.
- [8] Telleria JJ, Gee AO. Classifications in brief: Paprosky classification of acetabular bone loss. *Clin Orthop Relat Res* 2013;471(11):3725.
- [9] Parvizi J, Gehrke T. Definition of periprosthetic joint infection. *J Arthroplasty* 2014;29(7):1331.
- [10] Dairaku K, Takagi M, Kawaji H, Sasaki K, Ishii M, Ogino T. Antibiotics-impregnated cement spacers in the first step of two-stage revision for infected totally replaced hip joints: report of ten trial cases. *J Orthop Sci* 2009;14(6):704.
- [11] Pignatti G, Nitta S, Rani N, et al. Two stage hip revision in periprosthetic infection: results of 41 cases. *Open Orthop J* 2010;11(4):193.
- [12] Diwanji SR, Kong IK, Park YH, Cho SG, Song EK, Yoon TR. Two-stage reconstruction of infected hip joints. *J Arthroplasty* 2008;23(5):656.