

LigaSure for the Creation of Bloodless Breast Pockets in Patients Undergoing Transaxillary Breast Augmentation

Min Kuk Kim, MD
Sangdal Lee, MD

Background: The energy-based LigaSure device is widely utilized to facilitate dissection and hemostasis during various open and endoscopic procedures. Previous studies have demonstrated that this device can reduce intraoperative blood loss in various surgical settings. The present study aimed to report our experience with LigaSure and the advantages of using this device during transaxillary submuscular pocket dissection over those of a monopolar electrocautery dissector in patients undergoing breast augmentation.

Methods: A total of 156 patients who underwent transaxillary breast augmentation between November 2019 and May 2020 were retrospectively reviewed. Submuscular pocket dissection using LigaSure was performed in 92 patients and a conventional technique using a monopolar electrocautery dissector was performed in the remaining 64 patients. A bloodless breast pocket was defined as a clear operating field with little or no blood staining at any stage of the procedure. All endoscopic procedures were recorded to determine whether bloodless pockets had been established. The amount of postoperative drainage at 1 day after surgery was also assessed to compare between the LigaSure and conventional groups.

Results: Bloodless breast pockets were successfully established in 83 patients (90.2%) in the LigaSure group and in 38 patients (59.4%) in the conventional group ($P < 0.001$). Postoperative drainage amount at 1 day following surgery was significantly lower in the LigaSure group than in the conventional group ($P < 0.001$).

Conclusion: Our findings indicate that the LigaSure system is a safe and effective alternative in breast augmentation requiring transaxillary submuscular dissection. (*Plast Reconstr Surg Glob Open* 2020;8:e3295; doi: [10.1097/GOX.0000000000003295](https://doi.org/10.1097/GOX.0000000000003295); Published online 22 December 2020.)

INTRODUCTION

Previously, the transaxillary approach for breast augmentation, which was first introduced as a blind technique, was limited by an inability to predict the extent of dissection and by the risk of complications such as hematoma or trauma. However, endoscopic procedures have become more common since the introduction of refined techniques for endoscopic pocket dissection,¹⁻⁴ and transaxillary breast augmentation is now widely performed under direct endoscopic guidance.

Precise control of the dissection can be achieved using monopolar electrosurgical instruments, and the elimination of blunt dissection remarkably reduces tissue trauma. Electrocautery-based dissectors and bipolar forceps have been used to ensure meticulous dissection and hemostasis in patients undergoing endoscopic breast pocket dissection. However, the learning curve for using these techniques and instruments during endoscopic transaxillary procedures is steeper than that for the inframammary approach, which has made some surgeons to rely on blunt maneuvers.

Effective and efficient hemostasis ensures consistent technical control and improves patient safety intraoperatively. Previous studies have reported that the LigaSure device (Covidien Medtronic, Minneapolis, Minn.), which uses heat and pressure to coagulate and seal blood vessels,

From the MD Clinic, Breast Augmentation & Reconstruction Centre, Seoul, Republic of Korea.

Received for publication August 28, 2020; accepted October 14, 2020.

Copyright © 2020 The Authors. Published by Wolters Kluwer Health, Inc. on behalf of The American Society of Plastic Surgeons. This is an open-access article distributed under the terms of the [Creative Commons Attribution-Non Commercial-No Derivatives License 4.0 \(CCBY-NC-ND\)](https://creativecommons.org/licenses/by-nc-nd/4.0/), where it is permissible to download and share the work provided it is properly cited. The work cannot be changed in any way or used commercially without permission from the journal.

DOI: [10.1097/GOX.0000000000003295](https://doi.org/10.1097/GOX.0000000000003295)

Disclosure: The authors have no financial interest to declare in relation to the content of this article.

Related Digital Media are available in the full-text version of the article on www.PRSGlobalOpen.com.

is effective in reducing intraoperative blood loss in various surgical settings. Although LigaSure is widely utilized in various open and endoscopic procedures,⁵⁻⁷ relatively few studies have examined the use of this technology during breast augmentation. The LigaSure technology may represent an efficient alternative to blunt maneuvers or sharp monopolar dissectors, allowing for the creation of a bloodless breast pocket and achieving aesthetically satisfying results. Thus, the present study aimed to report our experience with LigaSure for transaxillary submuscular pocket dissection during aesthetic breast surgery, with an emphasis on technical refinements and a comparison between the LigaSure and a conventional technique.

METHODS

Patients

A total of 156 patients who underwent transaxillary breast augmentation between November 2019 and May 2020 were retrospectively reviewed. Submuscular pocket dissection using LigaSure was performed in 92 patients (the LigaSure group) and a conventional technique that uses a monopolar electrocautery dissector was performed in the remaining 64 patients (the conventional group). Patients with severe breast ptosis or a previous history of foreign body injection in the breast were excluded. All patients underwent primary augmentation, and the implants were placed in the submuscular pocket via a type I dual-plane dissection (the pectoralis muscle remains attached to the overlying breast tissue), followed by the insertion of bilateral negative pressure-closed suction drains to remove fluid or blood in the breast pockets. Postoperative drainage amount on the postoperative day 1 was assessed to compare between the LigaSure and conventional groups. The drain was removed when the amount of drainage was <100 mL. A bloodless breast pocket was defined as a clear operating field with little or no blood staining during any stage of the procedure. All endoscopic procedures were recorded to determine whether bloodless pockets had been established. The occurrence of early postoperative complications such as hematoma or seroma at 1 month after surgery was also reviewed. Informed consent was waived due to the retrospective study design. The current study was approved by the Public Institutional Bioethics Committee designated by the Ministry of Health and Welfare of Korea (2020-1912-001) and all procedures described herein were performed in accordance with the 1964 Declaration of Helsinki.

Surgical Instruments

The LigaSure system consists of a handset and an energy platform. The handset is a feedback-controlled bipolar unit with jaws that grasp, melt, and fuse vascular collagen and elastin. A controlled high-power current is delivered at low voltage to melt the collagen and elastin in the tissue, leading to permanent fusion of the vascular layers and obliteration of the lumen.⁶ Any surgeon familiar with endoscopic surgery can easily use LigaSure. LigaSure handsets are available in various shaft lengths and tip

shapes for different forms of operation. For example, LigaSure with a long shaft and blunt tip is used in laparoscopic surgery, while LigaSure with a short shaft and sharp tip can be conveniently used in open thyroidectomy.

In the present study, we used the LigaSure Atlas laparoscopic tissue-fusion instrument (LS1037), which features a 10-mm blunt tip and a 37-cm shaft for submuscular breast pocket dissection. A separate endoscope and retractor were used to free both hands for dissection, with the endoscope in one hand and the LigaSure handset in the other hand. Once an adequate amount of tissue had been grasped and secured, the LigaSure system provided a combination of pressure and energy to ensure vessel fusion. The sealing and cutting procedures were performed during the same grasp. The button on the handset was pressed until a characteristic 2-tone sound from the platform confirmed the complete coagulation of the tissue. The button was then released, the coagulated tissue was cut, and the jaw of the device was released by squeezing the handle until it unlocked.

Surgery Using LigaSure

All procedures were performed under general anesthesia with the patient in the supine position and the arms abducted to 90 degree. The axillary skin was incised along the skin crease and a shallow subcutaneous dissection was performed to identify the lateral border of the pectoralis major muscle. The pectoral fascia was carefully spread using a pair of dissecting scissors to avoid injury to the muscle, thus ensuring precise access to the correct layer between the pectoralis major and minor muscles. A double-ended retractor was inserted immediately beneath the pectoralis major muscle to confirm a clean areolar tissue plane, and the submuscular plane was established using a gentle finger sweep. Gentle blunt finger movement was used to provide an early space for endoscope entrance. Except for the enlargement created for the entrance pocket, no other blunt dissection technique was performed in any area of the pocket. After the endoscopic retractor had been positioned by an assistant, the LigaSure device was inserted with the endoscope through an axillary incision.

Pocket dissection using LigaSure was directed toward the lower medial pocket until the main body of the pectoralis major muscle had been clearly identified. The endoscopic retractor was advanced gradually, and loose areolar connective tissue and accessory slips of the pectoralis major muscle were sealed and divided sequentially using the LigaSure device, until the lower medial pocket was reached. (See Video 1 [online], which displays transaxillary breast pocket dissection using LigaSure.)

The deep side of the pectoralis major muscle was sealed and divided such that this layer remained intact on the ribs and the pectoralis minor. Areas medial and lateral to the body of the endoscopic retractor were also sealed and divided to enlarge the pocket. During progressive dissection to the lower medial pocket, large perforators (usually located 2–3 cm above the inframammary fold and at the junction between the inframammary fold and the sternum) were identified and sealed safely with LigaSure

(Fig. 1A-1B). Significant vessels were safely controlled using LigaSure in a prospective fashion, and the lower portion of the breast pocket was successfully enlarged, allowing surgeons to avoid avulsion of major perforators with retractor movement and ensuring the creation of bloodless pockets.

When the main body of the pectoralis major muscle was clearly visible with minimal or no blood staining, the dissection was advanced to the medial pocket. Thick fibrous and membranous septums in the upper medial pocket could be grasped and sealed safely by gently advancing the LigaSure device. Pinnate medial pectoralis origins and fibrous bundles containing minor vessels that could cause irregularities along the sternal border were sealed and divided using LigaSure. Medial pocket dissection continued until the main body of the sternal origin was reached, while frequently checking the extent of dissection relative to the skin markings.

The endoscope was then moved to the lateral pocket. With the endoscopic retractor repositioned to the lateral pocket, the main body of the pectoralis major muscle along the inframammary fold remained intact. To laterally expose the most lateral costal origins of the pectoralis major muscle, the endoscopic retractor was lifted, and the tip of the retractor was twisted at the same time. The muscle origins were placed under a slight tension via a proper retraction, and the pectoralis origins were sealed and divided from the lateral to medial direction using LigaSure (Fig. 1C, D). Muscle release using LigaSure was more convenient from the lateral to medial direction

because it was easy to hang the exposed lateral edge of the pectoralis major muscle. The internal anatomy was carefully corresponded with external reference markings to avoid excessive lowering. The use of the LigaSure system allowed the surgeon to simply push the blunt tip of the device internally to visualize corresponding points on the skin before sealing the muscle. Muscle release was continued medially until the junction between the sternal and costal origins of the pectoralis major muscle was reached. (See Video 2 [online], which displays muscle release from the lateral to medial direction using LigaSure.)

The pectoralis major muscle was easily released using LigaSure, and additional hemostasis for intramuscular bleeding was rarely necessary. Following the muscle release, the LigaSure device was replaced with a sharp endoscopic dissector, and all areas of the pocket were reinspected for proper tissue release. Breast pockets were then irrigated with an antibiotic solution, and the breast implants were positioned. The incision was closed using 4-0 absorbable sutures for subcutaneous tissue and 5-0 nylon for the skin.

Conventional Surgery

The initial procedures in patients who underwent conventional surgery are identical to those in the LigaSure group. However, when the submuscular plane had been approached, a blunt curved tissue dissector was used to enlarge the submuscular pocket in a blind fashion to facilitate a fast and convenient dissection. The range of blunt dissection was limited to the central area of the pocket to

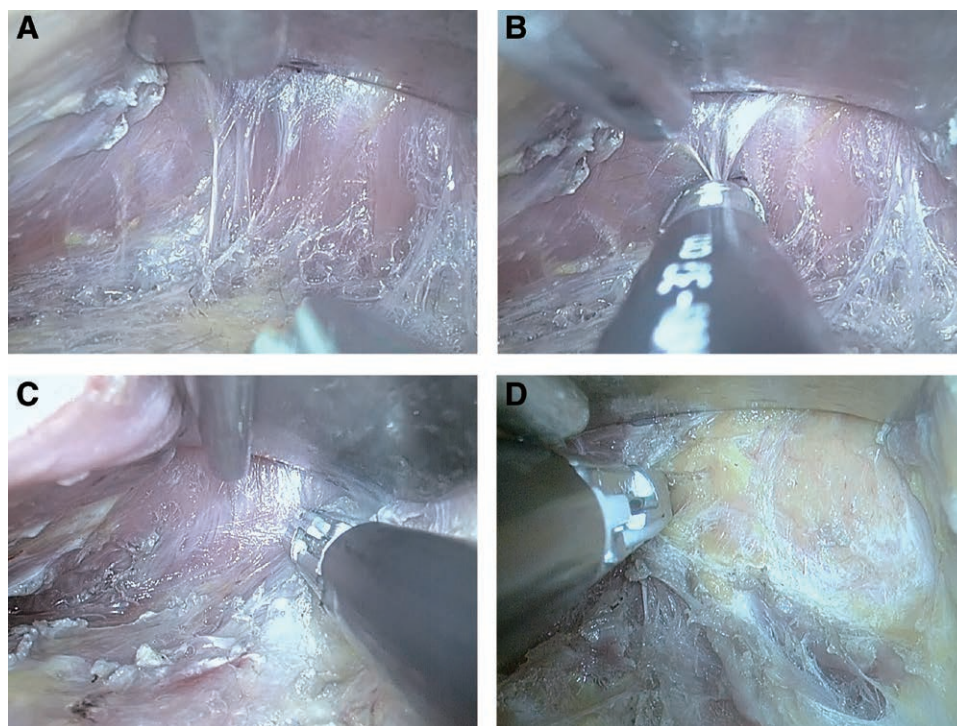


Fig. 1. Endoscopic view of the right breast pocket. The lower medial perforator was identified (A) and sealed safely using LigaSure (B). The exposed lateral edge of the pectoralis major muscle was grasped and sealed using LigaSure in the lower lateral pocket (C). Muscle release was continued medially till the junction between the sternal and costal origins of the pectoralis major muscle were reached (D).

create an optical cavity for the endoscope. After the centrally limited blunt dissection, a monopolar electrocautery dissector was inserted with the endoscope and further tissue release was proceeded with careful control of bleeding in a prospective fashion. Muscle release along the inframammary fold was conducted from the medial to lateral direction, and the remainder of the procedure was similar to that of the LigaSure group.

Statistical Analysis

All statistical analyses were performed using R version 3.2.5 (Vienna, Austria; <http://www.R-project.org>). To compare the median of continuous variables, Wilcoxon two-sample test was used. The Chi-square test was used to compare categorical variables. Differences were considered significant at $P < 0.05$.

RESULTS

Bloodless breast pockets were successfully established in 83 patients (90.2%) in the LigaSure group and in 38 patients (59.4%) in the conventional group ($P < 0.001$) (Table 1). Postoperative drainage amount at 1 day after surgery was significantly lower in the LigaSure group than in the conventional group ($P < 0.001$).

Based on the authors' experience, the operating time was similar between both groups or slightly longer in the LigaSure group; however, no significant intraoperative bleeding occurred in any of the patients and better prospective hemostasis was achieved using LigaSure. Three patients in the conventional group experienced unilateral hematoma within 2 days after surgery and the hematoma was evacuated.

DISCUSSION

To the best of our knowledge, the present study is the first to specifically outline the advantages of LigaSure during breast augmentation. Our findings indicate that LigaSure is efficient when the procedure is aimed to achieve bloodless breast pocket dissection. Advancing the LigaSure carefully can secure the endoscopic field-of-view, ensure reliable prospective hemostasis and dissection, and maintain a bloodless breast pocket. In contrast to the hemostasis provided by conventional endoscopic instruments, seals created by LigaSure are solid because they are intrinsic to the vessel wall structure, and the vessel-sealing

process is operator-independent, whereas the hemostasis achieved via conventional endoscopic dissectors depends on the skill level of the operator.⁶

Endoscopic transaxillary surgery requires a clear operating field with little or no blood staining at any stage of the procedure, necessitating the development of adequate hemostatic skills and instruments for optimal results. Adequate hemostasis is essential to reduce hemorrhage-related morbidity during surgical procedures, as the presence of a hematoma is one of the most critical risk factors for capsular contracture in patients undergoing breast augmentation. Surgeons are encouraged to employ prospective hemostatic techniques to control all vessels before dividing them because this helps avoid blood staining, which can obscure the visualization of anatomical details and increase postoperative inflammation and discomfort. Tebbetts described prospective hemostasis as a process of avoiding bleeding by controlling vessels before bleeding occurs and manipulating instruments to prevent inadvertent disruption of small vessels.⁴ Tebbetts further emphasized that such prospective management requires the knowledge of anatomical details and a determination to avoid intraoperative bleeding at all cost. In addition, an endoscopic instrument is required for accurate dissection and optimal prospective hemostasis. Given the technical skill required to perform transaxillary breast surgery, it remains necessary to investigate alternative surgical techniques that can make the procedures easier to perform and encourage more surgeons to utilize them.

Due to advancements in surgical techniques and the development of novel devices, hemostatic techniques have almost been completely replaced by energy-based devices such as LigaSure.⁸ Energy-based vessel-sealing devices have been developed to facilitate dissection and hemostasis during both open and laparoscopic procedures.⁹ Previous research has demonstrated the efficacy of LigaSure in reducing blood loss compared with other coagulating devices.¹⁰ Consistent with these findings, the present results suggest that LigaSure also facilitates prospective hemostasis in transaxillary breast augmentation by enabling the surgeon to perform dissection with efficient coagulation and division and providing a bloodless pocket dissection. All structures encountered when dissecting a submuscular pocket, including vessels, fibrotic bundles, and muscle fibers, were safely sealed and divided using LigaSure without the need for additional surgical

Table 1. Comparison of the Clinical Characteristics and Postoperative Results of the LigaSure Group versus the Conventional Group

	LigaSure Group (n = 92)		Conventional Group (n = 64)		P
Age (y)	32.5	[20–54]	34.5	[19–51]	0.12
BMI (kg/m ²)	18.8	[15.4–22.9]	19.1	[16.0–25.3]	0.41
Implant size (cm ³)	312.5	[230–400]	322.5	[225–400]	0.08
Outcomes of surgery					
Amount of drainage (mL)	70.0	[30–150]	100.0	[60–180]	<0.001
Bloodless pocket establishment	83	(90.2)	38	(59.4)	<0.001
Hematoma	0	(0.0)	3	(4.7)	—
Seroma	0	(0.0)	0	(0.0)	—
Infection	0	(0.0)	0	(0.0)	—

Values are given as median (range) or n (%).

motions for hemostasis. The LigaSure provided excellent results of prospective hemostasis in a safe and efficient manner, which may help simplify the process of submuscular pocket dissection.

Our results also indicated that the LigaSure system demonstrated a satisfactory performance in achieving muscle release during the dual-plane dissection. Transecting the muscle fibers after effective vessel sealing prevented an excessive use of cauterization to control intramuscular bleeding. In addition, the device ensured an optimal depth of dissection, which may increase the surgeon's comfort in performing the procedure, especially in patients with thin soft-tissue envelopes. A previous study reported that the LigaSure device reduced thermal spread compared with that observed during monopolar cautery.⁸ Without an adequate level of skill, the use of sharp dissectors can cause thermal damage to the skin flap or flap perforation, especially in thin patients with insufficient soft-tissue coverage. By preventing electric current from spreading beyond the jaws of the device, LigaSure reduces damage to surrounding tissues, which improves operative safety and ensures optimal tissue release while minimizing tissue trauma. Therefore, LigaSure can also prevent muscle twitching during submuscular dissection. Although conventional dissection via a monopolar electrocautery is fast and convenient, this technique is associated with a risk of electrical injury to the adjacent tissue. Electrocautery may induce intramuscular injury in cases of inadvertent contact with muscle, which can lead to hemorrhage.

Hemorrhage may occur under various circumstances in patients undergoing submuscular breast augmentation. Extensive use of blunt dissection techniques or inadvertent retractor movement can cause significant bleeding from large perforators, substantial tissue trauma, and injury to the rib periosteum and perichondrium, contributing to postoperative pain and related complications.² Excess blood remaining in the adjacent tissues increases inflammation, which can prolong recovery and increase the risk of capsular contracture. Consequently, all blunt dissection should be eliminated, and more effective surgical techniques for perforator control are essential for maintaining bloodless breast pockets during submuscular augmentation. In the present study, large perforators in the lower pocket and medial perforators along the sternum were clearly identified and safely controlled using LigaSure.

Despite our positive findings, there are some limitations to the LigaSure system. First, the cost of surgery was much higher in the LigaSure group than in the conventional group because of the cost of the LigaSure device. Although there were significant surgical advantages of LigaSure, the advantages may have been overcome by the cost of the device. Second, adhesion may occur between the jaws of the LigaSure handset and the grasped tissue with repeated surgical use. This tissue adhesion can increase resistance to energy transmission, thereby prolonging sealing time and increasing the risk of subsequent coagulation necrosis on either side of the jaws.⁹ The manufacturer recommends that the handsets be used in a single operative procedure alone before being discarded.

Further, the handsets are not designed to facilitate effective cleaning, and any method of gas sterilization would be relatively less effective in the presence of biological debris.¹¹ In addition, the blunt tip of the LigaSure handset may limit the ability to perform a meticulous pocket dissection. For a refined dissection of the lower and lateral pocket borders, additional instruments such as sharp endoscopic dissectors remain necessary.

There were several limitations to the current study. First, this study was performed at a single center in a retrospective manner, and it included a relatively small number of cases. Second, the surgical procedures in the conventional group included a blunt maneuver regardless of its extent, which contributed to the relatively lower achievement rate of bloodless breast pockets due to adjacent tissue trauma. This may have affected the comparison between the LigaSure and the monopolar device. Moreover, the assessment of the achievement of a bloodless pocket had a subjective aspect. However, after blunt dissection for the optical cavity, meticulous hemostasis was also conducted in a prospective fashion using a monopolar electrocautery dissector in the conventional group. Considering that the postoperative drainage amount was significantly reduced in the LigaSure group, the comparison may be meaningful in that it revealed an advantage of LigaSure.

CONCLUSIONS

Our findings indicate that the LigaSure system is a safe and effective alternative for breast augmentation requiring transaxillary submuscular dissection. Although the present results support the notion that the technique is relatively easy to learn and perform, further studies are required to provide quantitative evidence regarding the potential advantages of LigaSure over conventional techniques.

Min Kuk Kim, MD

MD Clinic, Breast Augmentation and Reconstruction Center
85-18 Chungdam-dong
Gangnam-gu, Seoul 06014
Republic of Korea
E-mail: kmk1208@hanmail.net

ACKNOWLEDGMENTS

The authors would like to thank Sook Young Woo, who is affiliated to Statistics and Data Center of Samsung Medical Center, for statistical analysis and Editage, for English language editing.

REFERENCES

1. Sim HB. Transaxillary endoscopic breast augmentation. *Arch Plast Surg*. 2014;41:458–465.
2. Tebbetts JB. Axillary endoscopic breast augmentation: processes derived from a 28-year experience to optimize outcomes. *Plast Reconstr Surg*. 2006;118:53S–80S.
3. Strock LL. Transaxillary endoscopic silicone gel breast augmentation. *Aesthet Surg J*. 2010;30:745–755.
4. Tebbetts JB. Achieving a predictable 24-hour return to normal activities after breast augmentation: part I. Refining practices by using motion and time study principles. *Plast Reconstr Surg*. 2002;109:273–290.

5. Grieco M, Apa D, Spoletini D, et al. Major vessel sealing in laparoscopic surgery for colorectal cancer: a single-center experience with 759 patients. *World J Surg Oncol*. 2018;16:101.
6. Hefni MA, Bhaumik J, El-Toukhy T, et al. Safety and efficacy of using the LigaSure vessel sealing system for securing the pedicles in vaginal hysterectomy: randomised controlled trial. *BJOG*. 2005;112:329–333.
7. Taşkın S, Şükür YE, Altın D, et al. Bipolar energy instruments in laparoscopic uterine cancer surgery: a randomized study. *J Laparoendosc Adv Surg Tech A*. 2018;28:645–649.
8. Janssen PF, Brölmann HA, Huirne JA. Effectiveness of electrothermal bipolar vessel-sealing devices versus other electrothermal and ultrasonic devices for abdominal surgical hemostasis: a systematic review. *Surg Endosc*. 2012;26:2892–2901.
9. Okhunov Z, Yoon R, Lusch A, et al. Evaluation and comparison of contemporary energy-based surgical vessel sealing devices. *J Endourol*. 2018;32:329–337.
10. Hubner M, Demartines N, Muller S, et al. Prospective randomized study of monopolar scissors, bipolar vessel sealer and ultrasonic shears in laparoscopic colorectal surgery. *Br J Surg*. 2008;95:1098–1104.
11. Kuvaldina A, Hayes G, Sumner J, et al. Influence of multiple reuse and resterilization cycles on the performance of a bipolar vessel sealing device (LigaSure) intended for single use. *Vet Surg*. 2018;47:951–957.