

Available online at [www.sciencedirect.com](http://www.sciencedirect.com)

ScienceDirect

journal homepage: [www.elsevier.com/locate/radcr](http://www.elsevier.com/locate/radcr)

## Case report

# Duodenal stenosis after transcatheter arterial embolization for rupture of an inferior pancreaticoduodenal aneurysm <sup>☆</sup>

Keita Nakayama, MD, Masashi Shimohira, MD\*, Keiichi Nagai, MD, Kengo Ohta, MD, Tatsuya Kawai, MD, Yusuke Sawada, MD, Shunsuke Shibata, MD, Yuta Shibamoto, MD

Department of Radiology, Nagoya City University Graduate School of Medical Sciences, Nagoya 467-8601, Japan

## ARTICLE INFO

## Article history:

Received 21 June 2021

Revised 27 June 2021

Accepted 29 June 2021

## Keywords:

Inferior pancreaticoduodenal artery

Aneurysm

Embolization

Complication

Duodenal stenosis

## ABSTRACT

A 64-year-old man presented with epigastric pain and underwent contrast-enhanced computed tomography. Ruptured aneurysm of the inferior pancreaticoduodenal artery was diagnosed. TAE was successfully accomplished using coils, but vomiting appeared 9 days later. Duodenal stenosis was diagnosed from contrast-enhanced computed tomography and upper gastrointestinal endoscopy and was attributed to edematous changes in the duodenum. Conservative management led to successful recovery and discharge.

© 2021 The Authors. Published by Elsevier Inc. on behalf of University of Washington.

This is an open access article under the CC BY-NC-ND license

(<http://creativecommons.org/licenses/by-nc-nd/4.0/>)

## Introduction

Pancreaticoduodenal aneurysms are rare, accounting for only 2% of abdominal visceral aneurysms [1]. Most visceral artery aneurysms are asymptomatic lesions that are incidentally diagnosed during examinations ordered for unrelated abdominal pathologies. Aneurysms of the pancreaticoduodenal arcade are unique, because many are symptomatic or ruptured at presentation [2]. If found, therapeutic intervention is necessary because visceral aneurysms can prove fatal if rupture occurs [3]. Transcatheter arterial embolization (TAE) is less invasive than open surgery and has become the first-choice

treatment [4], but reports have described duodenal stenosis after TAE for ruptured pancreaticoduodenal aneurysm [5–8]. We present herein a case of duodenal stenosis 9 days after TAE for ruptured aneurysm of the inferior pancreaticoduodenal artery (IPDA), and perform a systematic review of previous reports of duodenal stenosis after TAE.

## Case report

A 64-year-old man was referred to our hospital with complaints of epigastric pain and transient loss of

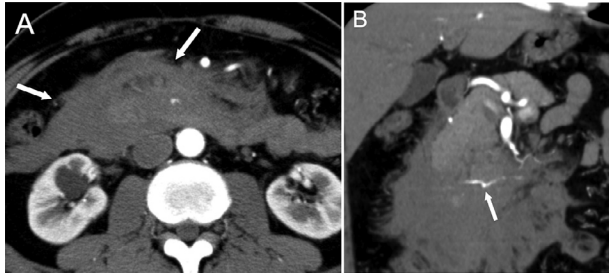
<sup>☆</sup> Competing interests: We do not have any conflicts of interest and financial disclosures.

\* Corresponding author.

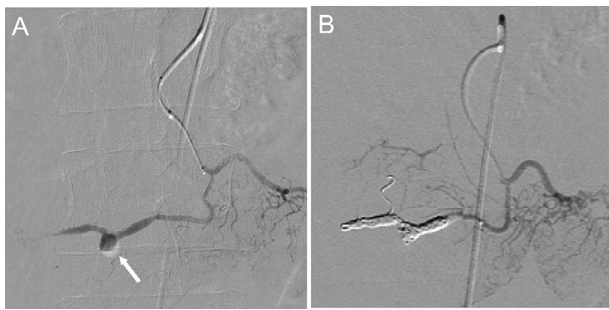
E-mail address: [mshimohira@gmail.com](mailto:mshimohira@gmail.com) (M. Shimohira).

<https://doi.org/10.1016/j.radcr.2021.06.090>

1930-0433/© 2021 The Authors. Published by Elsevier Inc. on behalf of University of Washington. This is an open access article under the CC BY-NC-ND license (<http://creativecommons.org/licenses/by-nc-nd/4.0/>)



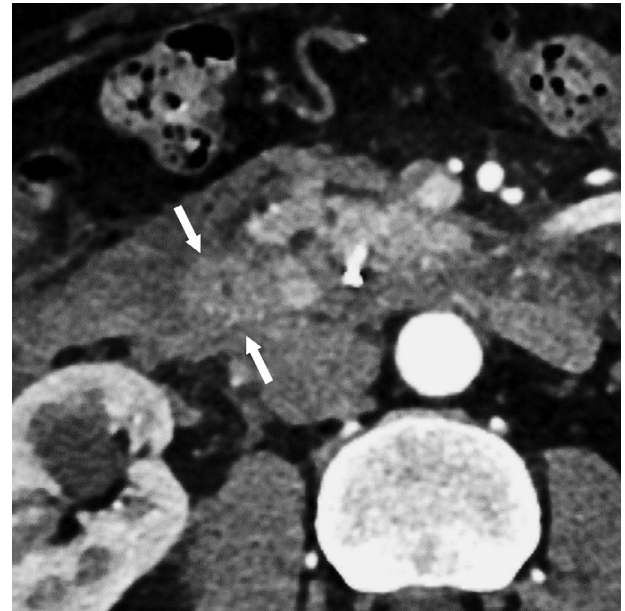
**Fig. 1 – (A) Contrast-enhanced CT shows retroperitoneal hematoma (arrows). (B) Coronal contrast-enhanced CT shows a 4-mm aneurysm on the inferior pancreaticoduodenal artery (IPDA) (arrow). Rupture of an aneurysm of the IPDA is therefore diagnosed.**



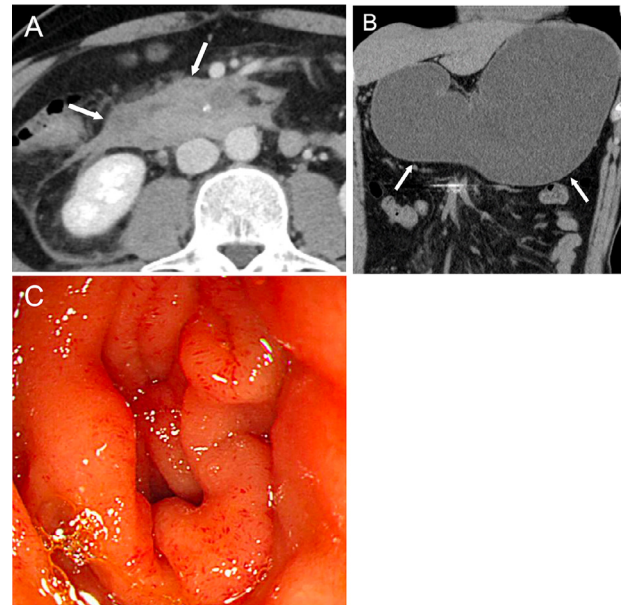
**Fig. 2 – (A) Angiography shows an aneurysm of the IPDA (arrow). Transcatheter arterial embolization (TAE) is then performed using coils. (B) After TAE, the aneurysm is no longer apparent.**

consciousness. Contrast-enhanced computed tomography (CT) showed retroperitoneal hematoma and a 4-mm aneurysm of the IPDA (Fig. 1A, B). Ruptured IPDA aneurysm was diagnosed. Emergent TAE using coils was therefore attempted. A 4-Fr sheath (Medikit, Tokyo, Japan) was introduced to the right femoral artery. A 4-Fr catheter (Terumo, Tokyo, Japan) was placed in the superior mesenteric artery and microcatheters (2.7-Fr Sniper 2 high-flow; Terumo, and 1.6-Fr MARVEL-S; Tokai Medical, Kasugai, Japan) were coaxially advanced to the IPDA. Angiography of the IPDA depicted the aneurysm (Fig. 2A), then TAE using coils (Target; Stryker, Fremont, CA and C-Stopper 14; Piolax, Kanagawa, Japan) was successfully accomplished (Fig. 2B).

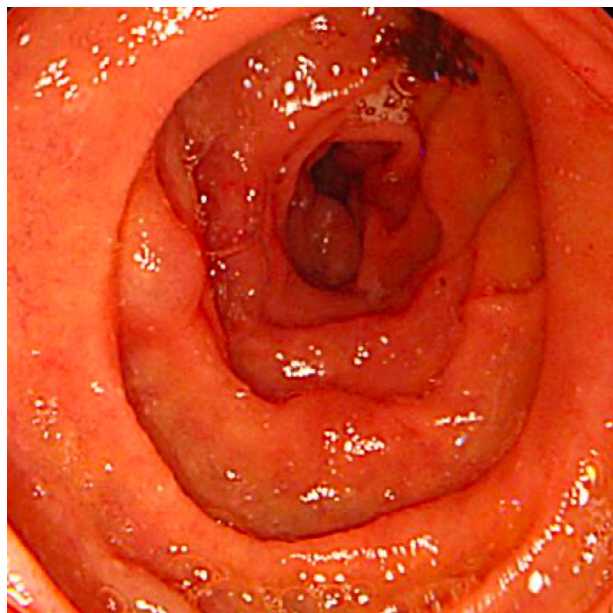
Contrast-enhanced CT performed the day after TAE showed that contrast effect was maintained in the intestinal tract, so no intestinal ischemia was found (Fig. 3). However, vomiting appeared 9 days after TAE. CT showed that the hematoma had shrunk compared to before TAE (Fig. 4A), but also revealed expansion of the stomach (Fig. 4B). Stenosis of the duodenum was therefore suspected. Upper gastrointestinal endoscopy was performed and revealed edematous changes in the duodenum (Fig. 4C). Conservative management was initiated and symptoms resolved spontaneously. Improvement of duodenal stenosis was confirmed by upper gastrointestinal endoscopy 41 days after TAE (Fig. 5), and the



**Fig. 3 – Contrast-enhanced CT the day after TAE shows enhancement of the duodenum (arrows), and no intestinal ischemia is considered present.**



**Fig. 4 – (A) The patient complained of vomiting 9 days after TAE. CT shows that the hematoma has shrunk compared to the size before TAE (arrows). (B) However, coronal-section CT reveals expansion of the stomach (arrows) and stenosis of the duodenum is suspected. (C) Upper gastrointestinal endoscopy shows duodenal stenosis due to edematous changes. Conservative management is initiated.**



**Fig. 5 – Upper gastrointestinal endoscopy 41 days after TAE reveals improvement of duodenal stenosis. The patient continued to do well without any complication and was discharged from the hospital.**

patient showed an uneventful course without complications and was discharged from the hospital.

## Discussion

We encountered a case of duodenal stenosis 9 days after TAE for ruptured aneurysm of the IPDA. TAE has been shown to be effective in controlling bleeding from rupture of visceral aneurysms [2], but may cause complications including access site complications, dissection of the target vessel, and organ infarction. TAE in the upper gastrointestinal tract is generally considered safe because of the rich collateral supply to the stomach and duodenum [9]. The risk of significant ischemia after TAE increased with the use of deeply penetrating embolic agents such as cyanoacrylate or very small particles [10]. Post-TAE ischemia usually presents as duodenal stenosis in the chronic phase. The risk of duodenal stenosis has been shown to be high in patients treated with TAE using cyanoacrylate [11]. On the other hand, coils have been successfully used in the pancreaticoduodenal arteries [12–14]. The advantage of coils is that they can be delivered in a precise fashion and carry a low risk of infarction because of the preservation of the distal arteries. Ischemic stenosis of the duodenum after TAE using coils is thus unlikely.

To clarify the cause of duodenal stenosis, we reviewed articles extracted from a search for "duodenal stenosis" and "TAE" in the PubMed search engine [5–7]. The present review focused on the period between the onset of duodenal stenosis and TAE, defining the acute phase as within 1 week, the subacute phase as more than 1 week but within 1 month, and the chronic phase as beyond 1 month. In total, 12 cases, including our own, were reviewed. In all 12 cases, TAE was successfully

**Table 1 – Literature review of duodenal stenosis after TAE for ruptured pancreaticoduodenal aneurysm.**

Authors	Age (years)	Sex	Symptom	Location of aneurysm	Embolic material	Re-bleeding	Aneurysm size (mm)	Interval between onset of duodenal stenosis and TAE (days)	Treatment	Outcome
Goda et al.[5]	60	M	Abdominal pain	AIPDA	Coils	No	83	10	Subacute	Conservative
Takeuchi et al.[6]	80	F	Vomiting	AIPDA	Coils	No	8	24	Subacute	Conservative
Yamamoto et al.[7]	72	M	Epigastric pain	PIPDA	Coils	No	75	8	Subacute	Conservative
	55	F	Back pain	PIPDA	Coils	No	30	10	Subacute	Conservative
	49	F	Abdominal pain	IPDA	Coils	No	Unknown	9	Subacute	Conservative
	53	M	Abdominal pain	IPDA	Coils	No	Unknown	2	Acute	Conservative
	71	M	Abdominal pain	IPDA	Coils	No	6	10	Subacute	Conservative
	86	M	Epigastric pain	IPDA	Coils	No	Unknown	6	Acute	Conservative
	47	M	Abdominal pain	PIPDA	Coils	No	Unknown	11	Subacute	Conservative
	66	M	Abdominal pain	AIPDA	Coils	No	Unknown	10	Subacute	Conservative
	70	M	Abdominal pain	AIPDA	Coils	No	10	14	Subacute	Conservative
Our case	64	M	Vomiting	IPDA	Coils	No	4	9	Subacute	Conservative

AIPDA, anterior inferior pancreaticoduodenal artery; PIPDA, posterior inferior pancreaticoduodenal artery; IPDA, inferior pancreaticoduodenal artery.



performed using coils without re-bleeding. The median period between the onset of duodenal stenosis and TAE was 10 days. The duodenal stenosis occurred in the subacute stage in 83% (10/12) (Table 1). In all cases, conservative management was performed and duodenal stenosis was improved.

When the duodenal stenosis occurred in the acute phase, the stenosis was presumed to have been caused by hematoma. However, in the present case, the hematoma had shrunk. An alternative cause of the stenosis would be ischemic changes in the duodenum due to TAE, but the risk of duodenal ischemia was low due to the presence of blood flow from the collateral vessels [2]. In the present case, ischemic changes were not confirmed by CT or upper gastrointestinal endoscopy. Edematous changes in the duodenum due to stagnant portal venous return were thus considered the cause of duodenal stenosis [8]. These changes can occur in the subacute phase, because time is required for the hematoma to harden and cause edema. Familiarity with this rare situation in subacute phase after TAE appears important for recognizing rupture of pancreaticoduodenal artery aneurysms and instituting appropriate treatment. Surgery is unnecessary and conservative management should be the first-line treatment for such cases.

In conclusion, duodenal stenosis can occur after rupture of pancreaticoduodenal artery aneurysms due to edematous changes in the duodenum. Conservative management appears appropriate.

## REFERENCES

- [1] Stanley JC, Wakefield TW, Graham LM, Whitehouse WM Jr, Zelenock GB, Lindenauer SM. Clinical importance and management of splanchnic artery aneurysms. *J Vasc Surg* 1986;3(5):836–40.
- [2] Corey MR, Ergul EA, Cambria RP, Patel VI, Lancaster RT, Kwolek CJ, et al. The presentation and management of aneurysms of the pancreaticoduodenal arcade. *J Vasc Surg* 2016;64(6):1734–40.
- [3] Branchi V, Meyer C, Verrel F, Kania A, Bölke E, Semaan A, et al. Visceral artery aneurysms: evolving interdisciplinary management and future role of the abdominal surgeon. *Eur J Med Res* 2019;24(1):17.
- [4] Cano-Valderrama O, Gallego-Béuter JJ, Giner M. Endovascular therapy as a treatment for ruptured pancreaticoduodenal artery aneurysms. *Minim Invasive Ther Allied Technol*, 20; 2011. p. 296–300.
- [5] Goda K, Yo S, Katsumata R, Fukushima S, Osawa M, Muraio T, et al. Duodenal obstruction after transarterial embolization for rupture of a pancreaticoduodenal artery aneurysm due to segmental arterial mediolysis: a case report. *Nihon Shokakibyō Gakkai Zasshi* 2019;116(6):515–22.
- [6] Takeuchi N, Emori K, Nomura Y. A case report of duodenal obstruction due to retroperitoneal bleeding after the rupture of a lower pancreaticoduodenal artery aneurysm. *Nihon Shokakibyō Gakkai Zasshi* 2017;114(4):667–75.
- [7] Yamamoto K, Kumada T, Kiriyama S, Tanikawa M, Hisanaga Y, Toyoda H, et al. Ruptured aneurysm of a posterior inferior pancreaticoduodenal artery associated with duodenal stenosis after transcatheter arterial embolization. *Nihon Shokakibyō Gakkai Zasshi* 2011;108(6):978–86.
- [8] Ishiyama M, Suzuki S, Makidono A, Morita Y, Saida Y. A concept of duodenal compartment syndrome: report of three cases of duodenal stenosis due to periduodenal hematoma. *Jpn J Radiol* 2013;31(1):56–60.
- [9] Foltz G, Khaddash T. Embolization of nonvariceal upper gastrointestinal hemorrhage complicated by bowel ischemia. *Semin Intervent Radiol* 2019;36(2):76–83.
- [10] Loffroy R, Favelier S, Pottecher P, Estivalet L, Genson PY, Gehin S, et al. Transcatheter arterial embolization for acute nonvariceal upper gastrointestinal bleeding: Indications, techniques and outcomes. *Diagn Interv Imaging* 2015;96(7-8):731–44.
- [11] Lang EK. Transcatheter embolization in management of hemorrhage from duodenal ulcer: long-term results and complications. *Radiology* 1992;182(3):703–7.
- [12] Defreyne L, Vanlangenhove P, Decruyenaere J, Van Maele G, De Vos M, Troisi R, et al. Outcome of acute nonvariceal gastrointestinal haemorrhage after nontherapeutic arteriography compared with embolization. *Eur Radiol* 2003;13(12):2604–14.
- [13] Loffroy R, Guiu B, Mezzetta L, Minello A, Michiels C, Jouve JL, et al. Short- and long-term results of transcatheter embolization for massive arterial hemorrhage from gastroduodenal ulcers not controlled by endoscopic hemostasis. *Can J Gastroenterol* 2009;23(2):115–20.
- [14] Loffroy R, Guiu B, Cercueil JP, Lepage C, Latournerie M, Hillon P, et al. Refractory bleeding from gastroduodenal ulcers: arterial embolization in high-operative-risk patients. *J Clin Gastroenterol* 2008;42(4):361–7.