

# Extracorporeal Worm Extraction of *Diphyllobothrium nihonkaiense* with Amidotrizoic Acid in a Child

Hye Kyung Shin<sup>1</sup>, Joo-Hyung Roh<sup>1</sup>, Jae-Won Oh<sup>1</sup>, Jae-Sook Ryu<sup>2</sup>, Youn-Kyoung Goo<sup>3</sup>, Dong-Il Chung<sup>3</sup>,  
Yong Joo Kim<sup>1,\*</sup>

<sup>1</sup>Department of Pediatrics, <sup>2</sup>Department of Environmental Biology and Medical Parasitology, Hanyang University College of Medicine, Seoul 133-792, Korea; <sup>3</sup>Department of Parasitology and Tropical Medicine, Kyungpook National University School of Medicine, Daegu 700-422, Korea

**Abstract:** Infection cases of diphyllbothriid tapeworms are not much in the below teen-age group. We report a case of *Diphyllobothrium nihonkaiense* infection in a 13-year-old boy. He presented with severe fatigue, occasional abdominal pain at night time. He also had several episodes of tapeworm segment discharge in his stools. By his past history, he had frequently eaten raw fish including salmon and trout with his families. Numerous eggs of diphyllbothriid tapeworm were detected in the fecal examination. We introduced amidotrizoic acid as a cathartic agent through nasogastrointestinal tube and let nearly whole length (4.75 m) of *D. nihonkaiense* be excreted through his anus. After a single dose of praziquantel, the child's stool showed no further eggs, and his symptoms disappeared. The evacuated worm was identified as *D. nihonkaiense* by mitochondrial *cox1* gene analysis. Here we report a successful extracorporeal worm extraction from an infection case of *D. nihonkaiense* by the injection of amidotrizoic acid.

**Key words:** *Diphyllobothrium nihonkaiense*, amidotrizoic acid, child, *cox1* gene

## INTRODUCTION

*Diphyllobothrium* spp. are known to distribute in Northwest Europe and East Asia. Eighteen species in *Diphyllobothrium* have been reported to cause diphyllbothriasis in humans [1]. Human can contract with these tapeworms by eating the intermediate or paratenic (transport) fish hosts infected with plerocercoid larvae. Among them, *Diphyllobothrium latum* and *Diphyllobothrium nihonkaiense* have been mainly reported in Korea [2-5]. These 2 species appear to have similar morphologic features, and so it is difficult that clinicians distinguish these 2 worms with naked eyes. Nucleotide sequencing analysis studies can identify these species [3,6].

In 1919, *Diphyllobothrium* infection was first reported in 2 stool egg-positive residents in Jinju, Korea [7]. After then, a small number of sporadic cases have been reported. Recently, a study for molecular identification of *D. nihonkaiense* collected from 62 patients was reported in 2009 [3]. Among them, only

2 cases of children's *D. nihonkaiense* infection have been reported in Korea and the age of those were 6 and 13 years old each [3].

In Japan, 2 cases of *D. nihonkaiense* ejected by administration of intraduodenal amidotrizoic acid were reported in adults [8,9]. However, there has been no pediatric case report concerning extracorporeal whole body evacuation of this worm with this medicine in Korea. In that sense, our case report had focused on the extracorporeal extraction of the worm and measuring the total length of the tapeworm. We report here a case of evacuation of the whole length of *D. nihonkaiense* by using amidotrizoic acid.

## CASE RECORD

A 13-year-old boy, who resides in Gapyeong, Gyeonggi-do was referred from another hospital. He and his family often ate various raw fish including salmon and trout, approximately 5 times a month. Three months before this visit, he noticed a whitish long flat parasite of about 70 cm in length out from the anus while he felt something inside a stool. Then, he took 1 tablet of albendazole. However, after a month, exactly 2 months before visiting our hospital, he experienced the same event of fecal discharge of segments of the parasite and he took

•Received 18 July 2014, revised 4 September 2014, accepted 10 September 2014.

\*Corresponding author (kjoo@hanyang.ac.kr)

© 2014, Korean Society for Parasitology and Tropical Medicine

This is an Open Access article distributed under the terms of the Creative Commons Attribution Non-Commercial License (<http://creativecommons.org/licenses/by-nc/3.0>) which permits unrestricted non-commercial use, distribution, and reproduction in any medium, provided the original work is properly cited.

mebendazole. Though, the worm came out again, the parents took him to the Department of Pediatrics, Hanyang University Hospital. He presented with fatigue and experienced several episodes of cramping abdominal pain at night. There was no weight gain during the 3 months' ill period. He looked thin, with height of 161 cm (50-75 percentile) and weight of 46.4 kg (25-50 percentile). In addition, he had no travel history to a foreign country within the past several months.

The eggs obtained from the feces were oval and brown in color. The eggs were approximately  $59.7 \pm 2.3 \times 43.8 \pm 1.4 \mu\text{m}$  in size (Fig. 1). When we confirmed eggs of *Diphyllobothrium* sp. from his stool, we recommended to perform a cathartic evacuation of the total length of *Diphyllobothrium* sp.

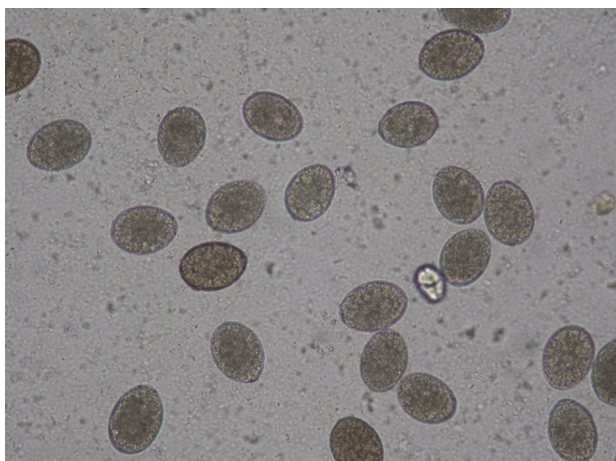
After his hospitalizations, blood chemistry, serology, and stool examination were done. CBC was in normal range without signs of anemia and eosinophilia (WBC 4,500/ $\mu\text{l}$ , total eosinophil count 150/ $\text{mm}^3$ , Hb 15.2 g/dl, Hct 42.9%, MCV 81.9 fL, MCH 29.0 pg, and platelet 181,000/ $\mu\text{l}$ ). Other blood biochemistry and serology tests were all within normal ranges (vitamin B<sub>12</sub> 459 pg/ml, folate 8.9 ng/ml, iron 99  $\mu\text{g}/\text{dl}$ , and ferritin 68 ng/ml). We also performed gastrofiberscopy and colonoscopy to confirm *Diphyllobothrium* sp. There was no visible strobila of *Diphyllobothrium* sp. in the proximal duodenum and colon and no other specific findings.

On the next day, small bowel series using amidotrizoic acid (Gastrografin) was performed for diagnostic and therapeutic purposes. A nasogastroduodenal tube was inserted and its tip was advanced into the second portion of the duodenum by using a guidewire. Amidotrizoic acid of 200 ml was injected into the duodenum via a nasogastroduodenal tube to confirm and


eject this tapeworm. However, there was no visible definite tapeworm in the small bowel series. After administration of an additional 200 ml of amidotrizoic acid, this examination ended up. Several hours later he felt something came out from the anus. Then, we observed *Diphyllobothrium* sp. coming out from his anus and carefully pulled it through the anus. However, he complained of abdominal pain during this work. It was impossible to remove it completely and the tapeworm cut its body by itself. The total length of the worm which was excreted extracorporeally (at initial trial) was about 475 cm. Fig. 2 shows the strobila of *Diphyllobothrium* sp. which was pushed out from the body by amidotrizoic acid injected into the duodenum. Unfortunately, however, the scolex was not detected. Another small segment of about 1 m long was also passed out in a few hours. The patient was administered with a single dose of praziquantel (15 mg/kg, 600 mg) in the evening.

On the next day, he was discharged without any complications. After 2 weeks, he visited our out-patient clinic, and the follow-up stool was free of any eggs. There was no evidence of recurrent *Diphyllobothrium* sp. infection after the treatment, and he looked healthy.

Later, the specimen was sent to the Department of Parasitology and Tropical Medicine, Kyungpook National University School of Medicine for genetic analysis of species as described by Song et al. [8]. Total genomic DNA was extracted from the specimen and analyzed by nucleotide sequences of mitochondrial cytochrome *c* oxidase subunit 1 (*cox1*) gene. The *cox1* sequences (858 bp) of the worm showed similarity of 99.8% (856/858 bp) with *D. nihonkaiense* (GenBank no. AB781787).



**Fig. 1.** Eggs of *D. nihonkaiense* (L,  $59.7 \pm 2.29 \mu\text{m}$ ; W,  $43.8 \pm 1.37 \mu\text{m}$ ) seen in the feces of the patient ( $\times 400$ ).



**Fig. 2.** A whole strobila without scolex of *D. nihonkaiense* extracorporeally discharged by the injection of amidotrizoic acid. The total length of the specimens was about 475 cm.

## DISCUSSION

*D. nihonkaiense* is known to distribute in Northwestern Europe and East Asia. Consumption of raw or uncooked fish leads to human infections with *D. nihonkaiense*. The intermediate hosts of *D. nihonkaiense* are salmonids such as *Oncorhynchus masou* (cherry salmon), *O. gorbuscha* (pink salmon), and *O. keta* (chum salmon) available in the Pacific Ocean [10]. On the other hand, the intermediate hosts of *D. latum* are freshwater fish, such as the pike, perch, burbot, trout, and salmon [11].

The first worm proven as *D. nihonkaiense* was described in 1986 in Japan [12], this worm had been mostly known as *D. latum* in Korea [2]. In 2009, a study for genetic identification was performed against the “so-called” *D. latum* worms that were reported in Korea, and a total of 62 cases were first proved to be caused by *D. nihonkaiense* [3]. Recently, additional 3 cases of *D. nihonkaiense* have been reported [4,5]. However, children’s cases of *D. nihonkaiense* are quite few in Korea. Four cases of children’s *D. latum* and 2 cases of children’s *D. nihonkaiense* have been reported in Korea [2,3].

In the past study, most of the cases of *D. nihonkaiense* infection had a few symptoms. The major symptoms of *D. nihonkaiense* infections were gastrointestinal problems such as abdominal pain, abdominal distension, vomiting and diarrhea. In other cases, the symptoms such as anemia, fatigue, anorexia, fever, and myalgia were observed. In our case, the patient complained the colicky abdominal pain and fatigue.

In recent several cases, colonoscopy and capsule endoscopy were useful diagnostic methods for detecting *D. latum* and *D. nihonkaiense* infections [13-16]. However, in our case, *D. nihonkaiense* infection could not be detected by colonoscopy.

It remains unclear how amidotrizoic acid evacuates the tapeworm and how the scolex of tapeworm is detached from the intestinal surface though [17]. It is most possible that the poly-sorbate 80 in amidotrizoic acid is a hypertonic solution and has the effects of laxatives; therefore, it may play a role in evacuation of this tapeworm [18]. When amidotrizoic acid rapidly passed through the small intestine, the tapeworm was expelled from the small intestine to the colon by intestinal peristalsis. The advantage of this method is complete evacuation of tapeworms. Several studies in Japan reported that the body and scolex of tapeworms were ejected by administration of amidotrizoic acid [8,9]. In domestic cases, there was no report concerning the evacuation of whole tapeworm by using a cathartic agent like amidotrizoic acid through the duodenal tube. In that

sense, the method for evacuation of tapeworm by using amidotrizoic acid in our case is thought to be one of the available methods to remove the whole body of *D. nihonkaiense*.

The medications such as atabrine, niclosamide, and bithionol have been used for treatment of *Diphyllobothrium* infections since 1971 [2]. However, from 1987 till present days, praziquantel has been used as the drug of choice. Tapeworms are completely removed by praziquantel and treatment failure cases were not reported [2]. In our case, the treatment with a single dose of praziquantel was effective as proved by the disappearance of eggs in the feces in 2 months. Through the nasoduodenal injection of amidotrizoic acid and extracorporeal acquisition of the worm, it could be possible for us to confirm what the worm was and how long it was, and to document the worm by a gene study.

## ACKNOWLEDGMENTS

The authors thank Ms. Soo-Young Lee for her assistance in sample preparation.

## CONFLICT OF INTEREST

We have no conflict of interest related to this work.

## REFERENCES

1. Yamane Y, Shiwaku K. *Diphyllobothrium nihonkaiense* and other marine-origin cestodes. *Prog Med Parasitol Jpn* 2003; 8: 245-254.
2. Lee EB, Song JH, Park NS, Kang BK, Lee HS, Han YJ, Kim HJ, Shin EH, Chai JY. A case of *Diphyllobothrium latum* infection with a brief review of diphyllobothriasis in the Republic of Korea. *Korean J Parasitol* 2007; 45: 219-223.
3. Jeon HK, Kim KH, Huh S, Chai JY, Min DY, Rim HJ, Eom KS. Morphologic and genetic identification of *Diphyllobothrium nihonkaiense* in Korea. *Korean J Parasitol* 2009; 47: 369-375.
4. Park SH, Eom KS, Park MS, Kwon OK, Kim HS, Yoon JH. A case of *Diphyllobothrium nihonkaiense* infection as confirmed by mitochondrial COX1 gene sequence analysis. *Korean J Parasitol* 2013; 51: 471-473.
5. Song SM, Yang HW, Jung MK, Heo J, Cho CM, Goo YK, Hong Y, Chung DI. Two human cases of *Diphyllobothrium nihonkaiense* infection in Korea. *Korean J Parasitol* 2014; 52: 197-199.
6. Wicht B, de Marval F, Peduzzi R. *Diphyllobothrium nihonkaiense* (Yamane et al., 1986) in Switzerland: first molecular evidence and case reports. *Parasitol Int* 2007; 56: 195-199.
7. Kojima R, Ko T. Researches on intestinal parasites of Koreans in

- South Keisho-Do. Especially on the distribution of liver flukes. *J Chosen Med Ass* 1919; 26: 42-86 (in Japanese).
8. Fujita A, Migita M, Ueda T, Fukunaga Y. A 2-year-old girl with *Diphyllobothrium nihonkaiense* infection treated with oral praziquantel and a laxative. *J Nippon Med Sch* 2008; 75: 225-227.
  9. Yoshida M, Hasegawa H, Takaoka H, Miyata A. A case of *Diphyllobothrium nihonkaiense* infection successfully treated by oral administration of Gastrografin. *Parasitol Int* 1999; 48: 151-155.
  10. Scholz T, Garcia HH, Kuchta R, Wicht B. Update on the human broad tapeworm (genus *Diphyllobothrium*), including clinical relevance. *Clin Microbiol Rev* 2009; 22: 146-160.
  11. Beaver PC, Jung RC, Cupp EW. *Clinical Parasitology*. 9th ed. Philadelphia, USA. Lea & Febiger. 1984, p 544-547.
  12. Yamane Y, Kamo H, Bylund G, Wikgren BJP. *Diphyllobothrium nihonkaiense* sp. nov. (Cestoda: Diphyllbothriidae): revised identification of Japanese broad tapeworm. *Shimane J Med Sci* 1986; 10: 29-48.
  13. Kim JH, Lee JH. Images in clinical medicine. *Diphyllobothrium latum* during colonoscopy. *N Engl J Med* 2010; 362: e40.
  14. Park SC, Keum B, Jeon YT, Chun HJ. *Diphyllobothrium latum* accidentally detected by colonoscopy. *Dig Liver Dis* 2011; 43: 664.
  15. Hirata M, Yamaguchi Y, Ikei Y, Koyama G, Matsui T, Ishida H, Takahashi S. A case of *Diphyllobothrium latum/nihonkaiense* infection identified by capsule endoscopy in small intestine. *Gastrointest Endosc* 2006; 64: 129-130.
  16. Soga K, Sakagami J, Handa O, Konishi H, Wakabayashi N, Yagi N, Yamada M, Kokura S, Naito Y, Yoshikawa T, Arizono N. Long fish tapeworm in the intestine: an in situ observation by capsule endoscopy. *Intern Med* 2011; 50: 325-327.
  17. Ko SB. Observation of deworming process in intestinal *Diphyllobothrium latum* parasitism by gastrografin injection into jejunum through double-balloon enteroscope. *Am J Gastroenterol* 2008; 103: 2149-2150.
  18. Kim TH, Kim HK, Lee YS, Choi DH, Kang SH, Jeong SJ, Park TI, Kim IT. A case of *Diphyllobothrium latum* infection in a patient with abdominal pain. *Korean J Gastroenterol* 2007; 50: 384-387.