

Aim of the study: Presents our experience in reconstruction of postsurgical defects with use of temporal muscle flap.

Material and methods: In the years 1996–2010 we treated 10 patients with malignant neoplasms of maxillo-facial region. Following tumor removal the fascia-muscle flaps of temporal muscle were used for reconstruction. Temporal muscle flaps were applied in 5 cases for reconstructing the defect of eye socket tissue after extensive resections and in the other 5 patients was used for reconstructing the defect of palate following maxillary resections.

Results: All the flaps of temporal muscle that were used for reconstructing eye sockets incorporated with no local reaction. In one case of flap applied into the oral cavity for tightly separate from nasal, partial necrosis of flap's edge and oro-nasal fistula occurred.

Conclusions: Fascia-muscular flap of temporal muscle is a simple, easy and effective method of tissue reconstruction in maxillo-facial region following extensive oncologic procedures.

Key words: facial reconstruction, muscles flaps, temporal muscle, SCC of the maxilla.

Temporal muscle flap in reconstruction of maxillo-facial tissues

Grzegorz Krzymański, Jarosław Dąbrowski, Jan Przybysz, Wojciech Domański, Barbara Biernacka, Tomasz Piętka

Department of Maxillofacial Surgery, Military Institute of Medicine, Warsaw, Poland

Oncology surgical procedures performed on the region of the head and neck require synchronous tissue reconstruction in order to close the defect of the removed tumor. A number of methods of tissue reconstruction can be found including local plasty, regional flaps and free grafts both simple and complex. The most common types of reconstruction are those evaluated as the most reliable methods which both have the weakest burdening effect on the patient and do not prolong surgical procedure.

As regards the most peduncled muscle grafts used for closing post-resection defects within the upper face, a special role is played by muscle-fascia flap of temporal muscle.

The first reports on using temporal muscle in reconstructive surgery come from the end from XIX century. In 1872 Vernuil used temporal muscle for isolation of incised surfaces of mandibular ramus in treatment of temporomandibular ankylosis (as cited in [1]). Another way of using temporal muscle was presented by Wagner in 1898 and involved application of muscle-bone flap that contained temporal muscle and attached part of parietal squamosa for reconstruction of tissue following removal of intracranial tumor (as cited in [1]). Lexer (1908) and Rosenthal (1916) used peduncled parts of temporal muscle for eyelid reinnervation in patients with facial paralysis (as cited in [1]). König (1926) used temporal muscle with upper part of mandibular ramus for reconstructing defects after removal of tumors from central face (as cited in [1]).

Campbell (1948) applied temporal muscle for closing defect after maxillary resection while Naquin (1956) and Webster (1957) used this method for reconstructing tissue defects following orbital exenteration (as cited in [1]).

In further years the flaps from temporal muscle became widely used in tissue reconstruction following extensive oncologic procedures around base of the skull, orbital, maxillary resection, zygomaxillary complex as well as for reconstructing defects of soft tissue in oral cavity and throat [1–12].

The authors of this work present own experiences in using temporal fascia-muscle flaps for reconstruction of maxillofacial tissue following extensive oncologic procedures.

Material and methods

In the years 1996–2010 we treated 10 patients with malignant neoplasms of maxillo-facial region. Following tumor removal the fascia-muscle flaps of temporal muscle were used for reconstruction. The group of patients included 8 men and 2 women. Mean age of the patients amounted to 64.7 and ranged between 31 and 83 years of age.

The diagnosis was made based on open biopsy. Evaluation of neoplastic process extent was determined in clinical studies, USG and radiology tests with critical role of CT. If necessary, the tests were completed by MRI and PET-CT.

Following both tumor removal and evaluation of procedure's radicalness based of intraoperative biopsy, the reconstructive part of the procedure was commenced.

Table 1.

Patient	Age	Sex	Diagnosis and staging	Type of operation	Main objective of use of the temporal muscle flap	Complications
1.	50	F	SCC of the left maxilla, infiltrating hard palate – T ₃ N ₀ M ₀	maxillary resection, leaving the lower wall of the orbit	tight separation of the oral cavity from the nasal cavity	small oro-nasal connection – healed after secondary suture
2.	81	M	SCC of the left medial corner of the eye, infiltrating eye socket, ethmoid bone, frontal sinus, nose bones and maxillary sinus – T ₄ N ₀ M ₀	eye socket exenteration with resection of adjacent parts of the maxilla, ethmoid, nose and frontal bone	reconstructing the defect of eye socket tissue and covering dura mater of anterior cranial fossa	–
3.	63	M	SCC of the right maxilla, infiltrating eye socket and lateral nose bone – T ₄ N ₀ M ₀	partial resection of the right maxilla and ethmoid sinus with orbital exenteration	reconstruction of the eye socket and covering dura mater of anterior cranial fossa	–
4.	77	M	SCC of the left medial corner of the eye, infiltrating eye socket, ethmoid bone and maxillary sinus – T ₄ N ₀ M ₀	eye socket exenteration with resection of adjacent parts of the maxilla, ethmoid and nose bone	reconstruction of the eye socket and covering facial skull bones	–
5.	70	M	SCC of the left maxilla, hard palate infiltrative – T ₄ N ₀ M ₀	bilateral partial resection of maxilla	tight separation of the oral cavity from the nasal cavity	small oro-nasal connection – healed after secondary suture
6.	35	M	SCC of the lacrimal sac infiltrating right maxilla and eye socket – T ₂ N ₀ M ₀	removing the tumor with enucleation of eyeball, leaving parts of the eyelids and conjunctival sac, partial resection of the maxilla	reconstruction of the eye socket; creation of the ground for eyelid allowing future use of eye prosthesis	–
7.	64	M	SCC developed on the basis of an inverted papilloma of the left maxilla – T ₄ N ₀ M ₀	resection of the maxilla, the ethmoid sinus and part of the orbital wall and zygomatic bone; reconstruction of orbital walls with titanium mesh	tight separation of the oral cavity from the nasal cavity; covering reconstructed orbital walls	partial necrosis of the skin-muscle flap and the oro-nasal fistula
8.	55	M	SCC of the left maxilla, infiltrating eye socket, ethmoid and zygomatic bone – T ₄ N ₀ M ₀	resection of the maxilla, the ethmoid sinus and the zygomatic bone with orbital exenteration	covering dura mater and reconstruction of tissue defect formed by removal of the tumor	–
9.	31	M	adenoid cystic carcinoma of left maxilla infiltrating palate and sphenoid bone – T ₄ N ₀ M ₀	resection of the maxilla, palatal bone, pterygoid process of the sphenoid bone, and part of the pterygoid muscle	tight separation of the oral cavity from the nasal cavity	–
10.	82	F	SCC infiltrating and destructive on the right maxilla, ethmoid sinus, zygomatic bone, nasal septum, nose bones, hard palate – T ₄ N ₀ M ₀	resection of right maxilla, zygomatic bone, part of the ethmoid sinus, the right bones of the nose and nasal septum, and part of the left corpus of maxilla	tight separation of the oral cavity from the nasal cavity	–

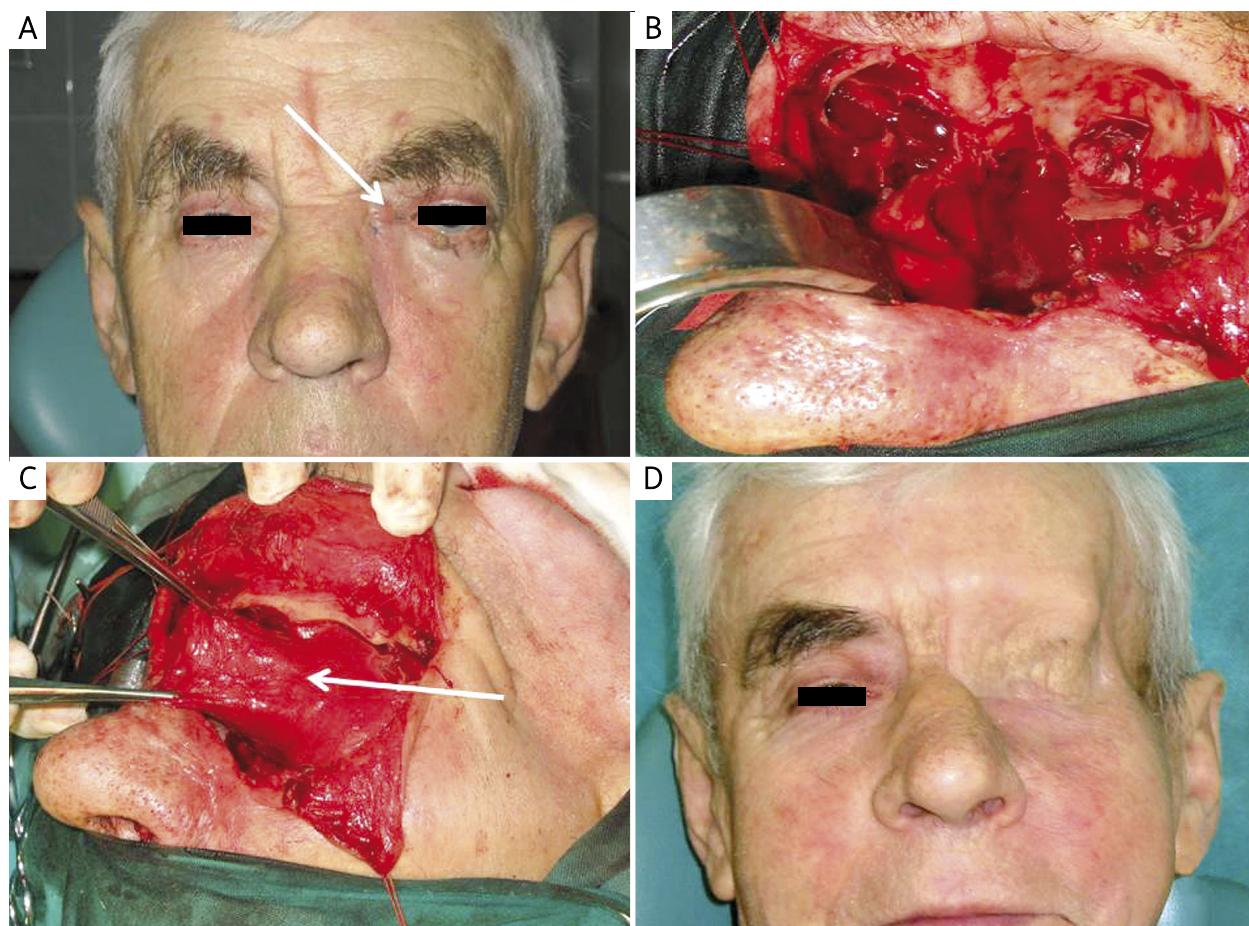


Fig. 1. Patient M.S. A – SCC the medial corner of eye; B – intraoperative view; C – reconstruction with temporal muscle flap; D – views of 3 years after surgery

In all the presented cases the tissue defect of the removed tumor was reconstructed with temporal muscle peduncled on mandibular attachment. The muscle was reached from semi-coronal cutaneous incision by cutting subsequently the skin, subcutaneous tissue, galea and temporal fascia. During preparation of the muscle-fascia flap special attention was paid to maintenance of its vascularization to maxillary artery through deep temporal rami. For this purpose, the temporal squamosa was removed from the muscle and periosteum by leading the raspatorily tightly attached to the bone. During placing temporal muscle in oral cavity, temporary incision of zygomatic arch that allowed for increasing flap's range occurred to be very useful. Another possibility of increasing flap's length is excision of the muscular process of the mandible [1].

The prepared flap was placed on the post-resection defect region and sutured to bone edges. Skin defects were closed with cutaneous-fascia flaps from neighboring regions. They were mainly flaps from the forehead or scalp.

Temporal muscle flaps were applied in 5 cases for reconstructing the defect of eye socket tissue after extensive resections within the upper face and for covering dura mater of anterior cranial fossa that was uncovered during the procedure. In the other 5 patients the dislocated temporal muscle was used for reconstructing the defect of hard palate fol-

lowing maxillary resections in order to tightly separate oral cavity from nasal cavity.

Detailed data of the patients including the diagnosis, type of surgical procedure, reconstruction method applied and incorporation process are presented in Table 1.

Following completion of surgical treatment all the patients underwent supplementary radiotherapy in Warsaw Oncology Center.

Results

All the flaps of temporal muscle that were used for reconstructing eye sockets and covering dura mater of anterior cranial fossa uncovered during the procedure incorporated with no local reaction. No intracranial complications were observed. Skin wounds healed by primary intention.

Most of the flaps applied into the oral cavity for hard palate reconstruction also incorporated with no complications. On the 7th–10th day following the procedure oral feeding was commenced. The surface of the muscle introduced into the oral cavity was first covered by fibrin, then in further days showed granulomatous response while after 4–6 weeks was covered with epithelium. In this time fibrosis of the muscle that restored the palate was observed as well as formation of a hard support beneficial for prosthetic restoration.

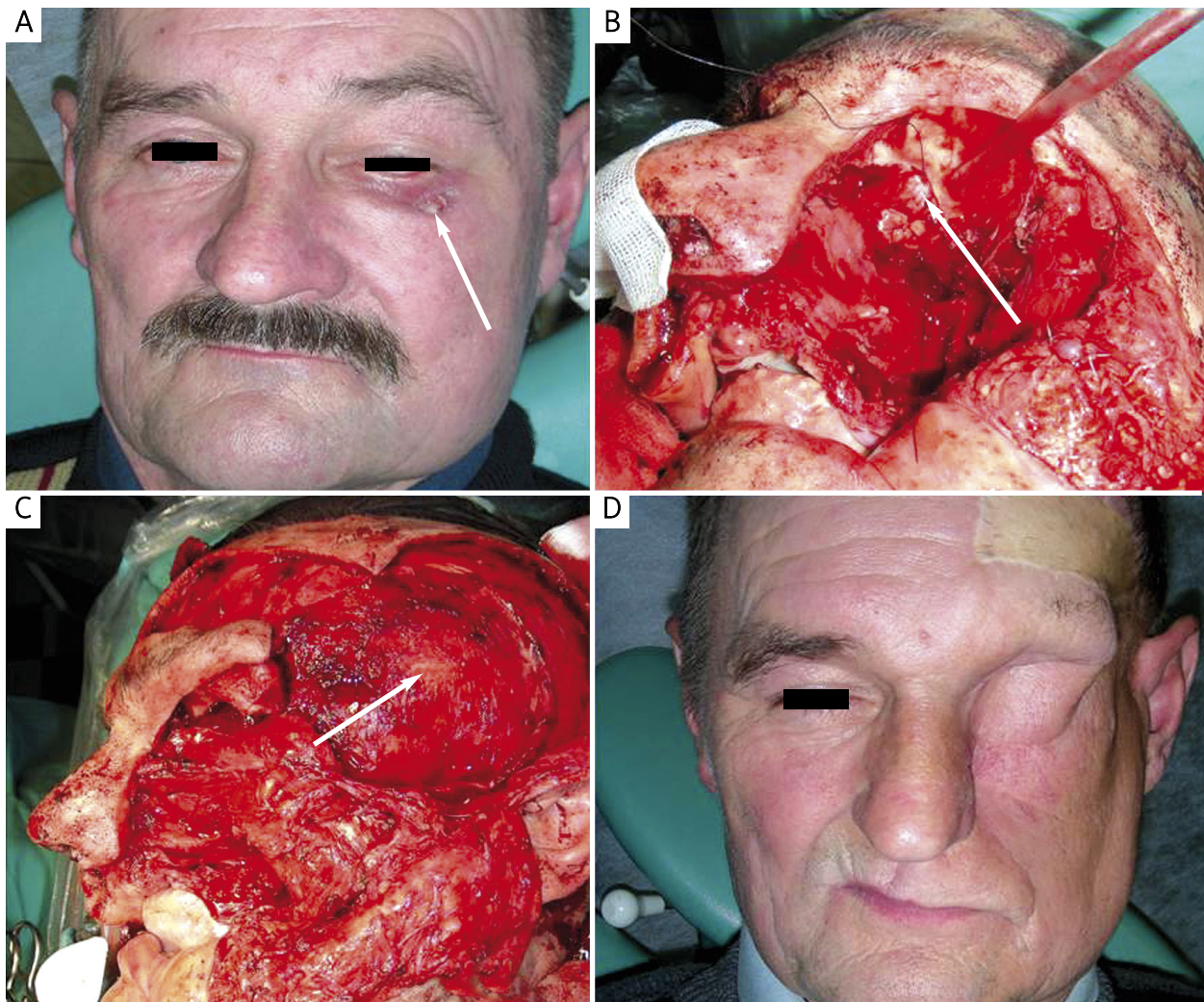


Fig. 2. Patient H.B. A – SCC of maxillary-en face view; B – intraoperative view-exposed dura mater; C – displaced temporal muscle; D – status 1 year after surgery

In one case partial necrosis of flap's edge and oronasal fistula occurred. The other part of the flap incorporated and constituted a good support for denture with obturator that separates oral cavity from the nose. In the other two patients little oroantral connections closed following application of secondary approximation sutures.

In 4th–6th week following the procedure radiotherapy (RT) was commenced. The flaps restoring hard palate responded to supplementary RT with no complications.

Discussion

In our material the muscular-fascia flap of the temporal muscle used for reconstruction of maxilla-facial tissues after oncologic procedures had one of the following functions:

- tight separation of the oral cavity from nasal cavity following maxillary resection
- or
- reconstruction of the orbit and/or covering dura mater of anterior cranial fossa uncovered during removal of the upper face.

Reconstruction of hard palate defect with temporal muscle placed in the oral cavity allowed for patients' normal

eating and reduced disability connected with maxillary resection. The temporal muscle placed in the oral cavity constituted a support for dentures by strengthening their fixation in the oral cavity. Tight separation of the oral cavity from the nasal cavity also allowed for maintenance of understandable speech. Possibility of normal eating and maintaining speech significantly improved patients' quality of life [13].

A similar evaluation of using temporal flap for restoration of hard palate following maxillary resection is presented by other authors [1–5, 7, 12, 14].

The second application of the temporal muscle flap was tilling the orbit and/or covering dura mater of anterior cranial fossa uncovered during removal of neoplasm from this region. This was necessary in 5 patients with tumors infiltrating orbit, ethmoid bone and frontal sinus. In these cases the temporal muscle constituted both a cover for the uncovered dura mater and reconstruction of tissue defect formed by removal of the tumor.

Application of temporal muscle into the orbit closed the empty space above which dehiscence of skin wounds with no tissue support frequently occurs and difficult to close fistulas are formed.

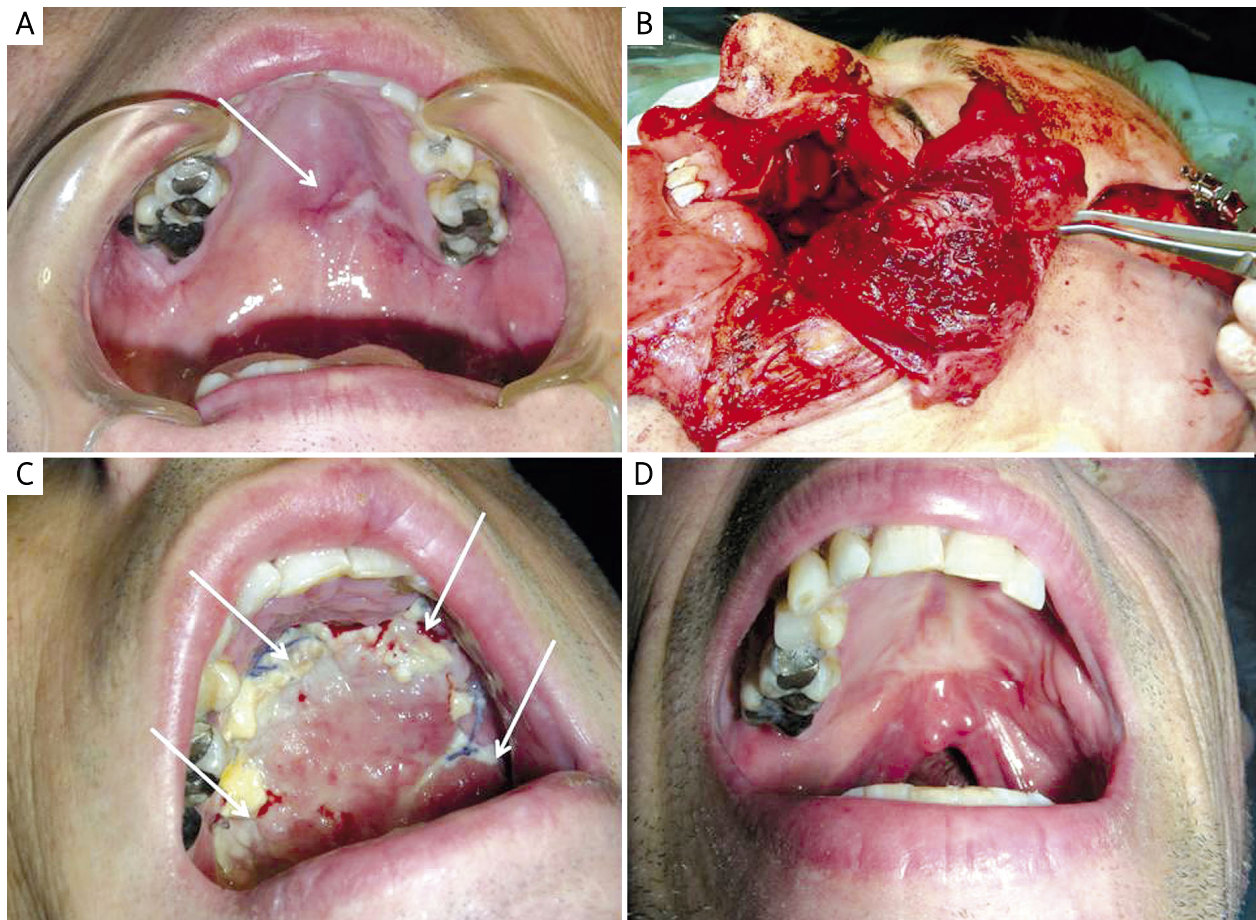


Fig. 3. Patient Z.K. A – adenoid cystic carcinoma of the maxillary sinus-status before treatment; B – intraoperative view; C – temporal muscle flap-status 2 weeks after surgery; D – view 1 year after surgery

In all the cases the transferred temporal muscle incorporated with no complications and isolated the uncovered dura mater from air spaces of nasal cavity and ethmoid bone. This minimized possibilities of intracranial complications and provided good conditions for skin wound healing as well as contributed to satisfactory esthetic effect. A similar evaluation of using temporal muscle flap for closing spaces after removal of upper face tumors is presented by other authors as well [8, 11, 12, 15].

Temporal muscle flap is especially easily predestinated for applying in reconstructive procedures of maxilla-facial regions. Its values are axial vascularization, location close to reconstruction site, easy harvest and good results with its use [9]. The flap is plane, easy to form and contrary to skin flaps has no hair. Also, if placed in the oral cavity defect within 4–6 weeks, it undergoes epithelization [16]. Its harvest has no impact on mandible mobility while harvesting site is not noticeable except for a little skin depression which can be easily covered by hair. Application of this flap is especially beneficial in the case of maxillary resection. Tight separation of the oral cavity from the nose eliminates disability connected with eating and speaking disorders as well as it significantly improves patients' quality of life [13].

Taking into account the values of applying fascia-muscular flap of temporal muscle, it ought to be considered as one of

the fundamental restoration methods in the maxilla-facial region rather than other, more complex, time-consuming and expensive methods of reconstructive therapy [1–3, 5, 7, 10, 12, 15].

In conclusion: fascia-muscular flap of temporal muscle is a simple, easy and effective method of tissue reconstruction in maxillo-facial region following extensive oncologic procedures.

References

1. Clauser L, Curioni C, Spanio S. The use of the temporalis muscle flap in facial and craniofacial reconstructive surgery. A review of 182 cases. *J Craniomaxfac Surg* 1995; 23: 203-214.
2. Abubaker AO, Abouzgia MB. The temporalis muscle flap in reconstruction of intraoral defects: an appraisal of the technique. *Oral Surg* 2002; 94: 24-30.
3. Ahmad S, Warraich RA, Abid H, Ali S. The Versatility of Temporalis Muscle Flap in Reconstruction of Maxillofacial Region Defects. *Annals* 2009; 15: 27-30.
4. Bakamjan V. A technique for primary reconstruction of the palate after radical maxillectomy for cancer. *Plast Reconstr Surg* 1963; 31: 103-17.
5. Cenzi R, Carinci F. Calvarial bone grafts and temporalis muscle flap for midfacial reconstruction after maxillary tumor resection: a long-term retrospective evaluation of 17 patients. *J Craniofac Surg* 2006; 17: 1092-104.
6. Curioni C, Toscano P, Fioretti C, Salerno G. Reconstruction of the orbital floor with the muscle-bone flap (temporalis muscle with coronoid process). *J Max Fac Surg* 1983; 11: 263-8.

7. Mani V, Panda AK. Versatility of temporalis myofascial flap in maxillofacial reconstruction – analysis of 30 cases. *Int J Oral Maxfac Surg* 2003; 32: 368-72.
8. Menderes A, Yılmaz M, Vayvada H, Demirdover C, Barutçu A. Reverse temporalis muscle flap for the reconstruction of orbital exenteration defects. *Ann Plast Surg* 2002; 48: 521-6.
9. Michaelidis IG, Hatzistefanou IM. Functional and aesthetic reconstruction of extensive oral ablative defects using temporalis muscle flap: a case report and a sort review. *J Craniomaxillofac Surg* 2011; 39: 200-5.
10. Smith JE, Ducic Y, Adelson R. The utility of the temporalis muscle flap for oropharyngeal, base of tongue, and nasopharyngeal reconstruction. *Otolaryngol Head Neck Surg* 2005; 132: 373-80.
11. Smith JE, Ducic Y, Adelson RT. Temporalis muscle flap for reconstruction of skull base defects. *Head Neck* 2010; 32: 199-203.
12. Yücel A, Yazar S, Aydin Y, Seradjimir M, Altıntaş. Temporalis muscle flap for craniofacial reconstruction after tumor resection. *J Craniofac Surg* 2000; 11: 258-64.
13. Krzymański G, Domański W, Biernacka B, Posmyk S. Zastosowanie płata z mięśnia skroniowego do rekonstrukcji tkanek po resekcji szczęki. Opis przypadku. *Czas Stomat* 1999; LII(1): 33-37.
14. Del Hoyo JA, Fernandez Sanroman J, Gil-Diez JL, Diaz Gonzalez FJ. The temporalis muscle flap: an evaluation and review of 38 cases. *J Oral Maxillofac Surg* 1994; 52: 143-7.
15. Menon NG, Girotto JA, Goldberg NH, Silverman RP. Orbital reconstruction after exenteration: use of a transorbital temporal muscle flap. *Ann Plast Surg* 2003; 50: 38-42.
16. Bradley P, Brockbank J. The temporalis muscle flap in oral reconstruction. *J Max Fac Surg* 1981; 9: 139-45.

Address for correspondence

Tomasz Piętko

Department of Maxillofacial Surgery
Military Institute of Medicine
Szaserów 128
04-141 Warszawa
e-mail: stomek@poczta.onet.pl

Submitted: 10.11.2011

Accepted: 15.02.2012