

Ocular Fireworks Injuries in Eastern Nigeria: A 3-Year Review

Akunne Ijeoma Apakama, Cosmas C Anajekwu¹

Department of Ophthalmology, Nnamdi Azikiwe University, Awka, ¹Department of Ophthalmology, Enugu State University of Science and Technology, Enugu, Nigeria

ABSTRACT

Aim: The aim of this study is to determine the incidence and types of ocular injuries caused by fireworks in patients seen at Guinness Eye Centre Onitsha and their effects on vision. **Methods:** This was a 3-year retrospective study evaluating case files of patients with ocular fireworks injuries seen at Guinness Eye Centre Onitsha during the Christmas and New Year festivities (2010–2012). Information was extracted into a pro forma and analyzed using Excel, AutoSum, and calculators. **Results:** Subconjunctival hemorrhage, corneal lacerations, and hyphema were the most common injuries seen. Patients had multiple ocular pathologies, and the left eye was affected in 62.5% of cases. Bystanders accounted for 75% of those with ocular fireworks injuries. All were males. Half of the affected eyes went blind. **Conclusion:** Fireworks injuries constituted only 5.1%, 0%, and 10% of ocular injuries in 2010, 2011, and 2012, respectively, with devastating consequence of blindness in 50% of affected eyes.

KEYWORDS: Fireworks, injuries, ocular

INTRODUCTION

Fireworks commonly known as “bangers” or “knockouts” are widely used in Nigeria during festivities such as Christmas, New Year, Eid-Maulud, Independence Day, and sporting activities. Fireworks are used in different parts of the world to commemorate national and religious events. The use of fireworks for purposes of celebration is associated with fireworks casualties.^[1] Eye injuries from fireworks can cause devastating visual and disfiguring effects.^[2] Eye trauma accounts for an estimated 18% of the total number of fireworks injuries.^[3] In India, a hospital-based, single-center, retrospective case series of fireworks injuries reported a range of ocular pathologies from conjunctival or corneal burns to globe rupture with interventions ranging from ocular wash to repair of globe perforation.^[4] Many patients, especially children, present with severe, acute eye injuries from fireworks, including globe rupture, hyphema, retinal detachment, and optic atrophy. A significant proportion requires surgery. These injuries deserve special concern because they often portend a poor prognosis for visual function.^[5]

Different countries have laws governing the production (including quantity and type of explosives) of

fireworks and its use by consumers. Countries or states implementing restrictive fireworks laws concerning the personal use of fireworks show significantly lower incidence rate of ocular fireworks trauma. Mean injury rate is 0.35/100,000 in restrictive regions compared to 2.70/100,000 in permissive regions. Restrictive regions show 87% less ophthalmic fireworks trauma.^[1]

There are laws guiding the importation, production, and use of explosives which include fireworks in Nigeria,^[6] but these laws do not translate into action or implementation.

This is a retrospective analysis of ocular fireworks injuries seen at Guinness Eye Centre Onitsha during the Christmas and New Year celebrations of 2010–2012.

Justification

Ocular injuries from fireworks have been shown to have lower incidence in countries implementing restrictive fireworks laws.^[1] The incidence in restrictive or nonrestrictive countries notwithstanding, these injuries

Address for correspondence: Dr. Akunne Ijeoma Apakama, Department of Ophthalmology, Nnamdi Azikiwe University, Awka, Nigeria.
E-mail: akunneapakama@yahoo.com

This is an open access journal, and articles are distributed under the terms of the Creative Commons Attribution-NonCommercial-ShareAlike 4.0 License, which allows others to remix, tweak, and build upon the work non-commercially, as long as appropriate credit is given and the new creations are licensed under the identical terms.

For reprints contact: reprints@medknow.com

How to cite this article: Apakama AI, Anajekwu CC. Ocular fireworks injuries in Eastern Nigeria: A 3-year review. *Niger J Surg* 2019;25:42-4.

Access this article online	
Quick Response Code: 	Website: www.nigerianjsurg.com
	DOI: 10.4103/njs.NJS_29_15

deserve attention because of their poor prognosis for visual function.

MATERIALS AND METHODS

This study was carried out in Guinness Eye Centre Onitsha, the Eye Department of Nnamdi Azikiwe University Teaching Hospital, Nnewi. This is the only stand-alone tertiary eye hospital in Eastern Nigeria. Majority of the patients attended to are from the five eastern states and across the Niger.

Case files of all patients with ocular trauma seen during Christmas–New Year festivity of December 2010\January 2011 to December 2012\January 2013 were examined and those due to fireworks further evaluated.

Information was abstracted into a pro forma and included history, presenting and last recorded visual acuity, anterior and posterior segment examination findings, intraocular pressure measurements, and results of ancillary tests. This was analyzed using Excel, AutoSum, and calculators.

RESULTS

In December 2010/January 2011, 59 ocular trauma patients were seen out of which 3 were due to fireworks. Seventy-five ocular trauma patients were seen December 2011/January 2012, but none was due to fireworks. Five ocular injuries due to fireworks were seen in December 2012/January 2013 out of 50 cases of ocular trauma. Incidence of ocular fireworks injuries was therefore 5.1%, 0%, and 10%, respectively.

All patients seen were males (M: F = 8/0) and 75% bystanders. Their ages ranged from 10 to 43 years, with a mean of 26 years. Three out of the eight patients presented within 24 h of sustaining injuries, four after 3 days, while one was seen more than a week after injuries.

Injuries on the left eye accounted for 62.5% while 37.5% sustained injuries on the right [Table 1].

Four (50%) of the patients were blind (visual acuity <3/60) in the affected eye on presentation while additional 2 (25%) were visually impaired (visual acuity <6/18). Visual acuity 4 weeks after presentation showed remarkable improvement in only 2 patients [Figure 1].

The patients had multiple presenting complaints, and the most common complaint was pain.

Adnexal and ocular pathologies

Seven out of the eight patients had ocular adnexal injuries which ranged from lid edema and lid abrasions to full-thickness lid lacerations [Figure 2].

Table 1: Visual acuity on presentation and 4 weeks after presentation

	Presenting visual acuity	Visual acuity 4 weeks after presentation
6/6-6/18	2	4
6/24-3/60	2	0
<3/60-LP	2	2
NPL	2	2
Total	8	8

NPL: No perception of light, LP: Light Perception

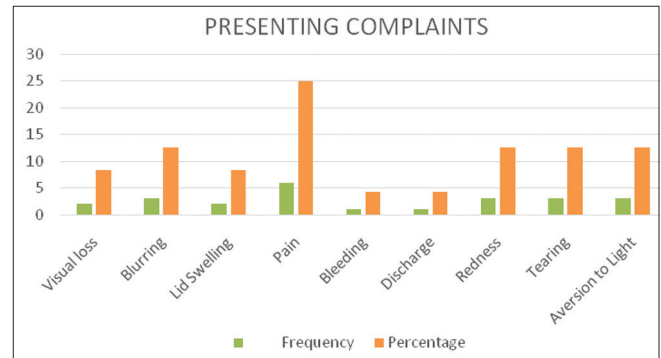


Figure 1: Presenting complaints. STDEV = 1.5

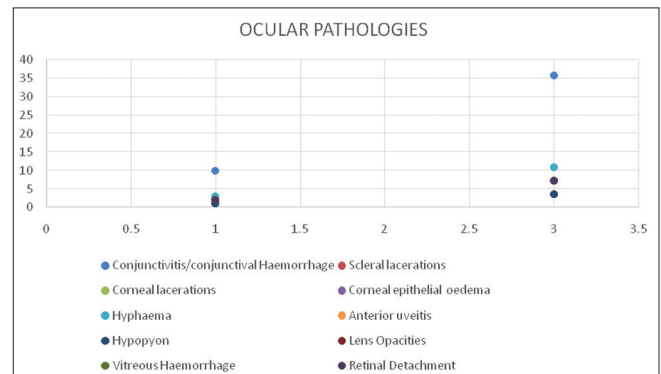


Figure 2: Ocular pathologies on presentation. STDEV = 2.6

The affected eyes had multiple pathologies from the trauma. Serious pathologies seen included corneal and corneoscleral lacerations with vitreous loss, hyphema (one full chamber), secondary glaucoma, vitreous hemorrhage, and retinal detachment.

DISCUSSION

Incidence of ocular injuries resulting from fireworks during the Christmas and New Year festivities was 5.1 in 2010, 0% in 2011, and 10% in 2012. All the patients seen in this study were males (100%) with an age range of 10–43 years while 75% of them were bystanders. The systematic review showed that fireworks trauma occurred predominantly in young men (male 77% and young 82%) with bystanders accounting for 47% of the injured.^[1] In the Indian study, bystanders accounted for over 50%.^[4]

Half of the affected eyes (50%) were blind as a result of these injuries, while in the systematic review, severe visual loss was seen in 16.4%.^[1] Firework use by revelers during festivities is widely spread in Nigeria. They have become an important cause of preventable visual disability, particularly in young males causing loss of vision in a single eye.^[2] The left eye was predominantly affected 62.5%, while during Deepavali festival, 60.8% right eyes were affected.^[4]

Two bystanders had no perception of light at presentation in the affected eye out of six. The two patients who threw the fireworks had better visual acuity and less serious pathologies in the affected eye than the bystanders. Serious injuries sustained by these bystanders included full-thickness upper lid laceration, corneoscleral laceration, full chamber hyphema, thigh, and hand bruises. They lost the use of their left eye (62.5%).

In Malaysia, during Eid al-Fitr celebration in 2008, it was noted in a prospective study of all patients with ocular burns and related injuries due to fireworks that 96.7% were males and the left eye was affected in 46.7%. Bystanders accounted for 50% of those injured. Thermal injuries such as burns to the eyelids and cornea accounted for 60% of the injuries while 40% were from explosion of the firework.^[7]

Sacu *et al.* also noted 68% male preponderance in Vienna though more on the right eye with skin and corneal erosions accounting for 25% of the injuries. Very severe injuries were in 10% while visual impairment (28%) was mainly due to corneal scar and retinal pathologies.^[8]

The single most dangerous type of fireworks is the bottle rocket, which flies erratically and causes bystander injury. The bottles and cans used to launch them often explode, showering fragments of glass and metal.^[9] Although most ocular trauma from fireworks is said to be mild and temporary, one in six casualties sustains eye trauma with severe vision loss (<10/200);^[11] in this study, it was not possible to objectively ascertain the sizes of the fireworks or the quantity of explosives in them, but the two patients who had no perception of light in the affected eyes described the banger as large based on the sound it made on explosion. This is subjective and is reflected in the lack of correlation between the presenting visual acuity in the affected eye and the size of the banger as judged by the patient. That notwithstanding the enormity of the effects of these fireworks whether large, medium, or small as shown by the visual acuity and the pathologies seen in these young males cannot be glossed over. At present, the laws guiding the

importation, production, and use of fireworks in Nigeria are not adequately enforced since fireworks are used at will during festivities and celebrations. It is common knowledge that fireworks are thrown into where groups of people are gathered during festivities. This usually is not to cause harm but to add to the excitement of the celebration. The public, therefore, do not seem knowledgeable on the provisions of the law which state that unlawful casting or throwing of any such fluid or substance (explosive substances including fireworks) at or upon any person is guilty of a felony and is liable to life imprisonment.^[5] Strict implementation of existing laws on the importation, production of fireworks, and the quantity of explosives in them is advocated.

CONCLUSION

The extent and consequences of injuries sustained in this report are clear indications to what indiscriminate use of fireworks could result in.^[1] The use of fireworks among the public should be regulated, in addition to public enlightenment on eye protection and safety measures during its use. This will help reduce preventable visual disability in our young males.

Financial support and sponsorship

Nil.

Conflicts of interest

There are no conflicts of interest.

REFERENCES

1. Wisse RP, Bijlsma WR, Stilma JS. Ocular firework trauma: A systematic review on incidence, severity, outcome and prevention. *Br J Ophthalmol* 2010;94:1586-91.
2. Knox FA, Chan WC, Jackson AJ, Foot B, Sharkey JA, McGinnity FG, *et al.* A British ophthalmological surveillance unit study on serious ocular injuries from fireworks in the UK. *Eye (Lond)* 2008;22:944-7.
3. US Consumer Product Safety Commission. Estimated Firework Trauma. National Electronic Injury Surveillance System. Available from: <http://www.cpsc.Gov/liberty/neiss.html>. [Last accessed on 2013 Sep 24].
4. Kumar R, Puttanna M, Sriprakash KS, Sujatha Rathod BL, Prabhakaran VC. Firecracker eye injuries during Deepavali festival: A case series. *Indian J Ophthalmol* 2010;58:157-9.
5. Rao RC, Dlouhy BJ. Exposure to fireworks and eye injuries. *JAMA* 2012;308:1523-4.
6. Criminal Act (Nigeria), Sec. 332, Subsections 3,4,5,6 and 7. chapter 77, laws of the federation 1990.
7. Rashid RA, Heidary F, Hussein A, Hitam WH, Rashid RA, Ghani ZA, *et al.* Ocular burns and related injuries due to fireworks during the Aidil Fitri celebration on the East Coast of the Peninsular Malaysia. *Burns* 2011;37:170-3.
8. Sacu S, Ségur-Eltz N, Stenng K, Zehetmayer M. Ocular firework injuries at new year's eve. *Ophthalmologica* 2002;216:55-9.
9. Prevent Blindness America. Available from: <http://www.preventblindness.org>. [Last accessed on 2013 Sep 24].