

# Foot Salvage with Selective Arterialization of Pedal Venosomes

Maleeh Effendi, BS\*

Austin Y. Ha, MD†

John M. Felder III, MD†

**Background:** Lower extremity salvage using microvascular flaps can be considered in high-functioning patients, but indications for salvage are often restricted by distal microvascular disease that may threaten the foot as a whole. Selective arterialization of specific pedal venosomes is a novel potential solution to this problem.

**Methods:** A 48-year-old man with a chronic left plantar forefoot wound, osteomyelitis of the second and third metatarsal heads, and critical limb ischemia was evaluated for foot salvage. Despite a patent popliteal to posterior tibial bypass graft, residual ischemia was present in the first and second toes due to severe microvascular disease. This wound was reconstructed with a free partial medial rectus abdominis flow-through flap based on the medial branch of the deep inferior epigastric artery. The lateral branch was used as a flow-through vessel to arterialize the dorsal veins of the first webspace.

**Results:** Arterialization of the first webspace veins resulted in an immediate intraoperative improvement of the color of the first and second toes, along with creation of an arterial Doppler signal. The flap effectively covered the wound. The patient went on to heal completely and return to unrestricted ambulation. Transcutaneous oxygen measurement values of the dorsal foot improved from 35.8 mm Hg preoperatively to 48.3 mm Hg postoperatively.

**Conclusions:** In patients with focal areas of critical ischemia, selective arterialization of the venous system may be an effective method of preventing tissue loss and improving wound healing. A flow-through flap can be used to accomplish this in tandem with wound reconstruction. (*Plast Reconstr Surg Glob Open* 2020;8:e2612; doi: 10.1097/GOX.0000000000002612; Published online 20 February 2020.)

## INTRODUCTION

Plantar foot salvage for a chronic wound, in the setting of diabetes and peripheral vascular disease, poses many difficult reconstructive challenges due to the paucity of local tissue, the dynamic weight-bearing surface, and the presence of microvascular disease. Current management of these patients ranges from local wound care to amputation, with free flap salvage as an option in select cases to avoid the high morbidity and mortality associated with lower extremity amputations. The decision to attempt salvage can be guided by published severity scores.<sup>1,2</sup> More

recent studies have shown that salvage should be attempted in the majority of cases, especially if lower extremity function is preserved and the patient is highly motivated.<sup>1-4</sup> In many cases, the decision to pursue salvage must take into account a number of complex factors requiring experience on the part of the surgeon. However, the primary factor for determining the feasibility of salvage is always the vascular status of the limb.

When considering plantar forefoot wounds that involve osteomyelitis, there are 3 basic surgical options for limb salvage. The first is local pedicled flaps, such as “fillet-of-toe” or toe pulp flaps, which are not reliable options in patients with severe microvascular disease.<sup>3</sup> The second is free tissue transfer, which may also be difficult to apply in the setting of coexisting vascular disease, due to the lack of suitable recipient vessels in the vicinity of the wound.<sup>5</sup> This is particularly true for forefoot wounds, where the nearest recipient vessels (in patients with severe microvascular disease) are at the level of the ankle and require a flap with

From the \*Section of Plastic and Reconstructive Surgery, Department of Surgery, University of Cincinnati, Cincinnati, Ohio; and †Division of Plastic and Reconstructive Surgery, Department of Surgery, Washington University in St. Louis, St. Louis, Mo.

Received for publication August 28, 2019; accepted November 13, 2019.

Copyright © 2020 The Authors. Published by Wolters Kluwer Health, Inc. on behalf of The American Society of Plastic Surgeons. This is an open-access article distributed under the terms of the [Creative Commons Attribution-Non Commercial-No Derivatives License 4.0 \(CCBY-NC-ND\)](https://creativecommons.org/licenses/by-nc-nd/4.0/), where it is permissible to download and share the work provided it is properly cited. The work cannot be changed in any way or used commercially without permission from the journal.

DOI: 10.1097/GOX.0000000000002612

**Disclosure:** The authors have no financial interest to declare in relation to the content of this article.

Related Digital Media are available in the full-text version of the article on [www.PRSGlobalOpen.com](http://www.PRSGlobalOpen.com).

a long pedicle. The final option is forefoot amputation. Although toe amputation is well tolerated, plantar forefoot wounds necessitate amputations at the transmetatarsal or more proximal levels. Large wounds of the plantar surface destroy the plantar flap needed for closure of a functional transmetatarsal-level amputation. Unfortunately, more proximal levels of partial foot amputation, such as the LisFranc or Chopart levels, demonstrate poor function for ambulation and are not appropriate for otherwise active and ambulatory patients.

In patients with critical limb ischemia who have exhausted traditional surgical revascularization options, arterialization of the venous system of the entire foot may be used to assist in wound healing and/or pain relief and is usually accomplished via the greater saphenous vein (GSV), medial marginal vein, dorsal venous arch, popliteal vein, or the tibial vein. Such procedures have been shown to have up to 75% salvage rates at 12 months.<sup>6-9</sup> To our knowledge, there is no report of selective arterialization of a specific pedal venosome to relieve distal forefoot ischemia in an otherwise adequately perfused foot. Here, we present a case in which a free rectus abdominis flow-through flap was used to reconstruct a stage IV diabetic plantar foot wound with selective arterialization of the first webspace venosome.

### MATERIALS AND METHODS

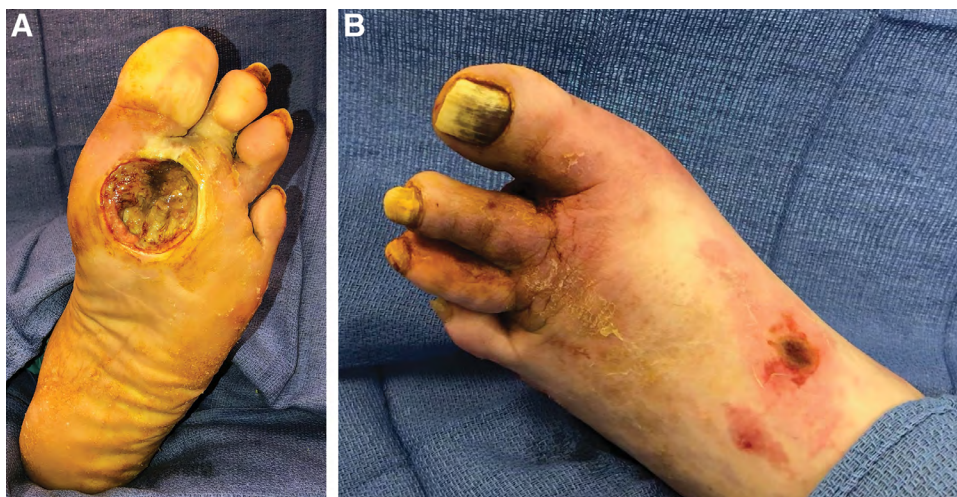
A 48-year-old man with multiple comorbidities presented with a stage IV left plantar forefoot wound and osteomyelitis of the second and third metatarsal heads (Fig. 1A). Months of local wound care, hyperbaric oxygen, and intravenous antibiotics at an outside hospital failed to heal the wound. He was also noted to have clinically worsening ischemia of the first and second toes with visible dorsal cyanosis and plantar pallor (Fig. 1B) despite multiple vascular surgery interventions, including a remote popliteal to posterior tibial artery bypass with GSV graft and a recent angioplasty of that bypass. Angiography at the time

of angioplasty revealed diffuse peripheral arterial disease with the foot supplied solely by the popliteal to posterior tibial artery bypass (Fig. 2). The pedal vasculature was diffusely diseased with no arterial targets for further revascularization. The dorsal circulation was largely absent. Given that he was a lifetime nonsmoker, ambulatory, and highly motivated, he was deemed a suitable candidate for salvage.

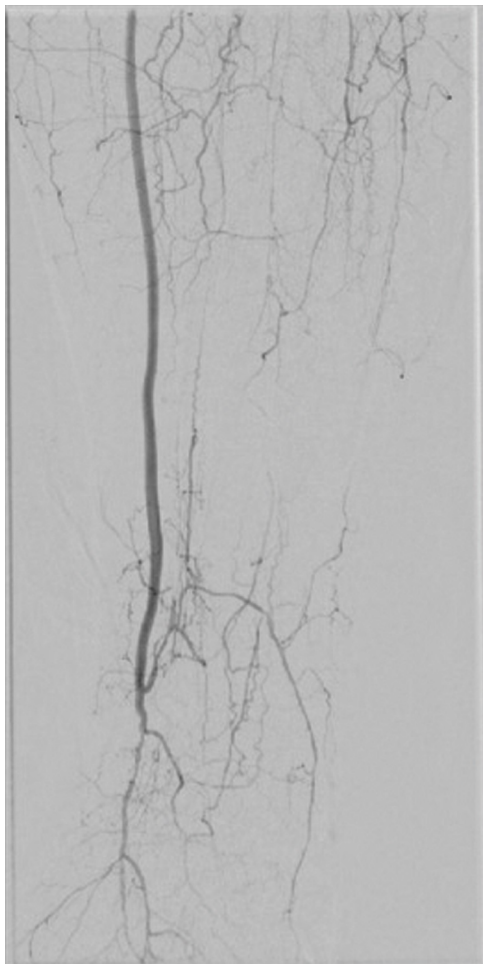
Surgical treatment began with radical debridement of all devitalized tissue from the wound. The second and third metatarsophalangeal joints were resected for treatment of osteomyelitis. A free partial medial rectus abdominis muscle flap based on the medial branch of the deep inferior epigastric artery (DIEA) was used to reconstruct the wound (Fig. 3A). The partial rectus (as opposed to the traditional rectus) was chosen both to fit the small shape of the wound and to allow maximum pedicle length for reach from the ankle to the distal forefoot (17 cm). A square “plug” of muscle and fascia were designed within the muscular segment of the rectus abdominis just cephalad to the umbilical inscription (Fig. 3B). This particular muscular segment of the rectus would also allow inclusion of the lateral branch of the DIEA as a flow-through vessel (See Video 1 [online], which displays a summary of preoperative wound and angiogram and intraoperative course, including immediate on-table improvement of first webspace and great toe perfusion).

The anterior rectus sheath overlying the muscle “plug” was also taken, to provide a durable surface for weight bearing on the plantar foot. The flap donor site was closed with a unilateral anterior component separation and onlay polyglactin mesh.

Arterial anastomosis was performed end to side to the distal GSV graft, and venous anastomosis was performed end to end to the posterior tibial venae comitantes. Although the flap provided coverage of the wound, residual ischemia of the great and second toes made wound coverage alone an inadequate solution for salvage. There were no arterial targets on the foot for bypass to improve



**Fig. 1.** Preoperative condition of the foot. A, Plantar view of the patient's stage IV diabetic foot ulcer of the forefoot. Cutaneous pallor of the first webspace indicates critical ischemia distal to the wound. B, Dorsal view of the foot with cyanosis of the first webspace indicating critical ischemia.



**Fig. 2.** Preoperative angiogram demonstrating a patent popliteal to posterior tibial artery bypass, diseased plantar circulation, and largely absent dorsal circulation.

ischemia of the toes and forefoot. Therefore, a lateral muscular arterial branch of the flap was used as a flow-through vessel and anastomosed end to end to the first dorsal metatarsal vein after lysing the venous valves with a valvulotome (Fig. 4). Immediate intraoperative improvement in distal toe ischemia was noted, as judged by tissue color and capillary refill. Arterialization of the first webspace was confirmed with a handheld pencil Doppler, which showed a newly audible biphasic signal in the dorsal first webspace, of similar quality to the flap arterial signal (See Video 1 [online], which displays a summary of preoperative wound and angiogram and intraoperative course, including immediate on-table improvement of first webspace and great toe perfusion). No anesthesia-related adverse events occurred.

Postoperatively, there were no flap-related complications. The Doppler signal in the dorsal first webspace remained present throughout follow-up (See Video 2 [online], which displays outcomes at 10 months, including foot appearance, ambulation, abdominal wall donor site function, and clinical Doppler examination of the foot demonstrating long-term patency of the arterialized venous system and return of normal skin color and quality).

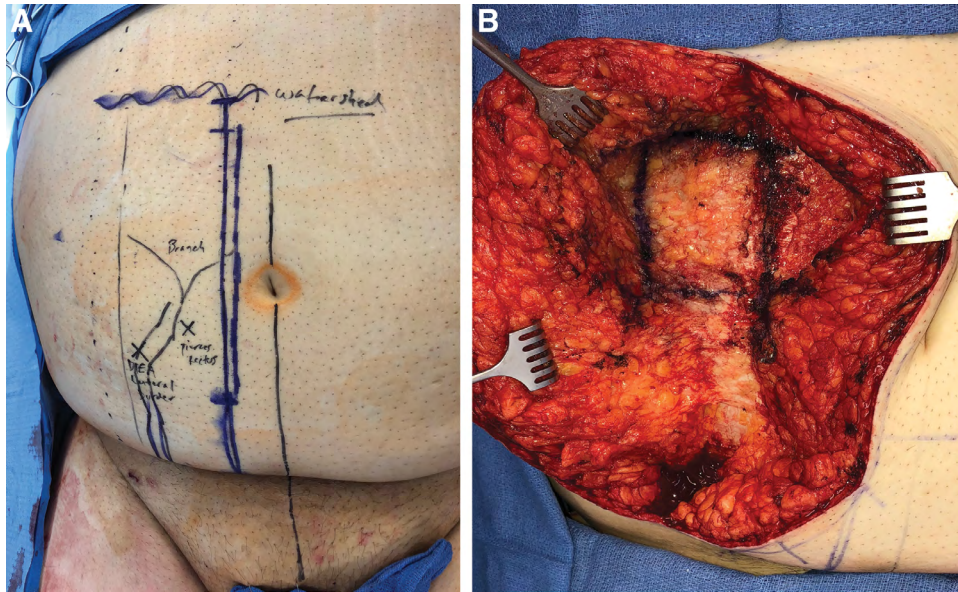
At 6 weeks postoperatively, the patient underwent flap thinning and reinsert, and repeated skin grafting to a small area of skin graft loss. The thinning was performed to correct an overly-bulky flap which was impeding wound healing and causing maceration. The flap was not thinned at the primary operation out of concern for potential injury to the flow-through system; at the time of thinning, the flap had matured and atrophied sufficiently to allow tailoring of the flap with less risk of injuring the intraflap vascular system. Additionally at this time, an Achilles tendon lengthening was performed to correct the equinus contracture.

At 3 months postoperatively from the index surgery, the patient had completely healed and returned to ambulation in a total contact cast (Fig. 5). No donor site complications were noted (See Video 2 [online], which displays outcomes at 10 months, including foot appearance, ambulation, abdominal wall donor site function, and clinical Doppler examination of the foot demonstrating long-term patency of the arterialized venous system and return of normal skin color and quality). At 5 months postoperatively from the index surgery (3.5 months after flap thinning and repeated skin grafting), the patient returned to ambulation in a normal diabetic shoe. At 10 months postoperatively (final follow-up), the dorsal first webspace retained an audible Doppler signal and normal skin color. Transcutaneous oxygen measurements (TCOMs) rose from 35.8 mm Hg preoperatively to 48.3 mm Hg postoperatively on the dorsal foot. TCOM values greater than 40 have been demonstrated to be an accurate predictor of ischemic ulcer healing.<sup>10</sup> Although postoperative angiogram would have been informative, it was not obtained due to a lack of any medical indication needed to justify the additional risk.

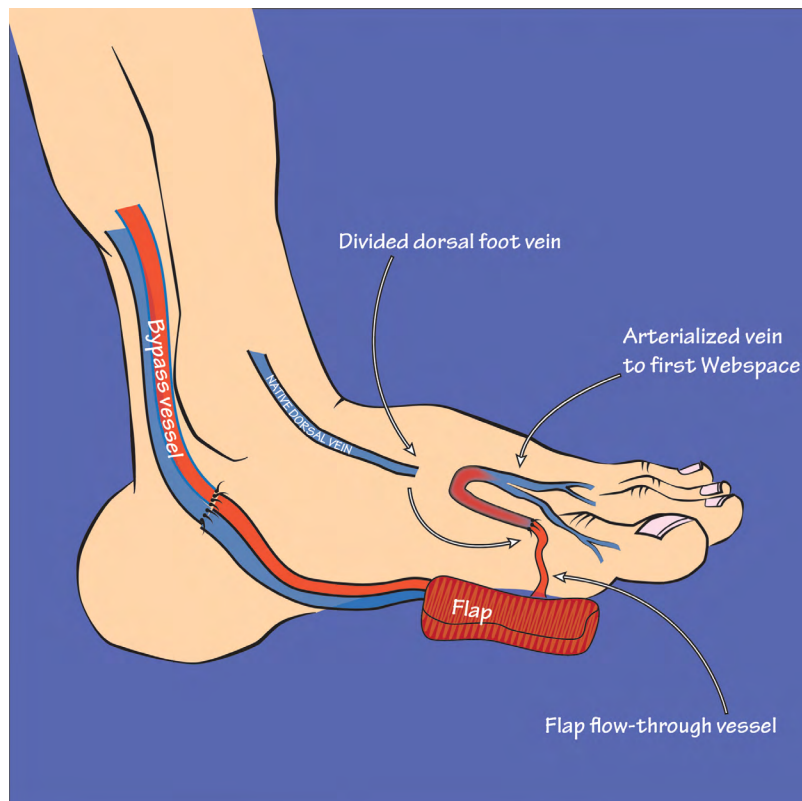
## DISCUSSION

Open plantar forefoot wounds associated with osteomyelitis in the setting of critical limb ischemia (despite appropriate revascularization procedures) represent a major risk for amputation with few solutions available for limb salvage. In fact, such a scenario could reasonably be considered a de facto criterion for below-knee amputation. This is because, even though a bypass or endovascular procedure may restore blood flow to the ankle or hindfoot, the forefoot may remain severely ischemic due to intrapedal arterial disease that limits outflow from the distal end of the bypass into the foot. Without adequate blood supply, salvage options relying on viable forefoot soft tissue, such as local flaps (eg, fillet-of-toe) or transmetatarsal amputations, are unlikely to heal.

A solution is needed, therefore, to restore arterial blood flow to the forefoot and peri-wound area in such cases, where the intrapedal arterial system is nonreconstructible, and traditional options for revascularization have already been exhausted. In this article, we introduce selective arterialization of a *targeted portion* of the venous system of the foot as a potential solution. We achieve this using a flow-through free flap as both the arterial conduit and the substrate for wound coverage, thus addressing “2 birds with 1 stone.”



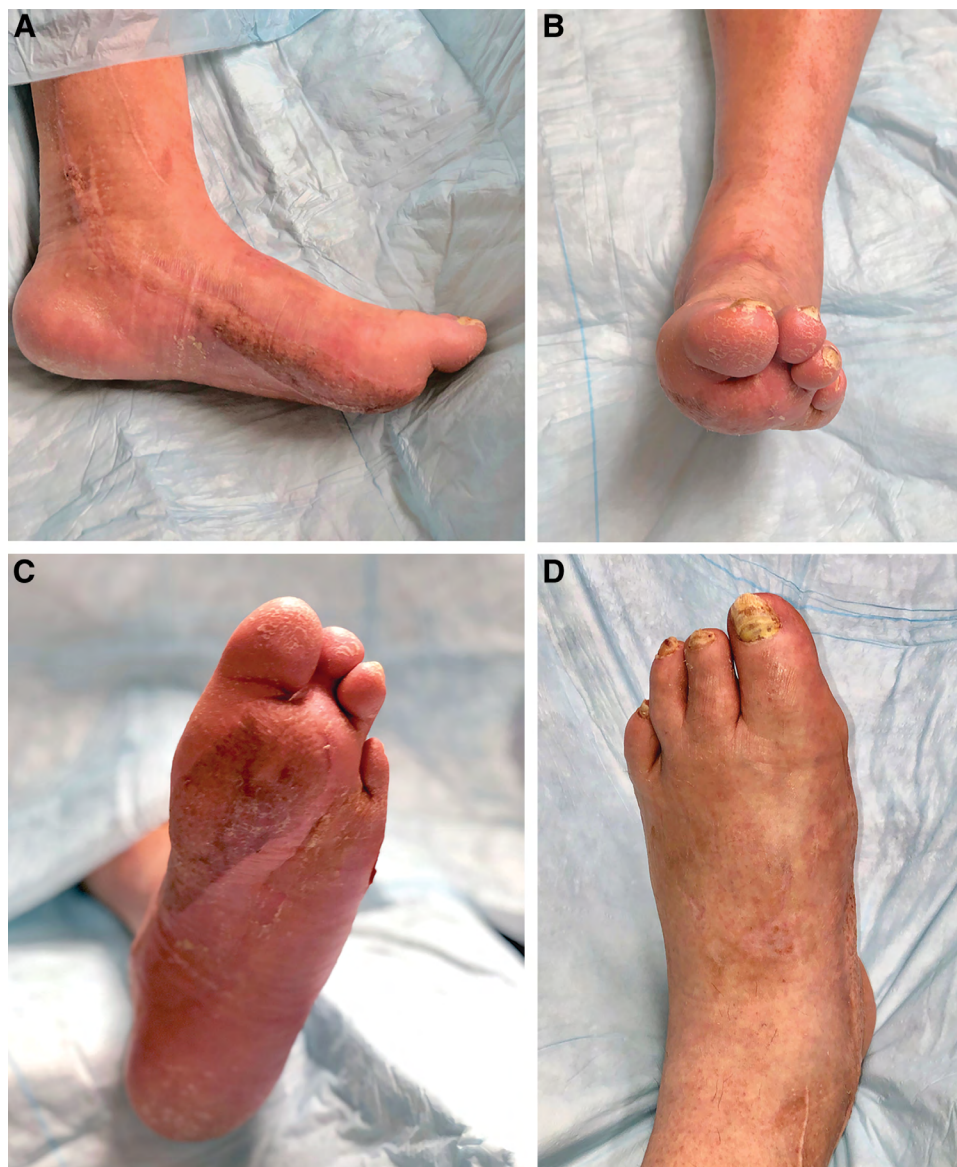
**Fig. 3.** Flap design. A, Preoperative markings for a partial medial rectus flap based on the medial branch of the DIEA with lateral branch as a flow-through vessel. B, Design of the partial medial rectus flap and inclusion of overlying anterior rectus sheath in the supra-umbilical segment of the rectus muscle.



**Fig. 4.** Schema of the vascular “plumbing” of the case demonstrating a free muscle flap anastomosed end to side to the bypass vessel, and a flow-through artery anastomoses end to end to the dorsal vein to the first webspace after lysis of venous valves.

Even in cases of severe arteriosclerosis, the venous system of the foot remains generally intact and therefore represents an open pathway for arterial bypass procedures. Arterialization of the *entire* foot, such as with

an arterialization of the saphenous vein at the popliteal artery, or arterialization of the posterior tibial vein in the leg, is a well-described procedure. Current vascular surgery research and meta-analysis suggest that venous



**Fig. 5.** Postoperative outcome at 3 months with total healing of the foot and restoration of normal contour. A, Medial view. B, Coronal view. C, Plantar view. D, Dorsal view.

arterialization of the entire foot can be useful in patients who have persistent ischemia despite exhaustive traditional vascular surgery interventions.<sup>7-9</sup> This technique utilizes the relatively disease-free venous system as a conduit for distal perfusion. Anastomosis is performed between the most distal patent artery and, most commonly, the great saphenous vein, posterior tibial vein in the leg, medial marginal vein, or the dorsal venous arch. The pooled rate of limb salvage at 12 months postoperatively was estimated to be 75% regardless of anastomosis site.<sup>7,8</sup> However, these studies have also shown postoperative complications of persistent lower extremity edema and even heart failure secondary to excessive arteriovenous shunting.

Arterialization of the entire foot may not be necessary when the hindfoot is sufficiently perfused via traditional revascularization procedures. In addition, if a foot wound is present that requires free flap coverage, arterialization

of the entire foot may preclude this option by depleting available recipient veins for flap outflow. Finally, arterialization of the entire foot represents a substantial change of physiology to the lower limb as a whole, and that may carry with it unintended negative consequences. This may explain why whole foot arterialization remains an uncommon procedure decades after its original description.

Patients with critical limb ischemia typically have an array of comorbidities, and avoidance of surgeries that may induce large physiologic changes is preferable. Although arterialization of the foot as a whole may be useful as a solution for severe pain at rest without tissue loss or to assist with whole foot wound healing, arterialization of a selective venosome may be preferred in patients with only focal areas of clinically significant ischemia. We suggest, based on our experience in this case, that selective arterialization may be able to resolve focal ischemia in an area

of threatened tissue loss, while avoiding the postoperative complications associated with entire foot arterialization. If the focal area of ischemia is also associated with a severe soft tissue defect, such as in this case, then use of a flow-through flap allows both wound reconstruction and selective arterialization of the ischemic area.

In our patient, the only patent vessel to the foot was a bypass from the popliteal artery to the posterior tibial artery at the level of the ankle. All arterial vessels distal to the bypass were nonreconstructible. The patient had developed a large ischemic ulceration with osteomyelitis in the region of the plantar first webspace. The skin of the dorsal first webspace was cyanotic, with impending necrosis. Thus, the partial medial rectus flap was selected for 3 reasons, with the idea of addressing both the wound and the ischemia. First, the pedicle length needed from the distal saphenous vein bypass graft at the ankle to the distal plantar forefoot was approximately 17 cm. By using a cephalad segment of the medial rectus, this pedicle length was achieved. Second, the DIEA has a reliable branching pattern that allowed for a separate arterial flow-through component via the lateral arterial branch; this flow-through vessel permitted concomitant arterialization of the veins to the first webspace. Lastly, inclusion of the anterior rectus sheath provided a more durable surface for weight bearing and ambulation. In this isolated case report, the use of this flap and selective arterialization of the pedal venous system provided an option for limb salvage that resulted in complete healing, return of normal tissue color and turgor, a meaningful improvement in local TCOM measurements, and a durable resurfacing of the wound that has allowed for continued ambulation at 10 months postoperatively.

This article is, of course, limited by its nature of being a case report. It is impossible to draw conclusions as to the wide applicability of these techniques from this isolated case and set of variables. However, given the severe circumstances of the presenting problem and the positive outcomes both functionally, in terms of return to unrestricted ambulation without recurrence of the wound, and qualitatively, in terms of restoration of normal tissue color and turgor, it seems like a promising start for a new area of investigation. In addition, the findings of this study would have been greatly strengthened by a postoperative angiogram directly demonstrating the effects of arterialization of the venous system. Although such imaging would have been very compelling, the risk to the patient of an invasive procedure involving exposure to contrast dye was deemed inappropriate given the lack of any anticipated clinical benefit. As a surrogate, TCOM measurements were taken from the dorsum of the foot (ie, not adjacent to the muscle flap but in the area of venous arterialization) and showed an improvement from the diseased range preoperatively to a level sufficient for wound healing postoperatively—this is at least suggestive of a meaningful vascular improvement related to arterialization of the venous system. In addition, simple photographic appearance of the tissues from preoperative to postoperative and a clinical Doppler examination (See [Video 1 \[online\]](#), which displays a summary of preoperative wound and angiogram and intraoperative course, including immediate on-table

improvement of first webspace and great toe perfusion, and See [Video 2 \[online\]](#), which displays outcomes at 10 months, including foot appearance, ambulation, abdominal wall donor site function, and clinical Doppler examination of the foot demonstrating long-term patency of the arterialized venous system and return of normal skin color and quality) give an outcome measure for the procedure that is certainly scientifically unvalidated, but perhaps, at the least, clinically demonstrative for surgeons interested in further investigating this type of work.

## CONCLUSIONS

In patients with focal areas of nonreconstructible critical ischemia in the foot, selective arterialization of portions of the venous system may be an effective method of preventing tissue loss and improving wound healing. A flow-through flap can be used to accomplish this procedure in tandem with wound reconstruction. Surgeons considering limb salvage in cases of nonhealing foot wounds where traditional options for revascularization have been exhausted may wish to consider this approach. Further study of this technique appears to be warranted.

**John M. Felder III, MD**

Division of Plastic and Reconstructive Surgery  
Department of Surgery  
Washington University School of Medicine  
660 South Euclid Avenue  
Northwest Tower, Suite 1150, Campus Box 8238  
St. Louis, MO 63110  
E-mail: [felder@wustl.edu](mailto:felder@wustl.edu)

## REFERENCES

1. Soltanian H, Garcia RM, Hollenbeck ST. Current concepts in lower extremity reconstruction. *Plast Reconstr Surg.* 2015;136:815e–829e.
2. Engel H, Lin CH, Wei FC. Role of microsurgery in lower extremity reconstruction. *Plast Reconstr Surg.* 2011;127(Suppl 1):228S–238S.
3. Ducic I, Attinger CE. Foot and ankle reconstruction: pedicled muscle flaps versus free flaps and the role of diabetes. *Plast Reconstr Surg.* 2011;128:173–180.
4. Endara M, Ducic I, Attinger C. Free tissue transfer for limb salvage in high-risk patients: worth the risk. *Adv Wound Care (New Rochelle).* 2013;2:63–68.
5. Ducic I, Rao SS, Attinger CE. Outcomes of microvascular reconstruction of single-vessel lower extremities: limb salvage versus amputation. *J Reconstr Microsurg.* 2009;25:475–478.
6. Zeng W, Hammert WC. Arterialization of the venous system for treatment of chronic ischemia in the hand. *Plast Reconstr Surg.* 2016;137:1213–1220.
7. Schreve MA, Vos CG, Vahl AC, et al. Venous arterialisation for salvage of critically ischaemic limbs: a systematic review and meta-analysis. *Eur J Vasc Endovasc Surg.* 2017;53:387–402.
8. Lu XW, Idu MM, Ubbink DT, et al. Meta-analysis of the clinical effectiveness of venous arterialization for salvage of critically ischaemic limbs. *Eur J Vasc Endovasc Surg.* 2006;31:493–499.
9. Mutirangura P, Ruangsetakit C, Wongwanit C, et al. Pedal bypass with deep venous arterialization: the therapeutic option in critical limb ischemia and unreconstructable distal arteries. *Vascular.* 2011;19:313–319.
10. Ruangsetakit C, Chinsakchai K, Mahawongkajit P, et al. Transcutaneous oxygen tension: a useful predictor of ulcer healing in critical limb ischaemia. *J Wound Care.* 2010;19:202–206.