

A clinical comparative study of dexmedetomidine as an adjuvant to 2% plain lignocaine and 2% lignocaine with 1:200,000 adrenaline as local anesthetic agents for surgical removal of impacted mandibular third molars

ABSTRACT

Introduction: Dexmedetomidine is a selective alpha-2 adrenoceptor agonist. It is conventionally used as a sedative in the intensive care unit. However, recently, the application of dexmedetomidine as an adjuvant to a local anesthetic agent has been studied. The present study intends to evaluate the effectiveness of dexmedetomidine as an adjuvant to 2% plain lignocaine for surgical removal of impacted mandibular third molar and to compare the efficacy of dexmedetomidine with 2% plain lignocaine with 2% lignocaine and 1:200000 adrenaline.

Materials and Methods: A total of 80 patients who required surgical removal of impacted mandibular third molar extraction were included in the study. Patients were randomly divided into two groups using a computer-generated table. Patients in the study group received 2% plain lignocaine with 1 mcg/ml dexmedetomidine. Patients in the control group received 2% lignocaine with 1:200000 adrenaline. The parameters evaluated were onset and duration of action, pulse rate, blood pressure, oxygen saturation, and blood loss.

Results: Onset of action was faster and the duration of action was longer when dexmedetomidine was used with lignocaine as a local anesthetic agent. The vital parameters in both the groups were stable. Bleeding at the surgical site was less in the dexmedetomidine group.

Conclusion: The study concluded that the combination of dexmedetomidine with lignocaine enhances the local anesthetic potency of lignocaine when injected for nerve blocks.

Keywords: Dexmedetomidine, impacted molar, lignocaine, local anesthesia, nerve block

INTRODUCTION

Pain is defined as “An unpleasant emotional experience usually initiated by noxious stimulus and transmitted over a specialized neural network to the central nervous system.”^[1] The invention of local anesthesia has made the oral minor surgical procedure to be accomplished successfully with no pain, but all surgical procedures whether minor or major are invariably associated with stress, anxiety, and minimal–moderate pain or discomfort.^[2–4]

Currently used local anesthetic agents are lidocaine, bupivacaine, tetracaine, benzocaine, and articaine etc.^[5] These local anesthetic agents have been used for surface anesthesia, spinal anesthesia, infiltration anesthesia, and

conduction blocks. In the field of anesthesia, there has always been a continuous search for newer local anesthetic

**SHUBHADA HARISHCHANDRA NALAWADE,
KUMAR NILESH, C. D. MOUNESH KUMAR,
PRASHANT A PUNDE, PANKAJ B PATIL**

Department of Oral and Maxillofacial Surgery, School of Dental Sciences, Karad, Maharashtra, India


Address for correspondence: Dr. Kumar Nilesh, Department of Oral and Maxillofacial Surgery, School of Dental Sciences, Kimsdu, Karad, Maharashtra, India. E-mail: drkumarnilesh@yahoo.com

Received: 24 January 2020, **Revised:** 08 May 2020, **Accepted:** 19 June 2020, **Published:** 15 July 2021

This is an open access journal, and articles are distributed under the terms of the Creative Commons Attribution-NonCommercial-ShareAlike 4.0 License, which allows others to remix, tweak, and build upon the work non-commercially, as long as appropriate credit is given and the new creations are licensed under the identical terms.

For reprints contact: WKHLRPMedknow_reprints@wolterskluwer.com

How to cite this article: Nalawade SH, Nilesh K, Kumar CD, Punde PA, Patil PB. A clinical comparative study of dexmedetomidine as an adjuvant to 2% plain lignocaine and 2% lignocaine with 1:200,000 adrenaline as local anesthetic agents for surgical removal of impacted mandibular third molars. *Natl J Maxillofac Surg* 2021;12:255-61.

Access this article online	
Website: www.njms.in	Quick Response Code 
DOI: 10.4103/njms.NJMS_7_20	

agents and adjuvants to improve efficacy, potency, and better handling properties.

Dexmedetomidine is an imidazole compound, which is pharmacologically active dextro-isomer of medetomidine that shows specific and selective α_2 -adrenoceptor agonism.^[6] These selective receptors are present in the brain and spinal cords. The mechanism of action of dexmedetomidine is unique and differs from currently used sedative agents. It binds to the alpha 2 receptor and sends a negative feedback to synaptic vesicles. This inhibits the release of nor-epinephrine, causing blockade of transmission of pain stimulus. Postsynaptic activation of α_2 adrenoceptors in the central nervous system inhibits sympathetic activity causing decrease blood pressure (BP) and heart rate. When these effects are combined, they can produce analgesia, sedation, and anxiolysis.^[7] It is also known to cause hypotension and bradycardia.

Dexmedetomidine is used intravenously as a sedative in intensive care unit and for procedural sedation. Attention has recently been paid to dexmedetomidine as a possible additive to local anesthesia.^[2,6] The addition of dexmedetomidine to local anesthetics has been carried out for spinal nerve blocks. Enhancing the effect of dexmedetomidine on local anesthetic action has been demonstrated including speeding up the onset of action and extending the duration of local anesthesia, reducing intraoperative bleeding, and providing a better surgeon's satisfaction score.^[2,4,6,8-11]

The application of dexmedetomidine as an adjuvant to local anesthesia in dental nerve blocks has been sparingly documented in the English literature.^[12-14] This study was undertaken to evaluate the effect of combination of dexmedetomidine with plain lignocaine injected for the inferior alveolar nerve and long buccal nerve block in patients undergoing surgical removal of impacted mandibular third molar and to compare it with 2% lignocaine with 1:200000 adrenaline.

MATERIALS AND METHODS

The present study was undertaken in the Department of Oral and Maxillofacial Surgery, after the due approval of the Institutional Ethical Committee (KIMSDU/IEC/02/2018: Protocol Number: 0253/2018–2019: Date: March 23, 2018). The sample size was calculated using G* Power software (version 3.1.9.7). There were two groups in the study. Assuming the interaction between groups and within the group, effect size of systolic BP at 0.1, the level

of significance at 5%, power at 90%, data follow sphericity assumption (non-sphericity correction taken as 1), and at the high positive correlation between the repeated measures, the sample size was obtained as 36 subjects per group. Considering possible dropouts (due to reasons like anxious or uncooperative patient or an event of syncope during the procedure), a total of 40 patients were included in each group.

The randomized prospective study was conducted in 80 patients in the age group of 18–35 years, requiring surgical removal of mesioangularly impacted mandibular third molar (according to the winter's classification). Patients were divided into two groups using a computer-generated table (free random number generator) with 40 patients in each group. After explaining the study protocol, written consent was obtained from patients. Patients with a known history of an allergy or hypersensitivity to lignocaine or dexmedetomidine, patients on beta-blockers, patients having dental phobia or fear, and pregnant or lactating mothers were not included in the study.

Orthopantomograph (Carestream, Health India Pvt. Ltd) was taken for the evaluation of position and classification of impacted mandibular third molar in the bone. Patients in the study group received 2% plain lignocaine with 1 mcg/ml dexmedetomidine. Patients in the control group received 2% lignocaine with 1:200000 adrenaline. Surgical removal of the mandibular third molar was done by injecting classical inferior alveolar nerve block, long buccal nerve block, and local infiltration (in the buccal vestibule in the third molar region).

Blinding of the procedure was done. The person who gave the block and did the procedure was aware of the drug and the block. A different person prepared the anesthetic solution (lidocaine with or without dexmedetomidine), and a third person, who was not aware of the block and its preparation, assessed and recorded the variables.

The following vitals were assessed preoperatively and then every 20 min during the surgery till 120 min: pulse rate (measured manually), noninvasive BP (measured using sphygmomanometer; diamond BP apparatus 112 Aug. 11 18090), and peripheral saturation of oxygen (SpO₂) (Comet Plus, Skanray Healthcare Pvt. Ltd., India).

All patients were evaluated for the following:

1. The time of onset of anesthesia was measured from the point at which the needle was removed till the patient felt no pain on probing (probing with stainless steel blunt

probe on buccal and lingual distal papilla of the second molar)

- The duration of anesthesia was measured from the time of onset of subjective symptoms to complete loss of the same (which was confirmed by an objective test of probing)
- Intraoperative bleeding assessment was done using the gravimetric method. Weighing of unused swabs before surgery was done using a digital weighing spoon scale. The swabs, which were soaked in blood, were re-weighed immediately after surgery before discarding them from the operative field. The difference between the weight (measured in gram) of the two was calculated as blood loss.

Surgical procedure

All treatments were performed on an outpatient basis. The surgical removal of the impacted tooth was carried as per the routine protocol by the same surgeon. The following standard steps were used in both the groups. Cleaning of the surgical site was done with 5% povidone-iodine solution. In the study group, local anesthesia was achieved by injecting 2% lignocaine with 1 mcg/ml dexmedetomidine. The drug was prepared by the addition of 1 mcg of dexmedetomidine to 1 ml of 2% lignocaine using an insulin syringe. In the control group, local anesthesia was attained by injecting 2% lignocaine with 1:200000 adrenaline. 1.5 ml the anesthetic solution was used for inferior alveolar nerve and lingual nerve block, 0.5 ml for long buccal block, and 0.5 ml for local infiltration in the buccal vestibule in the third molar region in both the groups. Classic ward incision was placed, full-thickness mucoperiosteal flap was raised, buccal guttering was done, and mesial purchase point was created. Elevation of the tooth and subsequent extraction of the tooth were done with elevator and third molar forceps. Debridement was done, followed by irrigation of the socket with 5% povidone-iodine and normal saline solution. Primary closure was attained by interrupted suturing using 3-0 black silk suture material.

None of the participants in both the groups reported any discomfort, anxiety, syncope, adverse reaction, or abnormal cardiovascular event during the procedure. Routine postoperative instructions were given to patients in both the groups. Postoperative analgesics (tablet enzoflam) and antibiotics (capsule amox 500) were prescribed to patients in both the groups for 3 days.

RESULTS

A total of 80 patients with mesioangular impacted mandibular third molar were enrolled in the study. A total number of

females and males in the control group were 19 and 21, respectively. The study group included 18 females and 22 males. The average age of the patients in control group was 27.43 years, and in the study group, it was 25.85 years. There was no statistically significant difference in the age of patients between the two groups ($P = 0.734$).

Parameters evaluated

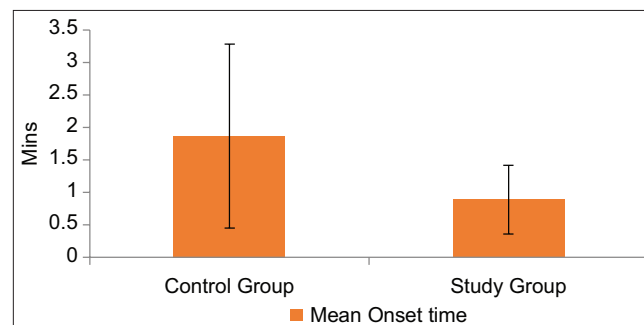
Time of onset of anesthesia [Graph 1]: The mean time of onset of anesthesia in the control group was 1.86 min as compared to 0.89 min in the study group. The difference between mean onset time among the control group and study groups was 0.97450, which was statistically significant ($P < 0.001$).

Duration of action [Graph 2]: The mean duration of action of anesthesia in the control group was 76.7107 min, as compared to 98.475 min in the study group. The difference between mean onset time among the control group and study group was 21.76450, which was statistically significant with $P < 0.001$.

Pulse rate [Graph 3]: The mean pulse rate in the study group at 60 min, 80 min, and at 100 min was 77.13, 76.93, and 77.25, respectively, and in the control group, it was 79.1, 79.38, and 78.83, respectively. The mean difference of pulse rate in both the groups at these time intervals was statistically significant, with the value of $P = 0.380, 0.270, \text{ and } 0.452$, respectively.

BP [Graph 4]: The mean systolic BP in the study group at 20 min, 40 min, 60 min, 80 min, and at 100 min was 120.9, 119.62, 118, and 120, respectively, and in the control group, it was 134.13, 133.5, 133, 129, and 129.62, respectively. The mean difference of systolic BP in both the group at all intervals except at preoperative, 0 min, and 120 min was statistically significant with $P < 0.001$.

Diastolic BP [Graph 5]: The mean diastolic BP in the study group at 20 min, 40 min, 60 min, 80 min, and at 100 min was 80.75, 79.5, 81.25, 80, and 80.5, respectively, and in the control group, it was 82.25, 82.77, 83.5, 82.35, and 81.15,



Graph 1: Comparison of the mean onset time between the two groups

respectively. The mean difference of diastolic BP in both the groups at 20 min, 40 min, 60 min, 80 min, and at 100 min intervals was statistically significant with $P < 0.001$ except at preoperative, 0 min, and 120 min.

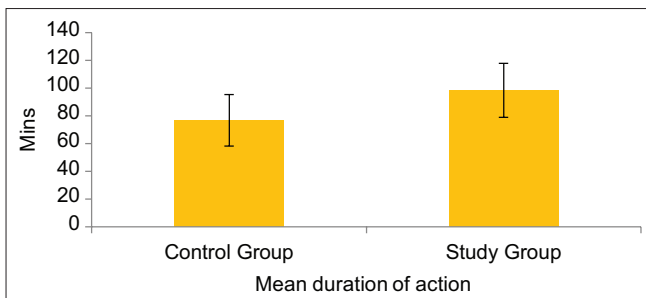
Oxygen saturation [Graph 6]: The mean oxygen saturation in the study group at 20 min, 40 min, 60 min, and 80 min was 98.57, 98.8, 99.02, and 98.47, respectively, and in the control group, it was 97.25, 97.4, 97.62, and 97.67, respectively. The mean difference of oxygen saturation in both the groups at these time intervals was statistically significant with $P < 0.001$.

Intraoperative bleeding assessment [Graph 7]: The mean total blood loss among the control group was 6.9567 g and study

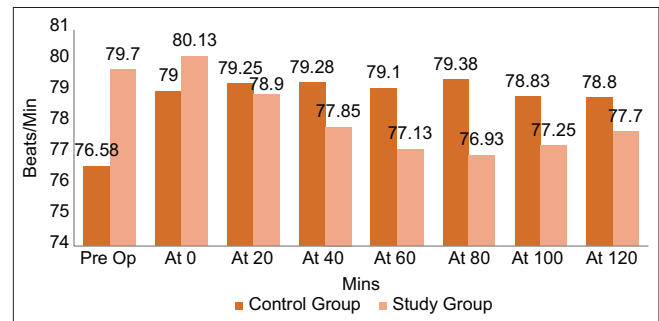
group was 5.163 g. The mean difference of total blood loss between the control group and study group was $- 1.794$ g with the value of $P = 0.01$ which was statistically significant.

DISCUSSION

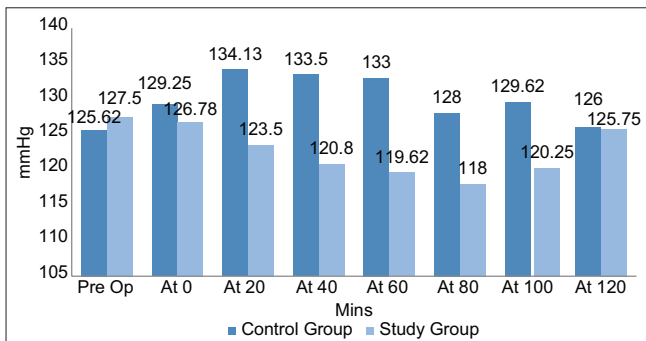
The invention of local anesthesia has made it possible to carry minor oral surgical procedures with no or little pain. The most commonly used local anesthetic agent in dentistry is lignocaine. Lignocaine is often combined with other additives to increase its potency and duration of action and reduces toxicity. The most common additive is adrenaline which increases the duration of action and reduces toxicity. However, the number of other adjuvants has also been reportedly added used with lignocaine. These



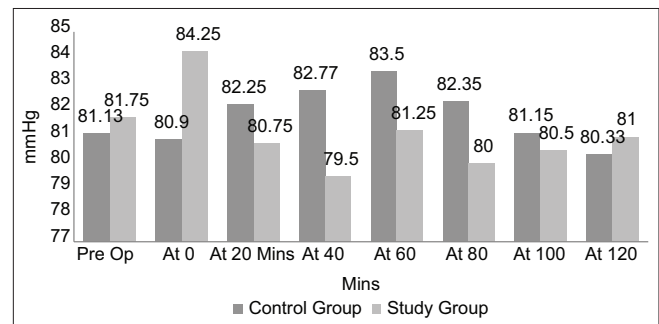
Graph 2: Comparison of the mean duration of action between the two groups



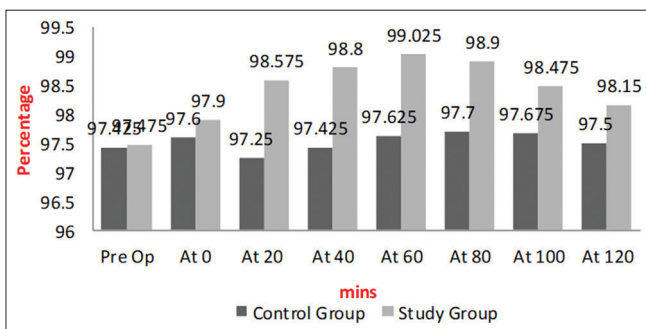
Graph 3: Comparison of pulse pressure between the two groups at various intervals of time (preoperative, at 0, 20, 40, 60, 80, 100, and 120)



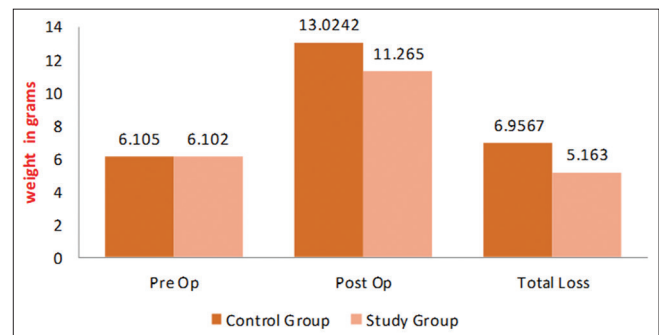
Graph 4: Comparison of systolic pressure between the two groups at various intervals of time (preoperative, at 0, 20, 40, 60, 80, 100, and 120)



Graph 5: Comparison of diastolic pressure between the two groups at various intervals of time (preoperative, at 0, 20, 40, 60, 80, 100, and 120)



Graph 6: Comparison of SpO₂ (%) between the two groups at various intervals of time (preoperative, at 0, 20, 40, 60, 80, 100, and 120)



Graph 7: Comparison of bleeding between the two groups at various intervals of time (preoperative, postoperative, and total loss)

include both nonopioids such as epinephrine, clonidine, nonsteroidal anti-inflammatory drugs, magnesium, and sodium bicarbonate and opioids such as fentanyl, sufentanil, and morphine.^[2]

Attention has recently been paid to dexmedetomidine as a possible additive for local anesthesia. Dexmedetomidine is an imidazole compound, which is pharmacologically active dextro-isomer of medetomidine that shows specific and selective α_2 -adrenoceptor agonism. It is believed to produce analgesia, sedation, and anxiolysis.^[7]

Brummett *et al.*^[10] first studied the action of perineural dexmedetomidine on the duration of analgesia after the application of thermal stimulus and compared it with systemic control in a rat sciatic nerve block. Dexmedetomidine was seen to increase the duration of analgesia in the studied group. In another animal study conducted by Brummett *et al.*,^[15] there was prolongation of duration of action when dexmedetomidine was added to ropivacaine for sciatic nerve block. The sensory and motor blockade was enhanced when dexmedetomidine was combined with bupivacaine for sciatic nerve blocks in rats.^[3] Ouchi *et al.*^[16] reported that dexmedetomidine (2.5 ml/L) improved the effect of local anesthesia, similar to adrenaline (1:80000) in rats. Marhofer *et al.*^[17] noticed that dexmedetomidine 20 g given perineurally with ropivacaine for ultrasound-guided ulnar nerve block prolonged the duration of action and increased the speed of onset.

Esmaoglu A *et al.*^[18] in 2013 studied the effects of dexmedetomidine when combined with levobupivacaine for a spinal block, in humans. They concluded that when dexmedetomidine was added to levobupivacaine for spinal anesthesia, it shortens sensory and motor block onset time and prolongs block duration without any significant adverse effects. Dexmedetomidine for posterior tibial nerve sensory blockade with ropivacaine was studied by Rancourt *et al.*^[19] in 2012, and they concluded that dexmedetomidine when combined with local anesthesia (ropivacaine) prolongs the duration of action with similar onset of action. However, in their study they noticed a decreased in systolic and diastolic pressure change up to 30% in dexmedetomidine group when compared to the baseline value. Esmaoglu *et al.*^[11] in 2014 studied the onset and duration of action in axillary brachial plexus block when combined with levobupivacaine and found short onset time with prolonged duration of action when compared with levobupivacaine alone. Swami *et al.*^[20] in 2012 combined dexmedetomidine with bupivacaine and compared it with clonidine for supraclavicular brachial plexus nerve block. There was an increase in the duration

of action for both sensory and motor nerve blockade. The time for rescue of analgesia was prolonged with enhanced quality of block as compared to clonidine. It has been demonstrated that locally injected dexmedetomidine has an anti-inflammatory effect and induces vasoconstriction at the injected site.^[21,22] These findings suggest that dexmedetomidine can be an effective additive to a local anesthetic.

Very few studies on dexmedetomidine have been reported in oral and maxillofacial surgery. Mandal *et al.*^[14] studied the effectiveness of adding dexmedetomidine to 2% lignocaine with adrenaline in patients with a jaw fracture. They concluded that dexmedetomidine when used as local infiltration at the site of trauma significantly reduced bleeding from the wound site. It also reduced perioperative fentanyl and propofol consumption and subsequently ensured earlier discharge from the postanesthetic care unit, better surgeon's satisfaction score with better hemodynamic control, and lesser side effects. Khandaitkar *et al.*^[12] in 2016 studied the efficacy of dexmedetomidine as an adjuvant to lidocaine in the infraorbital nerve block. The onset of anesthesia, duration of action, BP, oxygen saturation, and heart rate were assessed. The addition of 7 mg/L dexmedetomidine to lidocaine perineurally speeds up the onset of action and prolongs the duration of anesthesia. Differences in BP, oxygen saturation, and heart rate measured at different intervals were not significant. Kumar *et al.*,^[13] in 2016, conducted a pilot study comparing clinical efficacy and potency of dexmedetomidine combination with lignocaine. Patients undergoing orthodontic extraction were locally infiltrated with 2% lignocaine plus dexmedetomidine 1 μ /ml and 2% lignocaine plus adrenaline in 1:200,000 dilution at two different appointments. The onset of action, duration of action, and pain threshold were assessed. The onset of action in dexmedetomidine group was found to be faster, with longer duration of action and without any systemic effects when injected locally into the oral mucosa. The result of this study was consistent with the findings of other authors. The addition of dexmedetomidine to 2% plain lignocaine for the mandibular nerve block significantly prolonged the duration of action of block and shortened the onset of action.

The vital parameters evaluated in the study remained within normal limits in patients receiving dexmedetomidine. Khandaitkar *et al.*^[12] stated that when 7 mg/L of dexmedetomidine was given perineurally or systemically, it did not adversely affect heart rate, BP, and oxygen saturation. However, in this study, pulse rate measured at 60 min, 80 min, and at 100 min between the two groups

was statistically significant, with a study group showing a lower pulse rate. BP measured at 20 min, 60 min, 80 min, and 100 min time intervals between the two groups was statistically significant, with a study group showing lower BP. Oxygen saturation measured at 20 min, 40 min, 60 min, and 80 min between both the groups was statistically significant, with a study group showing higher oxygen saturation. This can be possibly be explained by the fact that dexmedetomidine has analgesic and anxiolytic effects which reduces the stress and eliminate pain, which, in turn, can help to improve the peripheral oxygen saturation. Patients whose heart rate and BP did not vary by >20% either way from baseline (measured preoperatively) were considered stable. The vital parameters recorded did not vary by >20% either way from baseline at all the mentioned intervals in both the groups and was considered stable. In this study, the intraoperative bleeding was assessed using the gravimetric method. The mean total blood loss between the control group and study group was -1.794 with the value of $P = 0.01$, which was statistically significant. This result was in accordance with the study done by Mandal *et al.*^[14]

CONCLUSION

Based on the findings of the present study, we conclude that the addition of dexmedetomidine shortens the onset of action and prolongs the duration of anesthesia of lignocaine as compared to lignocaine with 1:2,00,000 adrenaline. Although variation in pulse rate, BP, and oxygen saturation was seen between the two groups at various intervals, this was considered stable (within 20% of baseline value). Better hemostasis was achieved when dexmedetomidine was used as an adjuvant to the local anesthetic agent as compared to adrenaline and lignocaine.

Dexmedetomidine when used in combination with lignocaine enhances the local anesthetic potency with acceptable systemic effect when used for intraoral nerve blocks.

Financial support and sponsorship

Nil.

Conflicts of interest

There are no conflicts of interest.

REFERENCES

- Bennett CR. Monheim's Local Anesthesia and Pain Control in Dental Practice. 7th ed.. St. Louis, MO: C.V. Mosby; 1984.
- Calasans-Maia JA, Zapata-Sudo G, Sudo RT. Dexmedetomidine prolongs spinal anaesthesia induced by levobupivacaine 0.5% in guinea-pigs. *J Pharm Pharmacol* 2005;57:1415-20.
- Brummett CM, Norat MA, Palmisano JM, Lydic R. Perineural administration of dexmedetomidine in combination with bupivacaine enhances sensory and motor blockade in sciatic nerve block without inducing neurotoxicity in rat. *Anesthesiology* 2008;109:502-11.
- Yoshitomi T, Kohjitani A, Maeda S, Higuchi H, Shimada M, Miyawaki T. Dexmedetomidine enhances the local anesthetic action of lidocaine via an α -2A adrenoceptor. *Anesth Analg* 2008;107:96-101.
- Malamed SF. Handbook of Local Anesthesia. 6th ed.. St. Louis: Elsevier; 2013. p. 2-24.
- Gertler R, Brown HC, Mitchell DH, Silvius EN. Dexmedetomidine: A novel sedative-analgesic agent. *Proc (Bayl Univ Med Cent)* 2001;14:13-21.
- Kaur M, Singh PM. Current role of dexmedetomidine in clinical anesthesia and intensive care. *Anesth Essays Res* 2011;5:128-33.
- Kanazi GE, Aouad MT, Jabbour-Khoury SI, Al Jassar MD, Alameddine MM, Al-Yaman R, *et al.* Effect of low-dose dexmedetomidine or clonidine on the characteristics of bupivacaine spinal block. *Acta Anaesthesiol Scand* 2006;50:222-7.
- Saadawy I, Boker A, Elshahawy MA, Almazrooa A, Melibary S, Abdellatif AA, *et al.* Effect of dexmedetomidine on the characteristics of bupivacaine in a caudal block in pediatrics. *Acta Anaesthesiol Scand* 2009;53:251-6.
- Brummett CM, Padda AK, Amodeo FS, Welch KB, Lydic R. Perineural dexmedetomidine added to ropivacaine causes a dose-dependent increase in the duration of thermal antinociception in sciatic nerve block in rat. *Anesthesiology* 2009;111:1111-9.
- Esmoğlu A, Yegenoglu F, Akin A, Turk CY. Dexmedetomidine added to levobupivacaine prolongs axillary brachial plexus block. *Anesth Analg* 2010;111:1548-51.
- Khandaitkar S, Kolte V, Sheno SR, Budhraj N. A clinical study to determine the efficacy of 7 ppm dexmedetomidine as an adjuvant to 2% lignocaine in infraorbital nerve block. *Br J Oral Maxillofac Surg* 2016;54:997-1000.
- Kumar P, Thepra M, Bhagol A, Priya K, Singh V. The newer aspect of dexmedetomidine use in dentistry: As an additive to local anesthesia, initial experience, and review of literature. *Natl J Maxillofac Surg* 2016;7:76-9.
- Mandal D, Das A, Chhale S, Halder PS, Paul J, RoyBasunia S, *et al.* The effect of dexmedetomidine added to preemptive (2% lignocaine with adrenaline) infiltration on intraoperative hemodynamics and postoperative pain after ambulatory maxillofacial surgeries under general anesthesia. *Anesth Essays Res* 2016;10:324-31.
- Brummett CM, Hong EK, Janda AM, Amodeo FS, Lydic R. Perineural dexmedetomidine added to ropivacaine for sciatic nerve block in rats prolongs the duration of analgesia by blocking the hyperpolarization-activated cation current. *Anesthesiology* 2011;115:836-43.
- Ouchi K, Koga Y, Nakao S, Sugiyama K. Dexmedetomidine dose-dependently enhances local anesthetic action of lidocaine. *J Oral Maxillofac Surg* 2014;72:474-80.
- Marhofer D, Kettner SC, Marhofer P, Pils S, Weber M, Zeitlinger M. Dexmedetomidine as an adjuvant to ropivacaine prolongs peripheral nerve block: A volunteer study. *Br J Anaesth* 2013;110:438-42.
- Esmoğlu A, Türk S, Bayram A, Akin A, Uğur F, Ulgey A. The effects of dexmedetomidine added to spinal levobupivacaine for transurethral endoscopic surgery. *Balkan Med J* 2013;30:186-90.
- Rancourt MP, Albert NT, Côté M, Létourneau DR, Bernard PM. Posterior tibial nerve sensory blockade duration prolonged by adding dexmedetomidine to ropivacaine. *Anesth Analg* 2012;115:958-62.
- Swami SS, Keniya VM, Ladi SD, Rao R. Comparison of dexmedetomidine

- and clonidine (α_2 agonist drugs) as an adjuvant to local anaesthesia in supraclavicular brachial plexus block: A randomised double-blind prospective study. *Indian J Anaesth* 2012;56:243-9.
21. Sulaiman S, Karthekeyan RB, Vakamudi M, Sundar AS, Ravullapalli H, Gandham R. The effects of dexmedetomidine on attenuation of stress response to endotracheal intubation in patients undergoing elective off-pump coronary artery bypass grafting. *Ann Card Anaesth* 2012;15:39-43.
22. Kunisawa T, Ueno M, Kurosawa A, Nagashima M, Hayashi D, Sasakawa T, *et al.* Dexmedetomidine can stabilize hemodynamics and spare anesthetics before cardiopulmonary bypass. *J Anesth* 2011;25:818-22.