

# Paget's Disease of Bone: An Entity Still Exists in India

Kripa Elizabeth Cherian, Nitin Kapoor, Sahana Shetty, Felix K. Jebasingh, Hesarghatta Shyamasunder Asha, Julie Hephzibah<sup>1</sup>, Anne Jennifer Prabhu<sup>2</sup>, Simon Rajaratnam, Nihal Thomas, Thomas Vizhalil Paul

Departments of Endocrinology, <sup>1</sup>Nuclear Medicine and <sup>2</sup>Pathology, Christian Medical College, Vellore, Tamil Nadu, India

## Abstract

**Background:** Paget's disease of bone (PDB) is uncommonly reported from India. We attempted to study the clinical and imaging features and management of participants who presented with PDB. **Materials and Methods:** In this retrospective study, clinical and imaging profile, biochemistry, and treatment outcomes of participants with PDB ( $n = 48$ ) were obtained. **Results:** The mean age was  $60 \pm 11.3$  years and 35% were women. Twenty percent were asymptomatic. Many (87%) had polyostotic involvement. Sixty percent ( $n = 29$ ) underwent treatment with zoledronic acid and rest with oral bisphosphonates, and all achieved remission. **Conclusion:** Most of the pagetic participants had polyostotic disease and one-fifth were asymptomatic. All participants had disease remission following treatment.

**Keywords:** Bisphosphonates, India, Paget's disease of bone, polyostotic disease, zoledronic acid

## INTRODUCTION

Paget's disease of bone (PDB) is characterized by abnormal bone remodeling with exaggerated osteoclastic bone resorption followed by increased osteoblastic activity, leading to new bone formation.<sup>[1]</sup> The increased bone turnover results in the laying down of bone that is expanded, less compact, more vascular, fragile, and more susceptible to fractures. Although disorganized bone remodeling is present throughout the skeleton, it is the axial skeleton that is preferentially involved, with the pelvis, lumbar spine, skull, and femur being affected more commonly than the other sites.

The prevalence of Paget's disease has been reported to be high in individuals predominantly of a European descent<sup>[2]</sup> in contrast to Africans, Asians, and especially people of the Indian subcontinent. Paget's disease may be asymptomatic or present with bone pains, deformities, fractures, arthropathy, hearing loss, and other nerve compression syndromes. There is a male preponderance, and the disease may be mono-ostotic or polyostotic and occurs more frequently in the elderly.<sup>[3]</sup> The complications reported in untreated cases of Paget's disease include congestive cardiac failure, sarcomatous transformation, and rarely hydrocephalus due to obstruction of the aqueduct.<sup>[4]</sup> The diagnosis of Paget's disease relies on the use of biochemical parameters such as alkaline phosphatase (ALP) which is usually elevated, X-rays of involved regions, as well as a <sup>m</sup>Tc<sup>99</sup>

methylene diphosphonate (MDP) bone scan which shows an increased tracer uptake in the affected sites. Both oral and intravenous bisphosphonates have been used for treatment and reported to cause significant disease regression. There are no studies from India in the present decade (2007–2016) other than few case reports. The limited literature available from India has documented the use of oral bisphosphonates as the primary modality of treatment, and asymptomatic presentation was seen in <10% of cases.<sup>[5-7]</sup> We attempted to study the clinical and imaging features and management of Paget's disease over the last one decade.

## MATERIALS AND METHODS

### Patients

This retrospective study analyzed the clinical features, biochemical, and radiological profile, and treatment outcomes of 48 patients diagnosed to have Paget's disease from 2007 to 2016 at a tertiary care center in southern India. A diagnosis of PDB had been made based on clinical features, the presence of elevated serum ALP, characteristic findings of sclerotic

**Address for correspondence:** Prof. Thomas Vizhalil Paul, Department of Endocrinology, Christian Medical College, Vellore - 632 004, Tamil Nadu, India.  
E-mail: thomasvpaul@yahoo.com

### Access this article online

#### Quick Response Code:



**Website:**  
www.ijem.in

**DOI:**  
10.4103/ijem.IJEM\_19\_18

This is an open access journal, and articles are distributed under the terms of the Creative Commons Attribution-NonCommercial-ShareAlike 4.0 License, which allows others to remix, tweak, and build upon the work non-commercially, as long as appropriate credit is given and the new creations are licensed under the identical terms.

**For reprints contact:** reprints@medknow.com

**How to cite this article:** Cherian KE, Kapoor N, Shetty S, Jebasingh FK, Asha HS, Hephzibah J, *et al.* Paget's disease of bone: An entity still exists in India. Indian J Endocr Metab 2018;22:368-72.

and mixed sclerotic lytic lesions on plain X-rays, and bone scintigraphic images showing classical features of increased uptake of tracer in involved sites.

## Methods

The details of patients were obtained through the Computerized Hospital Information and Processing System, which includes a clinical workstation (CWS) and a picture archiving and communications systems (PACS). The access to CWS is authenticated by a password. The particulars of the patient including demography and clinical profile, biochemistry, treatment, and outcomes were obtained. The details regarding symptoms and signs of the disease such as bone pains, fractures, hearing loss, muscle pain, back pain, deformity, and neurological deficit were obtained. Blood biochemical data were collected which included ALP (N: 40–125 IU/L), albumin-corrected calcium (N: 8.3–10.4 mg/dL), phosphate (N: 2.5–5 mg/dL), 25-hydroxy Vitamin D (Vitamin D) (N: 30–75 ng/mL), and creatinine (N: 0.6–1.2 mg/dL). Information regarding skeletal X-rays and <sup>99m</sup>Tc MDP bone scintigraphy images were obtained through the PACS. The details of therapeutic modality used such as oral or intravenous bisphosphonates were noted, and on follow-up, the response to treatment and improvement in clinical features were studied as well. Remission was the rate of therapeutic response at 1 year and defined either as a normalization of ALP levels or a reduction of at least 75% in the total ALP excess. Disease relapse was considered when clinical symptoms such as bone pain worsened or blood levels of ALP increased or both. This study was approved by Institutional Review Board.

## RESULTS

A total of 48 patients were diagnosed to have Paget's disease during the study. The mean age at presentation was 60 ± 11.3 years, with about one-third of them being females (male:female – 31 [65%]:17 [35%]). The study group included a pair of siblings with Paget's disease.

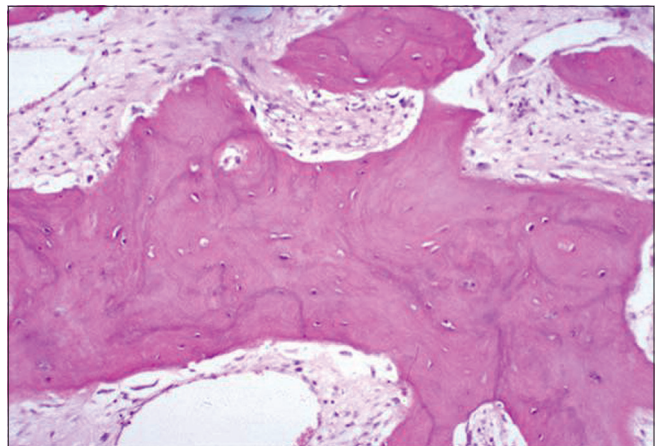
The mean duration between symptom onset and diagnosis of the disease was 24 ± 17.6 months. Ten participants (21%) were asymptomatic at diagnosis. The most common symptoms [Table 1] were low backache (56%) and bone pain (44.4%). A participant who presented with femoral neck fracture and an elevated ALP (612 U/L) was evaluated for suspected metastatic disease, but biopsy revealed Paget's disease [Figure 1].

The details regarding skeletal survey and bone scintigraphy [Table 2] were available in all participants. The disease was polyostotic in 42 participants (87%). The most commonly involved sites were noted to be the pelvis (73.3%) and spine (62.2%). All the participants with skull lesions (*n* = 14) also showed involvement of pelvis on radiographs. Radiograph of a participant with both skull and pelvis involvement is shown in Figure 2.

The biochemical profile of the participants is shown in Table 3. The mean standard deviation (SD) level of serum ALP was

**Table 1: Clinical features at presentation**

Symptoms and signs	Number of patients (%)
Bone pain	20 (44.4)
Low back pain	25 (55.6)
Skeletal deformity	4 (8.9)
Pathological fracture (femoral neck)	1 (2.2)
Neurological claudication	2 (4.4)
Head enlargement	2 (4.4)
Deafness	6 (13.3)
Toothache	1 (2.2)
Ptosis	1 (2.2)
Asymptomatic	10 (21)



**Figure 1:** Biopsy from the femoral neck (H and E, ×200) showing features of Paget's disease in the form of thickened lamellar bone with prominent thickened lamellar bone with prominent irregular cement lines, resembling mosaic pattern with increased osteoclastic and osteoblastic activity and cytokeratin negativity

511.6 (215.2) U/L. The mean ALP level at last follow-up was 122.7 (47.9) U/L. The mean (SD) level of 25-hydroxy Vitamin D was 21.7 (9.5) ng/mL, and Vitamin D deficiency (<20 ng/mL) was present in 20 participants (42%). All participants received calcium and Vitamin D supplementation. Participants with Vitamin D deficiency had received treatment with therapeutic doses of cholecalciferol before treatment with bisphosphonates.

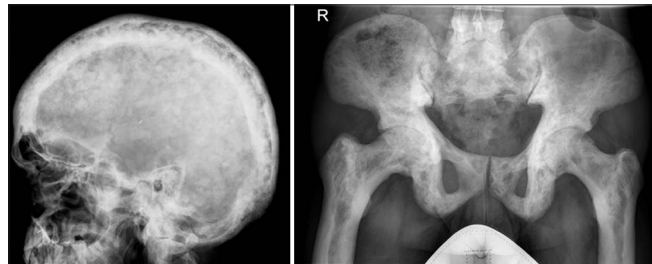About 60% (*n* = 29) of our patients received treatment with parenteral bisphosphonates (zoledronic acid 4 mg). Nineteen of our patients received oral bisphosphonates (risedronate [35 mg/day; *n* = 2] or alendronate [40 mg/day; *n* = 17]). In this study, 3 of 29 participants (10.3%) received more than one dose of yearly zoledronate (maximum 3 doses) to achieve clinical and biochemical remission and a regression of disease activity on bone scintigraphy. All three participants who received more than one dose of zoledronic acid had polyostotic disease with persistent symptoms and significantly high initial mean (SD) ALP level (801[297] IU/L versus 484[236] IU/L, *P* = 0.04) when compared to patients who did not require repeat treatment. One of them had significant worsening of pain on follow-up despite receiving zoledronic acid and nuclear scan confirmed increased tracer activity at many sites, when

compared to the previous scan. This participant improved clinically and bone scan also displayed marked regression after the second dose of zoledronate [Figure 3].

The mean (SD) duration of follow-up was 34 (20) months. Two patients were lost to follow-up. The mean (SD) time to remission was 11.1 (6.4) months. All participants responded to the treatment. Eighty-five percent of patients on zoledronic acid were in remission at the end of 1 year when compared to 72% of those on oral bisphosphonates ( $P=0.03$ ). The disease relapsed in four patients; all of them had been on alendronate. The relapse occurred following a reduction in dose of alendronate within 1 year. They were subsequently treated with a hike in the dose of alendronate ( $n=2$ ) or switching to zoledronic acid ( $n=2$ ) and all four achieved remission.

## DISCUSSION

Paget's disease is an uncommon metabolic bone disease in India, and in the present study, we sought to analyze the changing trends in its presentation and management over the past one decade. More than half of the study participants had presented in the seventh decade of life. Over one-third of the participants were women. Although the most commonly reported symptoms were low backache and bony pains, about one-fifth of our participants were asymptomatic at diagnosis. About 60% of our patients had received parenteral zoledronic acid and all our patients showed response to treatment.



**Figure 2:** X-ray skull and pelvis of a subject showing sclerotic and lytic lesions characteristic of Paget's disease

Although the occurrence of Paget's disease is more commonly described in the UK, recent studies have shown that case finding of Paget's disease is on a decline.<sup>[8]</sup> Paget's disease is not commonly reported from India. However, in a study of about 28,000 consecutive diabetic patients, the prevalence of Paget's disease was estimated to be 0.066%.<sup>[9]</sup> The apparent difference in susceptibility between different populations is attributed to genetic alterations that probably have a founder effect in Northwestern Europe, in addition to environmental influences. The proportion of women in this study was more than what was reported in the early Indian studies. This may be probably attributed to referral bias and recent improvements in health-seeking attitude of women. The diagnosis of this

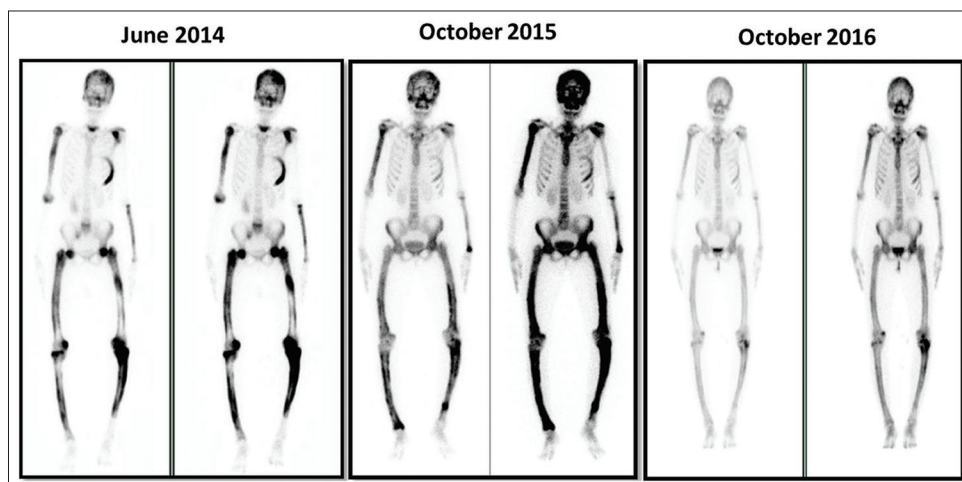
**Table 2: Skeletal sites involved on bone scintigraphy**

Site	Number of patients (%)
Pelvis	33 (73.3)
Spine	28 (62.2)
Skull	14 (31.1)
Femur	6 (13.3)
Humerus	13 (28.9)
Sternum	2 (4.4)
Sacrum	8 (17.8)
Tibia	13 (28.9)
Radius	1 (2.2)
Calcaneum	1 (2.2)

**Table 3: Biochemistry of the study subjects**

Biochemical	Mean $\pm$ SD ( $n=48$ )
Alkaline phosphatase (IU/L)	511.64 $\pm$ 215.29
Last follow-up alkaline phosphatase (IU/L)	122.74 $\pm$ 47.9
Calcium (mg/dL)	8.97 $\pm$ 0.34
Phosphorous (mg/dL)	3.57 $\pm$ 0.54
Creatinine (mg/dL)	0.94 $\pm$ 0.25
25-hydroxy Vitamin D (ng/mL)	21.74 $\pm$ 9.56
Albumin (g/dL)	4.19 $\pm$ 0.47

SD: Standard deviation



**Figure 3:** Serial bone scans of the subject showing initial worsening, then marked regression of the lesions following yearly zoledronic acid administration

condition requires a high index of suspicion. About 20% of the participants in the present study were asymptomatic and were identified on evaluation for other unrelated ailments. In a study by Wermers *et al.*, the prevalence of asymptomatic Paget's disease was about 40%.<sup>[10]</sup> This is also in contrast to earlier studies from India which quoted a prevalence of asymptomatic presentation to be less than 10%. This suggests that, nowadays more Indian participants are being routinely screened with a panel of investigations that include liver function tests in which an isolated elevation in ALP is further evaluated.

Familial Paget's disease has been reported in 15–20% and follows an autosomal dominant pattern of inheritance.<sup>[11]</sup> In our present study, we had a pair of siblings who presented with similar clinical features of macrocephaly, hearing loss, low backache, and biochemical investigations showing elevated ALP and increased uptake in multiple skeletal sites on radionuclide imaging of the bone.<sup>[12]</sup>

The most common clinical features at presentation were low backache and bone pain, and many of them had polyostotic disease. The skeletal sites involved were the pelvis, spine, and skull. Bones of the extremities were also involved, however, to a lesser extent. This is similar to the population-based study in which polyostotic disease was present in about 70%, and pelvis was the most commonly involved site.<sup>[10]</sup>

Hearing loss was seen in about 12% of participants and is a long-recognized complication of Paget's disease. Previously, various mechanisms were proposed to cause hearing loss and included loss of auditory hair and ganglion cells, stretching of the auditory nerve, and toxic cytokines.<sup>[13]</sup> Thereafter, studies done by Khetarpal and Schuknecht on the histological appearance of pagetic temporal bone have concluded that both conductive and sensory hearing loss are caused by changes in the bone density, mass, and form, resulting in the dampening of the motion mechanics of the middle and inner ears.<sup>[14]</sup>

Although X-rays show typical features of lysis and sclerosis, a radionuclide scan is more sensitive as it enables the identification of the extent of the disease and is also useful in asymptomatic individuals with Paget's disease.<sup>[4]</sup>

Majority of our patients were treated with parenteral zoledronic acid. There was a shift in management protocol, when compared to the previous study done at our center where many of them were treated with oral bisphosphonates.<sup>[7]</sup> About two-fifths of participants declined parenteral therapy and were thus initiated on oral bisphosphonates. A single dose of parenteral zoledronate is recommended, considering the fact that it is a potent enzyme inhibitor and is deposited in the bone.<sup>[4]</sup> However, we found in our study that one-tenth of them required more than one dose of zoledronate to achieve clinical and biochemical remission, as well as significant disease regression on bone radionuclide scan. These participants showed a polyostotic disease and a high ALP at initial presentation. Reid *et al.* has reported a relapse and second-dose administration of zoledronic acid

in 6 (4%) of 152 pagetic participants.<sup>[15]</sup> The relapse seen in four participants, who were on oral bisphosphonates, was consequent to a dose reduction in oral bisphosphonates; these patients had evidence of remission on optimizing treatment, either by instituting intravenous bisphosphonates or by increasing the dose of oral alendronate. In a study comparing zoledronic acid with risedronate for the treatment of Paget's disease, ALP levels normalized in 88.6% of patients in the zoledronic acid group and 57.9% of patients in the risedronate group ( $P < 0.001$ ) at the end of 6 months.<sup>[16]</sup> Serial measurement of ALP is recommended for monitoring disease remission or progression. An elevation in ALP is an early warning sign indicating disease relapse. Treatment should target serum ALP in the mid-reference range.<sup>[4]</sup>

Strength of this study included large number of participants with Paget's disease from a single center. Limitations of the study included its retrospective nature, and bone turnover markers and parathyroid hormone levels were not available in these participants.

## CONCLUSION

In the present study, about one-third of the participants were females, and most of the pagetic participants had polyostotic disease and 20% were asymptomatic. More than half of them received zoledronic acid, and all participants had disease remission with either parenteral or oral bisphosphonates.

## Financial support and sponsorship

Nil.

## Conflicts of interest

There are no conflicts of interest.

## REFERENCES

1. Ralston SH. Clinical practice. Paget's disease of bone. *N Engl J Med* 2013;368:644-50.
2. Griz L, Fontan D, Mesquita P, Lazaretti-Castro M, Borba VZ, Borges JL, *et al.* Diagnosis and management of paget's disease of bone. *Arq Bras Endocrinol Metabol* 2014;58:587-99.
3. Britton C, Walsh J. Paget disease of bone-an update. *Aust Fam Physician* 2012;41:100-3.
4. Singer FR, Bone HG 3<sup>rd</sup>, Hosking DJ, Lyles KW, Murad MH, Reid IR, *et al.* Paget's disease of bone: An endocrine society clinical practice guideline. *J Clin Endocrinol Metab* 2014;99:4408-22.
5. Bhadada S, Bhansali A, Unnikrishnan AG, Khadgawat R, Singh SK, Mithal A, *et al.* Does paget's disease exist in India?: A series of 21 patients. *J Assoc Physicians India* 2006;54:530-4.
6. Joshi SR, Ambhore S, Butala N, Patwardhan M, Kulkarni M, Pai B, *et al.* Paget's disease from Western India. *J Assoc Physicians India* 2006;54:535-8.
7. Anjali, Thomas N, Rajaratnam S, Shanthly N, Oommen R, Seshadri MS, *et al.* Paget's disease of bone: Experience from a centre in Southern India. *J Assoc Physicians India* 2006;54:525-9.
8. Cooper C, Schafheutle K, Dennison E, Kellingray S, Guyer P, Barker D, *et al.* The epidemiology of paget's disease in Britain: Is the prevalence decreasing? *J Bone Miner Res* 1999;14:192-7.
9. Palkar S, Mohan V. Paget's disease in diabetic subjects. *J Assoc Physicians India* 2006;54:585.
10. Wermers RA, Tiegs RD, Atkinson EJ, Achenbach SJ, Melton LJ 3<sup>rd</sup>. Morbidity and mortality associated with paget's disease of bone:

- A population-based study. *J Bone Miner Res* 2008;23:819-25.
11. Siris ES, Ottman R, Flaster E, Kelsey JL. Familial aggregation of paget's disease of bone. *J Bone Miner Res* 1991;6:495-500.
  12. Naik D, Asha HS, Mathews SS, Paul TV. Two siblings with paget's disease of bone. *BMJ Case Rep* 2014;2014:pii: bcr2013203219.
  13. Monsell EM. The mechanism of hearing loss in paget's disease of bone. *Laryngoscope* 2004;114:598-606.
  14. Khetarpal U, Schuknecht HF. In search of pathologic correlates for hearing loss and vertigo in paget's disease. A clinical and histopathologic study of 26 temporal bones. *Ann Otol Rhinol Laryngol Suppl* 1990;145:1-6.
  15. Reid IR, Brown JP, Levitt N, Román Ivorra JA, Bachiller-Corral J, Ross IL, *et al.* Re-treatment of relapsed paget's disease of bone with zoledronic acid: Results from an open-label study. *Bonekey Rep* 2013;2:442.
  16. Reid IR, Miller P, Lyles K, Fraser W, Brown JP, Saidi Y, *et al.* Comparison of a single infusion of zoledronic acid with risedronate for paget's disease. *N Engl J Med* 2005;353:898-908.