

3D-Customized Guiding Template for Posterior Fixation in Complex Atlantoaxial Instability—Preliminary Experiences of National Cheng Kung University Hospital

Yi-Yun Chen^{1,*}  Liang-Chun Chao^{1,*} Jing-Jing Fang² E-Jian Lee¹

¹Division of Neurosurgery, Department of Surgery, National Cheng Kung University Hospital, Tainan, Taiwan, R.O.C.

²Department of Mechanical Engineering, National Cheng Kung University, Tainan, Taiwan, R.O.C.

Address for correspondence E-Jian Lee, MD, PhD, Department of Surgery, National Cheng Kung University Hospital, No.138, Sheng Li Road, Tainan, Taiwan 704, R.O.C. (e-mail: ejian@mail.ncku.edu.tw).

J Neurol Surg Rep 2020;81:e20–e27.

Abstract

Objective Atlantoaxial fixation is technically demanding and challenging, especially in cases with anatomical abnormality. The purpose of this study is to report the effectiveness of the three-dimensional (3D)-customized guiding template for placement of C1 and C2 screws in cases with abnormalities.

Method Two patients with anatomical abnormality and one without were included. The preoperative computed tomography (CT) image was analyzed using our software. The entry point, trajectory, and depth of the screws were designed based on these images. Templates with screw guiding cylinders and cervical spine model were created. In operation, guiding templates were applied directly to the laminae. Drilling, tapping, and screwing were performed through the cylinders. To evaluate the accuracy, deviation of the screw axis from the preplanned trajectory was measured on postoperative CT. A classification system was taking to evaluate the pedicle screw insertion.

Results In complex cases, one of C2 screws has grade 2 deviation, and two has grade 1. There was no deviation in screws of C1. All patients achieved symptoms free after 6 months follow-up.

Conclusion Although 3D-printed template for atlantoaxial fixation still has limitation in complex cases, it has been proved usefulness and makes the most difficult and dangerous spinal posterior fixation easy to achieve.

Keywords

- ▶ atlantoaxial fixation
- ▶ guiding template
- ▶ C1–2 level
- ▶ cervical
- ▶ pedicle screw

Introduction

Atlantoaxial fixation with pedicle screws has been well documented as a good way to treat atlantoaxial instability. However, vertebral artery (VA) injury is the most serious complication while inserting screws into the pedicles of C1 and C2 with wrong directions. In complex cases, the entry

points of pedicle screws may be difficult to identify due to unusual atlantoaxial alignment. Variation of VA and narrow C2 pedicle are also the pitfall for screws insertion.^{1,2} Biplane conventional fluoroscopy guidance (C-arm) is limited in complex atlantoaxial instability due to poor image quality. Cone beam computed tomography (CT) with navigation (O-arm) guidance provides good precision but has disadvantages about long operation time, high-dose radiation exposure, and excessive cost.^{2–6}

* Yi-Yun Chen and Liang-Chun Chao contributed equally to this study.

A novel way to perform atlantoaxial posterior fixation with three-dimensional (3D)-printed guiding template has been developed since 2002 in hope to decrease the risk of VA injury and increase precision in pedicle screws placement.⁷ With the advance of 3D-printing technology, it becomes more available and affordable today. In recent years, many studies have proved guiding template for pedicle screw insertion has high accuracy and safety in lumbar and thoracic spine.^{8–11} In this study, we report our experience of performing atlantoaxial fixation in complex cervical deformity cases with 3D-customized guiding template.

Materials and Methods

Patient Inclusion

Patients with high risk of VA injury were identified and recruited after preoperative survey. The risk factors of VA injury include complex cervical deformity, narrow C2 pedicle, and VA path variation.⁸ The preoperative imaging surveys include cervical spine X-ray, CT angiography, and cervical spine magnetic resonance imaging. Informed consent was given after oral explanation. There were three patients enrolled from September 2017 to August 2018.

Model Design

Medical image processing software was developed with the basic functions of Digital Imaging and Communications in Medicine decoding and 3D anatomy reconstruction. A specific software was developed to reveal an optimal trajectory for pedicle screw insertion in each vertebra, to avoid injury to VA and spinal cord.^{12,13} We also referred to previous experience in producing templates for transpedicle screw and transarticular screw (TAS) of thoracic and cervical spine, respectively.^{14–16} Preoperative imaging of the cervical spine was obtained by CT scanner using a slice thickness of 0.7 mm. Images on any arbitrary trajectory was interpolated from the original CT imaging. By determining the entry point of the planning trajectory, the ideal screw length and its diameter were measured manually in the software. The depict screw trajectories on screen was documented and confirmed by experienced neurosurgeon. Then, we design a guiding template with foot that perfectly matches patient's lamina surface and can fit with it firmly. Model of the cervical anatomy and the guiding templates were fabricated first for preoperative rehearsal and for comparing with the fresh anatomy during operation. The template consists of a pair of sleeves with metal rings embedded which allows K-wires passing through to examine the trajectories on X-ray before screw insertion.

Preoperative Planning and Surgery

We input the thin-sliced CT raw data into the software and a trajectory with entry point was generated automatically. We adjusted the trajectory manually and was confirmed by the surgeon. The patients' cervical spine models and guiding templates are made according to the blueprints.

The posterior atlantoaxial fixation surgery was all performed by one professional neurosurgeon in the National Cheng Kung University Hospital (NCKUH). After intubation

and general anesthesia, the patient was placed as prone position with Mayfield skull clamp. Cervical spine lateral view was obtained by C-arm to adjust the cervical alignment as well as possible. Then, we performed the awake test to make sure no new neurological deficit due to positioning. The templates and spine model were sterilized by plasma. After well soft tissue dissection, templates were applied on C1 posterior arch and C2 lamina separately. Placement of the templates were compared and checked repeatedly between the patient cervical and the spine model, make sure that it is correctly and stably standing on the designed contact region. Pins and screws were inserted through the tunnel on the template. The posterior fixation system we used is SYNAPSE produced by Depuy Synthes Company. The screw diameter is 3.5 mm and the length is according to independent patient's preoperative planning. After completing insertion of the screws, we used C-arm to confirm their location, as we usually do by free-hand technique.

Postoperative Evaluation

Postoperative CT was taken to validate the precision of the placement of each vertebra between preoperative planning and postoperative image in complex cases. We use 2 mm increment classification system to evaluate the success rate of pedicle screw insertion. The grading system was classified into four grades as follows: grade 0—no deviation, screw was entirely contained within the pedicle; grade 1—deviation of less than 2 mm or less than half the screw diameter; grade 2—deviation of more than 2 mm and less than 4 mm, or half the screw diameter; and grade 3—deviation of more than 4 mm or complete deviation.¹⁷

The study was approved by Institutional Review Board of the National Cheng Kung University Hospital (NCKUH-IRB), Taiwan, numbered: B-ER-102-441.

Result

Case 1

The first patient was a 48-year-old woman, who has polio infection since her childhood and resulted in right limbs muscle atrophy. She came to our hospital due to neck pain with decreased four limbs muscle power. Through image studies, type 2 odontoid fracture with atlantoaxial subluxation and dens invagination were diagnosed. Severe spinal stenosis with myelopathy was identified at C1–2 level. There was also severe kyphoscoliosis at cervical and thoracic spine (►Fig. 1). Her VA had no variant despite the deformity. The computer illustrated blueprint and 3D-printed template are shown in ►Fig. 2.

The operation was done smoothly. No VA injury was noted during operation, and we obtained cervical CT image to validate the result. In the CT image after operation, we found her left side C2 screw breached the transverse foramen. The screws in C1 have grade 0 deviation. However, the screws in C2 have grade 2 deviation at the left side and grade 0 at the right side. And the trajectory of right C2 pedicle screw has a bit different from the original design. Although screw has breached through, her postoperative CT angiography showed

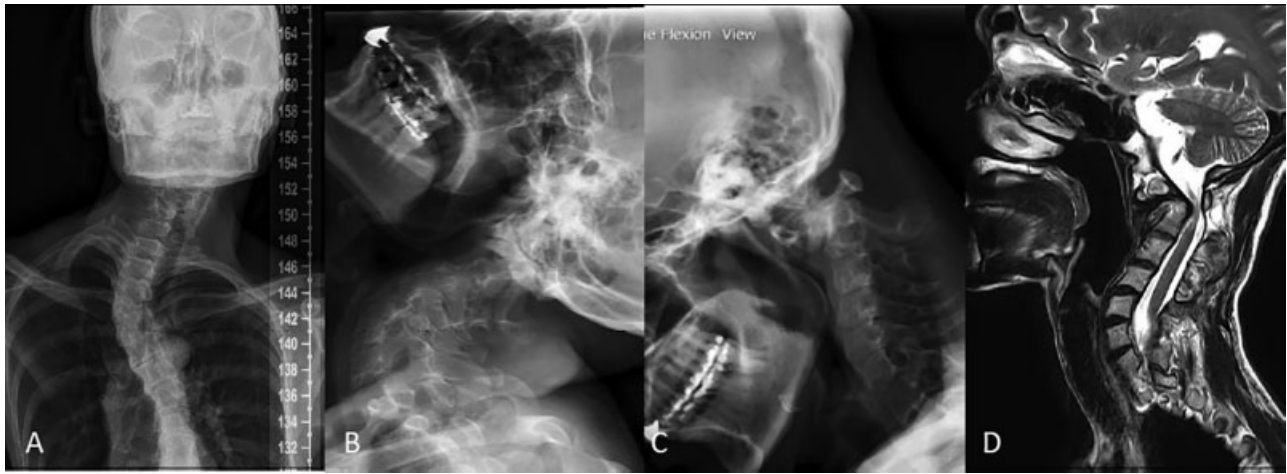

Fig. 1 Image of first case, severe deformity of cervical spine, with C1–2 subluxation. (A) C-spine AP view. (B) C-spine extension view. (C) C-spine flexion view. (D) MRI T2 sagittal view showed stenosis at C2 level. AP, anteroposterior; MRI, magnetic resonance imaging.

patent left VA without blood flow decrease or lumen narrowing (►Fig. 3).

Case 2

The second patient was a 73-year-old woman. She came to our hospital for neck pain with limited neck motion. Cervical spine images showed C1–2 subluxation and herniated intervertebral disc at C6–7 level (►Fig. 4). There was mild spinal stenosis at C1–2 level while in neutral position. Atlantoaxial posterior fixation was indicated. In preoperative evaluation, the VA had no variant, but bilateral C2 pedicles were thin, around 2.6 mm. Her computer illustrated blueprint is shown in ►Fig. 5.

The operation was done smoothly. No VA injury was noted during operation. The postoperative cervical CT showed screw breached the left C2 transverse foramen, and the trajectory was deviated from preoperative planning (►Fig. 6). The deviation grade at C1 is 0, and 1 at both side of C2. Although breach through, bilateral VA was patent on postoperative angiography.

Case 3

The third patient was a 62-year-old woman. She was a case of symptomatic C1–2 subluxation. In addition to the C1–2 subluxation, she also has herniated intervertebral disc (HIVD) at C3 to C6 level with radiculopathy and mild myelopathy. In preoperative survey, no variant was noted about VA, and the C2 pedicles were wider than the screw (3.5 mm) (►Fig. 7). This case was recruited as a control.

The screws were all well placed, no deviation from the preoperative plan. Her symptoms of nuchal pain with limited range of motion resolved soon after operation. Four months later, she admitted again for receiving C3–6 HIVD treatment (►Fig. 8).

Prognosis

The operation time was 145, 179, and 115 minutes, and blood loss was 300, 200, and 1,300 mL, respectively. All the three patients had no VA injury during operation, and their symptoms related to atlantoaxial subluxation were successfully

treated, no screw loosening or refractory symptoms after 6 months follow-up.

Discussion

For atlantoaxial instability, posterior fixation was developed decades ago and has been the standard procedure ever since. Among numerous variations of the surgical methods, Goel–Harms' method is the most widely used because of its high fusion rate and stability.^{3,18} Compare with TAS fixation, Goel–Harms' method has lower risk of VA injury and potential for reduction maneuver.^{1,19} However, the procedure for screw insertion is technical demand. Helgeson et al had reported that the accuracy of free-hand C2 pedicle screw insertion in cadaver was 89.1%.³ In clinical studies, accuracy of C2 pedicle screw ranged from 80 to 100% under different methods.^{1,20} VA injury is reported in 0.5 to 2.2% cases, and varies in different centers, cervical levels, and surgical approaches.⁸ The VA variation, pedicle size, and patient's cervical alignment affect the accuracy of screws insertion most. To diminish the risk and improve the accuracy, image guiding system is introduced into screw insertion surgery. But it still has some limitation. The inaccuracy of the screw insertion under 3D real-time navigation result from change in the cervical alignment between preoperative image and intraoperation position, and registration or probing error also occurred.

As a new method of pedicle screw insertion, concept of personalized image-based guiding template in atlantoaxial fixation was first proposed by Van Cleynenbreugel et al in a cadaveric study.⁷ With technology advancing, the cost of making a personalized template by 3D printing has dramatically decreased, and the 3D printing material is more durable and available than before. 3D guiding template has not only used in cervical spine but it has also been used in thoracic and lumbar spine.¹⁰ Recently, several navigation template systems for high cervical spine were reported.^{21–27} Although lack large comparative study, accuracy of cervical pedicle screw insertion using guiding template showed no inferior to previous methods.¹⁰ 3D-printed personalized guiding template has

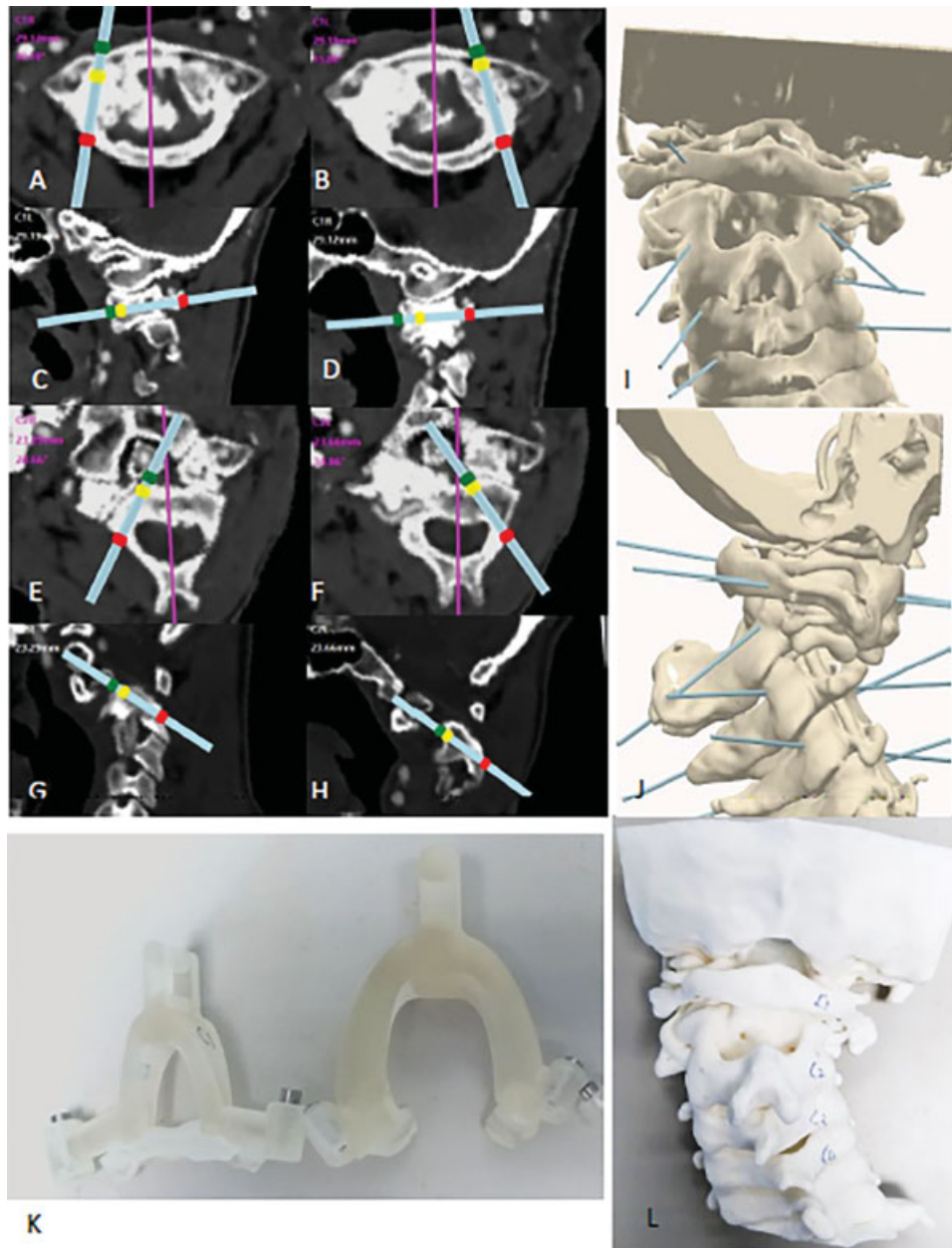


Fig. 2 Computer illustrated blueprint of the first patient. (A–H) Planning on CT axial and sagittal views. The red dot is the entry point, yellow dot is the end of screw, and the green dot shows the other side of cortex. (I–J) 3D blue print of screw trajectory. (K) Template of C1 (left) and C2 (right). (L) Spine model for preoperative simulation. CT, computed tomography; 3D, three-dimensional.

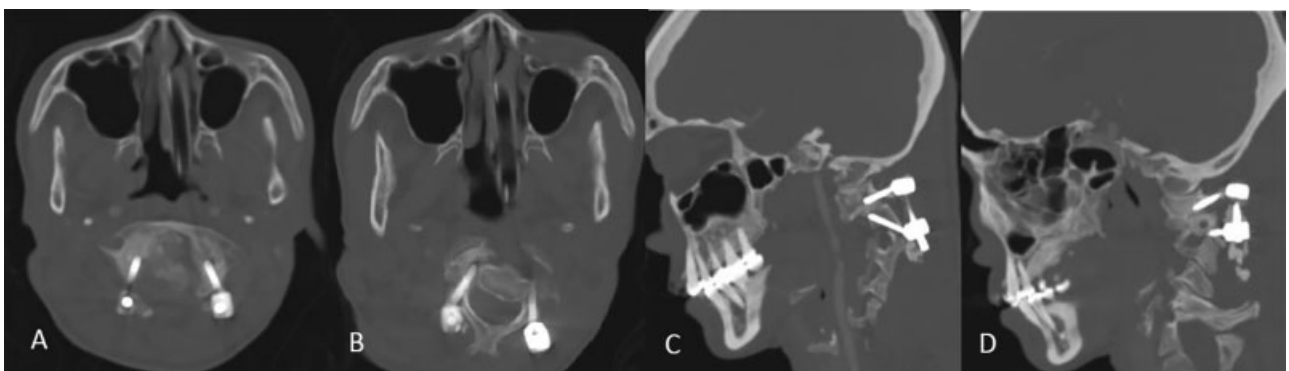


Fig. 3 Postoperative CT of first patient. (A) Screws of C1. (B) Screws of C2. The right C2 pedicle screw has malposition. (C) Sagittal view of left side screws. (D) Sagittal view of right side screws. CT, computed tomography.

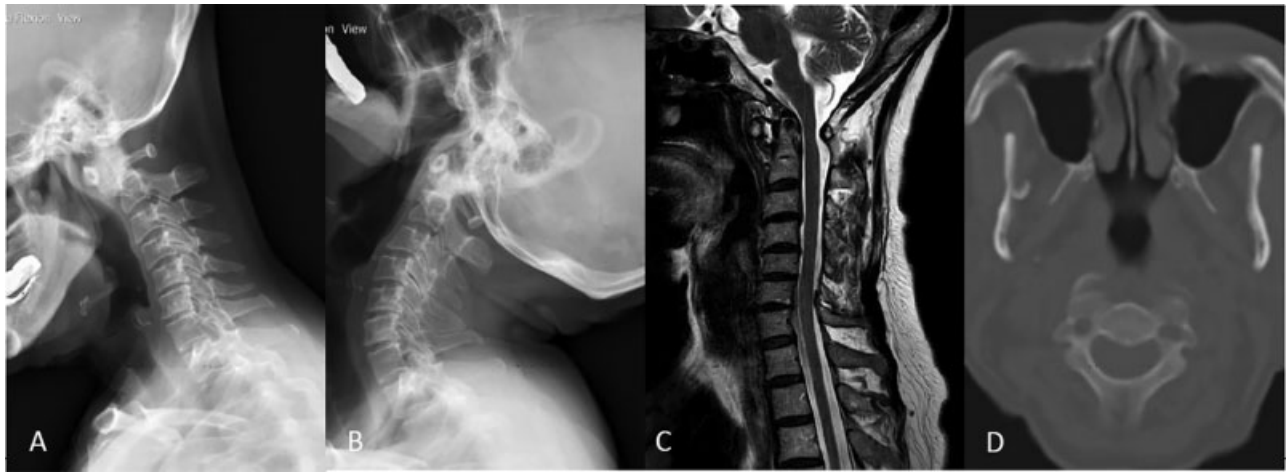

Fig. 4 Image of second case, C1–2 subluxation with small C2 pedicles. (A) Flexion view. (B) Extension view. (C) MRI T2 sagittal view, no spinal stenosis at C1–2 level. (D) CT axial view at C2 level. Both pedicles are less than 3.5 mm. CT, computed tomography; MRI, magnetic resonance imaging.

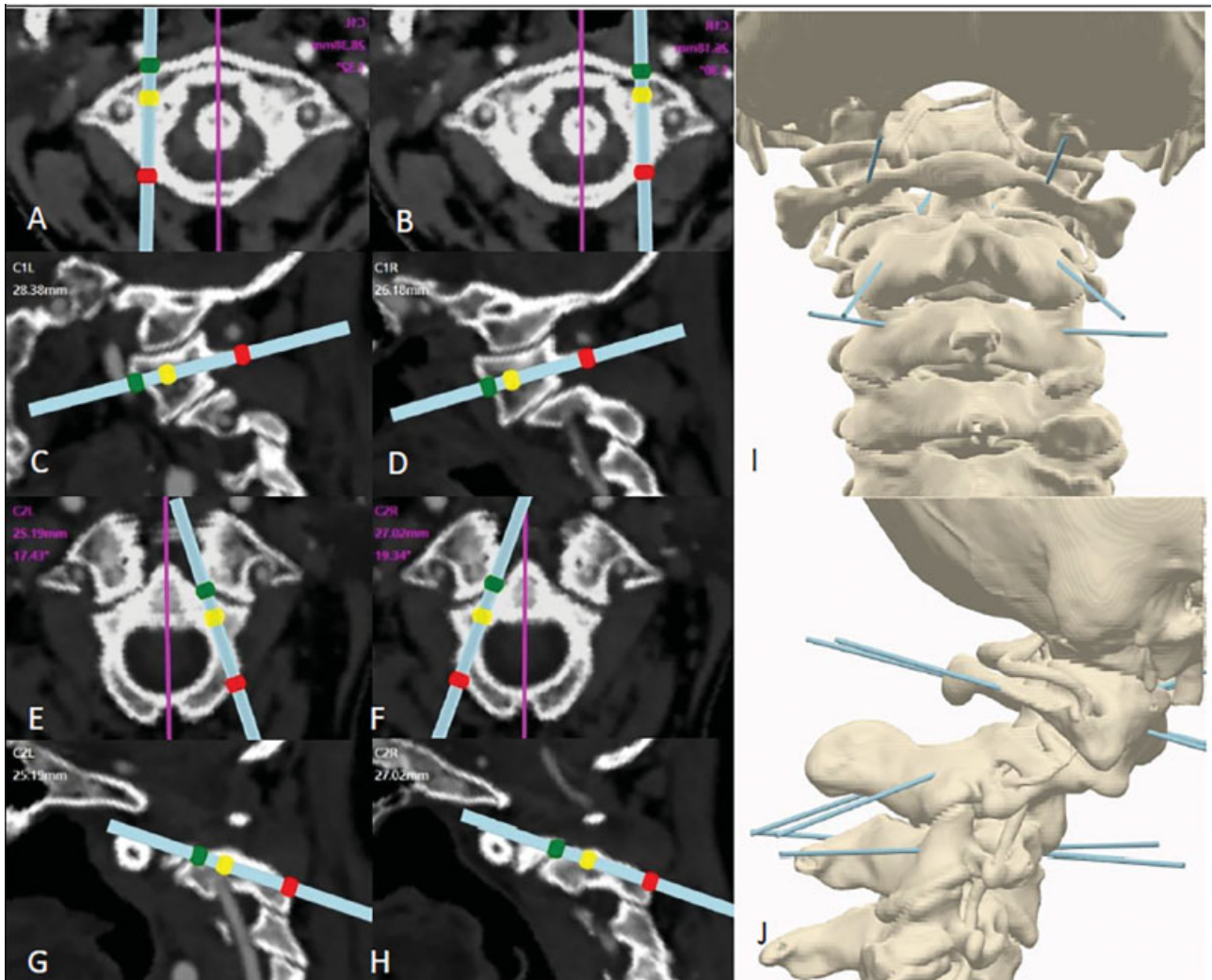


Fig. 5 Computer illustrated blueprint of the second patient. (A–H) Planning on CT axial and sagittal view. (I–J) 3D blue print of screw trajectory. CT, computed tomography; 3D, three-dimensional.

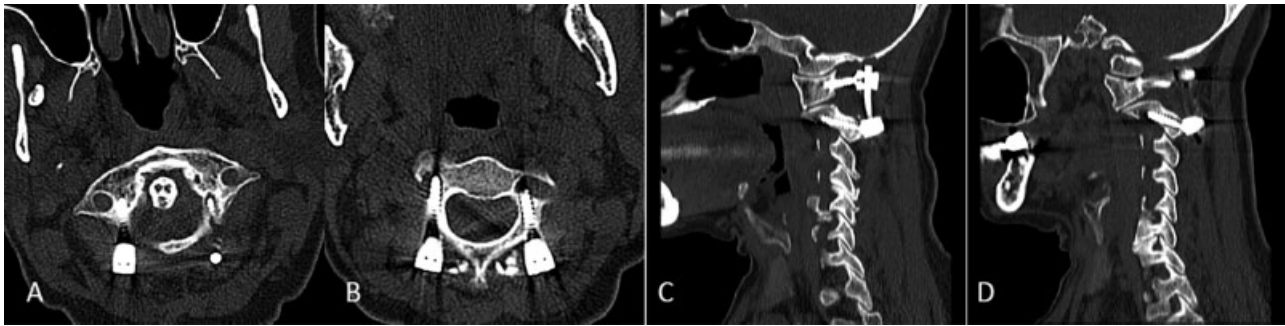


Fig. 6 Postoperative CT of second patient. (A) Screws of C1. (B) Screws of C2. The right C2 pedicle screw has breach into transverse foramen. (C) Sagittal view of right side screws. (D) Sagittal view of left side screws. CT, computed tomography.

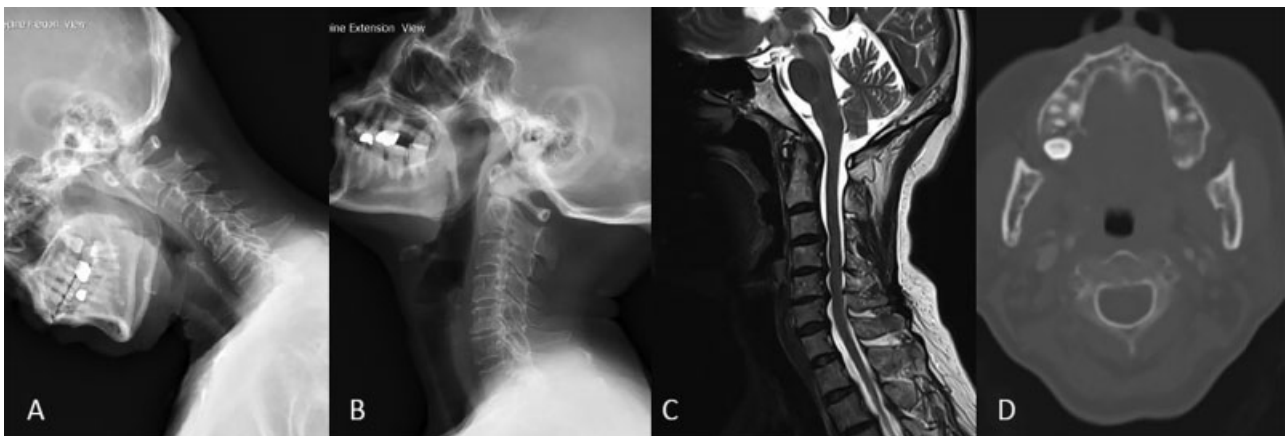


Fig. 7 Image of third case, C1–2 subluxation. (A) Flexion view. (B) Extension view. (C) MRI T2 sagittal view, no spinal stenosis at C1–2 level. (D) CT axial view at C2 level. Both pedicles are more than 3.5 mm. CT, computed tomography; MRI, magnetic resonance imaging.

advantage in addition to accuracy, such as less radiation exposure, lower operation time, and shorter learning curve.

3D printing guiding template also has its limitation. First, the limitation of image acquiring and 3D printing machine. Even using extreme thin-sliced CT, 0.1 mm per slice, we cannot make perfect cervical spine duplicate. Therefore, the template sometimes may not fit the laminae firmly as on the model. In some patients, their posterior surface of laminae is so smooth that lack of enough landmark or bony prominent for template to fit in. These will cause template unstable and result in screw misplacement. Second, to place the template on the laminae, we need to do well and widely soft tissue dissection for template to stand. However, doing bone preparation sometimes caused venous plexus massive bleeding. To design a template, the most important part is the contact area with the laminae. Small contact area causes the template hard to lock on the laminae surface, while large template is difficult to use in small operation field.

Our template design is based on the software. The trajectory of the screw is automatically calculated, but the contact area and the shape of the template are made manually. In previous report,²⁸ only template was printed. However, we also printed the patient's cervical spine as reference. The cervical spine model is useful in preoperative planning and helping recognized bony landmarks. By compare the model with the real human spine, we can quickly identify a parameter need to be cleaned, and we can make sure that the template attached

exactly at the same location and angle as we wanted. There are two cylinders on the template with metallic inlet. The inlet is changeable, different inlets match the size of pin, owl, or drill. This design prevents deviation of the trajectory when using different tools. The cost of the 3D printing set per patient is approximate 1,000 US dollars, including two templates and a cervical spine model. Our charge is higher than other reports²⁹ because we do not own the software or the 3D-printed machine. Template drawing and printing are outsourced to the NCKU virtual reality research laboratory and commercial 3D printing company separately.

In our cases, the first patient is an extremely difficult case to perform free-hand cervical screws insertion due to unusual cervical alignment. Without 3D printing guiding template, occipital–cervical (OC) fusion may be the only choice for this patient. Although right C2 pedicle was still breached into transverse foramen, no major VA complication happened because the screw's length was evaluated in advance when make the guiding template. Knowing the tricks of template using, and experience learned from first patient, the second and third patients received a successful surgery. The technique required in atlantoaxial fixation using 3D printing template is different from using C-arm, O-arm, or image guiding system. Although surgeons still need to learn the steps and concept of Goel–Harms' technique, finding the entry point and deciding the trajectory are no longer a problem for an unexperienced surgeon. The experienced surgeon may perform more atlantoaxial

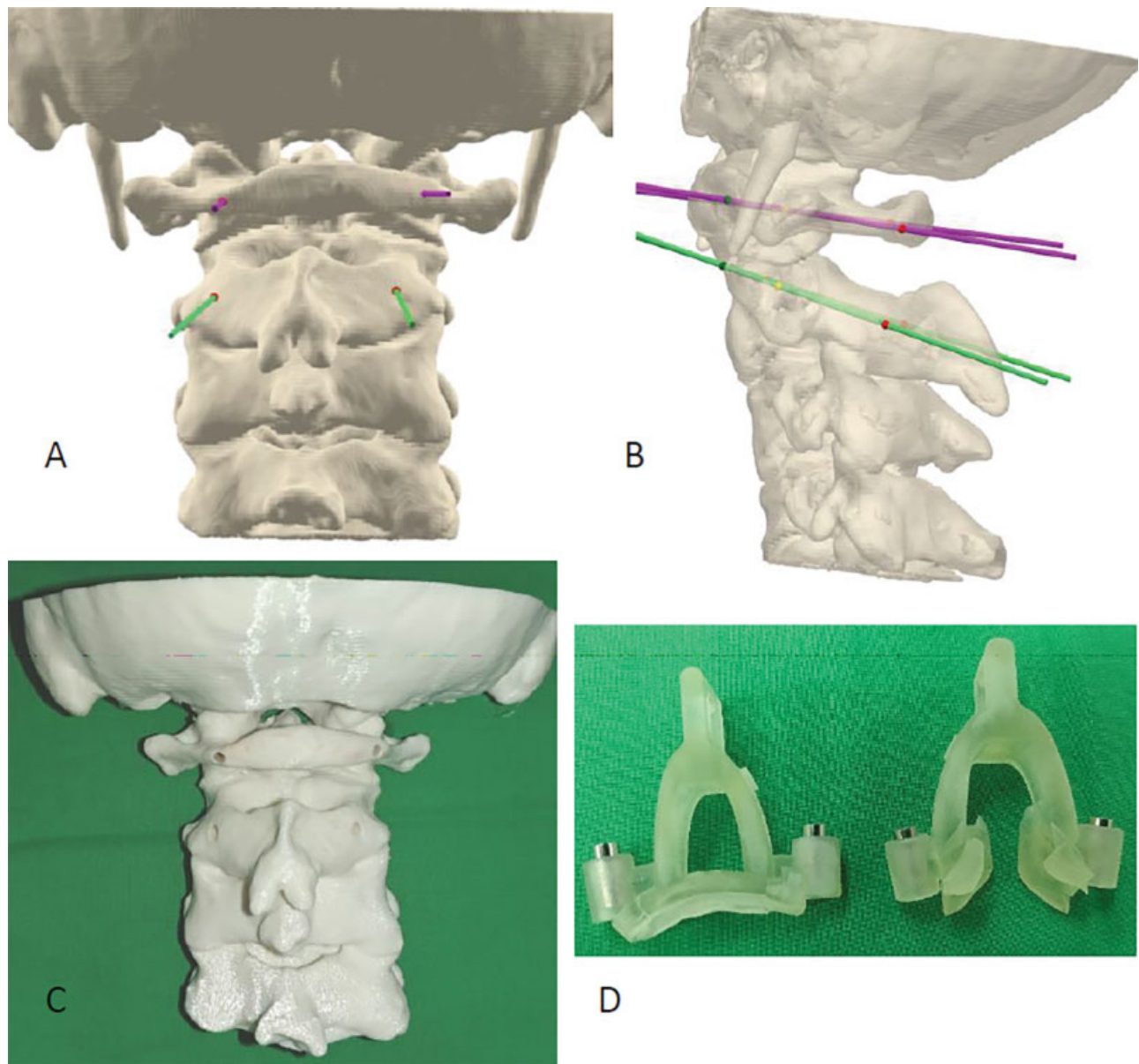


Fig. 8 (A, B) Computer illustrated 3D blueprint of the third patient. (C) Cervical spine model of the third patient. (D) Templates of the third patient.

fixation instead of OC fusion to preserve cervical motion in difficult cases with 3D printing template. However, this new technique still not guarantees 100% safe, knowing how to manage complications is still essential.

Conclusion

The 3D printing method is a broad road to atlantoaxial fixation. This way makes the most difficult and dangerous spinal posterior fixation easy to achieve. Compare with other screw insertion methods, it reduces the operation time, radiation exposure, risk of VA injury, and surgeon's learning curve. However, due to limitation in 3D printer's resolution, guiding blocks still has deviation in patient with less bony features. For patients with complex cervical anatomy, this technique still requires experience in planning and template design.

Conflict of Interest

None.

Acknowledgment

Special thanks to Prof. Ruey-Mo Lin, China Medical University, Taiwan, for his professional support on this study.

References

- 1 Bransford RJ, Russo AJ, Freeborn M, et al. Posterior C2 instrumentation: accuracy and complications associated with four techniques. *Spine* 2011;36(14):E936–E943
- 2 Yang YL, Zhou DS, He JL. Comparison of isocentric C-arm 3-dimensional navigation and conventional fluoroscopy for C1 lateral mass and C2 pedicle screw placement for atlantoaxial instability. *J Spinal Disord Tech* 2013;26(03):127–134
- 3 Ishikawa Y, Kanemura T, Yoshida G, et al. Intraoperative, full-rotation, three-dimensional image (O-arm)-based navigation

- system for cervical pedicle screw insertion. *J Neurosurg Spine* 2011;15(05):472–478
- 4 Ito H, Neo M, Yoshida M, Fujibayashi S, Yoshitomi H, Nakamura T. Efficacy of computer-assisted pedicle screw insertion for cervical instability in RA patients. *Rheumatol Int* 2007;27(06):567–574
 - 5 Miyata M, Neo M, Ito H, et al. Is rheumatoid arthritis a risk factor for a high-riding vertebral artery? *Spine* 2008;33(18):2007–2011
 - 6 Shin MH, Ryu KS, Park CK. Accuracy and safety in pedicle screw placement in the thoracic and lumbar spines: comparison study between conventional C-arm fluoroscopy and navigation coupled with O-arm® guided methods. *J Korean Neurosurg Soc* 2012;52(03):204–209
 - 7 Van Cleynebreugel J, Schutyser F, Goffin J, Van Brussel K, Suetens P. Image-based planning and validation of C1-C2 transarticular screw fixation using personalized drill guides. *Comput Aided Surg* 2002;7(01):41–48
 - 8 Hsu WK, Kannan A, Mai HT, et al. Epidemiology and outcomes of vertebral artery injury in 16 582 cervical spine surgery patients: an AOSpine North America Multicenter Study. *Global Spine J* 2017;7(1, Suppl):21S–27S
 - 9 Izatt MT, Thorpe PL, Thompson RG, et al. The use of physical biomodelling in complex spinal surgery. *Eur Spine J* 2007;16(09):1507–1518
 - 10 Wilcox B, Mobbs RJ, Wu AM, Phan K. Systematic review of 3D printing in spinal surgery: the current state of play. *J Spine Surg* 2017;3(03):433–443
 - 11 Sugawara T, Higashiyama N, Kaneyama S, et al. Multistep pedicle screw insertion procedure with patient-specific lamina fit-and-lock templates for the thoracic spine: clinical article. *J Neurosurg Spine* 2013;19(02):185–190
 - 12 Fang JJ, Wong TY, Wu TC. Method of quantifying asymmetry of an object, United States patent no. 7,801,345, 2010
 - 13 Fang JJ, Lin RM, Wu TC, Hou CY. Guiding assembly for spinal drilling operation, European Patent no. EP2502582 B1, 2017
 - 14 Wu HH, Su IC, Hsieh CT, Fang JJ, Chang CJ. Accuracy and safety of using customized guiding templates for cervical pedicle screw insertion in severe cervical deformity, fracture, and subluxation: a retrospective study of 9 cases. *World Neurosurg* 2018;116:e1144–e1152
 - 15 Fang JJ, Kuo TH, Lin RM, Ho CY. Guiding templates for pedicle screws insertion: a preliminary study. *Biomed Eng Appl Basis Commun* 2012;24(06):495–501
 - 16 Huang KY, Lin RM, Fang JJ. A novel method of C1-C2 transarticular screw insertion for symptomatic atlantoaxial instability using a customized guiding block: a case report and a technical note. *Medicine (Baltimore)* 2016;95(43):e5100
 - 17 Lu S, Xu YQ, Chen GP, et al. Efficacy and accuracy of a novel rapid prototyping drill template for cervical pedicle screw placement. *Comput Aided Surg* 2011;16(05):240–248
 - 18 Helgeson MD, Lehman RA Jr, Dmitriev AE, et al. Accuracy of the freehand technique for 3 fixation methods in the C-2 vertebrae. *Neurosurg Focus* 2011;31(04):E11
 - 19 Harms J, Melcher RP. Posterior C1-C2 fusion with polyaxial screw and rod fixation. *Spine* 2001;26(22):2467–2471
 - 20 Bydon M, Mathios D, Macki M, et al. Accuracy of C2 pedicle screw placement using the anatomic freehand technique. *Clin Neurol Neurosurg* 2014;125:24–27
 - 21 D'Urso PS, Williamson OD, Thompson RG. Biomodeling as an aid to spinal instrumentation. *Spine* 2005;30(24):2841–2845
 - 22 Guo F, Dai J, Zhang J, et al. Individualized 3D printing navigation template for pedicle screw fixation in upper cervical spine. *PLoS One* 2017;12(02):e0171509
 - 23 Madrazo I, Zamorano C, Magallón E, et al. Stereolithography in spine pathology: a 2-case report. *Surg Neurol* 2009;72(03):272–275, discussion 275
 - 24 Mao K, Wang Y, Xiao S, et al. Clinical application of computer-designed polystyrene models in complex severe spinal deformities: a pilot study. *Eur Spine J* 2010;19(05):797–802
 - 25 Mizutani J, Matsubara T, Fukuoka M, et al. Application of full-scale three-dimensional models in patients with rheumatoid cervical spine. *Eur Spine J* 2008;17(05):644–649
 - 26 Sugimoto Y, Tanaka M, Nakahara R, Misawa H, Kunisada T, Ozaki T. Surgical treatment for congenital kyphosis correction using both spinal navigation and a 3-dimensional model. *Acta Med Okayama* 2012;66(06):499–502
 - 27 Xiao JR, Huang WD, Yang XH, et al. En bloc resection of primary malignant bone tumor in the cervical spine based on 3-dimensional printing technology. *Orthop Surg* 2016;8(02):171–178
 - 28 Kaneyama S, Sugawara T, Sumi M, Higashiyama N, Takabatake M, Mizoi K. A novel screw guiding method with a screw guide template system for posterior C-2 fixation: clinical article. *J Neurosurg Spine* 2014;21(02):231–238
 - 29 Sugawara T, Higashiyama N, Kaneyama S, Sumi M. Accurate and simple screw insertion procedure with patient-specific screw guide templates for posterior C1-C2 fixation. *Spine* 2017;42(06):E340–E346