

Combined Endoscopic-Robotic Resection of a Giant Polyp to Avoid Colorectal Resection

Montserrat Guraieb-Trueba, MD, Víctor Manuel Rivera-Méndez, MD,
Juan Carlos Sánchez-Robles, MD

ABSTRACT

Colorectal cancer prevention relies on effective screening through colonoscopy and polypectomy. Several techniques and methods have been described to manage complex colonic polyps such as the ones that are endoscopically unresectable. Across time, we have been able to perform less invasive techniques that include different types of colonic resections, ranging from partial thickness, full-thickness and, segmental colectomies, however, none has proven to be the treatment of choice for these lesions. The technique presented here is an attractive alternative to segmental colectomy using a robotic platform to perform a full-thickness resection.

Key Words: Robotic surgery, Combined approach, Polyp, Colon, Colonoscopy, Colon cancer, Minimally invasive surgery.

INTRODUCTION

Prevention of colorectal cancer relies on appropriate screening, early detection and, if necessary, polypectomy.

Colorectal Surgery Department, Hospital Central Militar, México City, México (Dr. M. Guraieb-Trueba)

Advanced Endoscopy Department, Hospital Central Militar, México City, México (Dr. V. M. Rivera-Méndez)

Hospital San Ángel Inn Chapultepec, México City, México (Dr. J. C. Sánchez-Robles)

This is an open-access article distributed under the terms of the Creative Commons Attribution-Noncommercial-ShareAlike 3.0 Unported license (<https://creativecommons.org/licenses/by-nc-sa/3.0/>), which permits unrestricted non-commercial use, distribution, and reproduction in any medium, provided the original author and source are credited.

Disclosure: none.

Funding/Financial support: none.

Conflicts of interest: The authors declare no conflicts of interest.

Informed consent: Dr. Guraieb-Trueba declares that written informed consent was obtained from the patient's for publication of this study/report and any accompanying images.

Address correspondence to: Montserrat Guraieb-Trueba, Blvd Adolfo López Mateos s/n, Miguel Hidalgo, 11320, México City, México, Tel.: 52-8112902652, E-mail: mguraieb16@hotmail.com.

DOI:10.4293/CRSLS.2020.00097

© 2021 by SLS, Society of Laparoscopic & Robotic Surgeons. Published by the Society of Laparoscopic & Robotic Surgeons.

Benign polyps are widely accepted to be precursors to malignancy, and colonoscopic polypectomy is currently the standard of care. However, around 10–15% of the identified polyps are considered “difficult polyps” depending on their size, location, likelihood of perforation, macroscopic characteristics, or their localization within colonic folds, which makes them sometimes not candidates to resection thru colonoscopy. In this case, radical surgery has been traditionally the treatment of choice, with the obvious higher risk of complications, even in expert hands and when minimally invasive techniques are used.^{1,2}

Beck et al.¹ introduced in 1993, a laparoscopic-assisted colonoscopic polypectomy (LACP) for the treatment of benign polyps not suitable to colonoscopic resection, in an effort to spare the patients the morbidity associated with major bowel resection. This technique involved laparoscopic manipulation and mobilization of the bowel to facilitate the colonoscopic polypectomy. This procedure is feasible for polyps located anywhere in the colon with success rates between 61 and 84%.^{1,3} Furthermore, there is a subset of patients for whom LACP is not suitable and a combined endoscopic-laparoscopic (CELS) full-thickness resection might be the procedure of choice; this is especially true for cecal polyps where the bowel wall can be very thin and the size of the cecum can easily accommodate a wedge resection.

To date, two variations of CELS have been described: laparoscopic-assisted colonoscopic excision and colonoscopic-assisted laparoscopic resection. Where laparoscopic-assisted colonoscopic polyp excision involves the use of laparoscopic instruments to manipulate the colon to present the polyp to the colonoscope for its resection; colonoscopic-assisted laparoscopic resection entails direct intraluminal demonstration of a polyp for optimal localization and stapler placement during resection.⁴

According to our literature search, there are no reports of a combined endoscopic-robotic resection (CERS) of an endoscopically unresectable polyp. Therefore, we propose the technique and present a case where the colonoscope was used to localize an endoscopically unresectable polyp in the cecum and after proper identification, we performed

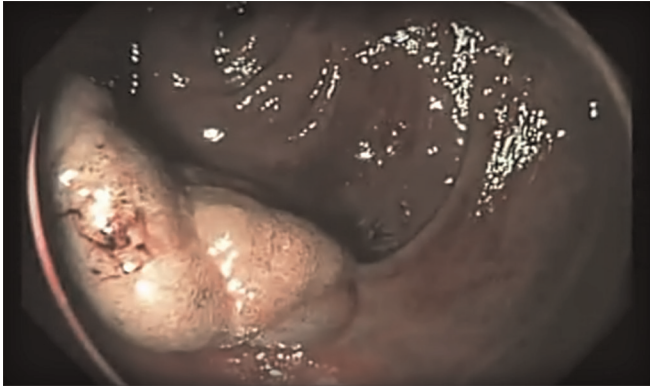

Figure 1. Endoscopic visualization of a cecal polyp.

a robotic-assisted full-thickness resection with primary suture closure.

CASE Presentation

A 45-year male, with a family history of colon cancer in the mother at age 50, who died due to the disease, came to our colorectal clinic, asymptomatic, for a screening colonoscopy. During the endoscopic study, we found a 30.5-cm sessile polyp in the cecum, which due to the location and size, it was determined as unresectable endoscopically (**Figure 1**). Biopsy reported an adenomatous polyp with high-grade dysplasia. Because of the patient's age, health, and polyp characteristics we decided to perform a Robotic full-thickness biopsy under endoscopic guidance. With the patient in French position; after a normal diagnostic laparoscopy, we placed three 8-mm Da Vinci X[®] (Intuitive Surgical Inc., Sunnyvale CA), one for the robotic camera at the umbilicus, one in the suprapubic region for robotic arm number 1, and another in the sub-xiphoid region for robotic arm number 2. A 10-mm laparoscopic port was placed in the left flank for the assistant. After docking the robot (**Figure 2**), we performed complete lateral mobilization of the ileo-cecal region and endoscopic identification and marking with methylene blue of the polyp to facilitate extraluminal identification. We located the polyp in the lateral-posterior wall of the cecum, near the ileo-cecal valve. Once the lesion was completely identified we placed two stay sutures at both ends of the marks and started the full-thickness resection with monopolar energy (**Figure 3**). After resection was completed, we placed the specimen in a bag and proceeded to the defect closure. A two-layer closure with a barbed suture was performed with colonoscopic cannulation of the ileo-cecal valve to assure permeability. A pneumatic

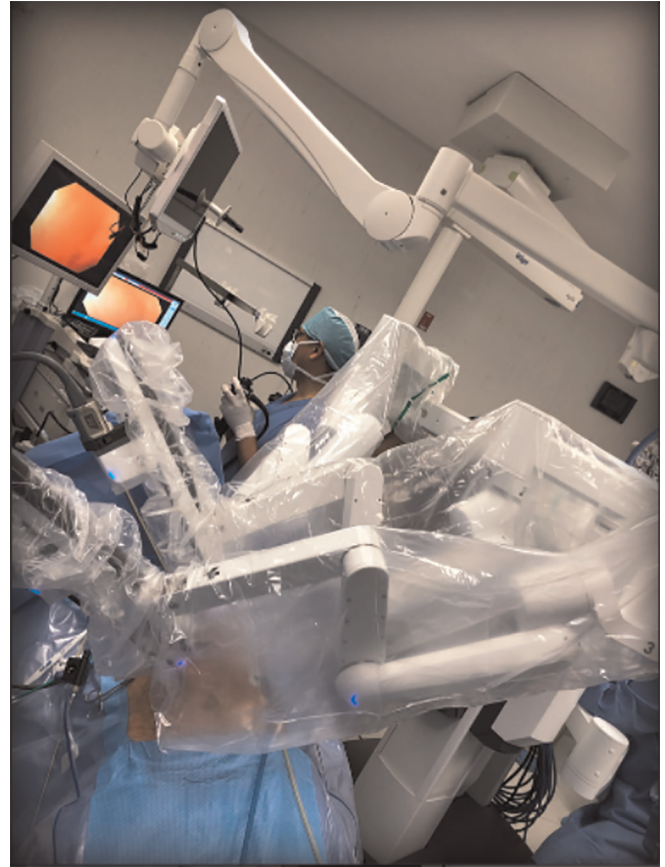

Figure 2. Robot and endoscopist setup. View from the patient's head.

test showed no evidence of leak (**Figure 4**). The specimen was sent to pathology (**Figure 5**). The final pathology report described an adenomatous polyp with no signs of dysplasia. The patient was discharged 24 hours after surgery with no adverse effects due to the procedure or perioperative care.

DISCUSSION

Colon cancer screening programs worldwide have increased the detection and diagnosis of early-stage colorectal cancer.⁵ This has led to the identification of a greater number of earlier stage lesions (polyps) with or without dysplasia. Currently, novel endoscopic techniques such as endoscopic submucosal dissection (ESD) and endoscopic mucosal dissection (EMD) have been described. However, even in expert hands, they carry up to 20.7% risk of perforation, which is much higher than the 1 in 1400–3000 risk for screening colonoscopy and the 1 in 1000 risk for therapeutic colonoscopy. Adding to this

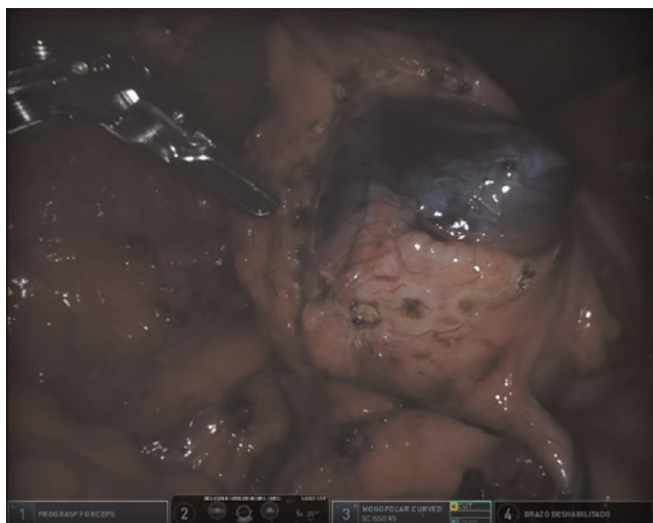


Figure 3. Resection site.

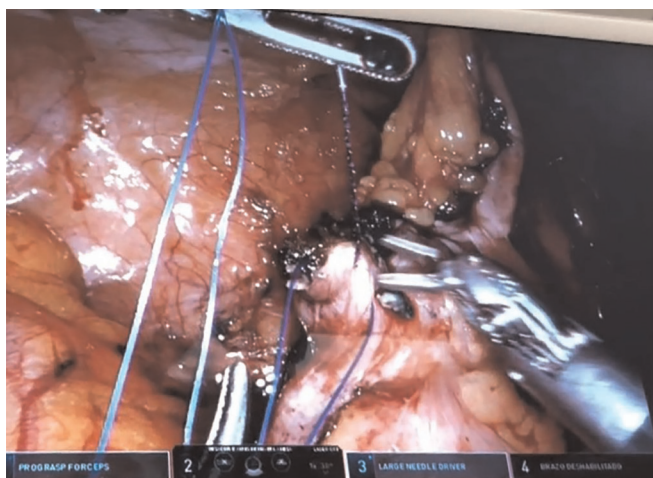


Figure 4. Complete closure of the defect.

increased risk of complications, a 50% recurrence rate after EMD has also been reported.^{2,6} Including the colonoscopic resections, ESD, and EMD all combined, around 15% of the polyps found are not amenable to any of these types of endoscopic resections. This has encouraged surgeons into finding different techniques to avoid unnecessary segmental resections while managing difficult and common lesions.⁶

Once endoscopic polypectomy has failed, surgical treatment is usually the next step. Most patients will undergo a segmental colectomy even if the endoscopic characteristics of the polyp appear to be completely benign.

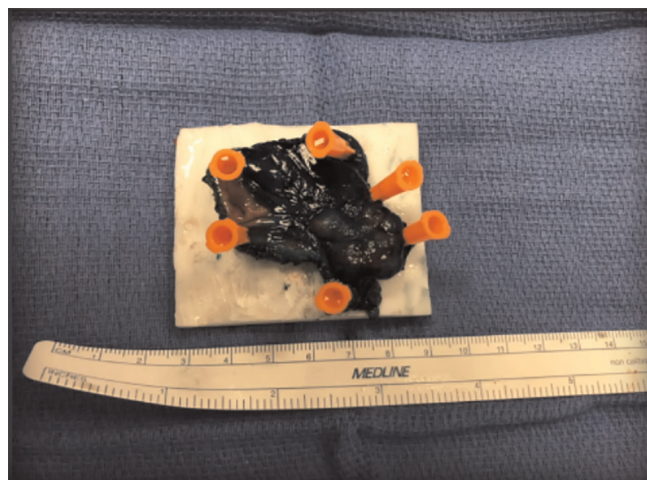


Figure 5. Specimen.

Laparoscopy in conjunction with endoscopy can help to remove difficult colonic polyps avoiding radical segmental colectomy. Hybrid laparoendoscopic techniques are reported in the literature as an alternative to segmental colectomy for the treatment of polyps that have a high probability of being benign.² From the patient's perspective, the assistance of laparoscopy will definitively care for the polyp with a single procedure, which can be more attractive than the prospect of multiple endoscopic procedures.^{2,6}

The risk of cancer in a polyp larger than 2 cm has been described to be as high as 50% nonetheless, in the literature, only 10% to 15% of large colonic polyps have been reported to harbor cancer, hence the need to find a technique to remove the polyps with minimal increase in morbidity and mortality for our patients.⁴

In 1993, the concept of CELS was first described as a way to avoid major bowel resections for benign or undetermined polyps that are not amenable to endoscopic polypectomy. CELS has been shown to decrease the morbidity rate and length of hospital stay when compared to segmental colectomy.^{7,8} For polyps that are unresectable through endoscopy, the CELS procedure has proven to be a reasonable alternative to formal bowel resection in selected patients. Cost-analysis studies have demonstrated that this is a cost-effective procedure when compared to segmental colonic resections.³

The recurrence rate for benign polyps after CELS resection has been reported to be as low as 30.3%.⁴ Although, studies where patients were reassessed following colonoscopic polyp excision at a mean follow-up time of

3.42 years, showed recurrence rates as high as 320.9%. In studies where the effect of a low-fat and high-fiber diet on the recurrence of adenomatous polyps was studied, the recurrence rate was 390.3%.⁹ In contrast, in a study by Binmoeller et al. regarding endoscopic removal of polyps larger than 3 cm, a recurrence rate of 16% was found.^{4,10} Thus, the recurrence rate for polyps removed by colonoscopy alone is higher than the recurrence rate of 30.3% for polyps removed by CELS.^{11,12} The largest study regarding long-term follow up after CELS was performed by Franklin et al.⁹ It included long-term follow-up of 160 patients with 209 polyps finding that at a median follow-up of 65 months (range 6–196 months), there were no recurrences (0%) of completely resected polyps.⁹

There are two other different procedures for the management and resection of difficult colonic polyps: LACP and laparoendoscopically placed BraceBars[®].²

During LACP, colonoscopy is used to locate the polyp in the colon. Mobilization of the colon is often necessary to facilitate wedge resection and polyp identification. The accurate location of the polyp and its edges is the key step in this approach to achieve a complete resection. Transillumination of the colon with subsequent stapler placement and endoscopic view to ensuring complete inclusion of the polyp in the stapler is the most commonly used options. Endoscopic tattooing and argon plasma coagulation application with a laparoscopic observation of the serosal surface for color and thermal changes are two options to facilitate the laparoscopic identification of the polyp during LACP. Whichever localization method is used, wedge resection is usually performed with an endoscopic linear stapler.²

Laparoendoscopically placed BraceBars[®] (Olympus Medical Systems, Olympus KeyMed, Southend-on-Sea, United Kingdom) are placed from inside of the colon to evert the polyp with subsequent stapled resection.²

Success rates with either of these techniques can be as high as 100% with good polyp selection, although some groups have used the technique sparingly for only the most benign-appearing polyps.²

Many different techniques and approaches for the management of difficult colonic polyps have been described and evolved during time. However, they have not yet been sufficiently established, probably because none of them have proven to have consistent results regarding recurrence rates and adequate resection margins as well as low morbidity. During our literature search, we did not find any information regarding the use of robotic surgery for this type

of organ sparing procedure. Taking into consideration the financial costs, we decided to only use 2 robotic arms (more than enough for the CERS procedure) and no staples, instead, we only used 1 barbed suture for defect closure. Early hospital discharge after surgery can decrease costs even more. After patient discharge, a cost analysis was made comparing materials used during laparoscopic procedures. The difference in costs was close to \$0. Taking this into account and adding the advantages of the robotic procedure, we believed this is a feasible approach compared to what has been described in the literature.

CONCLUSIONS

Current decision-making algorithms for the management of difficult polyps that are unresectable thru colonoscopy, do not include combined endoscopic-robotic (CERS) full-thickness resection, probably because there are no reports of this technique in the literature. We describe a novel, bowel-sparing technique for full-thickness excision of benign polyps not suitable to traditional endoscopic resection.

References:

1. Andicoechea-Agorria BE, Casar JM, Fernández JC. Combined endolaparoscopic surgery for colon polyps: a video vignette. *Colorectal Disease*. 2019;21(10):1217.
2. Aslani N, Alkhamesi NA, Schlachta CM. Hybrid laparoendoscopic approaches to endoscopically unresectable colon polyps. *J Laparoendosc Adv Surg Tech*. 2016;26(8):581–590.
3. Jayaram A, Barr N, Plummer R, Yao M, Chen L, Yoo J. Combined endo-laparoscopic surgery (CELS) for benign colon polyps: a single institution cost analysis. *Surg Endosc*. 2018;33(10):3238–3242.
4. Crawford A, Yang I, Wu RC, Moloo H, Boushey RP. Dynamic article: combined endoscopic-laparoscopic surgery for complex colonic polyps postoperative outcomes and video demonstration of 3 key operative techniques. *Dis Colon Rectum*. 2015;58(3):363–369.
5. Goh C, Burke JP, McNamara DA, Cahill RA, Deasy J. Endolaparoscopic removal of colonic polyps. *Colorectal Dis*. 2014;16(4):271–275.
6. Moss A, Bourke MJ, Williams SJ, et al. Endoscopic mucosal resection outcomes and prediction of submucosal cancer from advanced colonic mucosal neoplasia. *Gastroenterology*. 2011;140(7):1909–1918.
7. Lin AY, O'Maloney PR, Milsom JW, Lee SW. Dynamic article: full-thickness excision for benign colon polyps using combined endoscopic laparoscopic surgery. *Dis Colon Rectum*. 2015;59(1)16–21.

8. Garret KA, Lee SW. Combined endo-laparoscopic surgery (CELS). *Minimally Invasive Approaches to Colon Rectal Dis.* 2014;293–299; Springer-Verlag, New York.
9. Franklin ME Jr, Portillo G. Laparoscopic monitored colonoscopic polypectomy: long-term follow-up. *World J Surg.* 2009; 33(6):1306–1309.
10. Binmoeller KF, Bohnacker S, Seifert H, Thonke F, Valdeyar H, Soehendra N. Endoscopic snare excision of “giant” colorectal polyps. *Gastrointest Endosc.* 1996;43-(3):183–188.
11. Viel JF, Studer JM, Ottignon Y, Hirsch JP, Franche-Comté Polyp Surveillance Study Group. Predictors of colorectal polyps recurrence after the first polypectomy in private practice settings: a cohort study. *PLoS One.* 2012;7(12):E50990.
12. Laiyemo AO, Doubeni C, Pinsky PF, et al. Factors associated with the risk of adenoma recurrence in distal and proximal colon. *Digestion.* 2013;87(3):141–146.