

Transjugular Intrahepatic Portosystemic Shunt as the Treatment for Refractory Hepatic Hydrothorax with Portal Vein Thrombosis

Lin-Hao Zhang^{1,2}, Huan Tong¹, Bo Wei¹, Hao Wu¹, Cheng-Wei Tang¹

¹Department of Gastroenterology, West China Hospital, Sichuan University, Chengdu, Sichuan 610041, China

²West China School of Medicine, Sichuan University, Chengdu, Sichuan 610041, China

Hepatic hydrothorax occurs in 4–12% of patients with liver cirrhosis.^[1] A part of patients with persisted hydrothorax resists conservative treatment, known as refractory hepatic hydrothorax (RHH). Portal vein thrombosis (PVT) is observed in about 2.1–16.2% patients with liver cirrhosis,^[2] which may aggravate portal hypertension. If RHH and PVT are combined in a cirrhotic patient, transjugular intrahepatic portosystemic shunt (TIPS) may be a reasonable intervention.^[3] However, no such successful case has been reported. We herein reported a case of cirrhotic patient complicated with both RHH and PVT, who underwent TIPS and achieved long-term survival.

A 66-year-old female with a history of hepatitis B-related cirrhosis was admitted on October 14, 2011, with a 2-year history of progressive dyspnea. There was no history of variceal bleeding, ascites, or hepatic encephalopathy before admission. Electrocardiogram and echocardiogram were normal. Contrast computed tomography (CT) demonstrated pleural fluid and thrombosis of the portal vein [Figure 1a and 1b]. Accordingly, the patient was diagnosed with hepatic hydrothorax and PVT. The patient was placed on salt and fluid restriction, albumin infusion, and high-dosage diuretics (furosemide 140 mg/d and spironolactone 350 mg/d). Repeated thoracentesis was attempted but ineffective.

Due to RHH and PVT, the patient was considered for TIPS and subsequently underwent the procedure. During the operation, thrombus was observed in the main trunk and left branch of portal vein and the superior mesenteric vein. A 10 mm × 50 mm covered stent (Boston Scientific, Galway, Ireland) was implanted [Figure 1c and 1d]. One week after TIPS, the patient's dyspnea relieved. Two weeks later, the patient was discharged and received diuretics. No respiratory symptoms recurred. Follow-up CT at 4th month showed further regression of hydrothorax and PVT [Figure 1e and 1f]. As

such, the doses of diuretics were reduced. Nine months after TIPS, CT found minimal hydrothorax. Ultrasound demonstrated stent patency 18 months after stent placement. The patient has now undergone long-term follow-up for 5 years, during which she has had only one episode of hepatic encephalopathy.

Portal hypertension is the pathophysiological basis for the development of hepatic hydrothorax. Besides the enhanced intrahepatic resistance, PVT made the portal hypertension more severe in this case and no response to conventional treatments.

PVT was ever contraindicated for TIPS. With the technical progress in recent years, it has been reported that TIPS stents have been inserted in the portal vein with thrombus.^[4] PVT turned to be an indication for TIPS in some situations. Hydrothorax of this case was relieved effectively owing to TIPS intervention by which portal hypertension was greatly decreased.

With regard to application of anticoagulants after TIPS, especially for the patients with PVT, there is no consensus.^[5] What international normalized ratio (INR) level would be benefit for the post-TIPS patients is still unclear because there are too much interference factors of INR in the cirrhotic patients. This case obtained long-term stent patency without anticoagulation therapy after TIPS procedure. It might be

Address for correspondence: Prof. Cheng-Wei Tang,
Department of Gastroenterology, West China Hospital, Sichuan
University, No. 37, Guo Xue Xiang, Chengdu, Sichuan 610041, China
E-Mail: shcqdmed@163.com

This is an open access article distributed under the terms of the Creative Commons Attribution-NonCommercial-ShareAlike 3.0 License, which allows others to remix, tweak, and build upon the work non-commercially, as long as the author is credited and the new creations are licensed under the identical terms.

For reprints contact: reprints@medknow.com

© 2017 Chinese Medical Journal | Produced by Wolters Kluwer - Medknow

Received: 04-04-2017 **Edited by:** Xin Chen

How to cite this article: Zhang LH, Tong H, Wei B, Wu H, Tang CW. Transjugular Intrahepatic Portosystemic Shunt as the Treatment for Refractory Hepatic Hydrothorax with Portal Vein Thrombosis. Chin Med J 2017;130:1999-2000.

Access this article online

Quick Response Code:



Website:
www.cmj.org

DOI:
10.4103/0366-6999.211887

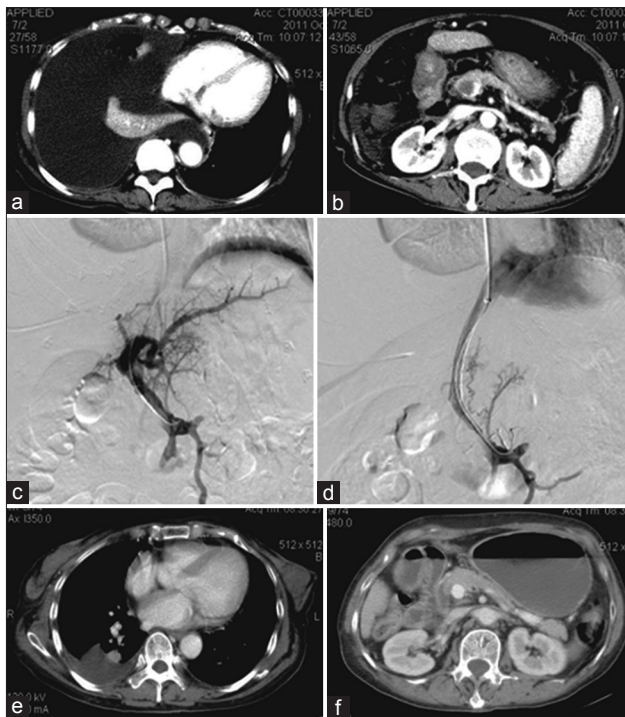


Figure 1: Preoperative contrast computed tomography demonstrated pleural fluid and thrombosis of the portal vein (a and b). (c) Before stent implantation, digital subtraction angiography showed that thrombus was observed in the main trunk and left branch of portal vein and the superior mesenteric vein. (d) A 10 mm × 50 mm covered stent was implanted. Follow-up computed tomography at the 4th month showed further regression of hydrothorax and portal vein thrombosis (e and f).

essential that the entire thrombus was covered with stent during TIPS procedure by which the turbulent flow in main trunk of portal vein was reduced.

In conclusion, TIPS may be indicated for the cirrhotic patient complicated with both RHH and PVT and may afford longer survival for those patients.

Declaration of patient consent

The authors certify that they have obtained all appropriate patient consent forms. In the form, the patient(s) has/have given his/her/their consent for his/her/their images and other clinical information to be reported in the journal. The patients understand that their names and initials will not be published and due efforts will be made to conceal their identity, but anonymity cannot be guaranteed.

Acknowledgments

The authors would like to thank Dr. Ting-Ting Qiu and Dr. Meng-Qi Zhou (Department of Ultrasound, West China Hospital) for helping us collect the information of the patient. The authors appreciate Dr. Nauman Malik (Schulich School of Medicine and Dentistry, Western University, London, Canada) for editing the language of this manuscript.

Financial support and sponsorship

This study was supported by grants from the National Natural Science Foundation of China (No. 81400637) and the Research Foundation for Residents of West China Hospital.

Conflicts of interest

There are no conflicts of interest.

REFERENCES

1. Badillo R, Rockey DC. Hepatic hydrothorax: Clinical features, management, and outcomes in 77 patients and review of the literature. *Medicine (Baltimore)* 2014;93:135-42. doi: 10.1097/MD.0000000000000025.
2. Sharma AM, Zhu D, Henry Z. Portal vein thrombosis: When to treat and how? *Vasc Med* 2016;21:61-9. doi: 10.1177/1358863X15611224.
3. Smith M, Durham J. Evolving indications for tips. *Tech Vasc Interv Radiol* 2016;19:36-41. doi: 10.1053/j.tvir.2016.01.004.
4. Qi X, Han G, Fan D. Management of portal vein thrombosis in liver cirrhosis. *Nat Rev Gastroenterol Hepatol* 2014;11:435-46. doi: 10.1038/nrgastro.2014.36.
5. Rössle M. TIPS: 25 years later. *J Hepatol* 2013;59:1081-93. doi: 10.1016/j.jhep.2013.06.014.