

Nonintubated Robotic-assisted Thoracic Surgery for Tracheal/Airway Resection and Reconstruction

Technique Description and Preliminary Results

Shuben Li, PhD,* Qing Ai, MD,* Hengrui Liang, MD,* Hui Liu, MD,† Chao Yang, MD,*
Hongsheng Deng, MD,* Yunpeng Zhong, MD,* Jie Zhang, MD,* and Jianxing He, MD, PhD, FACS*✉

Objective: We aim to report a novel surgical technique that RATS combined with nonintubated spontaneous ventilation to perform tracheal/airway surgery.

Summary of Background Data: Our team has demonstrated video-assisted transthoracic surgery can be used for thoracic tracheal diseases with satisfactory outcomes. Our team has also demonstrated that tracheal/airway resection and reconstruction under spontaneous ventilation can improve the anastomosis and operating time. Recently, RATS emerged as an available alternative minimally invasive approach for lung cancer, with lower perioperative mortality and conversion rate to open.

Methods: Five patients fulfilling the criteria for nonintubated approach underwent RATS tracheal/airway surgery. Patient 1 has a tumor in the thoracic trachea; patient 2 had involving secondary carina; patient 3 had involving trachea carina, and patient 4 had involving left main bronchus. Patient 5 had involving mid-tracheal.

Results: All patients had an uneventful procedure. The total operative time ranged from 5 hours 5 minutes to 9 hours 55 minutes. The postoperative hospital stays ranged from 4 days to 14 days. Fiber-optic bronchoscopy performed 1 month after the procedure showed good anastomotic healing with no stricture.

Conclusion: This is the first report on RATS use in tracheal/airway surgery, in combination with nonintubation spontaneous ventilation. In selected patients, this novel combined approach is feasible and safe. A patient can potentially benefit from the combined advantages of both techniques. More cases and longer-term data are required to establish its role in tracheal/airway surgery.

Keywords: nonintubated, robotic, surgery, trachea

(*Ann Surg* 2022;275:e534–e536)

Tracheal/airway surgery is traditionally performed via an open approach.^{1,2} Our team has demonstrated video-assisted transthoracic surgery (VATS) can be used for thoracic tracheal diseases with

satisfactory outcomes.³ Furthermore, our team has demonstrated that without muscle relaxant and tracheal intubation, tracheal/airway resection and reconstruction under spontaneous ventilation is also feasible and can improve the anastomosis and operating time.^{4,5} Recently, robotic-assisted thoracoscopic surgery (RATS) emerged as an available alternative minimally invasive approach for lung cancer, with lower perioperative mortality and conversion rate to open.⁶ However, RATS is rarely reported in the treatment of malignant tracheal tumors. In the current study, we report a novel technique of tracheal tumor resection and trachea reconstruction treated by RATS under nonintubated spontaneous ventilation.

CASE PRESENTATION

Five patients fulfilling the criteria for nonintubated surgery were selected for this novel approach. The 5 patients' average age is 42 years old (range 33 years old–59 years old). Patient 1 has a tumor in the thoracic trachea, causing a significant obstruction (Fig. 1A). Other tumor locations (Fig. 1B) were at the left secondary carina (patient 2), trachea carina (patient 3), left main bronchus (patient 4), mid-tracheal (patient 5). One patient (patient 3) underwent neoadjuvant targeted immunotherapy, using albumin-bound paclitaxel 400 mg D1 plus carboplatin 200 mg D2 plus sintilimab 200 mg D1 [q4w; 2 cycles].

ANESTHESIA MANAGEMENT

The anesthesia protocol for nonintubated spontaneous ventilation was described in detail elsewhere.⁵ Briefly, vital signs and bispectral index was monitored from beginning to the end of the anesthesia. Patients were anesthetized using intravenous anesthesia (Propofol + Remifentanyl + Sufentanal) and allowed to breathe spontaneously. No muscle relaxant was used. A laryngeal mask was used for assisting airway management.

SURGERY PROCESS AND OUTCOME

Depending on the tumor location, the patient was positioned either left or right lateral decubitus position; the 3-arms Da Vinci robotic surgical system was docked at 45-degree angle to the patient. Ports for the robotic arm were placed, as shown in Figure 1C. Bronchoscopy and fluoroscope were used to assist the localization of the tumor during the operation. The tumor was then excised with a clearance margin of 0.5 cm (patient 2, 4, 5) or 1 cm (patient 1, 3) from the tumor (Fig. 1D). After intraoperative frozen sections showed tumor invasion of the trachea resection margin is negative. The trachea was then anastomosed using a continuous PROLENE 2-0 suture, and the bronchus was using PROLENE 3-0 suture, followed by 3 MONOCRYL 4-0 intermittent suture for reinforcement (Fig. 1E and F) to avoid the risk of the continuing suture. The chest was closed with 1 chest drainage after confirming no bleeding and air leak.

From the *Department of Thoracic Surgery and Oncology, The First Affiliated Hospital of Guangzhou Medical University, State Key Laboratory of Respiratory Disease, National Clinical Research Center for Respiratory Disease, Guangzhou Institute of Respiratory Health, Guangzhou, China; and †Department of Anesthesia, The First Affiliated Hospital of Guangzhou Medical University, Guangzhou, China.

✉drjianxing.he@gmail.com

Author Contributions: (I) Conception and design: Shuben Li, Jianxing He; (II) Administrative support: Jianxing He; (III) Provision of study materials or patients: Jianxing He; (IV) Collection and assembly of data: Qing Ai, Hengrui Liang; (V) Data analysis and interpretation: Qing Ai, Hengrui Liang; (VI) Manuscript writing: All authors; (VII) Final approval of manuscript: All authors.

S.L., Q.A., and H.L. contributed equally to this work.

The authors report no conflicts of interest.

This is an open access article distributed under the terms of the Creative Commons Attribution-Non Commercial-No Derivatives License 4.0 (CCBY-NC-ND), where it is permissible to download and share the work provided it is properly cited. The work cannot be changed in any way or used commercially without permission from the journal.

Copyright © 2021 The Author(s). Published by Wolters Kluwer Health, Inc.

ISSN: 0003-4932/21/27502-e534

DOI: 10.1097/SLA.0000000000004887

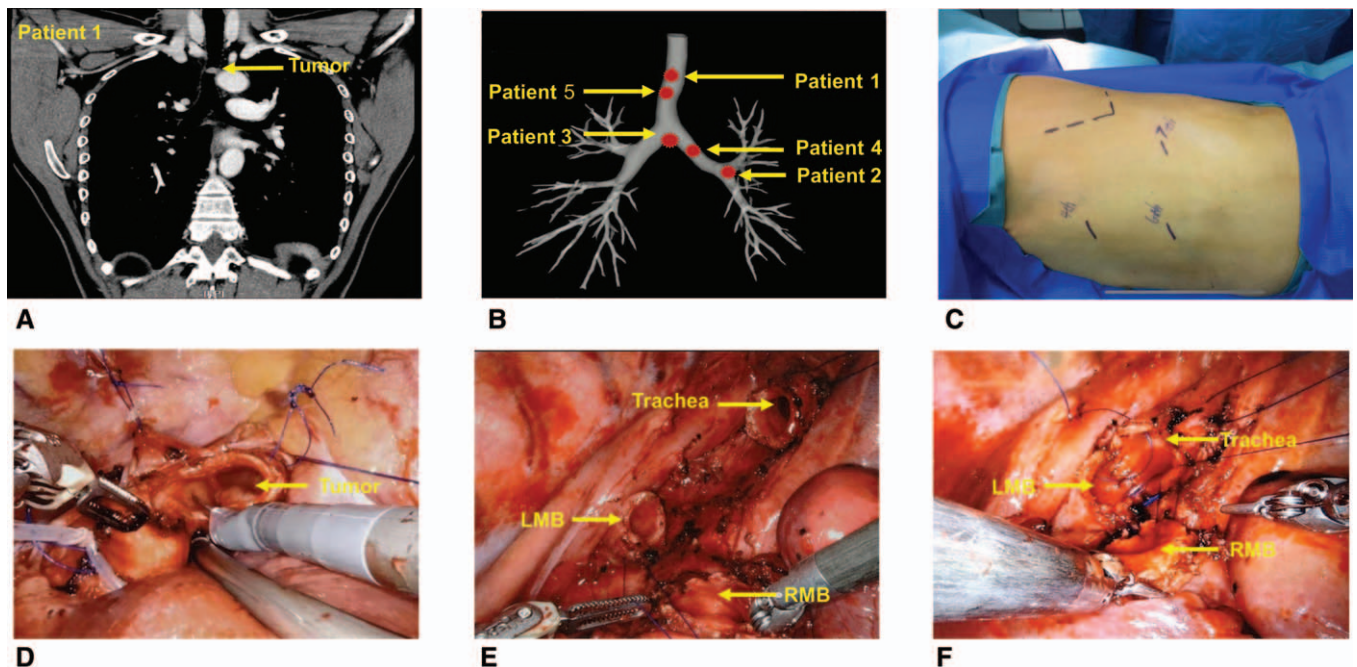


FIGURE 1. Preoperative images and surgical pictures. A, Preoperative CT image (patient 1); a 1.3 cm tumor located in the thoracic trachea causing a significant obstruction. B, A drawing of the tracheobronchial tree with all tumors located, Patient 1 has a tumor in the thoracic trachea. Others tumor location was at the left secondary carina (patient 2), trachea carina (patient 3), left main bronchus (patient 4), and mid-tracheal (patient 5). C, Second carinal reconstruction surgical approach (patient 2); the patient was placed in a right lateral decubitus position. The robotic thoracoscope port (1 cm) was made in the sixth intercostal space in the anterior axillary line. The main operation port (3 cm) was placed in the fourth intercostal space on the midaxillary line; the auxiliary operation port (1 cm) was made in the seventh intercostal space posterior axillary line. D, Full exposure of tumor site trachea (patient 3); the tumor was excised with a clearance margin of at least 0.5 cm from the tumor. E, Suturing the trachea and reconstruction carinal (patient 3); the airway was anastomosed using a continuous prolene suture. F, Suturing the posterior wall of the trachea and reconstructed carinal (patient 3). CT indicates computerized tomography; LMB, left main bronchus; RMB, right main bronchus.

The total preparation of the robotic system and operative time ranged from 5 hours 5 minutes to 9 hours 55 minutes, and the total blood loss ranges from 10 mL to 50 mL. Two patients' postoperative pathology showed mucoepidermoid carcinoma; the rest showed lymphoepithelioma-like carcinoma, adenoid cystic carcinoma, and squamous cell carcinoma, respectively. The average size of the tumor is 1.2 cm (range 0.9 cm–4.3 cm). The postoperative hospital stays ranged from 4 days to 14 days. All patients have no complications 1 month after the operation, and fiberoptic bronchoscopy reexamination showed good anastomotic healing and no anastomotic stenosis.

DISCUSSION

Franca et al⁷ first described their experience using the Da Vinci robotic system for thoracic surgery in 2002. Since then, the application of robotic surgical techniques has become increasingly widespread. We reported the initial experience on robotic surgery for nonintubated tracheal/airway resection and reconstruction, which has shown that this new surgical technique is feasible and can be performed safely within a reasonable time, comparing with the traditional VATS approach.

We have previously reported the technical benefits of nonintubated VATS in airway surgery over traditional endotracheal intubation VATS: it simplified airway surgery without the interference of endotracheal tube, reduces the unstable SpO₂ during surgery, allows better surgical field and airway anastomosis, thus reduces postoperative complications, and shorter hospital stay.⁴ These benefits were also maintained during the RATS approach

and potentially could enhance the benefit of RATS. It avoids the time loss associated with the repositioning of the robotic console during cross-field ventilation.

With the robotic arm's extra maneuverability, we found that the anastomosis suturing was relatively easier in RATS than the VATS approach under a similar nonintubation setting. Three-dimensional visualization also enhances the procedure's accuracy compared with VATS, compared with the routine 2-dimensional display. Prolene continuing suturing technique was applied, which was used in our previous report tracheal/airway series with good results,³ based on lung and trachea transplantation experiences.^{8,9} If interrupted sutures were used in the context of RATS, the robotic arm would need to be withdrawn frequently to reload the suture, thus increasing operating time.

When compared with the nonintubated VATS approach, several points need to be considered. Intraoperative mediastinal swing can be a life-threatening problem during surgery. This risk can be minimized by selecting the appropriate patients [male body mass index (BMI) <25, female BMI <23], satisfied vagus nerve block and tacit cooperation between surgeons and anesthesiologists. However, with increased experience, the restriction of BMI can be relaxed to 30.¹⁰ In addition, suppose a drop in oxygenation does not improve with continuous positive airway pressure or high-frequency jet ventilation. In that case, it may be more difficult to intubate the patient because of the robot console. Besides, 2 assistants were required during nonintubated RATS tracheal surgery, 1 assist the surgeon, and the other helps to clean the surgical field with a suction.

In conclusion, robotic-assisted thoracic surgery for tracheal/carinal/airway surgery under nonintubated spontaneous ventilation is feasible in carefully selected patients at the preliminary practice. However, more data is needed to establish its future role in this field.

ACKNOWLEDGMENTS

The authors thank Dr. Keng-Leong Ang for assisting with the language editing. The authors thank Dr. Ke Xu for assisting in drawing Figure 1B.

REFERENCES

1. Regnard JF, Fourquier P, Levasseur P. Results and prognostic factors in resections of primary tracheal tumors: a multicenter retrospective study. The French Society of Cardiovascular Surgery. *J Thorac Cardiovasc Surg.* 1996;111:808–813.
2. Grillo HC. Development of tracheal surgery: a historical review. Part 1: techniques of tracheal surgery. *Ann Thorac Surg.* 2003;75:610–619.
3. Li J, Wang W, Jiang L, et al. Video-assisted thoracic surgery resection and reconstruction of carina and trachea for malignant or benign disease in 12 patients: three Centers' experience in China. *Ann Thorac Surg.* 2016;102:295–303.
4. Jiang L, Liu J, Gonzalez-Rivas D, et al. Thoracoscopic surgery for tracheal and carinal resection and reconstruction under spontaneous ventilation. *J Thorac Cardiovasc Surg.* 2018;155:2746–2754.
5. Liang H, Gonzalez-Rivas D, Zhou Y, et al. Nonintubated anesthesia for tracheal/carinal resection and reconstruction. *Thorac Surg Clin.* 2020;30:83–90.
6. Liang H, Liang W, Zhao L, et al. Robotic versus video-assisted lobectomy/segmentectomy for lung cancer: a meta-analysis. *Ann Surg.* 2018;268:254–259.
7. Melfi FMA, Menconi GF, Mariani AM, et al. Early experience with robotic technology for thoracoscopic surgery. *Eur J Cardiothorac Surg.* 2002;21:864–868.
8. Aigner C, Jaksch P, Seebacher G, et al. Single running suture—the new standard technique for bronchial anastomoses in lung transplantation. *Eur J Cardiothorac Surg.* 2003;23:488–493.
9. He J, Liang S, Yang Y, et al. Tracheal transplantation. *Zhonghua Wai Ke Za Zhi [Chin J Surg].* 2000;38:595–597.
10. Wu D, Liang H, Liang W, et al. Spontaneous ventilation video-assisted thoracoscopic surgery for patients with non-small-cell lung cancer with excess body weight. *Eur J Cardiothorac Surg.* 2020;58:605–612.