



Protection of Surgical Team from COVID-19 during Bipolar Hemiarthroplasty in an Infected Elderly Patient

Sang Hyun Um, MD, Du-Han Kim, MD, Moon-Yul Youn, MD, Chul-Hyun Cho, MD, Hyun-Ah Kim, MD*, Byung-Woo Min, MD, Ki-Cheor Bae, MD, Kyung-Jae Lee, MD

*Department of Orthopaedic Surgery, *Division of Infectious Disease, Department of Internal Medicine, Keimyung University Dongsan Hospital, Keimyung University School of Medicine, Daegu, Korea*

The novel coronavirus disease 2019 (COVID-19), which began in Wuhan, China, has rapidly flared up all over the world, evolving into a pandemic. During these critical times, we should give emphasis on infection prevention for the health care staff as well as appropriate patient management in order to maintain the health care system. We report our experience in protecting a surgical team from COVID-19 infection during a bipolar hemiarthroplasty in an infected patient. This case highlights the importance of appropriate protection of the health care staff and education in minimizing the risk of transmission of the infection and maintaining the health care system.

Keywords: COVID-19, Personal protective equipment, Orthopedics, Protection of surgical team, Femur neck fracture

In December 2019, the People's Republic of China reported a cluster of patients with pneumonia of unknown cause in Wuhan, Hubei Province.¹⁾ The name of this disease, coronavirus disease 2019 (COVID-19), was announced by the World Health Organization on February 11, 2020, and a pandemic was formally declared on March 11, 2020.²⁾ Since epidemiologic data indicated that person-to-person transmission of COVID-19 could be occurring,³⁾ COVID-19 has rapidly spread to the entire world with an increasing transmission risk within the community and hospital. Although some institutions have released guidelines for restructuring the trauma and orthopedic service to minimize their patients' and staff's exposure to COVID-19,⁴⁾ there is an increasing risk of infection

transmission to some patients during these critical times. Furthermore, there is little existent knowledge on the preparation of the operating room (OR) for a COVID-19 patient and on the protection of the surgical team to help in the prevention of a collapse of the health system.²⁾ Herein, we present our experience in protecting a surgical team during a bipolar hemiarthroplasty in a patient with COVID-19.

CASE REPORT

The clinical practice protocol was reviewed and approved by the Institutional Review Board of Keimyung University Dongsan Hospital (No. 2020-04-080-001). The patient was informed that this case would be submitted for publication.

Hospital Course of the Patient

On March 25, 2020, an 86-year-old male patient was referred to our emergency care clinic for an operation of a right femoral neck fracture. He sustained a slip and fall injury on March 20, 2020, while being admitted to a skilled nursing facility in Daegu, Korea. The patient had

Received July 13, 2020; Accepted July 23, 2020

Correspondence to: Kyung-Jae Lee, MD

Department of Orthopaedic Surgery, Keimyung University Dongsan Hospital, Keimyung University School of Medicine, 1035 Dalgubeol-daero, Dalseo-gu, Daegu 42601, Korea

Tel: +82-53-258-7925, Fax: +82-53-258-4773

E-mail: oslee@dsmc.or.kr

The first two authors contributed equally to this article as first authors.

Copyright © 2020 by The Korean Orthopaedic Association

This is an Open Access article distributed under the terms of the Creative Commons Attribution Non-Commercial License (<http://creativecommons.org/licenses/by-nc/4.0>) which permits unrestricted non-commercial use, distribution, and reproduction in any medium, provided the original work is properly cited.

Clinics in Orthopedic Surgery • pISSN 2005-291X eISSN 2005-4408

diabetes mellitus, chronic obstructive pulmonary disease, and Alzheimer's dementia and was only capable of indoor activities before the injury. After the fall, the patient complained of right hip pain, but no radiological examination was done. Since February 18, 2020, there has been a rapid increase in the number of confirmed cases of COVID-19 in the Daegu region and cases of mass infection occurred in that facility. Nasopharyngeal swabs for COVID-19 detection were performed on all hospitalized personnel. The patient was confirmed positive for COVID-19 one day after the fall. He was transferred to a local COVID-19 treatment-designated hospital and was diagnosed with a right femoral neck fracture. However, the hospital was not prepared to perform orthopedic surgery for patients with COVID-19.

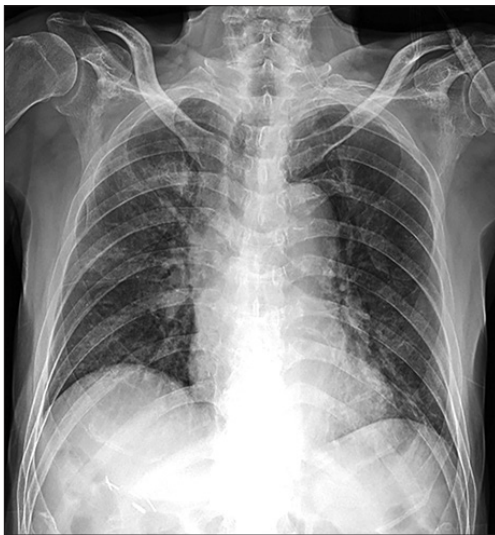

Fig. 1. Anteroposterior chest radiograph obtained on March 26, 2020 (hospital day 1), showing diffuse peribronchial infiltration in the parenchyma of both lungs.

Therefore, the patient was transferred to our hospital for COVID-19 management and orthopedic surgery. From March 26, 2020, one day after hospitalization, he had a fever above 38° Celsius, and radiological signs of pneumonia were observed in chest radiography (Fig. 1). COVID-19 medical management was continued for 2.5 weeks until a normal body temperature was achieved and signs of pneumonia were improved. However, the COVID-19 tests, conducted on April 8 and April 14, were both positive and he remained infectious. The orthopedic surgical team needed to devise a plan for protecting the surgical team from COVID-19 and performing the patient's surgery.

METHODS

Preoperative Preparation

Prior to the surgery, the hospital infection control department checked 3 factors: (1) Transportation: patient transport method, the number of staff required, and the route from the ward to the OR to minimize contact with other hospitalized patients. (2) OR: the number of required rooms, the required number of surgical staff including the surgeons, nurses, and anesthesiologists, and preparation to prevent contamination of other equipment in the OR. (3) Education: how to wear and remove the personal protective equipment (PPE).

Preparation of OR

Three serial negative-pressure ORs were prepared and designated as the "preparation room," "operating room," and "undressing room" (Fig. 2). One day before the index surgery, all unnecessary equipment was moved elsewhere and all other equipment in these rooms was covered with a transparent cover to protect from virus droplets (Fig. 3). In addition, specific signs were placed at the door of each room to guide staff entry and exit. Once they left a room,

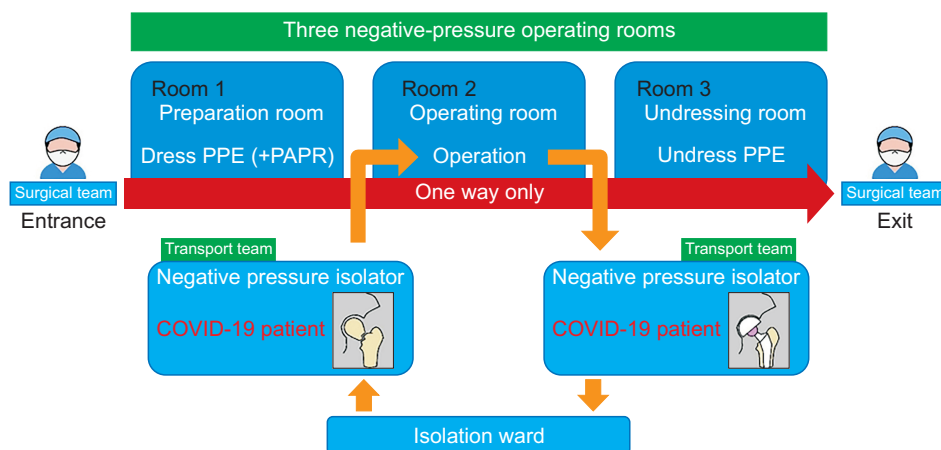


Fig. 2. Schematic diagram of the operating room layout, the surgical team flow, and transport team pathway. PPE: personal protective equipment, PAPR: powered air-purifying respirator.




Fig. 3. The day before the index surgery, all unnecessary equipment was moved elsewhere and all other equipment in the room was covered with a transparent cover to protect it from virus droplets.



Fig. 4. In the preparation room, all surgical staff wore waterproof, full-body, protective clothing including boots and a powered air-purifying respirator system, which drew clean air through a high-efficiency particulate air filter was used to ease breathing. (A) Front view. (B) Lateral view.

they were not allowed in again.

In the preparation room, all surgical staff (orthopedic surgeons, nurses, anesthesiologists, and other supporting personnel) entered already wearing their disposable surgical scrub suit after surgical hand preparation with water and chlorhexidine soap. Then, they wore waterproof full-body protective clothing including boots. A powered air-purifying respirator system, which drew clean air through a high-efficiency particulate air filter, was used to ease breathing (Fig. 4).

In the OR, the surgical staff received the patient and performed anesthesia when the patient was brought into



Fig. 5. After appropriate patient positioning, additional surgical hand preparation was performed over personal protective equipment with the use of a sensor-activated surgical hand disinfectant dispenser (isopropanol 65%, N-propyl alcohol 15%, and polyhexamethylene).

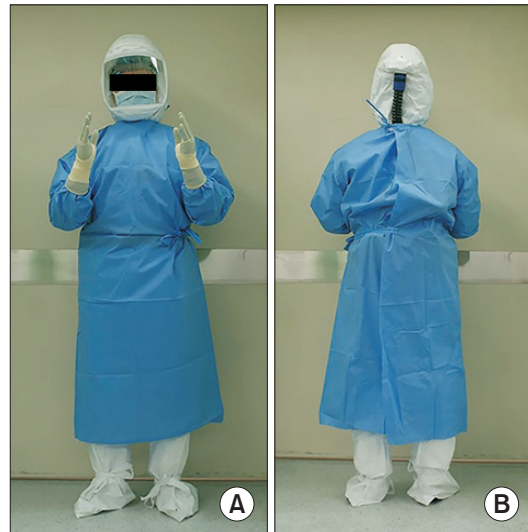

Fig. 6. After surgical hand scrubbing, a surgical gown and additional gloves were worn for the index surgery. (A) Front view. (B) Back view.

the OR in a negative-pressure carrier isolator accompanied by the transport team. Spinal anesthesia was performed to prevent contamination of the anesthesia equipment and patient aggravation. After appropriate positioning, additional surgical hand preparation was performed over PPE with the use of a sensor-activated surgical hand disinfectant dispenser (isopropanol 65%, N-propyl alcohol 15%, and polyhexamethylene) (Fig. 5). Then, a surgical gown and additional gloves were worn (Fig. 6). After operation, the surgical staff transferred the patient to the transport

team and sequentially exited the OR. In the undressing room, the surgical staff removed all PPE under the supervision of the supporting personnel from the hospital infection control department. After all protective clothing was removed, all the staff left the OR with masks (N95) on and access to all three ORs was restricted for 48 hours for disinfection.

Although the patient's physical examination revealed hypothermia (35.7°C) and hypotension (95/57 mmHg) in the immediate postoperative period, his vital signs were stabilized on postoperative day 1 (body temperature, 36.9°C; blood pressure, 110/60 mmHg; pulse, 89 beats per minute; respiratory rate, 18 breaths per minute; and oxygen saturation, 98% while the patient was breathing ambient air) and a chest radiograph did not show aggravated signs of pneumonia.

Postoperative rehabilitation was started on postoperative day 1. A walker necessary for ambulation practice was prepared in an isolated room before surgery. The patient could not go to the physical therapy room of the hospital unlike other patients who were not infected with COVID-19, so we prepared a rehabilitation training instruction sheet, which he could easily see and understand. Twice a day, using a monitor and microphone outside the isolation room, a designated orthopedic nurse educated the patient on rehabilitation exercises and monitored the progress. The patient's rehabilitation started with ankle dorsiflexion and quadriceps exercises, followed by straight leg raise exercises, which lasted for approximately 4 days. Since standing and walker-assisted ambulation training may cause a fall, the nurse wore PPE and helped with training at the time when the patient needed to stand and walk to fill his prescription in order to minimize the time of contact with the patient. One week later, he was able to walk freely inside the isolation room using a walker.

RESULTS

Presently, the patient can sit on a wheelchair and is undergoing physiotherapy (walking with a walker) in the isolated negative-pressure room. This has also helped him to recover from pneumonia. None of the surgical and supporting staff tested positive for COVID-19 at postoperative 2 weeks.

DISCUSSION

One of the most important things in this pandemic situation is to prevent the health system from collapsing due to medical staff infection. For this reason, many organiza-

tions recommend avoiding situations that can cause exposure between the medical staff and patients. For example, the British Association of Oral and Maxillofacial Surgeons strongly recommends avoiding unnecessary contact and surgery because their workspace is in a high aerosol-generating area.⁵⁾ Other COVID-19 prevention guidelines specific to orthopedic surgeons have been released. The guidelines of emergency British Orthopedic Association Standards for Trauma and Orthopedics were released on March 24, 2020, which provide recommendations on how to manage urgent orthopedic patients during the COVID-19 pandemic.⁴⁾ They recommend that upper limb fractures should be treated nonoperatively. Penetrating injury without contamination or neurologic deficit, and abscesses should be managed in the emergency department under local anesthesia. In the British Orthopedic Association's guidelines, they recommended that surgical decisions must consider both the best interests of the patient and up-to-date knowledge of the locally available medical resources.⁶⁾

However, patients who cannot avoid surgery such as those with trauma or malignant neoplasms keep showing up. Furthermore, most hip fractures occur at home, and the social isolation policy will not prevent such fractures. According to a study by Morgan et al.⁴⁾, the prevalence of trauma in older people, such as femoral neck fractures, is likely to remain the same, although major trauma patients have been reduced by 50%. Orthopedic literature has confirmed the advantages of early treatment of proximal femoral fractures in the elderly.^{7,8)} Catellani et al.⁷⁾ reported the stabilization of respiratory parameters in 12 COVID-19-positive patients who underwent surgical treatment of proximal femoral fractures, and concluded that surgery might contribute to the overall stability of the patients, seated mobilization, improvement in physiological ventilation, and general patient comfort in bed. For these reasons, orthopedic associations recommend that surgical treatment is still needed for limb-threatening injury or lower limb fragility fractures.^{4,6,9)} Moreover, avoiding surgery can also cause a disruption in the residency programs due to a prolonged COVID-19 situation.¹⁰⁾

To the best of our knowledge, there are currently few reports concerning the surgical team and OR preparation for orthopedic surgery in patients with COVID-19.^{2,9)} Rodrigues et al.²⁾ reported on the protocol developed at their institution for treating trauma patients. In their specific scenario, the operative complex was divided into 5 zones. In zone 1 (the entry dressing room), the surgical staff should don a disposable surgical suit, after which appropriate surgical hand preparation should be performed.

In zone 2 (the anteroom), wearing a lead garment is the first act. Surgical hand scrubbing with an aqueous alcohol solution should be performed, and the first pair of surgical gloves should be put on. Next, a sterile, disposable, reinforced surgical gown, followed by the second pair of gloves and surgical sleeve protectors should be put on. Zone 3 is the OR. At the end of the surgical procedure, and while still in zone 3, the surgeon should remove the gloves, the sleeve protectors, surgical mask, hair cap, and gown. In zone 4 (exit room), PPE removal is sequentially performed. Finally, the surgical staff should remove the scrub and bathe in zone 5 (exit dressing room). We operated the COVID-19 patient safely using 3 negative-pressure ORs according to the condition of our hospital. Because each hospital has a different OR environment, it will be useful for other institutions to report their COVID-19 safety protocols.

We reported our experience in protecting the surgi-

cal team from COVID-19 during a bipolar hemiarthroplasty in an infected elderly patient. This case highlights that proper protection of health care staff and appropriate education are important to minimize their infection with COVID-19 and prevent a collapse of the health care system.

CONFLICT OF INTEREST

No potential conflict of interest relevant to this article was reported.

ACKNOWLEDGEMENTS

The authors thank the member of hospital infection control department, Gi-Hyun Nam, and operating nurses (Keimyung University Dongsan Hospital) for their efforts in preparation and education during the index surgery.

REFERENCES

1. Zhu N, Zhang D, Wang W, et al. A Novel Coronavirus from Patients with Pneumonia in China, 2019. *N Engl J Med.* 2020;382(8):727-33.
2. Rodrigues-Pinto R, Sousa R, Oliveira A. Preparing to perform trauma and orthopaedic surgery on patients with COVID-19. *J Bone Joint Surg Am.* 2020;102(11):946-50.
3. Chan JF, Yuan S, Kok KH, et al. A familial cluster of pneumonia associated with the 2019 novel coronavirus indicating person-to-person transmission: a study of a family cluster. *Lancet.* 2020;395(10223):514-23.
4. Morgan C, Ahluwalia AK, Aframian A, Li L, Sun SN. The impact of the novel coronavirus on trauma and orthopaedics in the UK. *Br J Hosp Med (Lond)* 2020;81(4):1-6.
5. Ashford RU, Nichols JS, Mangwani J. Annotation: The COVID-19 pandemic and clinical orthopaedic and trauma surgery. *J Clin Orthop Trauma.* 2020;11(3):504-5.
6. British Orthopaedic Association. Clinical guide for the perioperative care of people with fragility fractures during the coronavirus pandemic [Internet]. London: British Orthopaedic Association [cited 2020 Mar 24]. Available from: <http://www.boa.ac.uk/standards-guidance/clinical-guide-for-the-perioperative-care.html>.
7. Catellani F, Coscione A, D'Ambrosi R, Usai L, Roscitano C, Fiorentino G. Treatment of proximal femoral fragility fractures in patients with COVID-19 during the SARS-CoV-2 outbreak in Northern Italy. *J Bone Joint Surg Am.* 2020;102(12):e58.
8. Merloz P. Optimization of perioperative management of proximal femoral fracture in the elderly. *Orthop Traumatol Surg Res.* 2018;104(1S):S25-30.
9. Coimbra R, Edwards S, Kurihara H, et al. European Society of Trauma and Emergency Surgery (ESTES) recommendations for trauma and emergency surgery preparation during times of COVID-19 infection. *Eur J Trauma Emerg Surg.* 2020;46(3):505-10.
10. Chang Liang Z, Wang W, Murphy D, Po Hui JH. Novel Coronavirus and orthopaedic surgery: early experiences from Singapore. *J Bone Joint Surg Am.* 2020;102(9):745-9.