

# Transhepatic hilar approach for Bismuth types III and IV perihilar cholangiocarcinoma with long-term outcomes

Journal of International Medical Research

49(5) 1–12

© The Author(s) 2021

Article reuse guidelines:

[sagepub.com/journals-permissions](https://sagepub.com/journals-permissions)

DOI: 10.1177/03000605211008336

[journals.sagepub.com/home/imr](https://journals.sagepub.com/home/imr)



Xinsen Xu\* , Linhua Yang\*, Wei Chen\* and Min He

## Abstract

**Objective:** To compare the outcomes of the transhepatic hilar approach and conventional approach for surgical treatment of Bismuth types III and IV perihilar cholangiocarcinoma.

**Methods:** We retrospectively reviewed the medical records of 82 patients who underwent surgical resection of Bismuth types III and IV perihilar cholangiocarcinoma from 2008 to 2016. The transhepatic hilar approach and conventional approach was used in 36 (43.9%) and 46 (56.1%) patients, respectively. Postoperative complications and overall survival were compared between the two approaches.

**Results:** Similar clinical features were observed between the patients treated by the conventional approach and those treated by the transhepatic hilar approach. The transhepatic hilar approach was associated with less intraoperative bleeding and a lower percentage of Clavien grade 0 to II complications than the conventional approach. However, the transhepatic hilar approach was associated with a higher R0 resection rate and better overall survival. Multivariate analysis showed that using the transhepatic hilar approach, the Memorial Sloan-Kettering Cancer Center classification, and R0 resection were independent risk factors for patient survival.

**Conclusion:** The transhepatic hilar approach might be the better choice for surgical resection of Bismuth types III and IV perihilar cholangiocarcinoma because it is associated with lower mortality and improved survival.

\*These authors contributed equally to this work.

### Corresponding author:

Min He, Department of Biliary-Pancreatic Surgery, Renji Hospital, School of Medicine, Shanghai Jiao Tong University, 160 Pujian Road, Pudong District, Shanghai 200127, P.R. China.

Email: [shirley0815@126.com](mailto:shirley0815@126.com)

Department of Biliary-Pancreatic Surgery, Renji Hospital, School of Medicine, Shanghai Jiao Tong University, Shanghai, P.R. China



Creative Commons Non Commercial CC BY-NC: This article is distributed under the terms of the Creative Commons Attribution-NonCommercial 4.0 License (<https://creativecommons.org/licenses/by-nc/4.0/>) which permits non-commercial use, reproduction and distribution of the work without further permission provided the original work is attributed as specified on the SAGE and Open Access pages (<https://us.sagepub.com/en-us/nam/open-access-at-sage>).

## Keywords

Perihilar cholangiocarcinoma, transhepatic hilar approach, Bismuth, survival, complication, surgical resection

Date received: 9 March 2021; accepted: 12 March 2021

## Introduction

Perihilar cholangiocarcinoma, also known as a Klatskin tumor, is a common malignant tumor of the biliary system. Because of the extensive ductal spread of this tumor from the hepatic hilum to the lower bile duct and its close relationship with portal vessels, surgical treatment using the conventional approach usually cannot achieve R0 resection.<sup>1</sup> Several attempts have been made to achieve a higher R0 resection rate. Takasaki et al.<sup>2</sup> first introduced the anterior approach in 1984, and Liu and Fan<sup>3</sup> applied the anterior approach to perihilar cholangiocarcinoma. They first transected the common bile duct and right hepatic artery and then transected the liver without prior mobilization of the right lobe and caudate lobe. This anterior approach was useful when rotation of the right liver lobe was difficult because of the tumor size or tumor infiltration into surrounding structures; it avoided excessive bleeding, tumor rupture, compression of the remnant liver parenchyma, and dissemination of tumor cells into the circulation.<sup>4,5</sup> Similarly, the liver parenchyma transection-first approach advocated by Kawabata et al.<sup>6</sup> is also an anterior approach. It involves transection of the hepatic parenchyma without mobilization of the liver, using a modified liver-hanging maneuver. Before hepatic parenchymal dissection, the authors dissected the branches of the hepatic artery and portal vein at the hepatic hilum. In the present study, we adopted the transhepatic hilar approach advocated

by Kuriyama et al.,<sup>7</sup> in which hepatic parenchymal transection is first performed to expose the proximal bile duct, presenting a wider surgical view to fully expose the hilar bile duct for safe R0 resection and vascular resection and reconstruction. No ducts or vessels are transected until the last stage. This surgical technique may be particularly useful and practicable for treatment of advanced cholangiocarcinoma such as Bismuth types III and IV. However, there is no consensus on the survival benefit of this approach because the number of patients who have undergone this approach is limited, and no definite long-term outcomes have been obtained.<sup>7,8</sup>

In this study, we retrospectively analyzed the survival outcomes of 77 consecutive patients with Bismuth types III and IV perihilar cholangiocarcinoma who underwent surgical resection using either the transhepatic hilar approach or conventional approach. The aim of this study was to assess the clinical value of the transhepatic hilar approach for surgical resection of perihilar cholangiocarcinoma.

## Patients and methods

### Patients

This study involved 82 consecutive patients with Bismuth types III and IV perihilar cholangiocarcinoma who underwent surgical resection at Renji Hospital from 2008 to March 2016. The study was approved by the Renji Hospital Ethics Committee,

Shanghai Jiaotong University School of Medicine in November 2019 (ethics approval no. 2018-076). Verbal informed consent for treatment was obtained from all patients. The work was carried out according to the Code of Ethics of the World Medical Association (Declaration of Helsinki). The study was conducted following the STROBE guideline. All patient details were de-identified. The 82 patients comprised 46 men and 36 women with a median age of 64.2 years and body mass index of 21.2 kg/m<sup>2</sup>. The average serum total bilirubin concentration was 75.1 mg/dL, and 81.7% of the patients presented with jaundice at the initial evaluation.

### *Preoperative assessment*

Before surgery, 4 patients underwent endoscopic biliary drainage and 19 patients underwent percutaneous biliary drainage. Contrast-enhanced computed tomography (CT) and ultrasonography were routinely performed for tumor imaging. Other imaging approaches, including magnetic resonance imaging (MRI), positron emission tomography–CT, cholangiography, and cholangioscopy, were selected when necessary.

### *Surgical procedures*

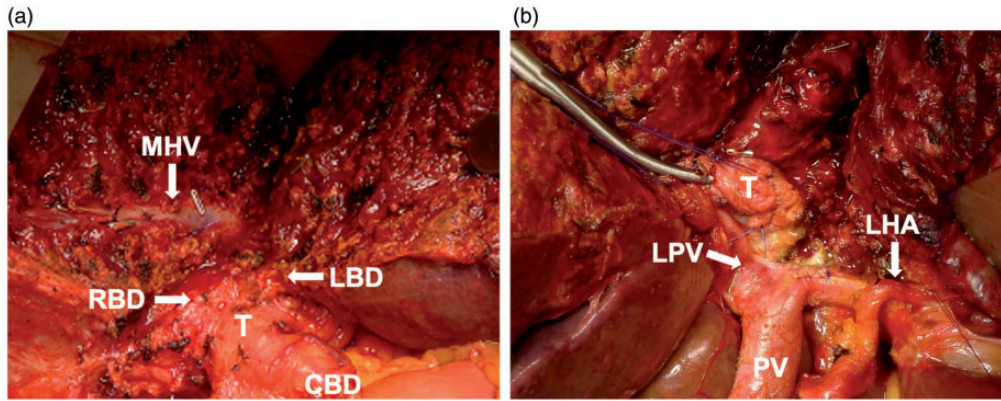
Two approaches were adopted for surgical resection of cholangiocarcinoma: the conventional approach and the transhepatic hilar approach. Judgment of tumor resectability during surgery was performed as previously described.<sup>9,10</sup>

When the tumor in patients undergoing the conventional approach was mostly right-sided, the left hepatic duct and left portal vein were dissected at the base of the falciform ligament. Exposure of an uninvolved hepatic duct and portal vein at segments 2 and 3 might permit the resection. When the tumor was mostly

left-sided, tumor extension to segments 6 and 7 was assessed by dissection along the posterior aspect of the right portal pedicle with the help of manual palpation and intraoperative ultrasound.

Once the resectability was determined, the hepatic artery was dissected, ensuring a blood supply to the remnant liver. At the level of the pancreas, the common bile duct was divided and reflected superiorly. Lymphadenectomy was performed for all lymph nodes of the celiac axis, common hepatic artery, and hepatoduodenal ligament. Caudate lobectomy was routinely performed. For type III and some type IV perihilar cholangiocarcinomas, an (extended) left or right hepatectomy was used. Some type IV perihilar cholangiocarcinomas were also treated by left or right trisectionectomy. Frozen pathology of the distal bile duct margin was used to guide resection. If the margin was positive or the tumor invaded the infraduodenal part of the common bile duct, pancreaticoduodenectomy was also considered. The cut margin of the hepatic bile duct was assessed at the last stage. Roux-en-Y biliary reconstruction with an isoperistaltic 60-cm limb of jejunum was performed to ensure biliary continuity.

When the margin status was judged to be high-risk, difficult, or impossible before hepatectomy, using the transhepatic hilar approach was determined by the surgeon before laparotomy. After laparotomy, the hepatic parenchyma was transected toward the hepatic hilum to visualize the hilar plate. The hepatic artery, portal vein, and bile duct of the remnant liver were subsequently exposed (Figure 1). The hepatic bile duct was transected until a cancer-negative margin was obtained. Skeletonization of the hepatoduodenal ligament was then performed. Before transection of the remnant liver, the hepatic artery and portal vein of the planned resected liver were divided. Finally, the residual hepatic



**Figure 1.** Right hepatectomy for perihilar cholangiocarcinoma using the transhepatic hilar approach. (a) After hepatic transection to the root of the anterior Glisson sheath, the middle hepatic vein (MHV) was preserved on the side of the planned remnant liver. The tumor (T), proximal right bile duct (RBD), and left bile duct (LBD) were exposed. The proximal bile ducts and common bile duct (CBD) were easily evaluated to ensure a tumor-negative margin first. (b) The tumor (T) was found to have invaded the left portal artery (LHA) after exposure of the hepatic artery and portal vein (PV). After partial hepatectomy, left portal vein (LPV) resection and reconstruction were easily performed under the wide surgical view.

parenchyma was transected along with the caudate lobe. When the portal vein of the remnant side was involved by the tumor, the liver resection and portal vein reconstruction could be performed under a wider surgical view. No patients in our study underwent hepatic artery reconstruction. All portal vein reconstructions were end-to-end venous anastomosis, and no graft was used in these patients.

Indications for unresectability included bilateral hepatic duct involvement up to the secondary biliary radicles, vessel involvement of the remnant liver that could not be reconstructed, insufficient remnant liver volume, and metastasis. Palliative surgery (laparotomy plus biopsy) was performed for patients with unresectable tumors.

#### *Follow-up and statistical analysis*

Data are expressed as median (range). Comparisons between the two approaches were based on Student's *t* test and the  $\chi^2$  test for continuous data and categorical

data, respectively. Hospital death was defined as death occurring after liver resection but before hospital discharge. Patient survival was defined as the time from surgical treatment to death. No patients were lost to follow-up (May 2017). Survival curves were constructed using the Kaplan–Meier method and compared using the log-rank test. Multivariate regression analysis was conducted to identify prognostic factors. All analyses were performed with PASW Statistics for Windows, Version 18.0 (SPSS Inc., Chicago, IL, USA).

## **Results**

### *Patient characteristics*

The transhepatic hilar approach and conventional approach were used in 36 (43.9%) and 46 (56.1%) patients, respectively. The patient characteristics and clinicopathological features are shown in Table 1. There were no significant differences in age, sex, or serum markers between the two groups. There were also no

**Table 1.** Clinicopathologic and intraoperative characteristics.

	Conventional approach (n = 46)	Transhepatic hilar approach (n = 36)	P
Age, years	64.2 (42–79)	64.1 (31–83)	0.956
Sex, male/female	23/23 (50%/50%)	23/13 (64%/36%)	0.208
Serum CA19-9, U/L	506.3 (0.42–2060)	792.1.3 (0.6–5749.0)	0.282
Serum albumin, g/L	34.7 (22.2–47.0)	37.1 (19.9–47.8)	0.071
ALT, U/L	117.6 (25.0–577.0)	113.1 (11.0–413.0)	0.868
AST, U/L	106.1 (25.0–478.0)	72.0 (16.0–318.0)	0.119
Serum total bilirubin, $\mu\text{mol/L}$	81.3 (12.5–188.2)	63.0 (9.3–150.6)	0.260
Preoperative biliary drainage			0.015
Yes/No	8/38 (17%/83%)	15/21 (42%/58%)	
Bismuth type			0.283
III/IV	24/22 (52%/48%)	16/20 (44%/56%)	
Hepatic artery invasion			0.100
Yes/No	21/25 (46%/54%)	23/13 (64%/36%)	
Portal vein invasion			0.522
Yes/No	21/25 (46%/54%)	19/17 (53%/47%)	
TNM stage			0.115
I/II/III/IV	2/10/13/21 (4%/22%/28%/46%)	0/10/16/10 (0%/28%/44%/28%)	
T stage			0.089
T1/2/3/4	1/10/14/21 (2%/22%/30%/46%)	1/6/20/9 (3%/17%/55%/25%)	
N stage			0.632
pN0/1	27/19 (59%/41%)	23/13 (64%/36%)	
M stage			0.860
pM0/1	45/1 (98%/2%)	35/1 (97%/3%)	
MSKCC classification			0.066
pT1/2/3	15/12/19 (33%/26%/41%)	6/14/16 (17%/39%/44%)	
Combined vascular resection			0.150
Yes/No	14/32 (30%/70%)	6/30 (17%/83%)	
Operation time, minutes	321.3 (100–780)	430.4 (140–840)	0.003
Operative blood loss, mL	824.4 (100–3000)	382.1 (100–2300)	0.001
R0 resection			0.016
Yes/No	27/19 (59%/41%)	30/6 (83%/17%)	

Data are expressed as number (percentage) or median (range).

CA19-9, carbohydrate antigen 19-9; ALT, alanine aminotransferase; AST, aspartate aminotransferase; MSKCC, Memorial Sloan-Kettering Cancer Center.

significant differences in pathologic data, namely the Bismuth type, TNM stage, Memorial Sloan-Kettering Cancer Center (MSKCC) classification, or percentage of hepatic artery invasion or portal vein invasion. The percentage of patients who underwent biliary drainage before surgery was significantly higher in the transhepatic hilar approach group ( $P = 0.015$ ).<sup>9,11,12</sup>

### Operative procedures and intraoperative parameters

The surgical data are also provided in Tables 1 and 2. The surgical duration of the transhepatic hilar approach was significantly longer than that of the conventional approach (430.4 vs. 321.3 minutes, respectively;  $P = 0.003$ ). However, although the

**Table 2.** Surgical procedures performed.

	Conventional approach (n = 46)	Transhepatic hilar approach (n = 36)
Hepatectomy	36 (78%)	32 (89%)
S1, 5, 6, 7, 8	17 (37%)	17 (47%)
S1, 4, 5, 6, 7, 8	1 (2%)	4 (11%)
S1, 2, 3, 4	18 (39%)	11 (31%)
Hepatopancreatoduodenectomy	1 (2%)	0 (0%)
Palliative	9 (20%)	4 (11%)

Data are expressed as number (percentage).

**Table 3.** Complications and in-hospital mortality.

	Conventional approach (n = 46)	Transhepatic hilar approach (n = 36)	P
Clavien 0-II	24 (52%)	10 (28%)	0.003
Bile leakage (grade A or B)*	6 (13%)	3 (8%)	
Wound infection	4 (8%)	2 (6%)	
Delayed gastric emptying	5 (11%)	2 (6%)	
Intra-abdominal bleeding	1 (2%)	0 (0%)	
Gastrointestinal bleeding	3 (7%)	2 (6%)	
Pneumonia	2 (4%)	1 (3%)	
Azotemia	3 (7%)	1 (3%)	
Clavien III/IV	5 (11%)	4 (11%)	0.972
Bile leakage (grade C)*	3 (7%)	3 (8%)	
Liver failure	2 (4%)	1 (3%)	
Acute respiratory distress syndrome	1 (2%)	0 (0%)	
Intra-abdominal bleeding	2 (4%)	1 (3%)	
Clavien V (mortality)	2 (4%)	1 (3%)	0.707

Data are expressed as number (percentage).

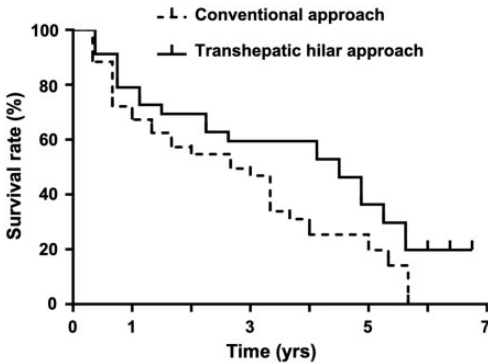
\*According to definition of International Study Group of Liver Surgery.

surgical duration was longer, the intraoperative blood loss was significantly less with the transhepatic hilar approach than conventional approach (382.1 vs. 824.4 mL, respectively;  $P=0.001$ ). In addition, the rate of R0 resection, which was defined as microscopically margin-negative resection, was significantly higher in the transhepatic hilar approach than conventional approach group (83.3% vs. 58.9%, respectively;  $P=0.016$ ).

### Surgical morbidity and mortality

The morbidity and mortality of the patients as assessed using the Clavien grading system are shown in Table 3.<sup>13</sup> The morbidity and mortality rates tended to be lower in the transhepatic hilar approach group than in the conventional approach group, but the difference did not reach statistical significance. However, the minor complication rate (Clavien grade  $\leq 2$ ) was significantly





**Figure 2.** Overall survival of patients who underwent surgical treatment by the conventional approach (46 patients) and transhepatic hilar approach (36 patients).

higher in the conventional approach group ( $P=0.003$ ).

### Postoperative survival

The 3- and 5-year overall survival rates for the patients who underwent the conventional approach were 46.9% and 19.7%, respectively, with a median survival of 2.67 years. In the transhepatic hilar approach group, the 3- and 5-year overall survival rates were 59.5% and 29.7%, respectively, with a median survival of 4.50 years. The postoperative survival of the patients who underwent the transhepatic hilar approach was significantly higher than that of patients who underwent the conventional approach ( $P=0.045$ ) (Figure 2).

Univariate and multivariate analyses were performed to identify prognostic factors (Table 4). The univariate analysis showed that the transhepatic hilar approach, intraoperative blood loss, MSKCC classification, and R0 resection were significantly associated with survival. The multivariate analysis indicated that the transhepatic hilar approach, MSKCC classification, and R0 resection were independent prognostic factors.

## Discussion

Curative resection with low postoperative mortality in patients with perihilar cholangiocarcinoma presents an ongoing challenge for hepatobiliary surgeons.<sup>14,15</sup> In the current study, the transhepatic hilar approach was associated with better surgical outcomes and longer overall survival in patients with Bismuth types III and IV perihilar cholangiocarcinoma than was the conventional approach. These better outcomes might have been due to the lower amount of bleeding and higher R0 resection rate because excessive intraoperative bleeding has an adverse effect on liver function and a positive resection margin is associated with higher postoperative recurrence.<sup>5,16,17</sup> However, the transhepatic hilar approach is rarely used because of its long surgical duration and high postoperative mortality.

Around 10 years ago, excluding patients who underwent preoperative portal vein embolization, hepatic parenchymal resection was started without confirming the demarcation line.<sup>18–20</sup> The transhepatic hilar approach was thus considered to be associated with bleeding from the liver parenchyma and bile leakage from the cut end of the remnant bile duct. Surgeons' growing experience with hepatic resection during the last decade, especially their deeper understanding of surgical anatomy and access to improved surgical devices, has drastically reduced the complications of hepatic parenchymal resection.<sup>20–22</sup> In the present study, although the surgical duration was longer with the transhepatic hilar approach than the conventional approach, the transhepatic hilar approach was associated with less bleeding and fewer complications, which was associated with lower morbidity and lower mortality. Other studies have even shown 0% postoperative mortality when using the transhepatic hilar approach.<sup>7,8</sup> The lower morbidity and mortality might be due to

**Table 4.** Univariate and multivariate analyses of long-term survival in 82 patients who underwent surgery for Bismuth types III and IV perihilar cholangiocarcinoma.

Variables	n	Median survival (95% CI)	Univariate P	Multivariate RR (95% CI)	P
Sex			0.519		
Male	46	4.00 (2.77–5.23)			
Female	36	2.25 (0.87–3.63)			
Age			0.211		
<60 years	25	4.00 (3.08–4.92)			
≥60 years	57	3.00 (2.08–3.92)			
Surgical approach			0.045		0.019
Conventional	46	2.67 (1.57–3.76)		1	
Transhepatic hilar	36	4.50 (2.79–6.21)		0.50 (0.28–0.90)	
Perioperative blood transfusion			0.502		
Present	38	3.33 (1.89–4.77)			
Absent	44	3.67 (2.24–5.10)			
Combined vascular resection			0.360		
With	18	3.00 (1.76–4.24)			
Without	64	3.33 (2.01–4.66)			
Intraoperative blood loss			0.140		
<800 mL	59	4.00 (2.64–5.36)			
≥800 mL	23	2.67 (0.91–4.42)			
Complications			0.680		
Present	53	3.33 (2.69–3.97)			
Absent	29	3.33 (0.98–5.69)			
TNM stage			0.593		
I	2	5.67 (0.00–13.14)			
II	20	3.67 (1.43–5.90)			
III	29	2.67 (1.34–3.99)			
IV	31	3.33 (1.69–4.98)			
Bismuth type			0.227		
III	40	2.67 (1.68–3.66)			
IV	42	2.30 (0.90–3.70)			
MSKCC classification			0.011		0.024
pT1	21	1.13 (2.06–5.20)		1	
pT2	26	5.33 (3.68–6.99)		1.87 (0.67–2.46)	
pT3	35	3.00 (2.33–3.67)		1.45 (0.88–2.24)	
Histological grade			0.511		
Well	7	4.00 (0.00–8.57)			
Moderate	45	3.00 (1.44–4.57)			
Poor	30	3.33 (2.05–4.62)			
Nodal status			0.335		
pN0	50	4.00 (2.99–5.01)			
pN1	32	3.00 (0.00–4.04)			
R status			0.003		0.011
R0	57	3.33 (2.05–4.62)		1	
R1, 2	25	1.67 (0.98–2.36)		2.02 (1.18–3.48)	

CI, confidence interval; RR, risk ratio; MSKCC, Memorial Sloan-Kettering Cancer Center.



surgeons' growing experience and the wider surgical view provided by the transhepatic hilar approach.<sup>23,24</sup>

Complete removal with a histologically negative margin is considered the most significant prognostic factor for perihilar cholangiocarcinoma.<sup>25-27</sup> Although modern CT and MRI can provide sufficient details to depict the longitudinal and radial extents of the tumor, unexpected cancer invasion along the hepatic duct might still be observed in a small fraction of patients during the operation.<sup>28,29</sup> In fact, in approximately 20% of patients, microscopic tumor invasion is present beyond the gross tumor border.<sup>30</sup> Precise detection of such microscopic spread is still unattainable.<sup>31</sup> When using the conventional approach for perihilar cholangiocarcinoma, the judgment of margin invasion of the proximal bile duct is usually unavailable until the last step. Thus, a change in the resection technique cannot be performed because the planned surgical area is already resected. In the transhepatic hilar approach, margin invasion of the proximal bile duct can be judged at the initial step of the surgical procedure under a wider surgical view. In addition, when a negative margin of the proximal bile duct cannot be observed even after repeated resections, the surgery type can still be changed to a more aggressive resection to completely remove the tumor. In the present study, the rate of R0 resection (a significant prognostic factor for patient survival) was significantly higher in the transhepatic hilar approach than in the conventional approach.

In a previous study using the transhepatic approach for perihilar cholangiocarcinoma, the R0 resection rate was 73.9%<sup>7</sup>; this was slightly lower than our R0 resection rate of 83.3%. Miyazaki et al.<sup>8</sup> reported that their R0 resection rate when using the transhepatic approach was 100%. However, only four patients with perihilar cholangiocarcinoma underwent surgical

resection in their study. Thus, the R0 resection rate of the transhepatic approach is much higher than that of the conventional approach, as previously reported.<sup>32</sup> In the current study, the 3- and 5-year overall survival rates were 59.5% and 29.7%, respectively, in the transhepatic hilar approach group, which were higher than those of the conventional approach reported in a previous study.<sup>32</sup> With the largest number of patients with advanced perihilar cholangiocarcinoma such as Bismuth types III and IV to date, our study has demonstrated that this approach is relatively safe and should be employed when curative resection appears to be available. This approach might result in improved survival in these patients.

Despite its advantages over the conventional approach, the transhepatic hilar approach should also be used with caution. In this study, the surgical duration of the transhepatic hilar approach was significantly longer than that of the conventional approach ( $P=0.003$ ). Extreme care should be taken during parenchymal transection to avoid excessive bleeding caused by hepatic vein injury; the transection should be performed with the help of intraoperative ultrasound, an ultrasonic dissector, and a cavitron ultrasonic surgical aspirator. Thus, the transhepatic hilar approach often requires a longer surgical duration. We recommend application of this approach for advanced perihilar cholangiocarcinoma (Bismuth types III and IV), especially when the surgeon has accumulated extensive experience with hepatectomy.

This study has two main limitations. First, this study was based on a retrospective analysis, and the number of patients was limited. Second, the number of patients who underwent preoperative biliary drainage was higher in the transhepatic hilar approach group. Preoperative biliary drainage is considered to increase the difficulty of evaluation of tumor resectability based on

CT or MRI.<sup>28</sup> Future randomized controlled trials with larger sample sizes are needed to confirm our findings.

## Conclusion

The transhepatic hilar approach might be a better choice for surgical resection of Bismuth types III and IV perihilar cholangiocarcinoma, which is associated with lower mortality and improved survival.

## Author contributions

X.X.S: conceptualization of the study and drafting of the manuscript. Y.L.H., C.W: data curation and statistical analysis. H.M: conceptualization of the study, funding acquisition, review and editing of the manuscript.

## Availability of data and material

The authors declare that all data supporting the findings of this study are available from the corresponding author on reasonable request.


## Declaration of conflicting interest

The authors declare that there is no conflict of interest.

## Funding

This research was supported by the Renji Hospital Fund PYII-17-007 (MH).

## ORCID iD

Xinsen Xu  <https://orcid.org/0000-0002-3339-9324>

## References

1. Nakeeb A, Pitt HA, Sohn TA, et al. Cholangiocarcinoma. A spectrum of intrahepatic, perihilar, and distal tumors. *Ann Surg* 1996; 224: 463–473; discussion 473–465. DOI: doi: 10.1097/00000658-199610000-00005.
2. Takasaki K, Kobayashi S, Muto H. Extended right hepatectomy with non touch isolation for giant hepatocellular carcinoma in the right liver. *Shokakigeka* 1984; 7: 1545. [in Japanese]
3. Liu CL and Fan ST. Anterior approach for right hepatectomy for hilar cholangiocarcinoma. *J Hepatobiliary Pancreat Surg* 2003; 10: 292–294. DOI: 10.1007/s00534-002-0812-9.
4. Lai EC, Fan ST, Lo CM, et al. Anterior approach for difficult major right hepatectomy. *World J Surg* 1996; 20: 314–317; discussion 318. DOI: 10.1007/s002689900050.
5. Liu CL, Fan ST, Lo CM, et al. Anterior approach for major right hepatic resection for large hepatocellular carcinoma. *Ann Surg* 2000; 232: 25–31. DOI: 10.1097/00000658-200007000-00004.
6. Kawabata Y, Hayashi H, Yano S, et al. Liver parenchyma transection-first approach in hemihepatectomy with en bloc caudate lobectomy for hilar cholangiocarcinoma: a safe technique to secure favorable surgical outcomes. *J Surg Oncol* 2017; 115: 963–970. DOI: 10.1002/jso.24612.
7. Kuriyama N, Isaji S, Tanemura A, et al. Transhepatic hilar approach for perihilar cholangiocarcinoma: significance of early judgment of resectability and safe vascular reconstruction. *J Gastrointest Surg* 2017; 21: 590–599. DOI: 10.1007/s11605-016-3332-7.
8. Miyazaki M, Kimura F, Shimizu H, et al. Extensive hilar bile duct resection using a transhepatic approach for patients with hepatic hilar bile duct diseases. *Am J Surg* 2008; 196: 125–129. DOI: 10.1016/j.amjsurg.2007.04.020.
9. Jarnagin WR, Fong Y, DeMatteo RP, et al. Staging, resectability, and outcome in 225 patients with hilar cholangiocarcinoma. *Ann Surg* 2001; 234: 507–517; discussion 517–509. DOI: 10.1097/00000658-200110000-00010.
10. Burke EC, Jarnagin WR, Hochwald SN, et al. Hilar cholangiocarcinoma: patterns of spread, the importance of hepatic resection for curative operation, and a presurgical clinical staging system. *Ann Surg* 1998; 228: 385–394. DOI: 10.1097/00000658-199809000-00011.
11. Bismuth H, Nakache R and Diamond T. Management strategies in resection for

- hilar cholangiocarcinoma. *Ann Surg* 1992; 215: 31–38. DOI: 10.1097/00000658-199201000-00005.
12. Chun YS, Pawlik TM and Vauthey JN. 8th Edition of the AJCC Cancer Staging Manual: Pancreas and Hepatobiliary Cancers. *Ann Surg Oncol* 2017. DOI: 10.1245/s10434-017-6025-x.
  13. Dindo D, Demartines N and Clavien PA. Classification of surgical complications: a new proposal with evaluation in a cohort of 6336 patients and results of a survey. *Ann Surg* 2004; 240: 205–213. DOI: 10.1097/01.sla.0000133083.54934.ae.
  14. Chen T, Wang HL, Wang H, et al. POSSUM and P-POSSUM as predictors of postoperative morbidity and mortality in patients undergoing hepato-biliary-pancreatic surgery: a meta-analysis. *Ann Surg Oncol* 2013; 20: 2501–2510. DOI: 10.1245/s10434-013-2893-x.
  15. Ito F, Cho CS, Rikkers LF, et al. Hilar cholangiocarcinoma: current management. *Ann Surg* 2009; 250: 210–218. DOI: 10.1097/SLA.0b013e3181afe0ab.
  16. Petrowsky H and Hong JC. Current surgical management of hilar and intrahepatic cholangiocarcinoma: the role of resection and orthotopic liver transplantation. *Transplant Proc* 2009; 41: 4023–4035. DOI: 10.1016/j.transproceed.2009.11.001.
  17. Wang H, Wang H, Chen T, et al. Evaluation of the POSSUM, P-POSSUM and E-PASS scores in the surgical treatment of hilar cholangiocarcinoma. *World J Surg Oncol* 2014; 12: 191. DOI: 10.1186/1477-7819-12-191.
  18. Van Gulik TM, Ruys AT, Busch OR, et al. Extent of liver resection for hilar cholangiocarcinoma (Klatskin tumor): how much is enough? *Dig Surg* 2011; 28: 141–147. DOI: 10.1159/000323825.
  19. Chen XP, Lau WY, Huang ZY, et al. Extent of liver resection for hilar cholangiocarcinoma. *Br J Surg* 2009; 96: 1167–1175. DOI: 10.1002/bjs.6618.
  20. Belghiti J and Ogata S. Preoperative optimization of the liver for resection in patients with hilar cholangiocarcinoma. *HPB (Oxford)* 2005; 7: 252–253. DOI: 10.1080/13651820500372335.
  21. Sun HC, Qin LX, Wang L, et al. Risk factors for postoperative complications after liver resection. *Hepatobiliary Pancreat Dis Int* 2005; 4: 370–374.
  22. Otto G, Hoppe-Lotichius M and Blettner M. Novel and simple preoperative score predicting complications after liver resection in noncirrhotic patients. *Ann Surg* 2011; 254: 831; author reply 832. DOI: 10.1097/SLA.0b013e318235dd6b.
  23. Kondo S, Katoh H, Hirano S, et al. Portal vein resection and reconstruction prior to hepatic dissection during right hepatectomy and caudate lobectomy for hepatobiliary cancer. *Br J Surg* 2003; 90: 694–697. DOI: 10.1002/bjs.4084.
  24. Shimada H, Endo I, Sugita M, et al. Hepatic resection combined with portal vein or hepatic artery reconstruction for advanced carcinoma of the hilar bile duct and gallbladder. *World J Surg* 2003; 27: 1137–1142. DOI: 10.1007/s00268-003-6801-6.
  25. Kang MJ, Jang JY, Chang J, et al. Actual long-term survival outcome of 403 consecutive patients with hilar cholangiocarcinoma. *World J Surg* 2016; 40: 2451–2459. DOI: 10.1007/s00268-016-3551-9.
  26. Bhardwaj N, Garcea G, Dennison AR, et al. The surgical management of Klatskin tumours: has anything changed in the last decade? *World J Surg* 2015; 39: 2748–2756. DOI: 10.1007/s00268-015-3125-2.
  27. Mansour JC, Aloia TA, Crane CH, et al. Hilar cholangiocarcinoma: expert consensus statement. *HPB (Oxford)* 2015; 17: 691–699. DOI: 10.1111/hpb.12450.
  28. Ni Q, Wang H, Zhang Y, et al. MDCT assessment of resectability in hilar cholangiocarcinoma. *Abdom Radiol (NY)* 2017; 42: 851–860. DOI: 10.1007/s00261-016-0943-0.
  29. Manfredi R, Barbaro B, Masselli G, et al. Magnetic resonance imaging of cholangiocarcinoma. *Semin Liver Dis* 2004; 24: 155–164. DOI: 10.1055/s-2004-828892.
  30. Ebata T, Watanabe H, Ajioka Y, et al. Pathological appraisal of lines of resection for bile duct carcinoma. *Br J Surg* 2002; 89: 1260–1267. DOI: 10.1046/j.1365-2168.2002.02211.x.

31. Ribero D, Amisano M, Lo Tesoriere R, et al. Additional resection of an intraoperative margin-positive proximal bile duct improves survival in patients with hilar cholangiocarcinoma. *Ann Surg* 2011; 254: 776–781; discussion 781-773. DOI: 10.1097/SLA.0b013e3182368f85.
32. Xiang S, Lau WY and Chen XP. Hilar cholangiocarcinoma: controversies on the extent of surgical resection aiming at cure. *Int J Colorectal Dis* 2015; 30: 159–171. DOI: 10.1007/s00384-014-2063-z.