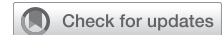

# Thoracoscopic right intrapericardial pneumonectomy



Mark W. Hennon, MD, and Todd L. Demmy, MD, Buffalo, NY

From the Department of Thoracic Surgery, Roswell Park Comprehensive Cancer Center, Buffalo, NY; and Department of Surgery, University at Buffalo, Buffalo, NY.

Received for publication June 25, 2023; revisions received Aug 26, 2023; accepted for publication Aug 31, 2023; available ahead of print Sept 10, 2023.

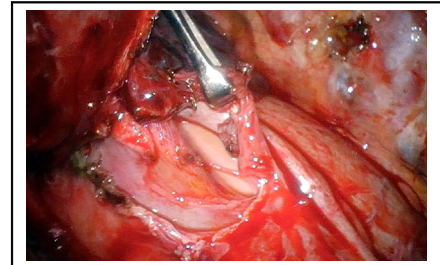
Address for reprints: Todd L. Demmy, MD, Department of Thoracic Surgery, Roswell Park Comprehensive Cancer Center, Elm and Carlton St, Buffalo, NY 14263 (E-mail: [todd.demmy@roswellpark.org](mailto:todd.demmy@roswellpark.org)).

JTCVS Techniques 2023;22:275-80

2666-2507

Copyright © 2023 The Author(s). Published by Elsevier Inc. on behalf of The American Association for Thoracic Surgery. This is an open access article under the CC BY-NC-ND license (<http://creativecommons.org/licenses/by-nc-nd/4.0/>).

<https://doi.org/10.1016/j.xjtc.2023.08.022>



Intrapericardial VATS approach yields safer hilar dissection.

## CENTRAL MESSAGE

VATS pneumonectomy challenges caused by tedious hilar dissections, surgeons' inexperience, and vascular injury risks are offset by enhanced retractors, optics, and intrapericardial exposures.

▶ Video clip is available online.

Video-assisted thoracoscopic surgery (VATS) and robotic-assisted thoracoscopic surgery approaches for lobectomy have increased steadily to become preferred over open thoracotomy. However, minimally invasive approaches for more challenging procedures such as chest wall resection and airway reconstruction are still in development.<sup>1</sup> Adoption of VATS pneumonectomy was slowed by case availability because total lung removal is appropriately avoided. Also, difficult hilar dissections for centrally located tumors risk unexpected vessel injuries. Generally, these challenges are from tumor girth, associated inflammation, and fibrosis from previous cancer treatments. Some can be overcome by intrapericardial dissections in unaffected tissues. Preoperative imaging may be predictive, but the ultimate decision to proceed with an intrapericardial approach is made intraoperatively based on the ability to safely dissect hilar structures.

## MATERIALS AND METHODS

Our technique for performing a safe and reproducible intrapericardial right pneumonectomy is described in 11 reproducible steps, each accompanied by a narrated video with graphical annotation. We previously described our general approach to advanced resections.<sup>1,2</sup> Briefly, the highly adaptable technique requires flexible 5-mm or 10-mm (3-dimensional) optics (Olympus Endoeye) and numerous thin shaft retractor instruments (Sontec) often filling the same ports (Figure 1). We use a 3-incision upper lobe approach achieving the key elements of pleural exploration, adequate proximal PA exposure, sequential structure divisions (bronchus last), lymphadenectomy, and stump coverage.

## RESULTS

### Preoperative Considerations

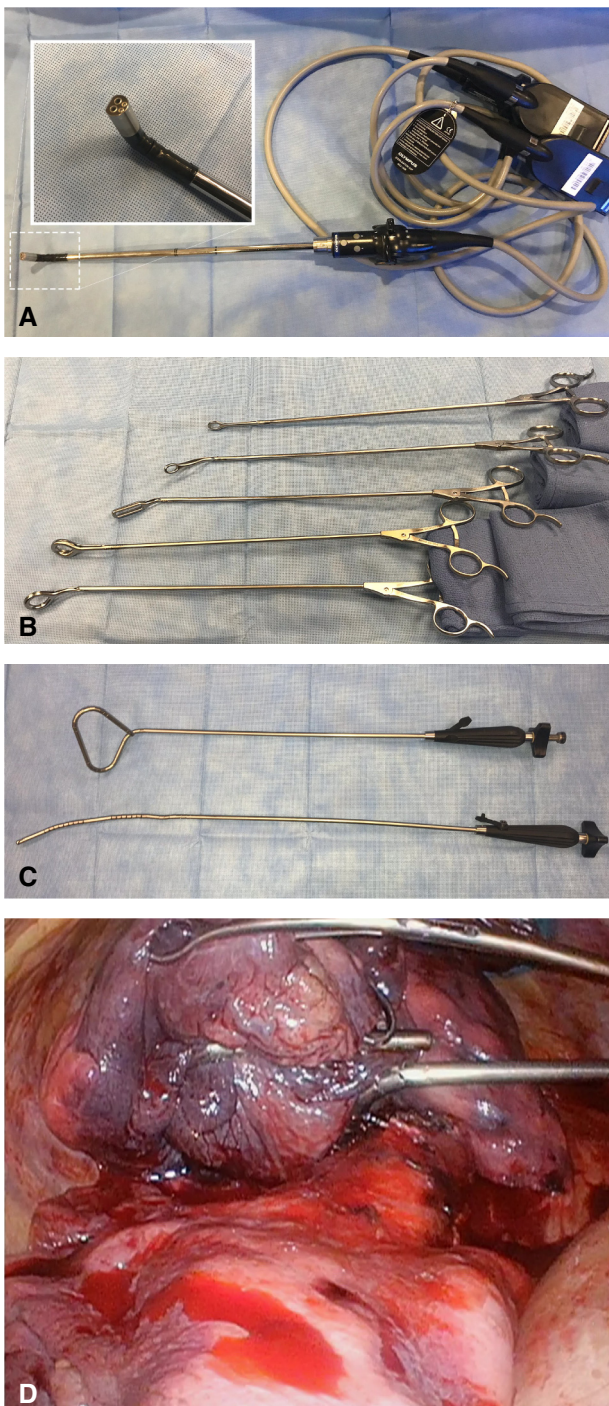
A parenchymal-sparing operation including VATS sleeve resection is preferred if possible and oncologically valid. In

this case, a bronchus intermedius squamous cell carcinoma extending proximally to encase the upper lobe airway mandated pneumonectomy.

Patients routinely undergo frailty screening, computed tomography/positron emission tomography imaging, pulmonary function testing, split lung perfusion scans, and echocardiography (Figure 2). Right heart catheterization and transesophageal echocardiography are occasionally useful to assess pulmonary artery (PA) occlusion tolerance but were not necessary in this case.

## DISCUSSION

Central tumors (and inflammation from preoperative chemoimmunotherapy or radiation) complicate hilar dissections and increase thoracoscopic pneumonectomy risks. As in this case, dissection may be facilitated by an intrapericardial approach. Although physiologic risk is uncertain, some VATS benefits associated with lessor resections might translate to pneumonectomy. We reported a retrospective 11-year experience of 67 VATS pneumonectomies, with 82% of cases in the second half of the series performed successfully without conversion.<sup>3</sup> By using the techniques described in this article, there were no intraoperative deaths from catastrophic PA bleeding or other technical mishaps. Survival curves by stage and perioperative outcomes were similar using an intent-to-treat



**FIGURE 1.** Flexible 3-dimensional optics (A) and low-profile retractors including the Sontec thoracoscopic (B) and Diamond-Flex laparoscopic (C) retractors. By virtue of 5-mm round (rather than ovoid) shaft cross-sections, multiple instruments can share the same port (D) to enable the complex traction-countertraction needed to dissect large tumors with hilar fibrotic changes. With permission.<sup>1</sup>

analysis.<sup>3</sup> Of note, we found that the pain reduction compared with thoracotomy associated with VATS was delayed by months, and this was recently replicated by

others.<sup>4</sup> Now that minimally invasive lung resection has become the standard of care, more complex operations naturally follow with larger series also showing no evidence of impaired outcomes.<sup>5</sup>

Loss of vascular control should a proximal vessel injury occur concerns most physicians. Besides a latex-free (relatively stiff plastic) catheter stapler leader (used first as a sling to aid PA dissection), catastrophic artery tears are avoided by preserving the bronchus. Dividing the bronchus early is tempting because it is accessible and obscures PA access, but it acts as a robust protective tether to oppose the dangerous force of large specimen retraction on the delicate vessel. Experience with main PA control comes with preparing for possible bleeding during difficult lobectomy cases. By encircling the artery with a double-looped silicone sling, the vessel will close completely if retracted. Similar PA control was routine practice for open lung resection cases performed in the era of tuberculosis surgery.

Whole lung specimen extraction can be difficult given the large size comparable to small VATS incisions and could be a mechanism behind delayed pain improvement noted earlier. A wide interspace in the axillary region is a good access incision for pneumonectomy, and lung specimens can be aligned so that the more malleable lobe is extracted first. Approximately 10% of cases experience a rib fracture that can be plated. Although this is not mandatory, increasing stability of the fracture potentially helps with postoperative pain and respiratory mechanics. Alternative extraction incisions also can be used. We also note cases in which the access incision is stretched by specimens (and without the rib approximation sutures used in thoracotomies) and facilitates air egress and mediastinal shift. We currently use the patch technique described, but there are other methods to seal this opening. Also, it may not be needed depending on the patient's anatomy and extent of mediastinal fixation from radiation or other treatment effects.

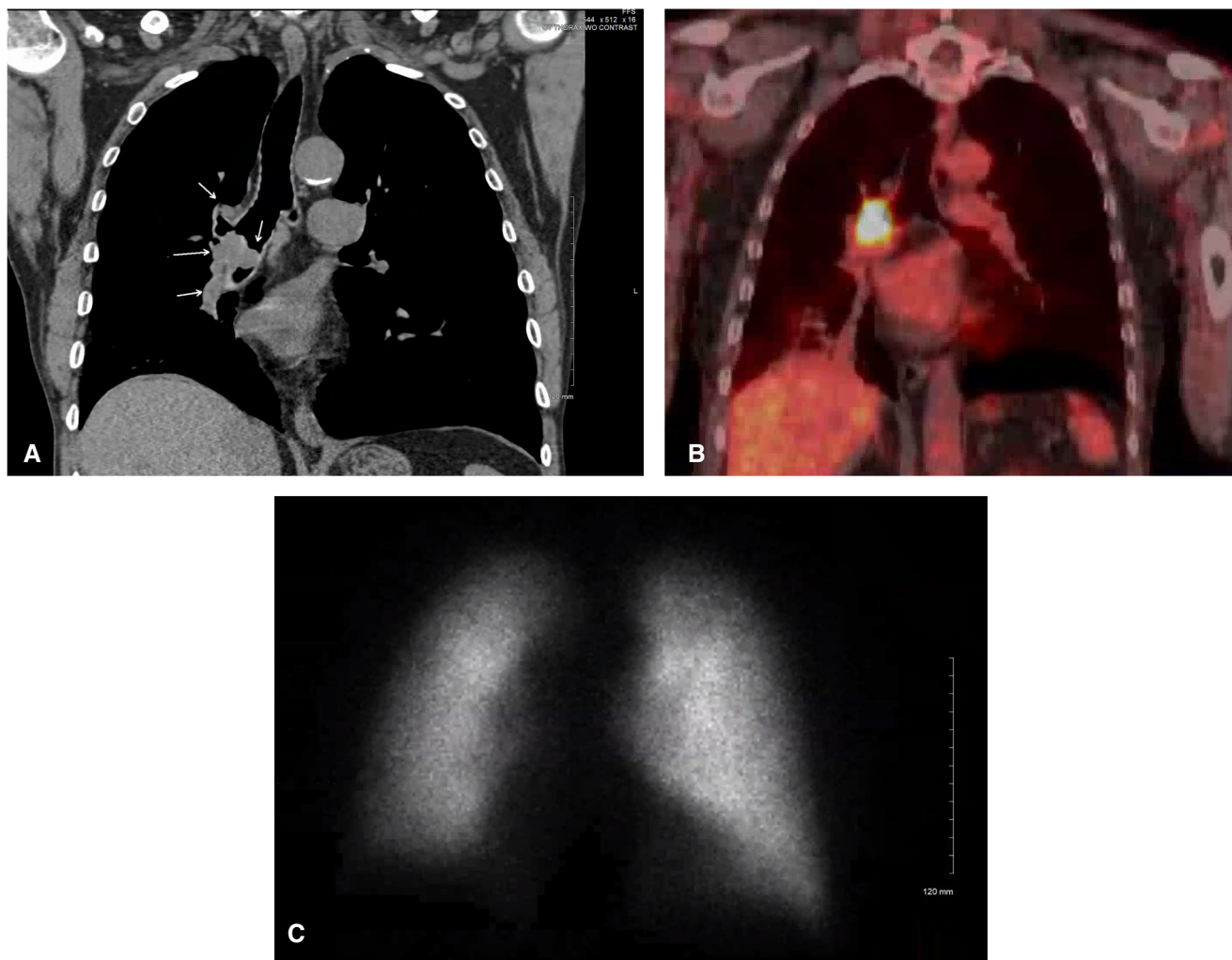
## CONCLUSIONS

For suitable patients without parenchymal-sparing options, thoracoscopic pneumonectomy is safe and feasible with possible long-term reduced pain.

## VIDEO SEGMENTS

### Positioning, Port/Incision Positioning

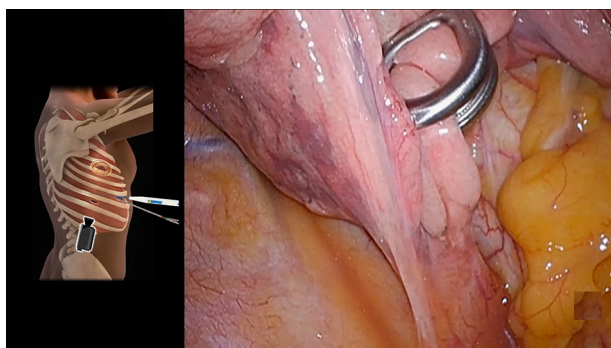
After double-lumen endotracheal intubation, the patient is moved to the left lateral decubitus position ([Video 1](#)). Standard VATS lobectomy incisions are created in the eighth intercostal space in the posterior axillary line, the seventh intercostal space more anteriorly, and a 4-cm access incision in the fourth intercostal space. An Alexis (Applied Medical) access wound protector retracts the chest wall soft tissues. Pleural metastases are excluded with camera



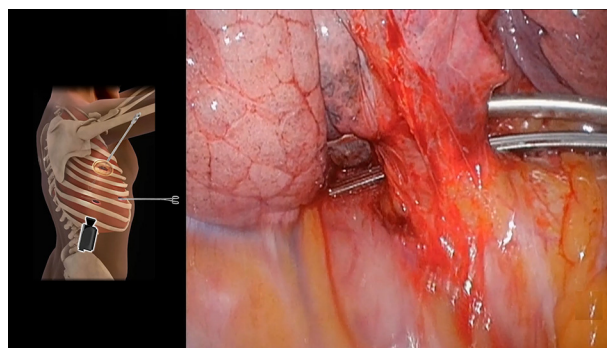
**FIGURE 2.** Initial imaging for presented case demonstrating coronal computed tomography (A), positron emission tomography (B), and split lung radio-nuclide findings (C) supporting pneumonectomy.

viewing from the posterior inferior incision. Intercostal nerve blocks are performed early to reduce central nociceptive sensitization-related chronic pain. The inferior

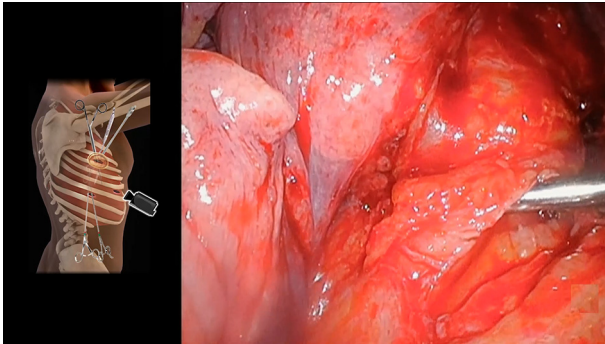
pulmonary ligament is then divided with energy while retracting the lower lobe superiorly. The anterior and posterior hilar pleurae are then opened with a bipolar sealer. At



**VIDEO 1.** Positioning, port/incision positioning. Video available at: [https://www.jtcvs.org/article/S2666-2507\(23\)00301-2/fulltext](https://www.jtcvs.org/article/S2666-2507(23)00301-2/fulltext).



**VIDEO 2.** Inferior pulmonary vein isolation. Video available at: [https://www.jtcvs.org/article/S2666-2507\(23\)00301-2/fulltext](https://www.jtcvs.org/article/S2666-2507(23)00301-2/fulltext).



**VIDEO 3.** Isolation of the superior pulmonary vein (intrapericardial). Video available at: [https://www.jtcvs.org/article/S2666-2507\(23\)00301-2/fulltext](https://www.jtcvs.org/article/S2666-2507(23)00301-2/fulltext).

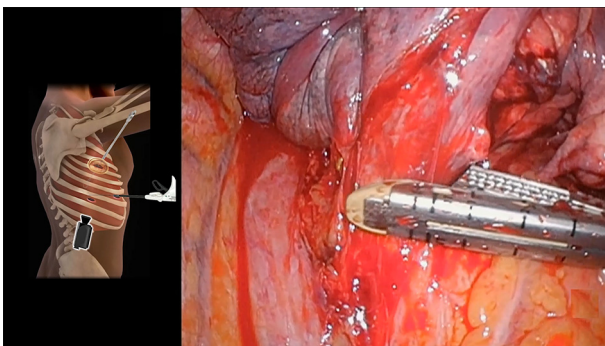
this point, dissection of level 9, 10 (inferior hilar), 7, and 8 lymph nodes can be performed.

### Inferior Pulmonary Vein Isolation

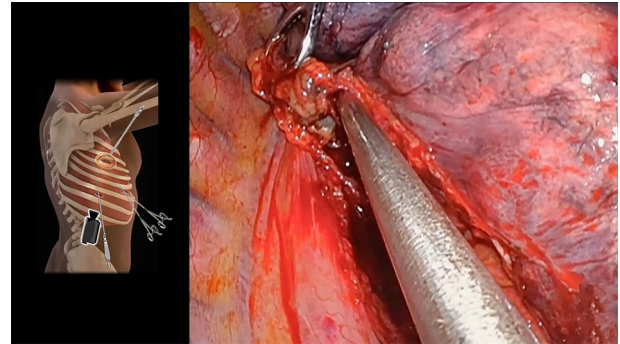
Circumferential inferior pulmonary vein dissection is then performed with both blunt dissection and energy while retracting the lung superiorly (Video 2). A vessel loop is placed around it to facilitate passing the stapler, but division is delayed until the superior vein is isolated as well. A camera swap is performed, and lung traction is exchanged from the access incision to the former camera port.

### Isolation of the Superior Pulmonary Vein (Intrapericardial)

Before dividing the inferior vein, the superior pulmonary vein is dissected. This occasionally reduces lung vascular congestion during prolonged hilar dissection in tumors with high bronchial artery perfusion (Video 3). In our case, local tumor hilar fibrosis necessitated intrapericardial vein dissection. A long-handle 15-blade scalpel is used to gently score the pericardium posterior to the phrenic nerve, which is then opened and extended using VATS scissors.



**VIDEO 4.** Sequential division of pulmonary veins. Video available at: [https://www.jtcvs.org/article/S2666-2507\(23\)00301-2/fulltext](https://www.jtcvs.org/article/S2666-2507(23)00301-2/fulltext).



**VIDEO 5.** PA isolation. Video available at: [https://www.jtcvs.org/article/S2666-2507\(23\)00301-2/fulltext](https://www.jtcvs.org/article/S2666-2507(23)00301-2/fulltext).

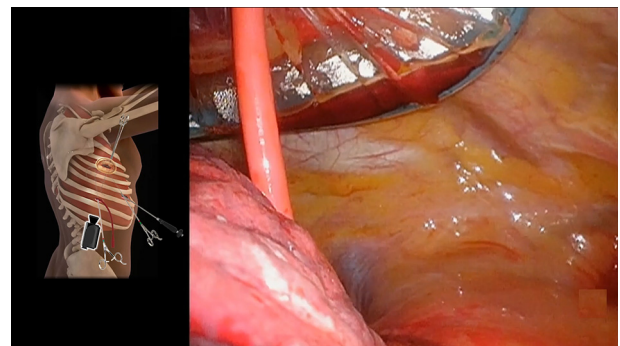
Although not mandatory, we find the scalpel to be the most useful instrument for the initial opening of the pericardium. The superior pulmonary vein is isolated within the opened pericardium and encircled with a vessel loop.

### Sequential Division of Pulmonary Veins

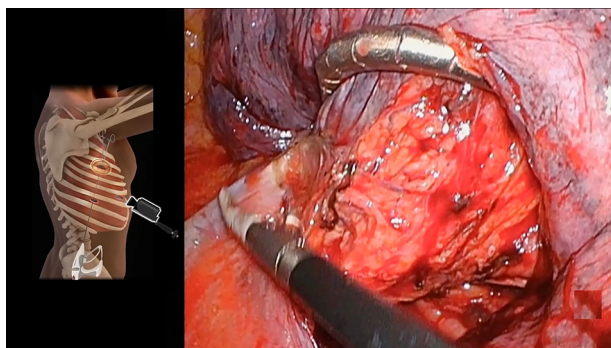
By using vessel loop control, the upper and lower pulmonary veins are divided in rapid succession with surgical stapler vascular loads (Video 4). Some peribronchial tissue is dissected from the airway at this point to improve hilar mobility.

### PA Isolation

Dissection of the right main PA from the right mainstem bronchus is then performed (Video 5). Level 7 lymph nodes are also dissected to facilitate the isolation of the PA. Peribronchial airway tissue and PA attachments are divided carefully with energy. Attention is turned to the anterior hilum to further dissect the PA. After some initial dissection between the airway and the main PA, retraction of the whole lung can be greatly aided by using a 5-mm laparoscopic flexible liver retractor such as the Diamond-Flex (CareFu-sion) through the anterior inferior incision. In addition to



**VIDEO 6.** Division of the right main PA. Video available at: [https://www.jtcvs.org/article/S2666-2507\(23\)00301-2/fulltext](https://www.jtcvs.org/article/S2666-2507(23)00301-2/fulltext).



**VIDEO 7.** Division of the bronchus. Video available at: [https://www.jtcvs.org/article/S2666-2507\(23\)00301-2/fulltext](https://www.jtcvs.org/article/S2666-2507(23)00301-2/fulltext).

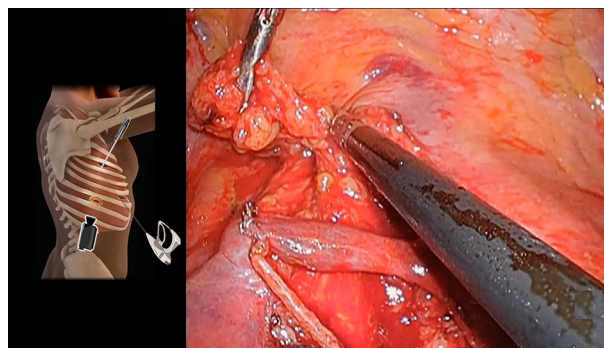
aiding arterial dissection, this retractor efficiently exposes the carina later in the case for lymph node dissection.

### Division of the Right Main PA

A red rubber catheter is positioned in between the artery and airway (Video 6). If controlling the airway, it can be swung around the PA (reverse exclusion technique). Such a sling applies gentle arterial traction while dissecting away other thickened tissues (lymphatics or residual pericardium) that impair stapler function. Last, the red rubber catheter acts as a leader to facilitate safe passage of the endoscopic vascular stapler anvil behind the main PA. A plastic latex-free catheter is stiffer, yielding more reliable anvil guidance. Before dividing the artery, the stapler is closed to assess for any hemodynamic compromise caused by inadvertent main PA narrowing or cardiac decompensation.

### Division of the Bronchus

Any remaining peribronchial attachments of lymphatics are divided while retracting the lung superiorly (Video 7). Lung retraction is again facilitated with the liver retractor, which helps leave the shortest bronchial stump possible, especially for left-sided pneumonectomy. The stapler is



**VIDEO 9.** Lymph node dissection. Video available at: [https://www.jtcvs.org/article/S2666-2507\(23\)00301-2/fulltext](https://www.jtcvs.org/article/S2666-2507(23)00301-2/fulltext).

brought in from the posterior incision for division of the bronchus.

### Specimen Extraction

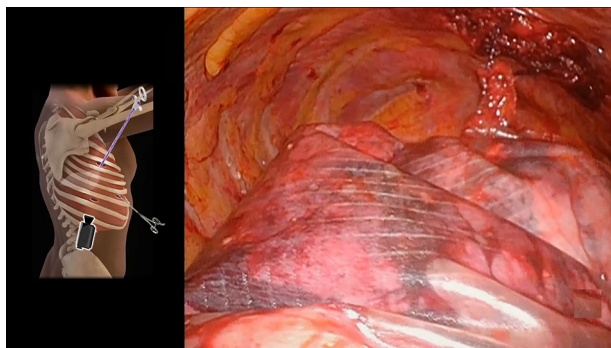
Extraction of the whole lung specimen can be difficult through the access incision (Video 8). To allow for maximal rib flexion, the pleura and intercostal muscles are divided as much as possible under the skin incision. We prefer a 15-mm Anchor tissue retrieval system (Anchor Products Co), but some specimens require the larger 8 × 10-inch traditional pouch.

### Lymph Node Dissection

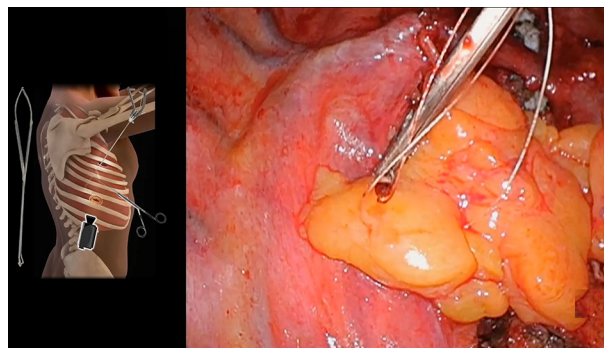
The right paratracheal lymph node tissue packet is removed (Video 9). Hemostasis is achieved with Aquamantys (Medtronic) and topical hemostatic agents. Although a debate on the merits of lymph node dissection versus sampling is beyond the scope of this article, minimizing the possibility of ischemia of the bronchial stump is important in preventing the complication of delayed bronchopleural fistula.

### Bronchial Stump Coverage

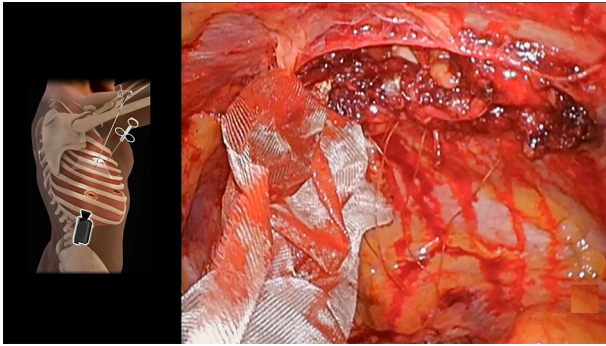
The pericardial and residual thymic fat were mobilized with the LigaSure (Medtronic) on a superior pedicle and



**VIDEO 8.** Specimen extraction. Video available at: [https://www.jtcvs.org/article/S2666-2507\(23\)00301-2/fulltext](https://www.jtcvs.org/article/S2666-2507(23)00301-2/fulltext).



**VIDEO 10.** Bronchial stump coverage. Video available at: [https://www.jtcvs.org/article/S2666-2507\(23\)00301-2/fulltext](https://www.jtcvs.org/article/S2666-2507(23)00301-2/fulltext).



**VIDEO 11.** Chest wall seal. Video available at: [https://www.jtcvs.org/article/S2666-2507\(23\)00301-2/fulltext](https://www.jtcvs.org/article/S2666-2507(23)00301-2/fulltext).

secured to the bronchial stump with interrupted absorbable sutures to the pleural reflection (**Video 10**). For noninfected and nonirradiated cases, this is optional.

### Chest Wall Seal

To limit postpneumonectomy space air egress into subcutaneous tissue, the access incision site is closed using a double layer of Vicryl mesh by interrupted horizontal 0 Vicryl mattress sutures to the superior and inferior rib margins

(**Video 11**). A chest tube is connected to a balanced pneumonectomy drainage system.

### Conflict of Interest Statement

T.L.D.: Medtronic has furnished grant funding and consultation fees. The other author reported no conflicts of interest.

The *Journal* policy requires editors and reviewers to disclose conflicts of interest and to decline handling or reviewing manuscripts for which they may have a conflict of interest. The editors and reviewers of this article have no conflicts of interest.

### References

1. Hennon M, Demmy TL. VATS for advanced T status (large tumors, mediastinal invasion and vascular control). *Video Assist Thorac Surg*. 2018;3:50. <https://doi.org/10.21037/vats.2018.12.03>
2. Hennon MW, Demmy TL. Technique of video-assisted thoracoscopic left pneumonectomy. *J Vis Surg*. 2017;3:32. <https://doi.org/10.21037/jovs.2017.02.06>
3. Battoo A, Jahan A, Yang Z, Nwogu CE, Yendamuri SS, Dexter EU, et al. Thoracoscopic pneumonectomy: an 11-year experience. *Chest*. 2014;146:1300-9. <https://doi.org/10.1378/chest.14-0058>
4. Al Sawalhi S, Gysling S, Cai H, Zhao L, Alhadidi H, Al Rimawi D, et al. Uniportal video-assisted versus open pneumonectomy: a propensity score-matched comparative analysis with short-term outcomes. *Gen Thorac Cardiovasc Surg*. 2021;69:1291-302. <https://doi.org/10.1007/s11748-021-01626-0>
5. Yang CJ, Yendamuri S, Mayne NR, Battoo A, Wang H, Meyerhoff RR, et al. The role of thoracoscopic pneumonectomy in the management of non-small cell lung cancer: a multicenter study. *J Thorac Cardiovasc Surg*. 2019;158:252-64.e2. <https://doi.org/10.1016/j.jtcvs.2018.12.001>