

Traumatic Right Diaphragmatic Rupture Combined with Avulsion of the Right Kidney and Herniation of the Liver into the Thorax

Dong Gon Yoo, M.D.*, ChongWook Kim, M.D.*, Chong-Bin Park, M.D.*, Jae Hong Ahn, M.D.**

Right-sided diaphragmatic rupture is less common and more difficult to diagnose than left-sided lesion. It is rarely combined with the herniation of the abdominal organs into the thorax. High level of suspicion is the key to early diagnosis, and a delay in diagnosis is implicated with a considerable risk of mortality and morbidity. We experienced a case of right-sided diaphragmatic rupture combined with complete avulsion of the right kidney and herniation of the liver into the thoracic cavity.

Key words: 1. Diaphragm
2. Kidney
3. Liver
4. Trauma
5. Diaphragm, trauma

CASE REPORT

A 54-year-old male worker was brought to our emergency room. He had been knocked down by a falling object while working in a construction site. On arrival his Glasgow Coma Scale was 9/15 with blood pressure of 80/50 mmHg, pulse rate of 88/min, and respiration rate of 26/min. His physical examination disclosed diminished right breath sound. Laboratory examinations revealed gross hematuria and anemia (hemoglobin level: 8.3 g/dL). Because his peripheral oxygen saturation was 90%, he was immediately intubated.

His chest X-ray showed a massive right hemothorax, which was treated with tube thoracostomy. Multi-detector computed tomography (CT) of his chest and abdomen showed disruption of the right diaphragm, superior displacement of the

liver into the thorax, active bleeding from the left kidney with perirenal hematoma, nonvisualization of the right kidney in its anatomical position with its dislodgement into the thoracic cavity, and right renal artery and vein obstruction with thrombus (Fig. 1). Left renal angiogram revealed hemorrhage from the upper polar branch of the left kidney, and the bleeding vessel was embolized with coil. Other associated injuries were multiple fractures of the ribs, the right humerus shaft, the right 4th and 5th metacarpal bone, and the spines.

Through right posterolateral thoracotomy, we identified the liver herniated into the thorax. The right diaphragm had a circumferential tear of approximately 25 cm in length along the whole periphery of diaphragm except the medial aspect. The right kidney was found lacerated in the upper thoracic cavity, separated from its vascular pedicle and ureter (Fig. 2).

*Department of Thoracic and Cardiovascular Surgery, Gangneung Asan Hospital, University of Ulsan College of Medicine

**Department of Diagnostic Radiology, Gangneung Asan Hospital, University of Ulsan College of Medicine

Received: July 16, 2010, Revised: August 18, 2010, Accepted: January 17, 2011

Corresponding author: Dong Gon Yoo, Department of Thoracic and Cardiovascular Surgery, Gangneung Asan Hospital, University of Ulsan College of Medicine, 415, Bangdong-ri, Sicheon-myeon, Gangneung 210-711, Korea
(Tel) 82-33-610-3270 (Fax) 82-33-641-8070 (E-mail) gonymd@naver.com

© The Korean Society for Thoracic and Cardiovascular Surgery. 2011. All right reserved.

© This is an open access article distributed under the terms of the Creative Commons Attribution Non-Commercial License (<http://creativecommons.org/licenses/by-nc/3.0>) which permits unrestricted non-commercial use, distribution, and reproduction in any medium, provided the original work is properly cited.

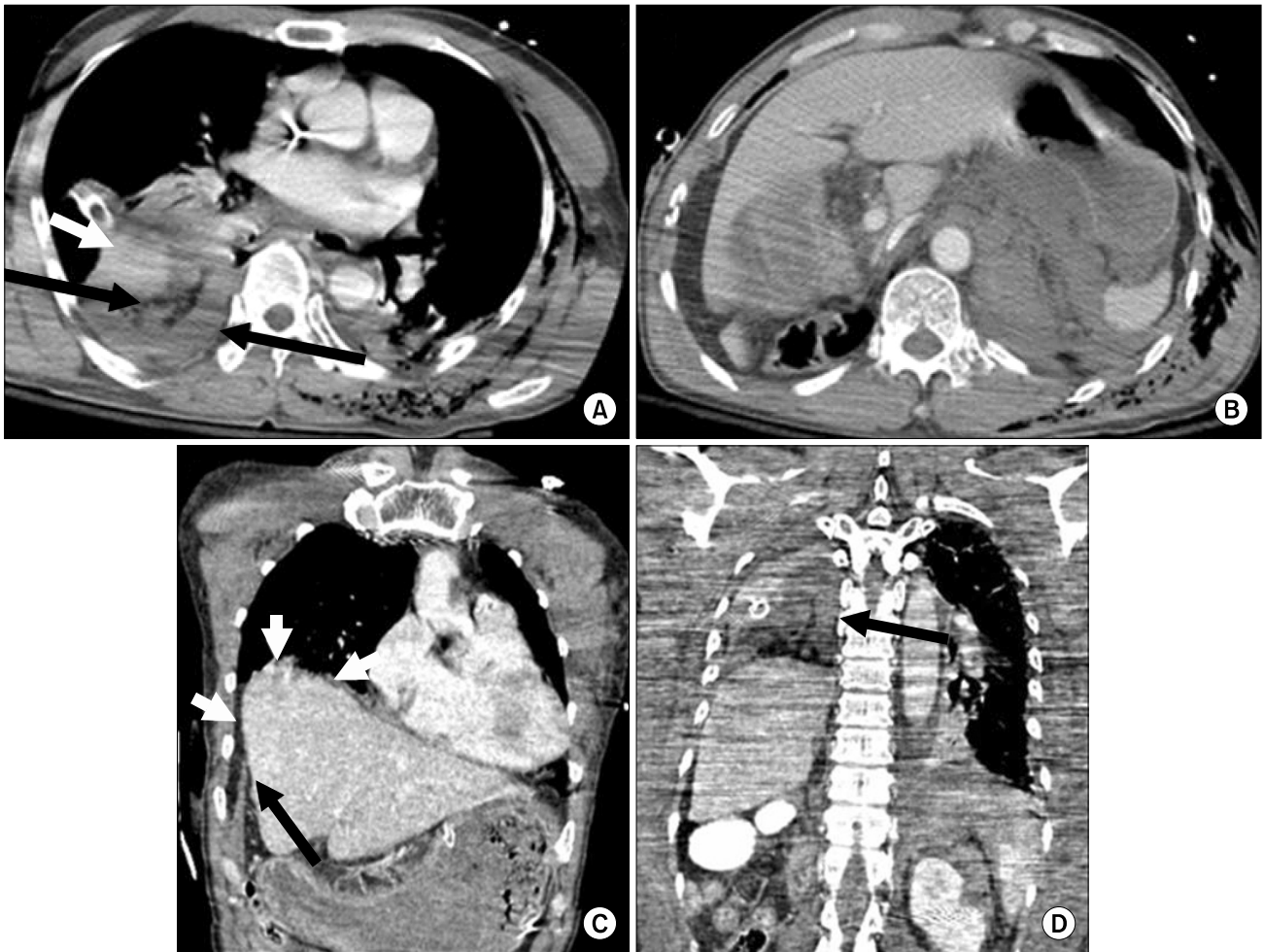


Fig. 1. (A) Contrast-enhanced axial CT shows intrathoracic dislodgement of the devascularized right kidney (black arrows) and the dome of the liver (short white arrow). (B) Contrast-enhanced CT shows non-visualization of the right kidney in right renal fossa. (C) Coronal reformation CT shows diaphragmatic disruption (black arrow) and intra-thoracic liver hernia (short white arrows). (D) Coronal reformation CT shows intra-thoracic migration of the devascularized right kidney (black arrow).

Because the renal vasculoureteral stump could not be found in the retroperitoneal space and there was no evidence of active bleeding, ligation of the stump was not attempted. We restored the liver into the abdominal cavity and repaired the diaphragm using interrupted non-absorbable sutures.

He was extubated 4 days after surgery. A few days later, pneumonia developed. His antibiotics regimen was changed, and new antibiotics were administered for 2 weeks. The patient gradually recovered with no further events.

DISCUSSION

Traumatic diaphragmatic rupture (TDR) may occur following blunt or penetrating truncal trauma. Its incidence was reported to range between 1~7% of the victims with significant blunt trauma, and 10~15% with penetrating trauma [1]. TDR is commonly associated with other organ injuries [1-3], and mortality and morbidity mostly result from associated injuries [1,2]. Its early diagnosis is often difficult and survival depends on prompt diagnosis and urgent surgical treatment [4]. TDR more commonly affects the left side than the right side [1-3]. The preponderance of left-sided ruptures

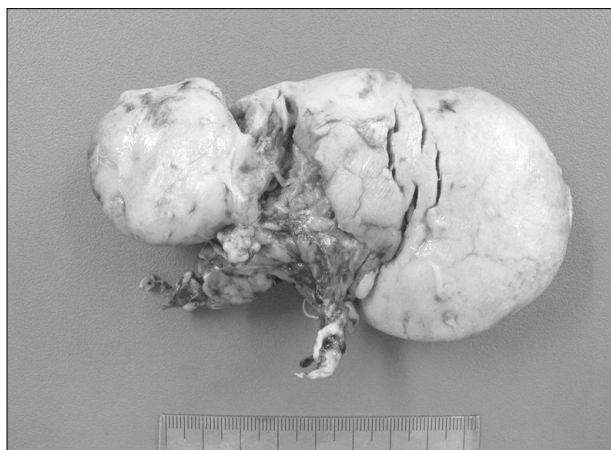


Fig. 2. The right kidney, found lacerated in the right upper thorax and completely separated from its vascular pedicle and ureter.

is related to the protective effect of the liver [1,4]. While herniation of the intra-abdominal organs through the ruptured left diaphragm is not rare, complete avulsion of the right kidney and the herniation of the liver into the thorax through a ruptured diaphragm are extremely rare [5].

TDR is constantly a marker of severe trauma [4]. The diaphragm is rarely injured alone, and the incidence of associated injuries ranges from 91% up to 100% [1-3,6,7]. Among the abdominal organs, the spleen and the liver are most frequently injured [3,4,7]. In our patient, both the left kidney and the liver were injured.

It is often difficult to make an early diagnosis of TDR, especially when the right side is involved [1,2,4,7,8]. Therefore, a high index of suspicion is the key to prompt diagnosis. Plain chest X-ray is the first step in the diagnostic workup [6]. Initial chest X-rays lead to the diagnosis of 27~62% of the left-sided ruptures and only 17% of right-sided lesions [1,6]. The pathognomic findings on chest X-ray include a nasogastric tube or herniated bowel loops within the chest, and liver herniation into the right thorax [1]. In our patient, the chest X-ray showed a massive right hemothorax without any other signs to suggesting TDR.

CT of thorax and abdomen is the most useful and reliable tool in diagnosing polytrauma patients [4]. It shows findings consistent with TDR, such as disruption of the diaphragm and intrathoracic herniation of the abdominal organs [1,8]. It also reveals other associated injuries [1]. The limitations of CT in-

clude difficulties in delineating the diaphragm from the adjacent organs, unnoticed important findings due to big slice thickness, and blurring of the image by respiratory motion around the diaphragm [2]. Helical CT has better diagnostic yields. It is widely known that helical CT can detect 71% of TDR, while conventional CT has variable sensitivity ranging from 14 to 61% [1,8]. Multi-detector CT provides more detailed information by thinner slicing, rapid imaging time, and a more flexible image reconstruction [1]. In our case, the direct signs of TDR (i.e. disruption of the right diaphragm, intrathoracic herniation of the liver, and intrathoracic dislodgement of the right kidney) were clearly depicted on the coronal reformed multi-detector CT imaging (Fig. 1). Other diagnostic tools include fluoroscopy, abdominal ultrasonography, barium study, peritoneal lavage, and magnetic resonance imaging [1,4,8]. Recently laparoscopy and thoracoscopy have been frequently performed for both diagnosis and repair of TDR [1,4,8].

Once the diagnosis is made, surgery must be performed quickly, as any delay may cause the herniation of the abdominal organs and increase morbidity and mortality [4,6]. Unless thoracic injuries are present, TDR is usually approached through a laparotomy which allows a complete exploration of abdominal organs for associated injuries [6]. The preferred method of diaphragmatic repair is interrupted or continuous full-thickness suturing using nonabsorbable suture material [4]. We performed a thoracotomy because associated active renal bleeding was controlled by coil embolization. Traumatic avulsion of the kidney is frequently difficult to identify and its combination with diaphragmatic rupture is extremely rare [5].

Early morbidity and mortality of TDR are mainly caused by the associated injuries [1-3]. Reported mortality rates range from 3.6 to 41%, and age, irreversible shock and trauma severity are major determinants for mortality [2,4]. Mortality in patients with an isolated TDR is very low. Prompt identification of associated injuries with adequate management for them is essential for successful outcome.

REFERENCES

1. Bosanquet D, Farboud A, Luckraz H. *A review of dia-*

- phragmatic injury*. Resp Med 2009;2:1-6.
2. Athanassiadi K, Kalavrouziotis G, Athanassiou M, et al. *Blunt diaphragmatic rupture*. Eur J Cardiothorac Surg 1999; 15:469-74.
3. Williams M, Carlin AM, Tyburski JG, et al. *Predictors of mortality in patients with traumatic diaphragmatic rupture and associated thoracic and/or abdominal injuries*. Am Surg 2004;70:157-62.
4. Reber PU, Schmied B, Seiler CA, Baer HU, Patel AG, Buechler MW. *Missed diaphragmatic injuries and their long-term sequelae*. J Trauma 1998;44:183-8.
5. Cohen Z, Gabriel A, Mizrachi S, Kapuler V, Mares AJ. *Traumatic avulsion of kidney into the chest through a ruptured diaphragm in a boy*. Pediatr Emerg Care 2000;16: 180-1.
6. Turhan K, Makay O, Cakan A, et al. *Traumatic diaphragmatic rupture: look to see*. Eur J Cardiothorac Surg 2008;33:1082-5.
7. Mihos P, Potaris K, Gakidis J, et al. *Traumatic rupture of the diaphragm: experience with 65 patients*. Injury 2003;34: 169-72.
8. Eren S, Kantarci M, Okur A. *Imaging of diaphragmatic rupture after trauma*. Clin Radiol 2006;61:467-77.