



Research paper

The utility of a methylation panel in the assessment of clinical response to radiofrequency ablation for Barrett's esophagus



Wladyslaw Januszewicz^{a,b}, Vinod V. Subhash^a, William Waldock^a, Daniel I. Fernando^a, Giorgio Bartalucci^a, Hamza Chettouh^a, Ahmad Miremadi^c, Maria O'Donovan^c, Rebecca C. Fitzgerald^a, Massimiliano di Pietro^{a,*}

^a MRC Cancer Unit, Hutchison-MRC Research Centre, University of Cambridge, CB2 0XZ Cambridge, UK

^b Department of Gastroenterology, Hepatology and Clinical Oncology, Medical Centre for Postgraduate Education, Warsaw, Poland

^c Department of Histopathology, Addenbrooke's Hospital, Cambridge, United Kingdom

ARTICLE INFO

Article History:

Received 8 April 2020

Revised 30 May 2020

Accepted 22 June 2020

Available online xxx

Keywords:

Precancerous lesions

Biomarkers

Methylation

Endoscopic therapy, Intestinal metaplasia

ABSTRACT

Background: Radiofrequency ablation (RFA) is an effective treatment for dysplastic Barrett's esophagus (BE), but recurrence can occur after initial response. Currently there is uncertainty about how to best define histological remission. A DNA methylation panel on esophageal samples was previously shown to have high diagnostic accuracy for BE. We aimed to investigate this biomarker panel in the assessment of response to RFA treatment.

Methods: We retrospectively analyzed esophageal and gastroesophageal junction (GEJ) biopsies from patients with BE before and after RFA treatment. We quantified the extent of intestinal metaplasia (IM) based on number of glands with goblet cells (IM-Score) and expression of the intestinal factor trefoil factor-3 (TFF3-Score). Promoter methylation of 3 genes (*ZNF345*, *TFF12*, *ZNF569*) was measured by methylight (Meth-Score) throughout the RFA treatment pathway.

Findings: We included 45 patients (11 non-dysplastic BE, 14 low-grade dysplasia, 20 high-grade dysplasia/intramucosal cancer). Meth-Scores were significantly higher in BE with and without dysplasia and GEJ with IM compared to GEJ without IM ($P < .001$). Meth-scores significantly correlated with the extent of IM at the GEJ measured both with IM-Scores ($\rho = 66.0\%$, $P < .001$), and TFF3-Scores ($\rho = 75.6\%$, $P < .001$). In patients with residual IM at the GEJ, RFA re-treatment brought about a 7.6-fold reduction in the methylation levels. The Meth-score had an area under the ROC curve of 95.1% (95%CI 91.1% - 99.1%) differentiating BE from normal GEJ.

Interpretation: A DNA methylation panel can discriminate between the extent of histological IM in esophageal and junctional biopsies and could be used to objectively quantify residual disease following RFA.

© 2020 The Authors. Published by Elsevier B.V. This is an open access article under the CC BY-NC-ND license. (<http://creativecommons.org/licenses/by-nc-nd/4.0/>)

1. Introduction

Barrett's esophagus (BE) is the only known premalignant condition to esophageal adenocarcinoma (EAC), which is the solid cancer with the steepest rise in incidence rate in the Western world over the last four decades [1,2]. BE is defined as an endoscopically visible

segment of columnar epithelium in the distal esophagus; the presence of intestinal metaplasia (IM) in biopsies corroborates the diagnosis and is believed to be related to the associated cancer risk [3,4]. The malignant progression of BE to cancer involves several stages from non-dysplastic BE (NDBE), to low-grade dysplasia (LGD) and high-grade dysplasia (HGD) and finally to intramucosal carcinoma (IMC) and invasive cancer [3]. Although the annual risk of malignant progression in NDBE is estimated to be as low as 0.3% [5], the presence of dysplasia increases this risk substantially, up to 20% per annum, in cases of HGD [6]. The presence of dysplasia remains the strongest risk factor for cancer progression in BE patients and warrants endoscopic treatment [4,7–9].

Radiofrequency ablation (RFA) is an endoscopic ablative technique that utilizes thermal energy to ablate BE mucosa, which is generally followed by re-epithelialization with squamous epithelium [10]. It is recommended for the treatment of BE with associated HGD and IMC without visible abnormality, as well as confirmed LGD

Abbreviations: APC, argon plasma coagulation; BE, Barrett's esophagus; BMI, body mass index; CR-D, complete remission of dysplasia; CR-IM, complete remission of intestinal metaplasia; EAC, esophageal adenocarcinoma; IND, indefinite for dysplasia; IM, intestinal metaplasia; IMC, intramucosal carcinoma; IQR, interquartile range; LGD, low-grade dysplasia; GEJ, gastroesophageal junction; GEJ-GM, gastro-esophageal junction with gastric-type mucosa; GEJ-IM, gastro-esophageal junction with intestinal metaplasia; GERD, gastro-esophageal reflux disease; GI, gastrointestinal (tract); GM, gastric metaplasia; HGD, high-grade dysplasia; NDBE, non-dysplastic Barrett's esophagus; RFA, radiofrequency ablation; SD, standard deviation; TFF-3, trefoil factor 3.

* Corresponding author.

E-mail address: md460@mrc-cu.cam.ac.uk (M. di Pietro).

<https://doi.org/10.1016/j.ebiom.2020.102877>

2352-3964/© 2020 The Authors. Published by Elsevier B.V. This is an open access article under the CC BY-NC-ND license. (<http://creativecommons.org/licenses/by-nc-nd/4.0/>)

Research in context

Evidence before this study

We have searched MEDLINE (via PubMed) for articles published in any language between Jan 1, 1974, and Jan 1, 2020 using the search terms (“Barrett esophagus” [MeSH Terms] AND “Biomarkers” [MeSH Terms] AND “Methylation” [MeSH Terms]) and identified 54 research papers.

Widespread DNA methylation changes are observed in Barrett’s esophagus carcinogenesis. Several methylation markers have been found accurate in discriminating Barrett’s epithelium from normal glandular mucosa in endoscopic biopsies, esophageal brushings, and samples obtained by non-endoscopic cell-collection devices such as the Cytosponge™ and EsophaCap™. For example, our group have previously shown that a methylation panel consisting of four genes (*TFPI2*, *TWIST1*, *ZNF345*, *ZNF569*) applied to Cytosponge™ samples can diagnose Barrett’s epithelium (intestinal metaplasia with goblet cells) with an area under the ROC curve (AUC) ranging from 78.7% to 87.7%. Moreover, a different four-gene methylation panel (*SLC22A18*, *PIGR*, *GJA12* and *RIN2*) was found useful in stratifying patients into three risk groups with potential clinical utility. So far, none of the methylation markers have been investigated as a test to assess response to endoscopic treatment of Barrett’s esophagus, such as radiofrequency ablation (RFA).

Added value of this study

In this study we demonstrate that three methylation markers genes (*ZNF345*, *TFPI2*, *ZNF569*) accurately differentiate Barrett’s epithelium from normal gastroesophageal junction samples with an area under the ROC curves of 95.1% (95%CI 91.1% - 99.1%). Moreover, the mean methylation score (“Meth-score”) measured at the gastroesophageal junction after completion of the RFA treatment significantly correlates with the amount of residual Barrett’s phenotype measured by number of glands with intestinal metaplasia (IM-Score) and the intensity of the TFF3 staining ($\rho=66.0\%$ and 75.6% , respectively; $P<.001$). Lastly, we show that patients with widespread IM at the gastroesophageal junction during the follow-up that received re-treatment with RFA have a 7.6-fold reduction in the methylation levels.

Implications of all the available evidence

Our data suggest that this methylation panel can objectively quantify the degree of response following radiofrequency ablation for Barrett’s esophagus. Given the subjectivity in the histologic assessment for intestinal metaplasia, this novel biomarker panel on clinical biopsies can measure the amount residual disease and inform clinical management.

patchy and focal distribution, it is often difficult to reproduce in clinical practice and constitutes a subjective histopathological diagnosis [15]. Moreover, focal IM at the GEJ is common in the general population, with a prevalence of 7-18% in patients undergoing endoscopy without evidence of BE [16,17]. For these reasons, more accurate markers of response and residual disease are required.

DNA methylation is an epigenetic phenomenon, whereby a methyl group is added to the carbon-5 position of cytosine at the CpG sites, a region consisting of a cytosine nucleotide adjunct to a guanine nucleotide. Dense methylation of gene promoter regions can lead to compacted chromatin structure and transcriptional silencing [18]. It is increasingly recognized that gene expression silencing by promoter methylation plays an important role in cancer development [18], including BE progression to EAC. Our group has previously shown that a multi-gene methylation panel has high diagnostic accuracy for BE when assessed on non-endoscopic Cytosponge™ samples with an area under the ROC curve (AUC) ranging from 78.7% to 87.7% [19]. Moreover, some studies showed a promising role of methylation markers in risk-stratification of BE patients [20,21] and a role in differentiating between non-dysplastic and dysplastic BE [20,22].

In this study, we aimed to evaluate the utility of a methylation panel as an objective test to measure the degree of response to the RFA treatment.

2. Materials and methods

2.1. Study design

We performed a retrospective study analyzing prospectively collected data from patients receiving RFA treatment at a single institution (Addenbrooke’s Hospital, Cambridge University Hospitals NHS Foundation Trust) between the years 2008 and 2018. The study was approved by the ethical committee at the local institution (LREC01/149). Informed consent for biomarker analysis was obtained from each patient before endoscopic treatment.

2.2. Patients

We included patients with endoscopically and histologically confirmed BE (at least 1 cm of columnar-lined mucosa in the tubular esophagus), who underwent RFA for neoplastic BE. Patients were eligible if they achieved endoscopic remission, defined as at least two post-RFA follow-up endoscopies with biopsies taken accordingly to the Seattle protocol [23] (GEJ + quadrantic esophageal biopsies every 2cm) with no evidence of neoplastic epithelium. Evidence of IM at the GEJ was not an exclusion criterion. We used biopsies from at least 3 time points as follows: (i) Pre-RFA biopsies taken within BE; (ii) Post-RFA biopsies taken at the GEJ with or without evidence of IM; (iii) Post-RFA biopsies taken at the GEJ at the last available follow-up endoscopy. For patients with evidence of IM at the GEJ that received clinically indicated re-treatment of the GEJ we also included an intermediate follow-up time point.

2.3. Histology

We analyzed paraffin-embedded 4-quadrant BE and GEJ biopsies. Baseline histology was recorded for all patients and classified accordingly to the Vienna classification [24] as NDBE, indefinite for dysplasia (IND), LGD, HGD, and IMC. Biopsies were examined by an expert GI pathologist and each case of dysplasia was confirmed by a second pathologist. The highest grade of dysplasia detected at baseline (pre-RFA) and during post-RFA surveillance was assigned to that patient. We performed immunohistochemistry staining (IHC) to characterize trefoil factor-3 (TFF3) expression. TFF3 stains were recorded as completely negative (0), non-specific staining (1), cytoplasmic (2) and positive (3). Examples of TFF3 scores are presented in

[4,8,11]. Additionally, given the risk of metachronous cancer following endoscopic mucosal resection (EMR) for early BE-related neoplasia, RFA is also recommended for the treatment of residual BE after EMR [4,7,8]. The efficacy of RFA in achieving complete remission of IM (CR-IM) and dysplasia (CR-D) ranges between 75-88% and 88-92%, respectively [11-13]. Once endoscopic remission is achieved, random biopsies at the gastroesophageal junction (GEJ) are generally taken to detect residual IM, as recurrence is more commonly detected at this site than in the tubular esophagus [14]. If residual IM is identified, further RFA is recommended. It is, however, debated whether IM at the GEJ is a reliable marker of the residual disease since it has a

Table 1
The scoring of intestinal metaplasia (IM-Score).

IM Score	Extent of IM	Number of biopsies with IM
0	No IM	None
1	Focal or Moderate	1
2	Focal or Moderate	≥2
	Extensive	1
3	Extensive	≥2

IM, intestinal metaplasia, Focal IM = goblet cells within one foveola or gland; Moderate IM = goblet cells within 2 to 5 foveola or glands, Extensive IM = goblet cells within more than five glands.

Supplementary Figure 1. The extent of IM in the biopsies was assessed using a scoring system based on a number of glands containing goblet cells, which was adapted from previous studies that quantified the extent of IM in gastric and BE mucosa [25,26]. The amount of IM was assessed as focal (goblet cells within one foveola or gland), moderate (goblet cells within 2 to 5 foveola or glands), or extensive (goblet cells within more than five glands). The total IM-Score included the number of biopsies containing IM and ranged from 0 to 3 as shown in Table 1.

2.4. Radiofrequency ablation

RFA was performed in patients with dysplastic BE or residual BE post EMR using the BARRX™ system (Medtronic, Dublin, Ireland). The BARRX™360, BARRX™60, BARRX™90, BARRX™Ultra or through-the-scope ablation devices were used depending on the length of the BE with selection of the device at the discretion of the operator. An intermediary cleaning phase between ablations was used up until November 2012, after which and following a European consensus meeting, the cleaning phase was abandoned [27]. Patients were scheduled for repeat RFA at approximately three-monthly intervals until endoscopic and histologic remission (CR-IM) was achieved. Endoscopic remission was defined as the lack of visible columnar epithelium at least of 1cm in length. An additional RFA treatment at the GEJ was performed at discretion of the managing physician in case of evidence of IM within an irregular Z-line (tongues shorter than 1 cm). Argon plasma coagulation (APC) was performed at the discretion of the endoscopist to ablate small, visible BE islands during follow-up.

2.5. Methylation panel

DNA promoter methylation of three genes (*ZNF345*, *TFP12*, *ZNF569*) was assessed by a MethyLight PCR assay and a mean value was generated (Meth-Score) [19]. Genomic DNA was extracted from formalin fixed paraffin embedded (FFPE) biopsy sets either from BE or GEJ, each containing four biopsies. Where previous pre-RFA biopsies were not available, DNA was extracted from EMR samples. Briefly, 10 × 10 μM FFPE sections were processed for DNA extraction using de-paraffinization solution and QIAamp FFPE DNA tissue kit as per manufacturer's instructions (Qiagen, Manchester, United Kingdom). The protocol was modified to include a 56°C overnight incubation of the FFPE lysates with 10ul extra of proteinase K. Extracted DNA was bisulfite modified following EZ DNA-Methylation Gold kit instructions (Zymo Research, Irvine, California, USA). The degree of methylation was analyzed by MethyLight using a LightCycler® 480 (Roche diagnostics Ltd, Rotkreuz, Switzerland) with published primers and probes, as previously described [19].

2.6. Statistics

Quantitative variables were described as the mean, median, standard deviation (SD) and interquartile range (IQRs), where appropriate. Categorical variables were presented as counts and percentages

of the cohort. The two-sample Welch's t-test and Wilcoxon rank sum test were used to compare continuous variables and the chi-square test was used to compare categorical data, where appropriate. Pairwise comparisons using Wilcoxon rank sum test with Benjamini–Hochberg *P*-value correction were used to compare methylation levels in GEJ biopsies during remission (GEJ-GM), relapse (GEJ-IM), and different BE grades (NDBE, LGD, HGD/IMC). A paired t-test with Bonferroni correction was used to compare methylation levels between individual time-points of the treatment (Pre-RFA vs. 1st follow-up and Pre-RFA vs. 2nd follow-up). The correlation between the Meth-score and the extent of IM (IM-Score and TFF-Score) was assessed using the Spearman method. The Receiver Operating Characteristic (ROC) curve was performed using pROC package v1.16.1 for R Statistics to calculate the accuracy of methylation panel in differentiating GEJ-GM from BE samples. With the Meth-score being a continuous variable, for every possible methylation level we assessed the best performing cut-off point to optimise sensitivity and specificity. For all analyses, a *P* value of less than 0.05 was considered statistically significant. All analyses were performed using R Statistics version 3.4.3 (R Foundation for Statistical Computing, Vienna, Austria).

3. Results

Forty-five patients were included in the study, of which 38 were male (84.4%), with a median age of 67 years (IQR 61 – 73 years). The median BE segment length was 4 cm (IQR 2-5 cm) and initial BE grades (pre-RFA) included: 11 NDBE (24.4%), 14 LGD (31.1%), 18 HGD (40.0%), and 2 IMC (4.5%). Patients with NDBE in the pre-RFA biopsies had received EMR for neoplastic BE prior to RFA. A summary of the patients' characteristics is presented in Table 2.

In the study cohort, CR-IM was achieved in all 45 patients (100%) with a median of 2 RFA sessions (IQR 1-3). The mean follow-up time was 4.1 years (±1.4 years). All patients (*n*=45) had two post-treatment follow-up endoscopies included in the study period, and 16 of them had an additional third follow-up examination with biopsies included in the study. Prior to RFA, EMR for focal lesions was performed in 28 patients (62.2%). Nearly half of the patients required circumferential treatment with the RFA360 device (*n*=21, 46.7%). After achieving endoscopic remission, 13 patients (28.9%) received an additional RFA treatment following evidence of IM at the GEJ during the first follow-up. The majority of patients (*n*=21, 56.7%) received additional APC treatment for diminutive BE islands after RFA.

We measured methylation levels in a total of 151 biopsy sets, both from BE and the GEJ after treatment, which included 85 biopsy sets from GEJ with GM (56.3%), 21 biopsy sets from GEJ with IM (13.9%); 11 biopsy sets from NDBE (7.3%), 14 biopsy sets from BE with LGD (9.3%) and 20 biopsy sets from BE with HGD/IMC (13.2%). The methylation levels were significantly lower in GEJ-GM biopsies (meth-score of 1.8% ±6.8%) compared to GEJ-IM, NDBE, BE with LGD and BE with HGD/IMC, which had a meth score of 35.9% (±50.7%), 61.8%

Table 2
Patients characteristics.

Demographic and clinical data	Total
Number of patients	45
Age, years, median (IQR)	67 (61 - 73)
Male, n (%)	38 (84.4%)
Presence of Hiatus hernia, n (%)	40 (88.9%)
Initial Barrett's esophagus length; median cm (IQR)	4 (2 – 5)
Pre-RFA grade of Barrett's:	
Intramucosal carcinoma	2 (4.5%)
High-grade dysplasia	18 (40.0%)
Low-grade dysplasia	14 (31.1%)
Intestinal or gastric metaplasia	11 (24.4%)

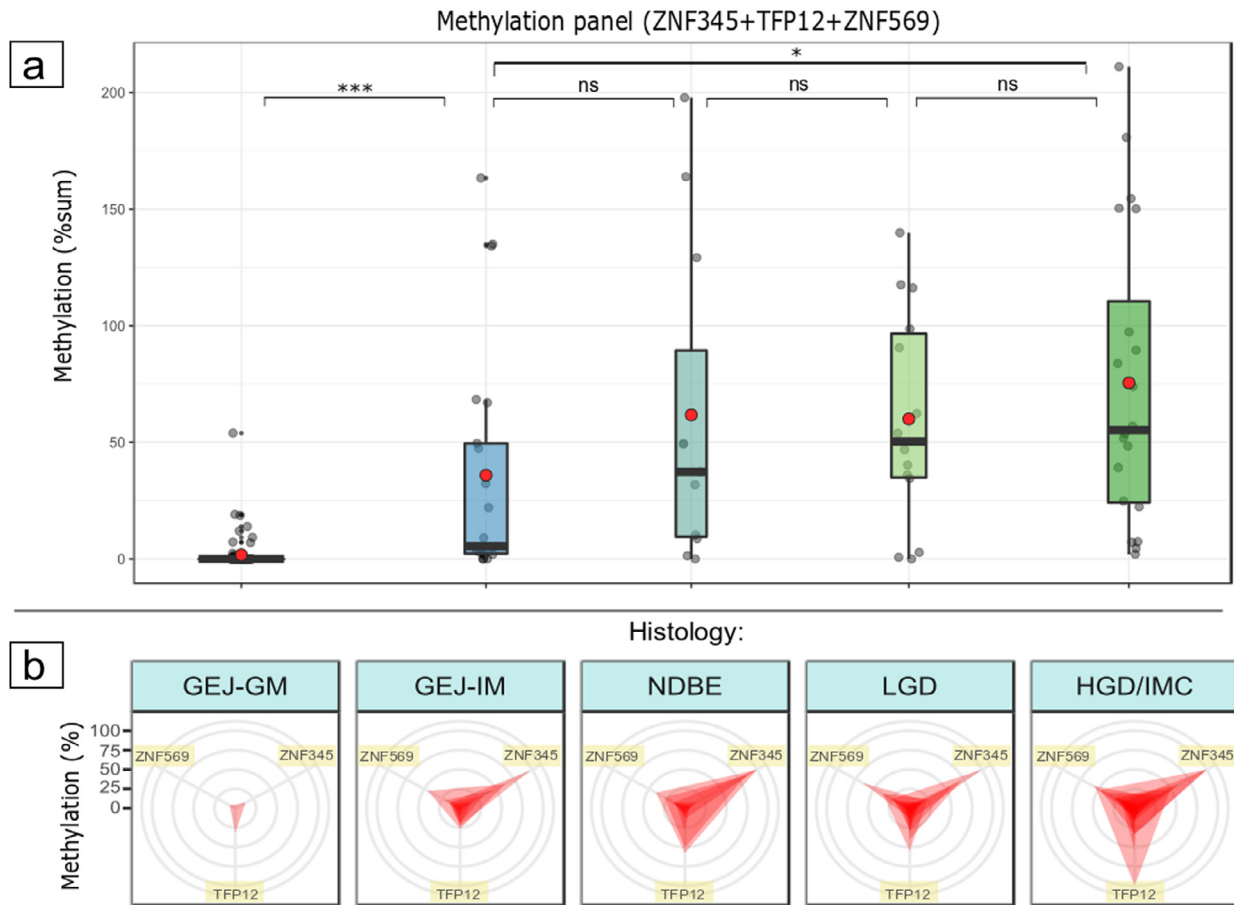


Fig. 1. a. Methylation levels expressed as Meth-score in quadrantic biopsy sets from gastroesophageal junction (without and with IM) and Barrett's esophagus (with different histological grades). **b.** Methylation levels of three individual genes (ZNF345, ZNF569, TFP12) for each of the biopsy sets from panel a.

GEJ-GM; gastroesophageal junction with gastric-type mucosa, GEJ-IM; gastroesophageal junction with intestinal metaplasia, NDBE; non-dysplastic Barrett's esophagus, LGD; low-grade dysplasia, HGD/IMC; high-grade dysplasia / intramucosal cancer.

($\pm 69.4\%$), 60.0% ($\pm 46.0\%$), and 75.5% ($\pm 63.3\%$), respectively ($P < .001$ for all comparisons), (Fig. 1a). When looking at the individual contribution of the three genes, we found that while ZNF345 and ZNF569 differentiated samples based on the Barrett's phenotype, with similar levels among dysplastic stages; whereas TFP12 showed steady increase during the dysplastic progression (Fig. 1b).

We then examined the temporal variation of the Meth-score in individual patients during the treatment pathway. The Meth-Score dropped significantly during the RFA treatment from 67.3% ($\pm 59.2\%$) in the pre-RFA assessment, to 17.5% ($\pm 38.5\%$) at the point of first post-RFA follow-up, and down to 2.28% (± 8.51) at the last follow-up endoscopy ($P < .001$). The methylation values throughout the treatment are listed in Table 3 and illustrated in Fig. 2. The subgroup of patients ($n=13$), who received RFA re-treatment after initial

endoscopic remission due to persistent/relapse of IM at the GEJ (GEJ-IM) showed significant reduction of the methylation levels at the last time point (Fig. 2b), indicating that the additional RFA reversed the methylation levels to a non-BE phenotype. For this reason, we decided to look specifically at the correlation between the extent of IM and the Meth-Score. For this analysis we have used the post-RFA biopsies taken from the GEJ after patients achieved endoscopic remission. Out of 105 biopsy sets, 84 had an IM score of 0 (80.0%), 3 had an IM score of 1 (2.9%), 10 showed an IM score of 2 (9.5%), and 8 had an IM score of 3 (7.6%); the corresponding Meth-scores were 1.8% ($\pm 6.9\%$), 3.0% ($\pm 5.2\%$), 38.5% ($\pm 62.0\%$), and 45.0% ($\pm 42.7\%$) respectively. When we grouped the extent of IM into none/focal IM (IM-scores of 0-1) and diffuse (IM-scores of 2-3), the methylation levels were 1.8% ($\pm 6.8\%$) and 41.4% ($\pm 52.9\%$), respectively. We then determined the correlation between the TFF-Score and methylation levels.

Table 3
Methylation levels throughout the RFA treatment.

Mean methylation for genes: Biopsy site:	Pre-RFA Barrett's	post-RFA (1st follow-up) GEJ	Post-RFA (2nd follow-up) GEJ	P-value*
Methylation panel (%sum)	67.3% ($\pm 59.2\%$)	17.5% ($\pm 38.5\%$)	2.28% (± 8.51)	$P < .001$
ZNF345	26.9% ($\pm 33.7\%$)	9.53% ($\pm 23.2\%$)	0.917% ($\pm 3.55\%$)	$P < .001$
TFP12	19.8% ($\pm 24.2\%$)	3.72% ($\pm 8.35\%$)	0.869% ($\pm 4.74\%$)	$P < .001$
ZNF569	17.8% ($\pm 17.0\%$)	4.64% ($\pm 10.4\%$)	0.525% ($\pm 1.41\%$)	$P < .001$

* - paired t-test with Bonferroni correction; GEJ, Gastroesophageal junction.

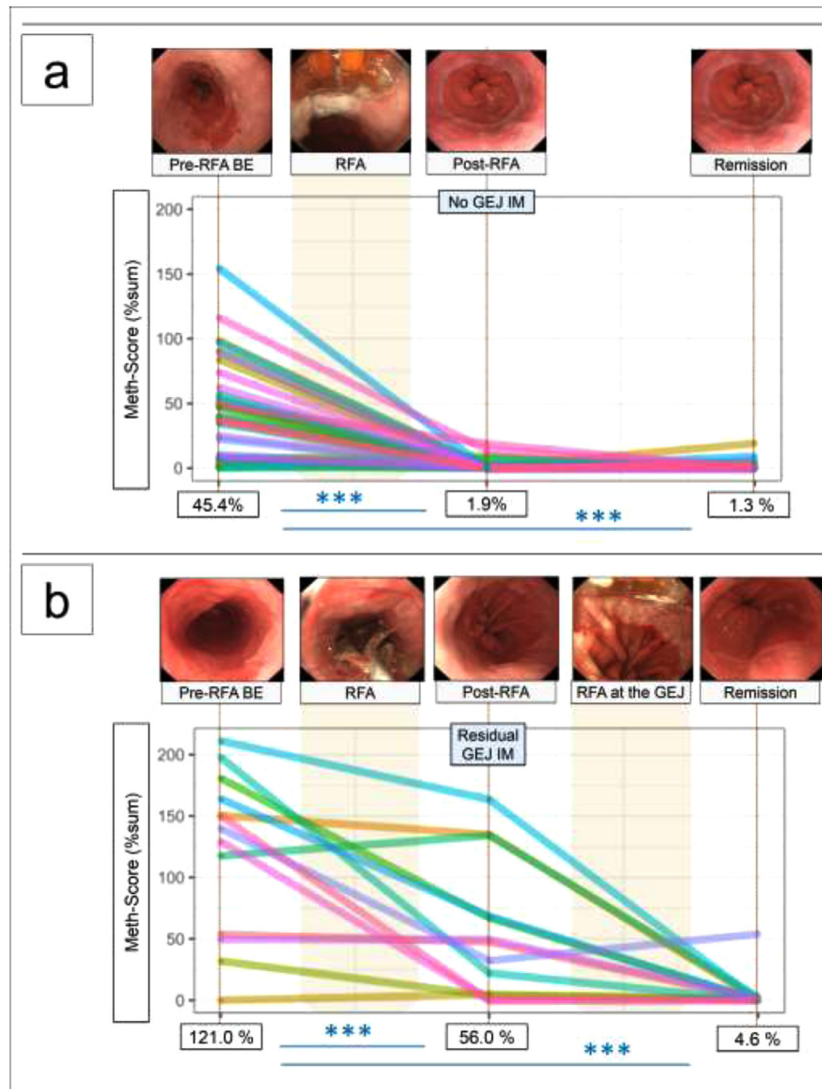


Fig. 2. Methylation levels throughout the RFA treatment were assessed for individual patients at 3 time points, corresponding to pre-RFA BE, first post-RFA follow-up and last time point. Values below the “y” axis represent the mean methylation scores for each time-point compared with a paired t-test. **a.** Patients achieving durable remission after the course of RFA treatment (n=13). **b.** Patients with evidence of IM at the GEJ during the follow-up, hence, which was treated with an additional session of RFA for the GEJ (n=32).

BE, Barrett’s esophagus; GEJ, gastroesophageal junction; IM, intestinal metaplasia; RFA, radiofrequency ablation.

The biopsy sets were divided based on the intensity and distribution of TFF3 staining into TFF3-scores 0 (n=51), 1 (n=10), 2 (n=9) and 3 (n=20); the corresponding Meth-scores were 0.1% ($\pm 0.6\%$), 5.5% ($\pm 7.8\%$), 2.83% ($\pm 4.8\%$), and 40.2% ($\pm 50.8\%$), respectively. The Meth-scores correlated significantly with the amount of IM represented both by the IM-Score ($\rho=64.6\%$, $P<.001$), and the TFF-Score ($\rho=75.6\%$, $P<.001$), as presented in Fig. 3. The Meth-Score performed better than any of the genes separately (*ZNF345*, *TFPI2*, *ZNF569*), in terms of correlation with the amount of IM as shown in Supplementary Figure 2.

In order to develop a clinically useful test to differentiate biopsies from diseased tissue from physiological GEJ mucosa, we performed an ROC curve analysis to test the diagnostic ability of the Meth-Score to distinguish BE from normal GEJ tissue. With a threshold value of 1.2%, the Meth-Score had an area under the ROC curve (AUC) of 95.1% (95CI 91.1% - 99.1%), as shown in Fig. 4. The sensitivity, specificity, positive predictive value and negative predictive value for differentiating the Barrett’s phenotype from the GEJ phenotype during remission were 93.3%, 88.2%, 80.8% and 96.2%, respectively. Using this threshold of Meth-Score, we could divide the 21 GEJ biopsy sets with any evidence of IM,

in 18 (85.7%) true relapse (Barrett’s phenotype) and 3 (14.3%) no relapse (GEJ phenotype).

4. Discussion

In this study we identified a molecular biomarker that helps diagnose persistent or recurrent BE in patients who underwent RFA.

Endoscopic ablation with RFA is recommended as treatment of dysplastic BE. Following endoscopic remission, which is generally defined as complete reversion of glandular into neo-squamous epithelium, the current practice is to take biopsies within the esophagus as well as at the GEJ to confirm the absence of IM or dysplasia. Histological remission is generally defined as the absence of IM in patients who have achieved endoscopic remission. There is significant variation in the medical literature over the definition of complete histological remission. In the early studies, histological remission was defined as absence of IM in both esophageal and GEJ biopsies [12,13]. In a prospective multicentre study involving 132 patients with BE-related neoplasia treated with RFA and 2.5 years median follow up, it was noted that 24% of patients who achieved endoscopic remission had IM at the GEJ [15]. However, in the majority of cases this was

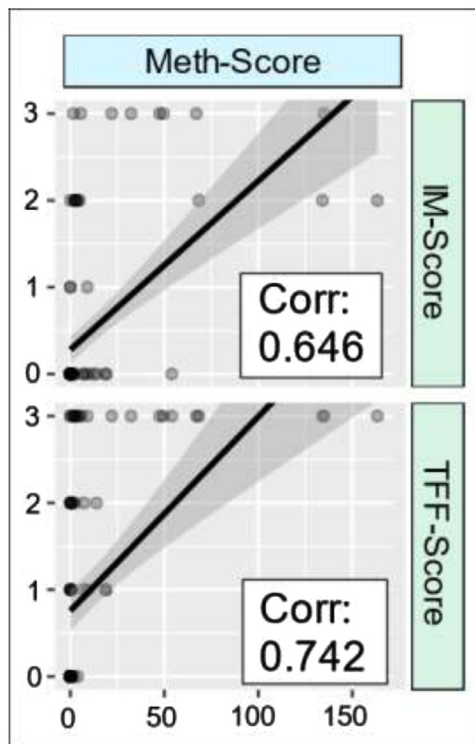


Fig. 3. A scatterplot representing the comparison of Meth-Score and the amount of intestinal metaplasia measured by IM-Score (number of goblet cells, top panel) and TFF3-Score measure by immunohistochemical staining (bottom panel). Values in the box represent the correlation coefficients (Spearman method).

transient and difficult to reproduce at follow up and did not progress to higher grades. This finding questions the real significance of focal IM at the GEJ and would not support a strategy based on re-treatment of the GEJ in the presence of focal IM. IM in this anatomical region is a

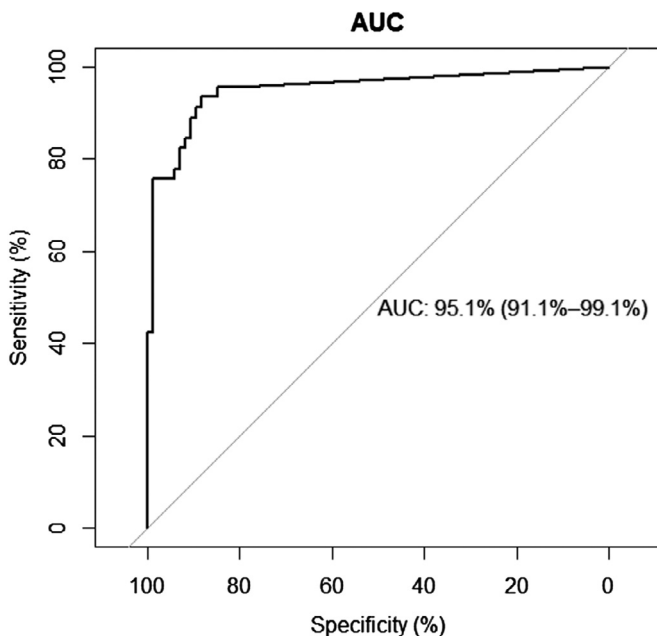


Fig. 4. Area Under the ROC curve to assess the accuracy of the Meth-Score in differentiating Barrett's oesophagus from normal GEJ mucosa after endoscopic and histological remission.

common findings in individuals without BE [16,28,29]. The definition of histological remission is also key to understand the risk of recurrence post RFA. Many studies have showed very high risk of recurrence, up to 40% in 5 years, which likely reflect a liberal inclusion of focal IM at the GEJ in the definition of disease relapse [11,30]. Finally, this definition has implication for patient management, particularly if IM at the GEJ is considered as an indication for additional RFA. This suggests that better markers of residual disease are required in order to guide patient management.

The utility of the methylation panel described in this study is several fold. First, this biomarker panel provides an objective measure of disease phenotype. IM can be subjective and can be mistaken for pseudo-IM. In addition, the quantification of IM is not done in routine clinical practice, as pathologists do not count the number of glands with features of IM. Second, our biomarker panel not only detects the BE phenotype but is sensitive to the presence of dysplasia. It has been observed that often dysplastic progression is accompanied by loss of IM in the background mucosa and also that the GEJ and esophageal adenocarcinoma can occur in the absence of IM [31]. For this reason, the methylation panel presented in our study has the potential to offer a risk stratification tool, also in the absence of visible IM. Third, we developed this test to be applicable with formalin-fixed biopsies even after diagnostic histopathology, which means that this test is compatible with routine clinical practice and does not require additional biopsies or special sample preservation.

This study has however some limitations. This is a retrospective single centre study with no formal sample size calculation. This was an exploratory investigation to develop the biomarker rather than validate its clinical applicability. In order to do this, we have tested a large number of biopsies with several time points, including different group of patients, *i.e.* those with durable response, patients with focal IM at the GEJ that were followed up endoscopically, as well as patients with post RFA GEJ-IM treated at the discretion of the managing clinician. Furthermore, we did not have any patients that developed recurrent neoplasia at the GEJ on follow up, therefore we could not validate this biomarker as a risk stratification tool. A prospective study is currently underway to test this panel in real-time in a large patient cohort undergoing endoscopic follow up post RFA. Finally, the source of DNA to perform this study was archive DNA from a historical cohort. Although methylation assays have been performed successfully by our group on FFPE tissue with comparable results to fresh frozen samples [20], there is evidence that tissue preserved in formalin-free fixation reagents can improve quality of the DNA [32]. For clinical implementation of methylation biomarkers strategies, formalin-free fixation strategies should be considered.

In summary, the methylation panel presented in this study has high diagnostic accuracy in differentiating BE from physiological GEJ tissue and has the potential to assist the clinician in identifying BE recurrence at the GEJ. Future studies are required to define the best diagnostic cut-off.

Funding Sources

This study was funded by an MRC core grant to RCF. WJ was funded by a Cancer Research UK multidisciplinary award (C47594/A21202).

Declaration of Competing Interest

RCF declares financial involvement with Cyted Ltd, outside of the submitted work. RCF declares a patent licensed to Medtronic (US20120009597A1). All other authors declare no conflict of interest.

Author contributions

Study concept and design (MDP, RCF), endoscopic treatment and patients' management (MDP, WJ), data collection (MDP, WJ, WW, GB), laboratory assays (VVS, DF, GB, HC), histopathological diagnoses (AM, MOD), statistical analysis (WJ), data analysis and interpretation (WJ, VVS, WW, MDP), drafting of manuscript (WJ and MDP), critical revision of manuscript (ALL).

Acknowledgements

Authors would like to thank Emma Leeman for her significant help with Methylight experiments and Marcel Gehrung for his help with data presentation.

Supplementary materials

Supplementary material associated with this article can be found, in the online version, at [doi:10.1016/j.ebiom.2020.102877](https://doi.org/10.1016/j.ebiom.2020.102877).

References

- [1] Arnold M, Soerjomataram I, Ferlay J, Forman D. Global incidence of oesophageal cancer by histological subtype in 2012. *Gut* 2015;64:381–7. doi: [10.1136/gutjnl-2014-308124](https://doi.org/10.1136/gutjnl-2014-308124).
- [2] Coleman HG, Xie SH, Lagergren J. The epidemiology of esophageal adenocarcinoma. *Gastroenterology* 2018;154:390–405. doi: [10.1053/j.gastro.2017.07.046](https://doi.org/10.1053/j.gastro.2017.07.046).
- [3] Spechler SJ, Souza RF. Barrett's Esophagus. *N Engl J Med* 2014;371:836–45. doi: [10.1056/NEJMra1314704](https://doi.org/10.1056/NEJMra1314704).
- [4] Fitzgerald RC, di Pietro M, Ragunath K, Ang Y, Kang JY, Watson P, et al. British Society of Gastroenterology guidelines on the diagnosis and management of Barrett's oesophagus. *Gut* 2014;63:7–42. doi: [10.1136/gutjnl-2013-305372](https://doi.org/10.1136/gutjnl-2013-305372).
- [5] Desai TK, Krishnan K, Samala N, Singh J, Cluley J, Perla S, et al. The incidence of oesophageal adenocarcinoma in non-dysplastic Barrett's oesophagus: a meta-analysis. *Gut* 2012;61:970–6. doi: [10.1136/gutjnl-2011-300730](https://doi.org/10.1136/gutjnl-2011-300730).
- [6] Rastogi A, Puli S, El-Serag HB, Bansal A, Wani S, Sharma P. Incidence of esophageal adenocarcinoma in patients with Barrett's esophagus and high-grade dysplasia: a meta-analysis. *Gastrointest Endosc* 2008;67:394–8. doi: [10.1016/j.gie.2007.07.019](https://doi.org/10.1016/j.gie.2007.07.019).
- [7] Shaheen NJ, Falk GW, Iyer PG, Gerson LB. American College of G. ACG Clinical Guideline: Diagnosis and Management of Barrett's Esophagus. *Am J Gastroenterol* 2016;111:30–50 quiz 5. doi: [10.1038/ajg.2015.322](https://doi.org/10.1038/ajg.2015.322).
- [8] Weusten B, Bisschops R, Coron E, Dinis-Ribeiro M, Dumonceau JM, Esteban JM, et al. Endoscopic management of Barrett's esophagus: European Society of Gastrointestinal Endoscopy (ESGE) Position Statement. *Endoscopy* 2017;49:191–8. doi: [10.1055/s-0042-122140](https://doi.org/10.1055/s-0042-122140).
- [9] di Pietro M, Fitzgerald RC, group BSGB guidelines working. Revised British Society of Gastroenterology recommendation on the diagnosis and management of Barrett's oesophagus with low-grade dysplasia. *Gut* 2017. doi: [10.1136/gutjnl-2017-314135](https://doi.org/10.1136/gutjnl-2017-314135).
- [10] Pouw RE, Sharma VK, Bergman JJ, Fleischer DE. Radiofrequency ablation for total Barrett's era—dication: a description of the endoscopic technique, its clinical results and future prospects. *Endoscopy* 2008;75:233–45. doi: [10.1055/s](https://doi.org/10.1055/s).
- [11] Haidry RJ, Dunn JM, Butt MA, Burnell MG, Gupta A, Green S, et al. Radiofrequency ablation and endoscopic mucosal resection for dysplastic Barrett's esophagus and early esophageal adenocarcinoma: Outcomes of the UK national halo RFA registry. *Gastroenterology* 2013;145:87–95. doi: [10.1053/j.gastro.2013.03.045](https://doi.org/10.1053/j.gastro.2013.03.045).
- [12] Shaheen NJ, Sharma P, Overholt BF, Wolfsen HC, Sampliner RE, Wang KK, et al. Radiofrequency Ablation in Barrett's Esophagus with Dysplasia. *N Engl J Med* 2009;360:2277–88. doi: [10.1056/NEJMoa0808145](https://doi.org/10.1056/NEJMoa0808145).
- [13] Phoa KN, van Vilsteren FGI, Weusten BLAM, Bisschops R, Schoon EJ, Ragunath K, et al. Radiofrequency Ablation vs Endoscopic Surveillance for Patients With Barrett Esophagus and Low-Grade Dysplasia. *JAMA* 2014;311:1209. doi: [10.1001/jama.2014.2511](https://doi.org/10.1001/jama.2014.2511).
- [14] Overholt BF, Madanick RD, Sampliner RE, Eisen GM, Fleischer DE, Sharma P, et al. Durability of Radiofrequency Ablation in Barrett's Esophagus With Dysplasia. *Gastroenterology* 2011;141:460–8. doi: [10.1053/j.gastro.2011.04.061](https://doi.org/10.1053/j.gastro.2011.04.061).
- [15] Phoa KN, Pouw RE, Bisschops R, Pech O, Ragunath K, Weusten BLAM, et al. Multimodality endoscopic eradication for neoplastic Barrett oesophagus: Results of an European multicentre study (EURO-II). *Gut* 2016;65:555–62. doi: [10.1136/gutjnl-2015-309298](https://doi.org/10.1136/gutjnl-2015-309298).
- [16] Spechler SJ, Zeroogian JM, Antonioli DA, Wang HH, Goyal RK. Prevalence of metaplasia at the gastro-oesophageal junction. *Lancet* 1994;344:1533–6. doi: [10.1016/S0140-6736\(94\)90349-2](https://doi.org/10.1016/S0140-6736(94)90349-2).
- [17] Siddiki HA, Lam-Himlin DM, Kahn A, Bandres MV, Burdick GE, Crowell MD, et al. Intestinal metaplasia of the gastric cardia: findings in patients with versus without Barrett's esophagus. *Gastrointest Endosc* 2019;89:759–68. doi: [10.1016/j.gie.2018.10.048](https://doi.org/10.1016/j.gie.2018.10.048).
- [18] Laird PW. The power and the promise of DNA methylation markers. *Nat Rev Cancer* 2003;3:253–66. doi: [10.1038/nrc1045](https://doi.org/10.1038/nrc1045).
- [19] Chettouh H, Mowforth O, Galeano-Dalmau N, Bezawada N, Ross-Innes C, Macrae S, et al. Methylation panel is a diagnostic biomarker for Barrett's oesophagus in endoscopic biopsies and non-endoscopic cytology specimens. *Gut* 2017;67:1942–9. doi: [10.1136/gutjnl-2017-314026](https://doi.org/10.1136/gutjnl-2017-314026).
- [20] Alvi MA, Liu X, O'Donovan M, Newton R, Wernisch L, Shannon NB, et al. DNA methylation as an adjunct to histopathology to detect prevalent, inconspicuous dysplasia and early-stage neoplasia in Barrett's esophagus. *Clin Cancer Res* 2013;19:878–88. doi: [10.1158/1078-0432.CCR-12-2880](https://doi.org/10.1158/1078-0432.CCR-12-2880).
- [21] Dilworth MP, Nieto T, Stockton JD, Whalley CM, Tee L, James JD, et al. Whole genome methylation analysis of nondysplastic barrett esophagus that progresses to invasive cancer. *Ann Surg* 2019;269:479–85. doi: [10.1097/SLA.0000000000002658](https://doi.org/10.1097/SLA.0000000000002658).
- [22] Moinova HR, LaFramboise T, Lutterbaugh JD, Chandar AK, Dumot J, Faulx A, et al. Identifying DNA methylation biomarkers for non-endoscopic detection of Barrett's esophagus. *Sci Transl Med* 2018;10. doi: [10.1126/scitranslmed.aao5848](https://doi.org/10.1126/scitranslmed.aao5848).
- [23] Levine DS, Haggitt RC, Blount PL, Rabinovitch PS, Rusch VW, Reid BJ. An endoscopic biopsy protocol can differentiate high-grade dysplasia from early adenocarcinoma in Barrett's esophagus. *Gastroenterology* 1993;105:40–50. doi: [10.1016/0016-5085\(93\)90008-Z](https://doi.org/10.1016/0016-5085(93)90008-Z).
- [24] Dixon MF. Gastrointestinal epithelial neoplasia: Vienna revisited. *Gut* 2002;51:130–1. doi: [10.1136/gut.51.1.130](https://doi.org/10.1136/gut.51.1.130).
- [25] Weston AP, Sharma P, Mathur S, Banerjee S, Jafri AK, Cherian R, et al. Risk stratification of Barrett's esophagus: updated prospective multivariate analysis. *Am J Gastroenterol* 2004;99:1657–66. doi: [10.1111/j.1572-0241.2004.30426.x](https://doi.org/10.1111/j.1572-0241.2004.30426.x).
- [26] Goldstein NS. Gastric cardia intestinal metaplasia: Biopsy follow-up of 85 patients. *Mod Pathol* 2000;13:1072–9. doi: [10.1038/modpathol.3880198](https://doi.org/10.1038/modpathol.3880198).
- [27] Tan WK, Ragunath K, White JR, Santiago J, Fernandez-Sordo JO, Pana M, et al. Standard versus simplified radiofrequency ablation protocol for Barrett's esophagus: comparative analysis of the whole treatment pathway. *Endosc Int Open* 2020;08:E189–95. doi: [10.1055/a-1005-6331](https://doi.org/10.1055/a-1005-6331).
- [28] Hirota WK, Loughney TM, Lazas DJ, Maydonovitch CL, Rholi V, Wong RKH. Specialized intestinal metaplasia, dysplasia, and cancer of the esophagus and esophagogastric junction: Prevalence and clinical data. *Gastroenterology* 1999;116:277–85. doi: [10.1007/s004640090025](https://doi.org/10.1007/s004640090025).
- [29] Wallner B, Sylvan A, Stenling R, Janunger KG. The Z-line appearance and prevalence of intestinal metaplasia among patients without symptoms or endoscopic signs indicating gastroesophageal reflux. *Surg Endosc* 2001;15:886–9. doi: [10.1007/s004640090025](https://doi.org/10.1007/s004640090025).
- [30] Haidry RJ, Lipman G, Banks MR, Butt MA, Sehgal V, Graham D, et al. Comparing outcome of radiofrequency ablation in Barrett's with high grade dysplasia and intramucosal carcinoma: A prospective multicenter UK registry. *Endoscopy* 2015;47:980–7. doi: [10.1055/s-0034-1392414](https://doi.org/10.1055/s-0034-1392414).
- [31] Takubo K, Aida J, Naomoto Y, Sawabe M, Arai T, Shiraishi H, et al. Cardiac rather than intestinal-type background in endoscopic resection specimens of minute Barrett adenocarcinoma. *Hum Pathol* 2009;40:65–74. doi: [10.1016/j.humpath.2008.06.008](https://doi.org/10.1016/j.humpath.2008.06.008).
- [32] Groelz D, Viertler C, Pabst D, Dettmann N, Zatloukal K. Impact of storage conditions on the quality of nucleic acids in paraffin embedded tissues. *PLoS One* 2018;13. doi: [10.1371/journal.pone.0203608](https://doi.org/10.1371/journal.pone.0203608).