



# Faricimab: Transforming the Future of Macular Diseases Treatment - A Comprehensive Review of Clinical Studies

Georgios D Panos <sup>1,2</sup>, Arun Lakshmanan<sup>1</sup>, Panagiotis Dadoukis<sup>3</sup>, Matteo Ripa <sup>4</sup>, Lorenzo Motta<sup>4</sup>, Winfried M Amoaku<sup>1,2</sup>

<sup>1</sup>Department of Ophthalmology, Queen's Medical Centre, Nottingham University Hospitals, Nottingham, UK; <sup>2</sup>Division of Ophthalmology and Visual Sciences, Faculty of Medicine & Health Sciences, School of Medicine, University of Nottingham, Nottingham, UK; <sup>3</sup>Eye Treatment Centre, Whipps Cross University Hospital, Barts Health NHS Trust, London, UK; <sup>4</sup>Department of Ophthalmology, William Harvey Hospital, East Kent Hospitals University NHS Foundation Trust, Kent, UK

Correspondence: Georgios D Panos, Department of Ophthalmology, Queen's Medical Centre, Derby Road, Lenton, Nottingham, NG7 2UH, UK, Tel +44 115 924 9924, Email [gpanos@gmail.com](mailto:gpanos@gmail.com); Lorenzo Motta, Department of Ophthalmology, William Harvey Hospital, Kennington Road, Willesborough, Ashford, Kent, TN24 0LZ, UK, Tel +44 1233 633331, Email [lorenzo.motta@nhs.net](mailto:lorenzo.motta@nhs.net)

**Abstract:** Degenerative eye conditions such as age-related macular degeneration (AMD), diabetic retinopathy, and retinal vein occlusion are major contributors to significant vision loss in developed nations. The primary therapeutic approach for managing complications linked to these diseases involves the intravitreal delivery of anti-vascular endothelial growth factor (VEGF) treatments. Faricimab is a novel, humanised, bispecific antibody that simultaneously binds all VEGF-A isoforms and Angiopoietin-2, which has been approved by regulatory agencies, such as the US Food and Drug Administration (FDA), the UK Medicines and Healthcare products Regulatory Agency (MHRA) and the European Medicines Agency (EMA), for the treatment of neovascular AMD and diabetic macular oedema (DMO). Intravitreal faricimab holds the promise of reducing the treatment burden for patients with these conditions by achieving comparable or superior therapeutic outcomes with fewer clinic visits. The scope of faricimab's application includes addressing complex macular conditions such as DMO. This review intends to elucidate the distinctive pharmacological characteristics of faricimab and provide an overview of the key clinical trials and real-world studies that assess its effectiveness and safety in treating degenerative macular diseases.

**Keywords:** degenerative macular disorders, faricimab, anti-VEGF, efficacy, safety, intravitreal treatment, age-related macular degeneration, diabetic macular oedema, retinal vein occlusion, diabetic retinopathy

## Introduction

Age-related macular degeneration (AMD), diabetic macular oedema (DMO) and retinal vein occlusion-related macular oedema (RVO-MO) have been identified as key contributors to global blindness and visual impairment.<sup>1,2</sup> These conditions, which damage the vital centre of the retina, the macula, can be devastating in terms of central vision loss, and subsequently quality of life.

AMD is a significant cause of vision impairment among the elderly population and has been classified into two forms: dry or non – neovascular and wet or neovascular (nAMD).<sup>1</sup> The latter occurs when a choroidal neovascular membrane (CNV) develops beneath the macula leading to intra- and subretinal leakage and fibrotic lesions in the macular area and without timely treatment will result in severe loss of central vision.<sup>3</sup>

DMO and RVO-MO, on the other hand, are vascular complications associated with systemic conditions such as diabetes and hypertension. DMO is characterised by the accumulation of fluid in the macula due to damaged blood vessels, while RVO-MO is caused by the occlusion of the retinal veins, leading to retinal hemorrhages and macular oedema.<sup>4,5</sup>

Current treatment options predominantly involve intravitreal injections of anti-vascular endothelial growth factor (anti-VEGF) agents such as Ranibizumab, Aflibercept, Brolucizumab and Bevacizumab.<sup>3,6–10</sup> These agents inhibit VEGF, a protein which promotes angiogenesis and vascular permeability, and can lead to the pathological neovascularisation and fluid accumulation observed in the above conditions.<sup>11</sup>

These treatments, while revolutionary for the management of the conditions mentioned above, pose substantial challenges. The frequent injections required for efficacy present both a significant treatment burden and risks of complications.<sup>12</sup> Furthermore, some patients exhibit an incomplete response to these therapies, underlining the necessity for treatments with novel mechanisms of action.<sup>13</sup>

Faricimab, a novel bispecific antibody, offers potential solutions to these challenges. Engineered to simultaneously bind and neutralise Angiopoietin-2 (Ang-2) and VEGF-A, faricimab targets two key pathways involved in nAMD pathogenesis.<sup>14</sup> This dual mechanism of action could provide a more comprehensive therapeutic effect and durable response, potentially reducing the frequency of treatment.

This review aims to examine the clinical studies surrounding faricimab, exploring its potential as a potent tool for the treatment of macular conditions, including AMD, DMO and RVO-MO.

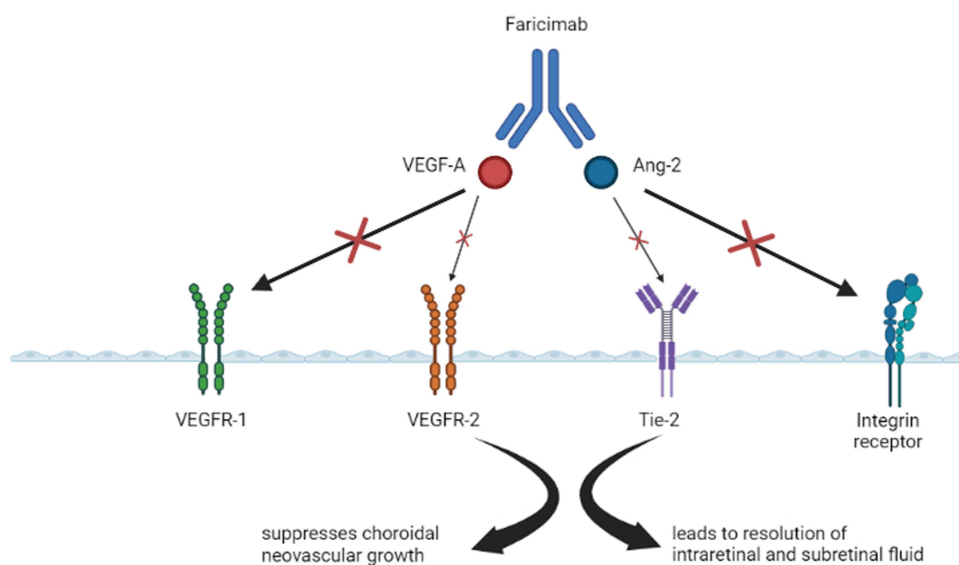
## Pharmacology of Faricimab: Molecular Characteristics and Pharmacokinetics

Faricimab, a pioneering bispecific antibody, emerges on the therapeutic landscape for macular diseases, particularly DMO and nAMD. Notably, faricimab concurrently targets angiopoietin-2 (Ang-2) and vascular endothelial growth factor A (VEGF-A), disrupting two pivotal signaling pathways in the pathogenesis of these conditions (Figure 1).<sup>15,16</sup>

Faricimab is a fully human 150-kDa monoclonal antibody of bispecific design. Its unique architecture is born from the CrossMAb technology, which allows for the development of bispecific antibodies with a structure akin to that of a typical immunoglobulin, complete with two distinct antigen-binding fragments.<sup>17</sup>

Faricimab binds and neutralises both VEGF-A, a key driver of neovascularisation and vascular permeability, and Ang-2, a critical regulator of vascular stability.<sup>17,18</sup> Accordingly, the simultaneous inhibition of these pathways offers the potential for comprehensive therapeutic efficacy compared to existing VEGF-A inhibitors.<sup>19</sup>

Intravitreal administration of faricimab results in dispersal within the vitreous humour and subsequent binding to free VEGF-A and Ang-2 proteins. Faricimab's VEGF-A inhibition curtails neovascularisation and vascular permeability,



**Figure 1** Mechanism of action of Faricimab.

thereby reducing the retinal fluid accumulation that induces vision loss in macular diseases.<sup>18</sup> Concurrently, its binding to Ang-2 disrupts vascular destabilisation, further countering retinal fluid accumulation.<sup>18,20</sup>

Faricimab successfully treated spontaneous CNV lesions with reduced neurone loss, inhibited VEGF-induced endothelial barrier breakdown, showed good safety and tolerability in preclinical studies and a Phase I clinical trial, and demonstrated improvements in BCVA and anatomical parameters.<sup>17,21,22</sup>

A Phase II clinical trial suggests that faricimab's duration of action may extend beyond existing intraocular anti-VEGF therapy with ranibizumab, thus permitting a less frequent dosing schedule (faricimab Q12W or Q16W vs ranibizumab Q4W).<sup>14</sup> This characteristic could significantly alleviate the treatment burden for patients and healthcare systems.

Faricimab plasma concentrations showed a dose-proportional rise after intravitreal administration, ranging from 0.5 to 3 mg. The exposure was similar in both 3-mg and 6-mg doses.<sup>22</sup> Faricimab reaches its peak plasma levels around 2 days after being administered and does not accumulate in the vitreous or plasma even if given through repeated intravitreal injections.<sup>23</sup> Faricimab is believed to be broken down into peptides and amino acids similar to endogenous IgG through lysosomal catabolism, but its exact pathways are not yet understood.<sup>23</sup> The mean apparent systemic and vitreous half-life of faricimab is roughly 7.5 days.<sup>23,24</sup> Comprehensive exploration of faricimab's exact clearance rates, systemic absorption, and overall pharmacokinetic profile in humans remains a subject of ongoing investigation.

Faricimab's molecular characteristics and pharmacokinetics underscore its potential as a promising, long-acting treatment option for macular conditions. However, the detailed landscape of its therapeutic performance will only fully emerge through the ongoing scrutiny of clinical trial outcomes and post-marketing surveillance.

## Faricimab in nAMD

### Phase II Trials

STAIRWAY was a Phase II, multicentre, randomised trial that utilised a comparator-controlled design in order to assess the efficacy of extended faricimab dosing in comparison to monthly ranibizumab.<sup>14</sup> The study enrolled treatment-naive patients with nAMD, who were then randomly assigned to one of the three groups, each in a 1:2:2 ratio.

Patients in each group were administered either ranibizumab 0.5 mg every 4 weeks, faricimab 6 mg every 12 weeks, or faricimab 6 mg every 16 weeks, respectively.

Patients in the faricimab groups received monthly injections as a loading dose until the end of Week 12. If patients who received faricimab Q16W displayed evidence of disease activity at Week 24, upon assessment of the predefined criteria for activity, they were deemed appropriate to transition to a dosing regimen of one injection every 12 weeks. At Week 40, the mean change in best corrected visual acuity (BCVA) was the primary endpoint taken into consideration, while anatomical structural improvement and safety constituted the secondary endpoints.

No clinically significant differences were observed between the groups treated with faricimab and ranibizumab. Additionally, the secondary endpoints of the mean change in central subfield thickness (CST) and overall lesion area were akin to the ranibizumab treatment, which highlights the efficacy of faricimab in addressing both anatomical and visual outcomes.

The AVENUE study was a Phase II, multi-dose (MD)-regimen, comparator-controlled, multicenter randomised trial aimed at evaluating the safety and effectiveness of faricimab in comparison to ranibizumab for treatment-naive patients with nAMD.<sup>25</sup> In this trial, patients were randomly assigned to five different treatment groups, with a ratio of 3:2:2:2:3. The initial arm was utilised as a control group, where patients were administered ranibizumab 0.5 mg every 4 weeks (Q4W). Faricimab was administered in three different treatment arms; specifically 1.5 mg administered every 4 weeks (Q4W), 6 mg administered every 4 weeks (Q4W), and 6 mg administered every 4 weeks until Week 12, followed by a 6 mg dose administered every 8 weeks (Q8W). For the final treatment regimen, patients were administered ranibizumab 0.5 mg Q4W until Week 8. Subsequently, they were transitioned to faricimab 6 mg Q4W. The mean BCVA change was identified as the primary endpoint, while evaluate anatomic and safety parameters were the secondary endpoints.

It was observed that the various treatment arms involving faricimab had improved BCVA and anatomic attributes, at week 36, including a significant reduction in CST, much akin to the arm receiving monthly ranibizumab. Moreover, a comparative analysis of ocular and systemic safety outcomes between faricimab and monthly ranibizumab demonstrated analogous findings, with no

significant occurrences of treatment-related serious adverse events. Despite failing to demonstrate superiority over ranibizumab in the AVENUE trial, the overall positive visual and anatomical outcomes of faricimab supported the need for continued research and clinical trials.

## Phase III Trials

After successful phase II trials, two phase III trials (TENAYA and LUCERNE), with an identical design, were conducted worldwide. These were randomised, double-masked trials that examined the sustained efficacy of faricimab for nAMD, using personalised treatment intervals of up to Q16W.<sup>19</sup> Patients from 271 sites, from all over the world, were assigned randomly to receive 6 mg of faricimab or 2 mg of aflibercept in a 1:1 ratio. The faricimab group received four Q4W injections up to Week 12 as the initial dose. Following the initial loading dose, patients were set for dosing intervals of Q8W, Q12W, or Q16W, contingent on the activity of their disease at designated time points prior to Week 60. Aflibercept patients received 3 injections at 4 week intervals for the first 8 weeks and then received injections every 8 weeks until the 60th week. The primary endpoint was mean BCVA change from the start of the study to Year 1, measured at Weeks 40, 44, and 48, and ensure that the difference was no more than four letters (non-inferiority margin). Analyses of safety profile involved subjects who were administered the study treatment at least once.

Faricimab demonstrated non-inferiority to aflibercept in both TENAYA and LUCERNE trials, meeting the primary endpoints. The changes in BCVA between the treatment groups fell within the non-inferiority boundary of four letters (TENAYA=0.7 letters; LUCERNE=0.0 letters). Moreover, in both studies, 78% of patients managed to achieve dosing at or beyond every 12 weeks, and 45% of patients attained the longest dosing interval of every 16 weeks by the end of the first year, suggesting the long-lasting effect of faricimab treatment. Faricimab treatment resulted in CST reduction similar to the aflibercept group. The occurrence of eye-related side effects was alike among all groups and in line with anticipated effects in people getting intravitreal nAMD treatment. No occurrences of retinal occlusive events or vasculitis were reported in the studies.

The outcomes from the Japanese subgroup of the Phase 3 TENAYA trial indicated that the adjusted mean BCVA changes were +7.1 and +7.7 letters for the faricimab and aflibercept treatment groups, respectively. By week 48, the faricimab group had 66.1%, 22.6%, and 11.3% of patients on Q16W, Q12W, Q8W dosing schedules, respectively. The rates of ocular adverse events were comparable between the treatment groups (faricimab, n = 14 [21.2%] versus aflibercept, n = 17 [25.4%]).<sup>26</sup> In general, the safety outcomes in the TENAYA Japan subgroup are aligned with the combined global TENAYA/LUCERNE trial outcomes.

Publication of data for Year 2 is expected with great interest for both TENAYA and LUCERNE, and patients receiving faricimab are being given customised interval dosing from every 8 weeks to every 16 weeks up to Week 108, followed by a final visit at Week 112. Genentech stated the following, about the TENAYA and LUCERNE studies Year 2 results, in a news release:<sup>27</sup>

- Over 60% of faricimab patients could be treated quarterly with similar vision improvements compared to those receiving bi-monthly aflibercept, an increase of about 15% from the initial analysis at Year 1.
- About 80% of faricimab recipients could have treatment intervals of 3 months or more.
- Faricimab-treated patients had a median number of 10 injections over 2 years, while those treated with aflibercept had 15.
- Faricimab given every 4 months showed similar reduction in CST compared to aflibercept given every 2 months.
- Faricimab remained well tolerated with no new safety concerns.

## Real World Studies

Recent real-world studies have provided supportive data that complement the results of clinical trials, further establishing the efficacy and safety of faricimab in the treatment of nAMD.

In a retrospective study from a US Retina Centre, faricimab was evaluated in 190 eyes of 186 patients with treatment-resistant nAMD. The results showed a significant reduction in CST and an improvement in BCVA after the initiation of faricimab treatment with a tolerated faricimab dosing interval being longer than for the other anti-VEGF agents.<sup>28</sup> Another

retrospective case-controlled series from the USA examined the short-term impact of intravitreal faricimab in 55 nAMD patients who were resistant to previous treatment with aflibercept. The study discovered that faricimab could enhance both visual and anatomical results in about 40% of nAMD patients who had not responded to prior aflibercept treatment.<sup>29</sup>

A retrospective case series from the UK reported on the outcomes of faricimab treatment in nine patients (11 eyes) with nAMD.<sup>30</sup> Treatment-naïve and non-naïve eyes were included. The study revealed a significant improvement in both BCVA and central retinal thickness (CRT) a month following the initial faricimab injection, with a complete resolution of subretinal and intraretinal fluid (SRF and IRF) in 75% and 66.6% of the eyes, respectively. The study also reported improvement or flattening in pigment epithelium detachments in all patients.

A multicentre study in Japan evaluated the effectiveness and safety of faricimab loading therapy (3 injections) in previously untreated eyes (63 eyes of 61 patients) with nAMD including also retinal angiomatous proliferation (RAP, type 3 CNV) and polypoidal choroidal vasculopathy (PCV).<sup>31</sup> The study found that BCVA and CRT improved over the 3 months after the first faricimab treatment, with a complete resolution of IRF and SRF in 82% of the eyes and a complete regression of PCV lesion in 52% of the eyes with PCV at month 3. No ocular or systemic complications were observed except retinal pigment epithelium tears developed in two eyes.

The TRUCKEE study was a multicentre, retrospective study from 14 US sites, which evaluated the efficacy and safety of faricimab in patients with nAMD.<sup>32</sup> Both treatment-naïve patients and those previously treated with other anti-VEGF therapies were included. The study found that all patients who received one injection of faricimab demonstrated a mean BCVA increase of +1.1 letters (0.7 letters in non-naïve eyes vs 4.9 letters in naïve eyes), while after three injections BCVA improved by 3.4 letters (2.7 letters in non-naïve vs 8.1 letters in naïve eyes). The study also reported favourable changes in CST, presence of retinal fluid (complete resolution of SRF and IRF in 25% and 40% of naïve eyes respectively), and PED morphology (41% resolution in naïve eyes). Except for one case of infectious endophthalmitis and one case of intraocular inflammation, both treated successfully with steroids and local antibiotics respectfully, no other significant adverse events were reported suggesting that faricimab is safe and effective in improving visual acuity and macular anatomy in patients with nAMD, including those who had previously received other anti-VEGF treatments.

Finally, another retrospective study from Japan, presented the results of a faricimab loading dose (three monthly injections) in previously untreated eyes (40 eyes) of 38 patients with nAMD.<sup>33</sup> The study found that BCVA, CRT and central choroidal thickness (CCT) significantly improved at week 16, with a complete resolution of IRF and SRF in 79.5% of the eyes and a complete regression of PCV lesions in 61.1% of the eyes with PCV. A comprehensive overview of all studies investigating the use of faricimab in nAMD is presented in [Table 1](#).

## Faricimab in DMO

### Phase II Trials

The BOULEVARD trial, a double-masked, multicentre, phase II study, was designed to compare the effectiveness and safety of faricimab and ranibizumab in patients with DMO.<sup>16</sup> Individuals who had not undergone prior treatment were distributed evenly to receive either 6 mg of faricimab, 1.5 mg of faricimab, or 0.3 mg of ranibizumab every 4 weeks. For those who had previously been treated with anti-VEGF therapy, they were allocated in equal proportions to receive either 6 mg of faricimab or 0.3 mg of ranibizumab every 4 weeks. All participants received monthly doses until Week 20, after which a period of observation was conducted until Week 36 to evaluate the durability of the treatment. The main objective was to evaluate the mean BCVA changes from baseline to the 24th week in patients who were undergoing treatment for the first time. Secondary outcomes included anatomical and safety outcomes.

The trial achieved its primary outcome, with patients who received faricimab 6 mg demonstrating a statistically significant improvement in mean BCVA compared to those who received ranibizumab. Both in patients who had not previously received treatment and in those who had, faricimab treatment led to a dose-dependent reduction in CST and diabetic retinopathy severity scale scores. Moreover, the interval until the need for retreatment was extended in the faricimab group compared to the ranibizumab group during the monitoring phase. Faricimab did not present any unforeseen safety concerns during the study, and no incidents of intraocular inflammation, endophthalmitis, or retinal

**Table 1** Summary of the Studies on Faricimab in nAMD

Study	Design	Number of Patients	Key Findings
STAIRWAY <sup>14</sup>	Phase 2 randomised clinical trial	76 patients mean age: 78.5 years, 58% women, 97% white	<ul style="list-style-type: none"> <li>• After 24 weeks, no disease activity was observed in 65% of all participants treated with faricimab.</li> <li>• By the 40th week, the average BCVA gains from the starting point were +11.4, +9.3, and +12.5 for the groups receiving ranibizumab Q4W, faricimab Q12W, and faricimab Q16W, respectively.</li> <li>• On average, participants received 12.9, 6.7, and 6.2 injections for the ranibizumab Q4W, faricimab Q12W, and faricimab Q16W groups, respectively, over the course of 52 weeks.</li> <li>• Faricimab administered every 12 or 16 weeks maintained initial vision and anatomical improvements on par with monthly ranibizumab at the 52-week mark.</li> <li>• There were no unexpected or new safety concerns identified.</li> </ul>
TENAYA and LUCERNE <sup>19</sup>	Phase 3 randomised clinical trials	1329 patients from 271 sites	<ul style="list-style-type: none"> <li>• Faricimab demonstrated non-inferiority to aflibercept in both the TENAYA and LUCERNE trials, meeting the primary endpoints.</li> <li>• The changes in BCVA between the treatment arms were within the non-inferiority margin of four letters.</li> <li>• 78% of patients in both studies achieved dosing intervals of 12 weeks or more</li> <li>• 45% of patients reached the maximum dosing interval of 16 weeks by Year 1</li> <li>• Faricimab treatment resulted in a reduction in CST similar to the aflibercept group.</li> <li>• The occurrence of eye-related side effects was similar across all groups and consistent with expected effects in people receiving intravitreal nAMD treatment.</li> <li>• No cases of retinal vasculitis or retinal occlusive events were reported in the studies.</li> </ul>
Mori et al <sup>26</sup>	Subgroup analysis of the Phase 3 TENAYA trial	133 Japanese patients	<ul style="list-style-type: none"> <li>• The average change in BCVA was an increase of +7.1 letters for the faricimab group and +7.7 letters for the aflibercept group.</li> <li>• At week 48, the faricimab group had 66.1% of patients on a 16-week dosing interval, 22.6% on a 12-week interval, and 11.3% on an 8-week interval.</li> <li>• The occurrence of ocular adverse events was similar between the two treatment groups, with 21.2% in the faricimab group and 25.4% in the aflibercept group.</li> <li>• Faricimab administered Q16W demonstrated sustained efficacy and an acceptable safety profile, aligning with the global findings from the TENAYA and LUCERNE studies.</li> </ul>
Stanga et al <sup>30</sup>	Retrospective, observational study	9 patients (11 eyes)	<ul style="list-style-type: none"> <li>• Mean BCVA improved from 0.612±0.75 logMAR to 0.387±0.54 logMAR at month 1 after the switch to faricimab</li> <li>• Mean CRT decreased from 256.16±12.98µm to 245.43±15.34µm at month 1 after the switch to faricimab.</li> <li>• Mean BCVA improved from 0.33±0.29 logMAR to 0.30±0.29 logMAR in treatment naive eyes at month 1</li> <li>• Mean CRT decreased from 874.67±510.86µm to 536.04±36.15µm in treatment naive eyes at month 1</li> <li>• Complete resolution of SRF was observed in 75% of the eyes and of IRF in 66.67% of the eyes.</li> </ul>
Rush and Rush <sup>29</sup>	Retrospective, case-controlled series	55 patients	<ul style="list-style-type: none"> <li>• 39.3% (11 out of 28) of the Study Group achieved a CMT of less than 300µm without retinal fluid on OCT, compared to 7.4% (2 out of 27) in the Control Group, at month 4.</li> <li>• 35.7% (10 out of 28) of the Study Group experienced a gain of 2 or more lines of BCVA at month 4, compared to 7.4% (2 out of 27) in the Control Group.</li> </ul>

(Continued)

Table I (Continued).

Study	Design	Number of Patients	Key Findings
Leung et al <sup>28</sup>	Retrospective study	186 patients (190 eyes)	<ul style="list-style-type: none"> <li>The average BCVA improved from 0.33±0.32 logMAR to 0.27±0.32 logMAR.</li> <li>The CST improved from 312±87µm to 287±71µm.</li> <li>24% of patients had no subretinal fluid or intraretinal fluid on OCT at last visit.</li> <li>The average dosing interval between the last two consecutive faricimab injections was 7.64±6.2 weeks, which was significantly longer than that for ranibizumab (5.16 ±2.0 weeks) or aflibercept (5.57±3.6 weeks).</li> <li>No patients developed idiopathic intraocular inflammation.</li> </ul>
Matsumoto et al <sup>33</sup>	Retrospective study	38 patients (40 eyes)	<ul style="list-style-type: none"> <li>BCVA improved significantly from 0.33 ± 0.41 to 0.22 ± 0.36 by week 16.</li> <li>Foveal thickness reduced significantly from 278 ± 116 µm at baseline to 173 ± 48 µm at week 16.</li> <li>CCT decreased significantly from 214 ± 98 µm at baseline to 192 ± 89 µm at week 16.</li> <li>By week 16, a dry macula was achieved in 79.5% of the eyes (31 out of 39).</li> <li>After the loading phase, complete regression of polypoidal lesions was observed in 61.1% of eyes (11 out of 18) with PCV.</li> <li>One eye (2.5%) experienced vitritis without loss of vision at week 16.</li> </ul>
TRUCKEE study <sup>32</sup>	Real –world, multicentre, retrospective study	335 patients (376 eyes) from 14 sites	<ul style="list-style-type: none"> <li>Following the first faricimab injection, all eyes (n=376) showed a BCVA improvement of +1.1 letters (p=0.035) and a CST reduction of –31.3µm (p&lt;0.001).</li> <li>In previously-treated eyes (n=337), there was a BCVA improvement of +0.7 letters (p=0.196) and a CST reduction of 25.3µm (p&lt;0.001).</li> <li>Treatment-naïve eyes (n=39) demonstrated a BCVA improvement of +4.9 letters (p=0.076) and a CST reduction of 84.5µm (p&lt;0.001).</li> <li>After three faricimab injections, all eyes (n=94) showed a BCVA improvement of +3.4 letters (p=0.03) and a CST reduction of 43.4µm (p&lt;0.001).</li> <li>In previously-treated eyes (n=81), there was a BCVA improvement of +2.7 letters (p=0.045) and a CST reduction of 38.1µm (p&lt;0.001).</li> <li>Treatment-naïve eyes (n=13) demonstrated a BCVA improvement of +8.1 letters (p=0.437) and a CST reduction of 80.1µm (p&lt;0.204).</li> <li>One case of intraocular inflammation was reported after four faricimab injections, which resolved with topical steroids.</li> <li>One case of infectious endophthalmitis was treated with intravitreal antibiotics and resolved.</li> </ul>
Mukai et al <sup>31</sup>	Retrospective, multicentre study	61 patients (63 eyes)	<ul style="list-style-type: none"> <li>82% of the eyes achieved a dry macula at month 3, defined as the absence of intraretinal or subretinal fluid.</li> <li>Complete regression of polypoidal lesions was observed in 52% of eyes with PCV.</li> <li>There was a significant decrease in subfoveal choroidal thickness at 1, 2, and 3 months compared to the baseline (p &lt; 0.0001).</li> <li>Retinal pigment epithelium tears developed in two eyes, but no other ocular or systemic complications were observed.</li> </ul>

**Abbreviations:** BCVA, Best Corrected Visual Acuity; CST, Central Subfield Thickness; CRT, Central Retinal Thickness; CMT, Central Macular Thickness; OCT, Optical Coherence Tomography; AMD, Age-related Macular Degeneration; PCV, Polypoidal Choroidal Vasculopathy; SRF, Subretinal Fluid; IRF, Intraretinal Fluid.

detachment were reported. The results of the BOULEVARD trial suggest that faricimab, which bispecifically targets Ang-2 and VEGF, may provide extended durability in DMO compared to anti-VEGF monotherapy.

## Phase III Trials

Two international phase III studies, YOSEMITE and RHINE, were started to further evaluate faricimab in DMO as a result of the promising results from the BOULEVARD trial.<sup>34</sup> These trials, which were identical in design, were randomised, double-masked, and aimed to establish non-inferiority to standard aflibercept therapy. Both studies included treatment-naïve as well as patients who had undergone prior treatment. Participants were divided evenly into three

groups: one group received faricimab 6 mg every 8 weeks (Q8W), another received faricimab 6 mg based on a customised treatment interval with adjustable dosing up to every 16 weeks (Q16W), and the last group received aflibercept 2 mg Q8W. From the 12th week onwards, the treatment intervals for the customised treatment group could be extended by 4 weeks (up to Q16W) or shortened by four or 8 weeks (down to Q4W), depending on specific CST and BCVA criteria. To ensure blinding throughout the study, all patients had study visits every 4 weeks (Q4W) and were given placebo injections during non-dosing visits. The primary outcome was the mean BCVA change from the start of the study to the first year, calculated over Weeks 48, 52, and 56. Secondary outcomes included anatomical changes and safety measures. All patients who had received at least one injection were included in the safety analysis.

The YOSEMITE and RHINE studies, both in their first and second years, successfully demonstrated that faricimab treatment groups were non-inferior to the aflibercept group.<sup>34–37</sup> Over the course of these studies, faricimab's durability was consistently highlighted, with over 70% of patients in the customised treatment group extending their dosing interval to 12 weeks or more in the first year, and 78% achieving a dosing interval of 12 weeks or more, and 62% reaching a 16-week dosing interval by the second year.

Anatomically, the groups treated with faricimab demonstrated a significantly greater decrease in mean CST over both years, with a higher proportion of patients achieving DMO absence by the 52nd week in the first year and sustaining this through the second year, in comparison to the group treated with aflibercept. Additionally, patients who received faricimab experienced a quicker resolution of DMO (identified as  $CST < 325 \mu m$ ) and intraretinal fluid compared to those who received aflibercept, across both years. The average number of injections required to first achieve DMO resolution was consistently least in the group receiving faricimab on a customised treatment interval, followed by the group receiving faricimab every 8 weeks, and then the aflibercept group.

Faricimab was well tolerated throughout the two-year period, with a balanced and relatively low occurrence of ocular and systemic adverse events across all treatment groups. No safety issues were detected with the use of faricimab, as evidenced by the low occurrence of intraocular inflammation and the absence of retinal vasculitis across all treatment groups.

In summary, the data from both years of the YOSEMITE and RHINE studies support the conclusion that faricimab is non-inferior to standard anti-VEGF therapy in terms of visual, anatomical, and safety outcomes, with the added benefit of extended dosing intervals.

## Real World Studies

A retrospective real-world study from Japan evaluated the short-term effects of intravitreal faricimab injections on patients with DMO.<sup>38</sup> The authors aimed to assess the visual and anatomical outcomes following the first injection.

The treatment scheme was as needed (*pro re nata*: PRN), and the study followed up with patients for a mean duration of 5.5 months including both naïve and previously treated eyes of 19 patients (21 eyes). The mean number of intravitreal faricimab injections was  $1.6 \pm 0.8$ , with 57% of cases having only one faricimab injection. Of the 21 eyes studied, 15 (71%) continued the faricimab treatment, while the remaining six (29%) switched to other anti-VEGF or steroid drugs due to insufficient CRT decrease, CRT worsening, or side effects.

The mean BCVA did not show any significant changes at any time point; however, CRT improved significantly at 1 month, with 52% and 76% of the eyes having a CRT below  $325 \mu m$  at month 1 and at the final visit, respectively. The study concluded that good vision at baseline was maintained with faricimab treatment in the short term.

A retrospective, case-controlled study conducted in a private practice specialising in vitreoretinal diseases in Amarillo, TX, USA from February to May 2022, aimed to assess the short-term effects of switching patients with DMO from intravitreal aflibercept to intravitreal faricimab when resistance to aflibercept was occurred.<sup>39</sup> This was done in a real-world setting using a personalised OCT-guided treatment protocol.

The study included 51 eyes from 51 patients, 24 in the study group and 27 in the control group. The study group switched from aflibercept to faricimab, while the control group continued on aflibercept. The primary outcome was the percentage of subjects with a central macular thickness (CMT) of less than  $300 \mu m$  on OCT without identifiable retinal oedema, and the secondary outcome was the percentage of subjects whose BCVA improved by two or more lines at the end of the 4-month study.



The results showed that 37.5% of patients in the study group achieved a CMT less than 300  $\mu\text{m}$  without visible retinal oedema on OCT, compared to just 3.7% in the control group. Furthermore, 41.7% of subjects from the study group experienced improvement by two or more lines on BCVA at the end of the study compared to only 11.1% from the control group.

The research findings suggest that transitioning DMO patients, who are unresponsive to aflibercept therapy, to faricimab could result in improved visual and anatomical outcomes for a substantial subset of these patients. This could potentially facilitate extended periods between injection appointments when employing a treat-and-extend approach in a real-world setting.

A comprehensive summary of all studies investigating the use of faricimab in DMO is presented in [Table 2](#).

**Table 2** Summary of the Studies on Faricimab in DMO

Study	Design	Number of Patients	Key Findings
BOULEVARD <sup>16</sup>	Phase 2 Randomized Trial	229 patients (168 treatment-naïve and 61 non-naïve)	<ul style="list-style-type: none"> <li>• In the treatment-naïve group, those treated with 6.0 mg faricimab showed an average improvement of 13.9 ETDRS letters, with a gain of 3.6 letters over those treated with 0.3 mg ranibizumab (<math>P = 0.03</math>).</li> <li>• Patients treated with 1.5 mg faricimab showed an average improvement of 11.7 ETDRS letters from the baseline.</li> <li>• Those treated with 0.3 mg ranibizumab showed an average improvement of 10.3 ETDRS letters from the baseline.</li> <li>• Both treatment-naïve and previously treated patients showed dose-dependent reductions in CST when treated with faricimab.</li> <li>• Improvements in Diabetic Retinopathy Severity Scale (DRSS) score were observed in patients treated with faricimab.</li> <li>• Patients treated with faricimab also demonstrated a longer time to re-treatment during the observation period compared to those treated with ranibizumab.</li> <li>• No new or unexpected safety signals were observed with faricimab treatment.</li> </ul>
YOSEMITE and RHINE <sup>34</sup>	Phase 3 randomised clinical trials	1891 patients	<ul style="list-style-type: none"> <li>• The primary endpoint of non-inferiority was achieved with both faricimab Q8W and faricimab PTI compared to aflibercept Q8W.</li> <li>• The adjusted mean ETDRS letters improvement for faricimab Q8W were 10.7 in YOSEMITE and 11.8 in RHINE, compared to 10.9 and 10.3 for aflibercept Q8W, respectively.</li> <li>• The adjusted mean ETDRS letters improvement for faricimab PTI were 11.6 in YOSEMITE and 10.8 in RHINE.</li> <li>• The incidence of ocular adverse events was comparable across all treatment groups in both studies.</li> </ul>
Rush and Rush <sup>39</sup>	Retrospective study	51 patients	<ul style="list-style-type: none"> <li>• 37.5% (9 out of 24) of the patients in the study group achieved a CMT &lt; 300 <math>\mu\text{m}</math> without retinal fluid on OCT, compared to 3.7% (1 out of 27) in the control group (<math>p=0.001</math>) at month 4.</li> <li>• 41.7% (10 out of 24) of the patients in the study group gained two or more lines of visual acuity compared to 11.1% (3 out of 27) in the control group (<math>p=0.01</math>) at month 4.</li> </ul>
Kusuhara et al <sup>38</sup>	Retrospective study	19 patients (21 eyes)	<ul style="list-style-type: none"> <li>• Mean logMAR BCVA was 0.236 at baseline, 0.204 at 1 month, 0.190 at 3 months, and 0.224 at 6 months (all <math>p &gt; 0.05</math>).</li> <li>• Mean CRT was 400.6 <math>\mu\text{m}</math> at baseline, 346.6 <math>\mu\text{m}</math> at 1 month, 342.1 <math>\mu\text{m}</math> at 3 months, and 327.5 <math>\mu\text{m}</math> at 6 months. CRT significantly decreased from baseline to 1 month (<math>p = 0.001</math>), but the change was not significant over 6 months (<math>p = 0.070</math>).</li> <li>• No significant difference in BCVA or CRT was observed between the treatment-naïve and switch groups.</li> <li>• No serious safety concerns were noted during the study.</li> </ul>

**Abbreviations:** BCVA, Best Corrected Visual Acuity; CST, Central Subfield Thickness; CRT, Central Retinal Thickness; CMT, Central Macular Thickness; OCT, Optical Coherence Tomography; ETDRS, Early Treatment of Diabetic Retinopathy Study; DMO, Diabetic Macular Oedema; PTI, Personalised Treatment Interval.

## Faricimab in RVO-MO

### Phase III Trials

The BALATON and COMINO studies, both of which were randomised trials, allocated participants with RVO-MO (central and branch RVO) to receive either 6.0 mg of faricimab or 2.0 mg of aflibercept through a series of six injections administered monthly over a span of 20 weeks.<sup>40</sup> The primary measure, assessed at the 24-week mark, was successfully met in both trials, with faricimab demonstrating comparable gains in BCVA to aflibercept. The average BCVA improvement from the initial baseline was similar across both treatments in both trials. In BALATON, the faricimab cohort experienced an increase of +16.9 eye chart letters, while the aflibercept cohort experienced an increase of +17.5 letters at the 24-week evaluation. In COMINO, the increases were +16.9 letters and +17.3 letters for the faricimab and aflibercept cohort, respectively, at the same evaluation point. Additionally, the proportion of patients experiencing an improvement of 15 or more letters was similar across treatment cohorts in both studies.

A secondary outcome demonstrated that faricimab led to a rapid and substantial reduction of retinal fluid from the baseline, as indicated by the decrease in CST. In both studies, the CST reductions were similar across treatment cohorts. In the BALATON trials, the reductions were  $-311.4 \mu\text{m}$  in the faricimab cohort and  $-304.4 \mu\text{m}$  in the aflibercept cohort. In the COMINO trial, the reductions were  $-461.6 \mu\text{m}$  and  $-448.8 \mu\text{m}$  in the faricimab and aflibercept cohort, respectively. Furthermore, both studies showed that a higher proportion of faricimab patients had no leakage of blood vessels in the retina compared to patients treated with aflibercept, as observed in a pre-determined explanatory measure. In the BALATON study, 34% of the patients who received faricimab had no leakage compared to 21% of the patients treated with aflibercept. In the COMINO study, the proportions were 44% for faricimab and 30% for aflibercept patients, respectively.

In both studies, the safety parameters of faricimab remained consistent with previous trials. Conjunctival hemorrhage (3%) was the predominant adverse event observed.

The studies are currently in progress, and the findings from the 24th to the 72nd week will evaluate the possibility of extending the faricimab administration schedule to once every 4 months.

### Cost-Effectiveness

A theoretical cost-saving analysis from San Francisco, CA, USA aimed to assess the cost of use of faricimab, ranibizumab, and aflibercept over the first 3 years of initial injection administration.<sup>41</sup> The study took into account the wholesale acquisition prices for the medications, the frequency of the injections in the first 3 years as determined by the drug label, the transportation costs, and the time spent for travel and clinic appointments for both the patient and their carer. The study found that over the first 3 years of treatment, faricimab is less costly than both ranibizumab and aflibercept, even when considering travel distances for patients. The cost difference increases with larger travel distances, for instance, at 100 miles, ranibizumab and aflibercept become \$41,502 and \$7464 more expensive than faricimab, respectively, making faricimab the most cost-effective option among the three treatments.

### Future Directions

Intravitreal administration of anti-VEGF agents is the current gold standard for treating nAMD.<sup>42</sup> However, this treatment method is invasive, potentially painful, and can, potentially, lead to serious ocular and systemic complications.<sup>43</sup> Moreover, long-term intravitreal therapy can impose financial strain on patients and health systems, while the therapeutic response may diminish due to repeated injections. Faricimab emerges as a new treatment tool in the management of nAMD that aims to alleviate this treatment burden. Evidence from clinical studies suggests that faricimab-treated patients exhibit superior anatomical improvement and can maintain comparable visual results with extended injection intervals.

Despite its promise, faricimab shares the limitations of intravitreal therapy. The advent of nanotechnology aims to revolutionise the current treatment approach for AMD. At present, this approach necessitates a constant active release of the anti-VEGF agent to attain maximum therapeutic effect and prevent complications arising from multiple injections.<sup>44</sup> Explorations are underway for nanotechnology-based delivery systems as potential future replacements for intravitreal injections in nAMD treatment. These systems present advantages like enhanced drug bioavailability, targeted drug accumulation, regulated release, and reduced toxicity.

Beyond extended-acting anti-VEGFs like faricimab and sustained-release delivery mechanisms, novel strategies including gene therapy and agents targeting different elements in the angiogenesis process are anticipated to have a substantial impact on the future treatment of nAMD. More specifically, gene therapy through long-lasting VEGF inhibition is currently gaining attention as a potential treatment for nAMD.<sup>45</sup> RGX-314, ADVM-022, and ADVM-032 are among the most promising candidates in this area.<sup>45</sup> However, more advanced clinical trials are necessary to confirm their safety and effectiveness. Additionally, early-stage clinical trials are exploring the role of TGF-beta in preventing the fibrotic stage in the macular area in patients with nAMD and DMO.<sup>46</sup> The results of these studies will help clarify the potential of TGF-beta as a molecular target in these conditions.

The newly-developed molecule, OPT-302, can neutralise VEGF-C and VEGF-D molecules. This innovative approach, supplementing VEGF-A therapy, showed promising results in Phase Ib/2a trials for DMO patients, comparing combination therapy with aflibercept against its monotherapy.<sup>47</sup> In Phase II trials for nAMD patients, the efficacy of OPT-302 combined with ranibizumab was assessed against ranibizumab alone.<sup>48,49</sup> Phase III ShORe and COAST studies are underway, evaluating OPT-302's efficacy in combination with ranibizumab and aflibercept.<sup>50</sup>

Other preliminary studies are exploring tyrosine kinase inhibitors, which target VEGFR, PDGFR, FGFR, and c-kit, for their potential against CNVs.<sup>51</sup> For instance, a phase I study on the oral tyrosine kinase inhibitor X-82 showed that 60% of nAMD patients did not require further anti-VEGF treatment during the follow-up period.<sup>51</sup> However, a temporary elevation of liver enzymes was observed as a side effect. Further advanced-phase trials are required to validate the efficacy of oral tyrosine kinase inhibitors in treating nAMD.

## Conclusion

The evidence gathered from phase III clinical trials and real-world studies indicates that faricimab is a potent treatment option for nAMD. It holds the potential to alleviate the treatment burden associated with this condition. Its application has shown promising outcomes in terms of functional and anatomical improvements in nAMD, DMO and other ocular conditions, such as PCV. However, the exploration of faricimab's efficacy in the treatment of less common conditions like macular telangiectasia and myopic CNV is yet to be undertaken, and it would be intriguing to see future studies investigating these areas.

Moreover, the potential of faricimab in the management of RVO-MO is an area of interest, and we anticipate further studies to shed light on this application. It is also crucial to conduct additional clinical trials or real-world studies to gain a deeper understanding of faricimab's effectiveness and safety profile, particularly in treatment-naïve patients with DMO and nAMD, as well as in patients who have previously been treated with anti-VEGF agents. This patient group (non-naïve) was underrepresented in the pivotal phase III clinical trials, and further research is needed to fully understand faricimab's potential in these contexts.

Unlike some other treatments, faricimab has not been associated with significant safety concerns, which adds to its appeal as a treatment option. However, it remains essential for healthcare professionals to closely monitor their patients and manage any potential adverse events effectively. When deciding on the best course of treatment for nAMD, practitioners should carefully consider the balance between the potential benefits and the demonstrated effectiveness of faricimab.

## Disclosure

Winfried M Amoaku has provided consultancy services to Alcon, Alimera, Allergan (AbbVie), Bayer, Novartis and Roche. The other authors report no conflicts of interest in this work.

## References

1. Wong WL, Su X, Li X, et al. Global prevalence of age-related macular degeneration and disease burden projection for 2020 and 2040: a systematic review and meta-analysis. *Lancet Glob Health*. 2014;2(2):e106–116. doi:10.1016/S2214-109X(13)70145-1
2. Bourne RR, Stevens GA, White RA, et al. Causes of vision loss worldwide, 1990–2010: a systematic analysis. *Lancet Glob Health*. 2013;1(6):e339–349. doi:10.1016/S2214-109X(13)70113-X
3. Mitchell P, Liew G, Gopinath B, Wong TY. Age-related macular degeneration. *Lancet*. 2018;392(10153):1147–1159. doi:10.1016/S0140-6736(18)31550-2

4. Yau JW, Rogers SL, Kawasaki R, et al. Global prevalence and major risk factors of diabetic retinopathy. *Diabetes Care*. 2012;35(3):556–564. doi:10.2337/dc11-1909
5. Rogers S, McIntosh RL, Cheung N, et al. The prevalence of retinal vein occlusion: pooled data from population studies from the United States, Europe, Asia, and Australia. *Ophthalmology*. 2010;117(2):313–319 e311. doi:10.1016/j.ophtha.2009.07.017
6. Supuran CT. Agents for the prevention and treatment of age-related macular degeneration and macular edema: a literature and patent review. *Expert Opin Ther Pat*. 2019;29(10):761–767. doi:10.1080/13543776.2019.1671353
7. Triantafylla M, Massa HF, Dardabounis D, et al. Ranibizumab for the treatment of degenerative ocular conditions. *Clin Ophthalmol*. 2014;8:1187–1198. doi:10.2147/OPHTH.S40350
8. Anguita R, Tasiopoulou A, Shahid S, Roth J, Sim SY, Patel PJ. A review of aflibercept treatment for macular disease. *Ophthalmol Ther*. 2021;10(3):413–428. doi:10.1007/s40123-021-00354-1
9. Karasavvidou EM, Tranos P, Panos GD. Brolucizumab for the treatment of degenerative macular conditions: a review of clinical studies. *Drug Des Devel Ther*. 2022;16:2659–2680. doi:10.2147/DDDT.S378450
10. Moon BH, Kim Y, Kim SY. Twenty years of anti-vascular endothelial growth factor therapeutics in neovascular age-related macular degeneration treatment. *Int J Mol Sci*. 2023;24(16). doi:10.3390/ijms241613004
11. Ferrara N, Gerber HP, LeCouter J. The biology of VEGF and its receptors. *Nat Med*. 2003;9(6):669–676. doi:10.1038/nm0603-669
12. Pham B, Thomas SM, Lillie E, et al. Anti-vascular endothelial growth factor treatment for retinal conditions: a systematic review and meta-analysis. *BMJ Open*. 2019;9(5):e022031. doi:10.1136/bmjopen-2018-022031
13. Mettu PS, Allingham MJ, Cousins SW. Incomplete response to Anti-VEGF therapy in neovascular AMD: exploring disease mechanisms and therapeutic opportunities. *Prog Retin Eye Res*. 2021;82:100906. doi:10.1016/j.preteyeres.2020.100906
14. Khanani AM, Patel SS, Ferrone PJ, et al. Efficacy of every four monthly and quarterly dosing of faricimab vs ranibizumab in neovascular age-related macular degeneration: the STAIRWAY Phase 2 randomized clinical trial. *JAMA Ophthalmol*. 2020;138(9):964–972. doi:10.1001/jamaophthalmol.2020.2699
15. Peyrin-Biroulet L, Demarest S, Nirula A. Bispecific antibodies: the next generation of targeted inflammatory bowel disease therapies. *Autoimmun Rev*. 2019;18(2):123–128. doi:10.1016/j.autrev.2018.07.014
16. Sahni J, Patel SS, Dugel PU, et al. Simultaneous inhibition of angiopoietin-2 and vascular endothelial growth factor-A with faricimab in diabetic macular edema: BOULEVARD phase 2 randomized trial. *Ophthalmology*. 2019;126(8):1155–1170. doi:10.1016/j.ophtha.2019.03.023
17. Regula JT, Lundh von Leithner P, Foxton R, et al. Targeting key angiogenic pathways with a bispecific CrossMab optimized for neovascular eye diseases. *EMBO Mol Med*. 2016;8(11):1265–1288. doi:10.15252/emmm.201505889
18. Nair AA, Finn AP, Sternberg P. Spotlight on faricimab in the treatment of wet age-related macular degeneration: design, development and place in therapy. *Drug Des Devel Ther*. 2022;16:3395–3400. doi:10.2147/DDDT.S368963
19. Heier JS, Khanani AM, Quezada Ruiz C, et al. Efficacy, durability, and safety of intravitreal faricimab up to every 16 weeks for neovascular age-related macular degeneration (TENAYA and LUCERNE): two randomised, double-masked, phase 3, non-inferiority trials. *Lancet*. 2022;399(10326):729–740. doi:10.1016/S0140-6736(22)00010-1
20. Jousen AM, Ricci F, Paris LP, Korn C, Quezada-Ruiz C, Zarbin M. Angiopoietin/Tie2 signalling and its role in retinal and choroidal vascular diseases: a review of preclinical data. *Eye*. 2021;35(5):1305–1316. doi:10.1038/s41433-020-01377-x
21. Foxton RH, Uhles S, Gruner S, Revelant F, Ullmer C. Efficacy of simultaneous VEGF-A/ANG-2 neutralization in suppressing spontaneous choroidal neovascularization. *EMBO Mol Med*. 2019;11(5). doi:10.15252/emmm.201810204
22. Chakravarthy U, Bailey C, Brown D, et al. Phase I trial of anti-vascular endothelial growth factor/anti-angiopoietin 2 bispecific antibody RG7716 for neovascular age-related macular degeneration. *Ophthalmol Retina*. 2017;1(6):474–485. doi:10.1016/j.oret.2017.03.003
23. FDA US. VABYSMO™ (faricimab-svoa) injection, for intravitreal use - US prescribing information; 2022. Available from: [https://www.accessdata.fda.gov/drugsatfda\\_docs/label/2022/761235s000lbl.pdf](https://www.accessdata.fda.gov/drugsatfda_docs/label/2022/761235s000lbl.pdf). Accessed September 11, 2023.
24. Roche. Vabysmo: product Monograph Including Patient Medication Information; 2022. Available from: [https://www.roche.ca/content/dam/rochexx/roche-ca/products/ConsumerInformation/MonographsandPublicAdvisories/vabysmo/Vabysmo\\_PM\\_E.pdf](https://www.roche.ca/content/dam/rochexx/roche-ca/products/ConsumerInformation/MonographsandPublicAdvisories/vabysmo/Vabysmo_PM_E.pdf). Accessed September 11, 2023.
25. Sahni J, Dugel PU, Patel SS, et al. Safety and efficacy of different doses and regimens of faricimab vs ranibizumab in neovascular age-related macular degeneration: the AVENUE phase 2 randomized clinical trial. *JAMA Ophthalmol*. 2020;138(9):955–963. doi:10.1001/jamaophthalmol.2020.2685
26. Mori R, Honda S, Gomi F, et al. Efficacy, durability, and safety of faricimab up to every 16 weeks in patients with neovascular age-related macular degeneration: 1-year results from the Japan subgroup of the phase 3 TENAYA trial. *Jpn J Ophthalmol*. 2023;67(3):301–310. doi:10.1007/s10384-023-00985-w
27. Hutton D. Two-year data confirms faricimab improves vision for patients diagnosed with wet-AMD; 2022. Available from: <https://www.opthalmologytimes.com/view/two-year-data-confirms-faricimab-improves-vision-for-patients-diagnosed-with-wet-amd>. Accessed September 11, 2023.
28. Leung EH, Oh DJ, Alderson SE, et al. Initial real-world experience with faricimab in treatment-resistant neovascular age-related macular degeneration. *Clin Ophthalmol*. 2023;17:1287–1293. doi:10.2147/OPHTH.S409822
29. Rush RB, Rush SW. Intravitreal faricimab for aflibercept-resistant neovascular age-related macular degeneration. *Clin Ophthalmol*. 2022;16:4041–4046. doi:10.2147/OPHTH.S395279
30. Stanga PE, Valentin-Bravo FJ, Stanga SEF, Reinstein UI, Pastor-Idoate S, Downes SM. Faricimab in neovascular AMD: first report of real-world outcomes in an independent retina clinic. *Eye*. 2023. doi:10.1038/s41433-023-02505-z
31. Mukai R, Kataoka K, Tanaka K, et al. Three-month outcomes of faricimab loading therapy for wet age-related macular degeneration in Japan. *Sci Rep*. 2023;13(1):8747. doi:10.1038/s41598-023-35759-4
32. Khanani AM, Aziz AA, Khan H, et al. The real-world efficacy and safety of faricimab in neovascular age-related macular degeneration: the TRUCKEE study - 6 month results. *Eye*. 2023. doi:10.1038/s41433-023-02553-5
33. Matsumoto H, Hoshino J, Nakamura K, Nagashima T, Akiyama H. Short-term outcomes of intravitreal faricimab for treatment-naive neovascular age-related macular degeneration. *Graefes Arch Clin Exp Ophthalmol*. 2023. doi:10.1007/s00417-023-06116-y
34. Wykoff CC, Abreu F, Adamis AP, et al. Efficacy, durability, and safety of intravitreal faricimab with extended dosing up to every 16 weeks in patients with diabetic macular oedema (YOSEMITE and RHINE): two randomised, double-masked, phase 3 trials. *Lancet*. 2022;399(10326):741–755. doi:10.1016/S0140-6736(22)00018-6

35. Bauml CR, Kitchens J, Jaffe G, et al. Personalized treatment interval (PTI) dosing dynamics over 2 years in the phase 3 YOSEMITE and RHINE trials of faricimab in diabetic macular edema. *Invest Ophthalmol Vis Sci.* 2022;63(7):3851.
36. Schlottmann P, Wells JA, Haskova Z, et al. Efficacy, durability and safety of faricimab in diabetic macular edema: 2-year results from the phase 3 YOSEMITE and RHINE Trials. *Invest Ophthalmol Vis Sci.* 2022;63(7):3850. Hamburg.
37. Korobelnik JF, Jaffe GJ, Gerendas BS, et al. Personalised treatment interval (PTI) dosing dynamics over 2 years in the phase 3 YOSEMITE and RHINE trials of faricimab in diabetic macular edema. *Invest Ophthalmol Vis Sci.* 2022;63(7):3851. Hamburg.
38. Kusuhara S, Kishimoto-Kishi M, Matsumiya W, Miki A, Imai H, Nakamura M. Short-term outcomes of intravitreal faricimab injection for diabetic macular edema. *Medicina.* 2023;59(4). doi:10.3390/medicina59040665
39. Rush RB, Rush SW. Faricimab for treatment-resistant diabetic macular edema. *Clin Ophthalmol.* 2022;16:2797–2801. doi:10.2147/OPTH.S381503
40. Tadayoni R, Paris LP, Abreu F, et al. Faricimab in RVO: results from the BALATON and COMINO phase 3 studies. *Angiogenesis Degener.* 2023;2023:1.
41. Meer EA, Oh DH, Brodie FL. Time and distance cost of longer acting anti-VEGF therapies for macular degeneration: contributions to drug cost comparisons. *Clin Ophthalmol.* 2022;16:4273–4279. doi:10.2147/OPTH.S384995
42. Wykoff CC, Clark WL, Nielsen JS, Brill JV, Greene LS, Heggen CL. Optimizing anti-VEGF treatment outcomes for patients with neovascular age-related macular degeneration. *J Manag Care Spec Pharm.* 2018;24(2):S3–S15. doi:10.18553/jmcp.2018.24.2-a.s3
43. Falavarjani KG, Nguyen QD. Adverse events and complications associated with intravitreal injection of anti-VEGF agents: a review of literature. *Eye.* 2013;27(7):787–794. doi:10.1038/eye.2013.107
44. Yang B, Li G, Liu J, et al. Nanotechnology for age-related macular degeneration. *Pharmaceutics.* 2021;13(12):2035. doi:10.3390/pharmaceutics13122035
45. Guimaraes TAC, Georgiou M, Bainbridge JWB, Michaelides M. Gene therapy for neovascular age-related macular degeneration: rationale, clinical trials and future directions. *Br J Ophthalmol.* 2021;105(2):151–157. doi:10.1136/bjophthalmol-2020-316195
46. Tosi GM, Orlandini M, Galvagni F. The controversial role of TGF-beta in neovascular age-related macular degeneration pathogenesis. *Int J Mol Sci.* 2018;19(11):3363. doi:10.3390/ijms19113363
47. Boyer DS. Phase 1b/2a DME Study Results of OPT-302 to Block VEGF-C/-D in Combination with Aflibercept. In: Proceedings of the American Academy of Ophthalmology Annual Meeting; Las Vegas, NV, USA; 2020.
48. Jackson TL, Slakter J, Buyse M, et al. A Randomized Controlled Trial of OPT-302, a VEGF-C/D Inhibitor for neovascular age-related macular degeneration. *Ophthalmology.* 2023;130(6):588–597. doi:10.1016/j.ophtha.2023.02.001
49. Dugel PU, Boyer DS, Antoszyk AN, et al. Phase 1 Study of OPT-302 inhibition of vascular endothelial growth factors C and D for neovascular age-related macular degeneration. *Ophthalmol Retina.* 2020;4(3):250–263. doi:10.1016/j.oret.2019.10.008
50. Patel P, Sheth V. New and innovative treatments for neovascular age-related macular degeneration (nAMD). *J Clin Med.* 2021;10(11):2436. doi:10.3390/jcm10112436
51. Pedersen KS, Grierson PM, Picus J, et al. Voralanib (X-82), an oral anti-VEGFR/PDGFR/CSF1R tyrosine kinase inhibitor, with everolimus in solid tumors: results of a phase I study. *Invest New Drugs.* 2021;39(5):1298–1305. doi:10.1007/s10637-021-01093-7

## Drug Design, Development and Therapy

Dovepress

### Publish your work in this journal

Drug Design, Development and Therapy is an international, peer-reviewed open-access journal that spans the spectrum of drug design and development through to clinical applications. Clinical outcomes, patient safety, and programs for the development and effective, safe, and sustained use of medicines are a feature of the journal, which has also been accepted for indexing on PubMed Central. The manuscript management system is completely online and includes a very quick and fair peer-review system, which is all easy to use. Visit <http://www.dovepress.com/testimonials.php> to read real quotes from published authors.

Submit your manuscript here: <https://www.dovepress.com/drug-design-development-and-therapy-journal>