

Gastric Prolapse with Pseudocysts Following Laparoscopic Adjustable Gastric Banding

Jason A. Glenn, MD, Gezzer Ortega, MD, Dani O. Gonzalez, BS, Jasmine A. Reed, BS, Patricia L. Turner, MD, Daniel D. Tran, MD, Stephen McKenna, MD, Christine C. Bauer, RN, MSN, CNS, CBN, Terrence M. Fullum, MD

ABSTRACT

Introduction: Laparoscopic adjustable gastric banding (LAGB) is a reversible method of surgical gastric restriction. Following LAGB, the adverse event most commonly necessitating subsequent reoperation is prolapse of the gastric corpus or fundus above the band. A review of the medical literature reveals no reports of nonpancreatic pseudocysts being associated with this adverse event. Nonpancreatic pseudocysts, encountered during revisional bariatric surgery should be considered a cause of irreducible gastric prolapse.

Case Report: We report the case of a 41-year-old Caucasian female who underwent laparoscopic surgery to revise an adjustable gastric band and to repair an anterior gastric prolapse. Intraoperatively, 2 pseudocysts were found on the gastric fundus above the band in association with the gastric prolapse. The pseudocysts were resected, the gastric prolapse was reduced, and the band was left in place. The patient recovered uneventfully.

Conclusion: Nonpancreatic pseudocysts may be associated with gastric prolapse in patients who have undergone LAGB. These pseudocysts can often be excised laparoscopically without violating the gastric lumen. This atypical presentation of gastric prolapse may pose a diagnostic and therapeutic challenge as these patients may

present to an outpatient clinic or emergency room with nonspecific symptoms.

Key Words: Pseudocyst, Laparoscopic adjustable gastric band, Gastric prolapse, Pars flaccida.

INTRODUCTION

Laparoscopic adjustable gastric banding (LAGB) is a popular bariatric surgery ($\approx 300,000$ performed worldwide from 2001 to 2007¹), which is indicated for weight reduction in severely obese patients. The adjustable gastric band was approved by the United States Food and Drug Administration (FDA) in June 2001, for patients who have failed trials of medical weight loss, and who have a body mass index (BMI) $\geq 40\text{kg/m}^2$, or a BMI $\geq 35\text{kg/m}^2$ with one or more severe comorbidities, or weigh ≥ 100 pounds above their estimated ideal body weight.² Once inserted, the device creates a restricted gastric opening and a small gastric pouch that limits food consumption and promotes early satiety.

Although band placement has the advantage of being adjustable and reversible when compared to other bariatric surgeries, LAGB has been associated with adverse events in the acute and long-term settings.³ As reported by the FDA, during the course of the LAP-BAND System US clinical trial (1997 through 2001), 89% of the 299 subjects reported at least one adverse event. The most commonly reported events were nausea/vomiting (51%), gastroesophageal (GE) reflux (34%), abdominal pain (27%), band slippage/pouch dilation (24%), stoma obstruction (14%), and dysphagia (9%). At 3 years, 9% of the 299 subjects had subsequently required revision surgery of their gastric band.² These trends were further characterized by Mittermair et al in 2009, when it was reported that of 733 LAGB patients who completed a 10-year follow-up in Sweden, 50.4% of these patients reported at least one complication and 32% required revision surgery.⁴

Gastric prolapse and/or band slippage is the most common complication of LAGB necessitating reoperation.⁵ It is often due to improper surgical fixation, premature re-introduction of solid food postoperatively, excessive band

Howard University College of Medicine, Washington, DC, USA (Drs. Glenn, Gonzalez).

Howard University Hospital Division of Bariatric and Minimally Invasive Surgery, Washington, DC, USA (Drs. Ortega, Tran, Fullum).

Syracuse University, Syracuse, New York, USA (Ms. Reed).

University of Maryland School of Medicine, Baltimore, Maryland, USA (Dr. Turner).

Upper Chesapeake Bariatric Surgery, Harford Memorial Hospital, Havre De Grace, Maryland, USA (Ms. Bauer).

Address correspondence to: Terrence M. Fullum, MD, FACS, Associate Professor of Surgery, Howard University College of Medicine, 2041 Georgia Ave, NW, Tower Suite 4100-B, Washington, DC 20060, USA. Telephone: (202) 865-1286, Fax: (202) 865-3063

DOI: 10.4293/108680811X13176785204436

© 2011 by JSLs, *Journal of the Society of Laparoendoscopic Surgeons*. Published by the Society of Laparoendoscopic Surgeons, Inc.

inflation, or recurrent vomiting. Gastric prolapse can represent a surgical emergency, which has been associated with cases of gastric necrosis, obstruction, esophageal or gastric dilatation with perforation, malnutrition, and dehydration.⁵ Gastric prolapse poses a diagnostic challenge for both surgeons and nonsurgeons, because the symptoms are often nonspecific. In a review of gastric prolapse-related events, pseudocyst development on the gastric wall has not been previously described. As such, the potential of pseudocyst formation as a complication of LAGB needs to be further characterized and evaluated. The purpose of this case report is to document this adverse event, so that future occurrences can help to clarify any confounding factors, predisposed patient population, and treatment of choice.

CASE REPORT

History

In October 2009, a 41-year-old Caucasian female with a history of Class II Obesity, hypertension, hypercholesterolemia, obstructive sleep apnea, gastroesophageal reflux disease, and depression, presented 18 months after undergoing LAGB. The LAP-BAND Advanced Platform (AP) System standard band was placed via the pars flaccida (PF) technique with the position confirmed by a postoperative upper GI series. At this presentation, she developed symptoms of persistent dysphagia, nausea, vomiting, regurgitation, and failure to thrive with 3.2mL of saline in her band (BMI=22.1kg/m², down from 35.8kg/m² at initial operation). Although the patient had been properly educated on food portion size and follow-up procedure, she was non-compliant. She experienced episodic vomiting and regurgitation from ingesting large food portions. A routine, single contrast upper GI barium series showed, severe gastroesophageal (GE) reflux and delayed emptying through the gastric band. A significant portion of the gastric fundus was found above the band, strongly indicative of a gastric prolapse. There were no strictures, ulcerations, or dilatation of the esophagus. EGD was remarkable for Grade II erosive reflux-induced esophagitis, but the gastric prolapse was not appreciated. The patient was informed of the band slippage and the need for surgical intervention. However, she declined to have the surgery at this time. The remaining saline was removed from the band but her symptoms failed to resolve. Three months later, the patient consented to surgery.

Operative Report (January 2010)

Using a laparoscopic approach, the gastric prolapse could not be reduced despite the freeing of multiple dense adhesions around the band and the gastric pouch (**Figure 1**). We discovered 2 moderately firm masses on the gastric pouch above the band, which were initially thought to be bezoars. These masses prevented the reduction of the gastric fundus (**Figure 2**). Intraoperative endoscopy was performed. The gastric mucosa appeared normal with no evidence of ischemia. No apparent connection was found between the lumen of the pouch and the masses. After careful inspection, we concluded that these masses were

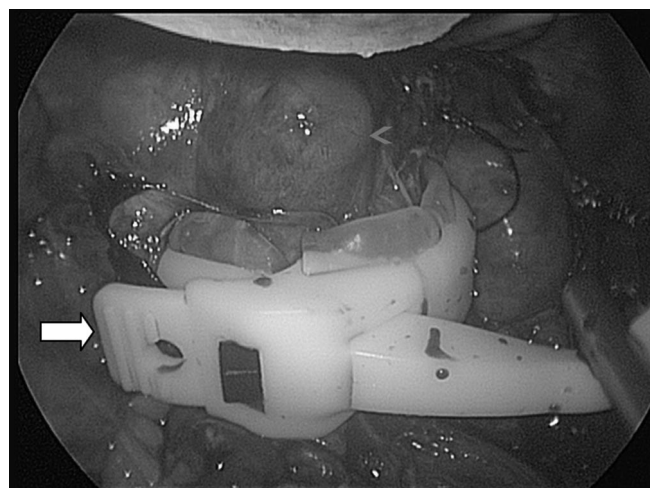


Figure 1. Initial laparoscopic view of gastric band (white arrow), demonstrating prolapse with associated mass (blue arrowhead).

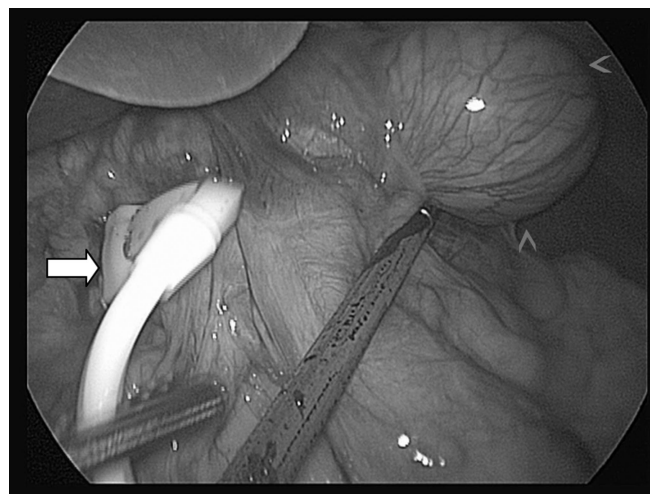


Figure 2. After opening the gastric band (white arrow) and freeing the stomach of adhesions, a 4.4x3.6x3.0-cm fundal pseudocyst (blue arrowheads) is clearly visible.

extraluminal on the wall of the gastric pouch. One of the masses was pedunculated and was connected to the gastric wall via a broad stalk (**Figure 3**). Resection of the mass was performed using a linear stapler. The specimen was removed and inspected. It appeared to be cystic in nature. Incision into the mass was performed, which produced a clear serous fluid. The fluid did not appear to be infected, and the gram stain proved negative.

Satisfied that the cyst was not infected, we concluded that the band could be safely left in place. The second cystic mass had a wider base but was resected and removed in a similar fashion. At no time was there any air leak or bubbles from the insufflated stomach. The stomach was then deflated, and the gastric prolapse could now be completely reduced. Pathologic evaluation of the cysts (4.4 x 3.6 x 3.0cm and 6.1 x 3.5 x 0.3cm) revealed fibrous walls with acute and chronic inflammation, granulation tissue, areas of necrosis, and no gastric mucosa. Postoperatively, the patient recovered remarkably well with resolution of dysphagia and vomiting.

DISCUSSION

Since the advent of LAGB, improved surgical techniques have significantly reduced the frequency and severity of early and late postoperative complications. The widespread adoption of the pars flaccida (PF) technique of band insertion, over the traditional perigastric (PG) method, has significantly reduced the incidence of gastric prolapse. Early reported incidences of gastric prolapse

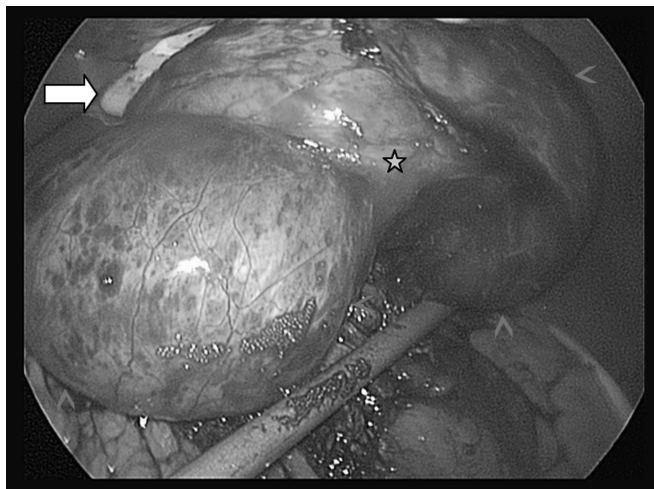


Figure 3. Two pseudocysts (blue arrowheads) and their stalk-like attachments (green stars) to the gastric fundus are visible after blunt dissection and opening of the laparoscopic adjustable gastric band (white arrow).

following PG banding of >25%, have now been reduced to <2% with the PF technique.⁶ However, due to a lack of reported occurrences, it is difficult to determine whether pseudocyst formation is more common following the PG or the PF technique.

The majority of the gastric surface is covered with a single layer of peritoneum, so it does not have the intramembranous space that would predispose it to the development of cysts. Nonpancreatic pseudocysts have thick fibrous walls and lack epithelial lining, such as those seen in our patient. These pseudocysts have been further classified as being either infectious, traumatic, or in rare cases degenerative. Their contents can be chylous or serous, but more commonly are bloody or purulent material. On cytological analysis, the wall characteristically contains inflammation and granulation tissue, with or without calcification or cellular necrosis.⁷ Although, more often associated with either blunt trauma or abscess formation, a few cases have been associated with GI surgeries including partial gastrectomy, gastrojejunostomy, and pyloroplasty.⁸

What these surgeries may have in common with our patient is that due to the trauma of the surgery or a chronically malpositioned band, lymph channels draining the stomach may become disrupted, resulting in a confined extravasation of lymph and blood components, causing a localized inflammatory response in susceptible patients. A laparoscopic approach to excise a pseudocyst is probably favorable, since it is likely to be encountered as an incidental finding during laparoscopic gastric band revision surgery. Extraluminal pseudocysts may be difficult to discern preoperatively with an upper gastrointestinal (GI) series or esophagogastroduodenoscopy (EGD). Therefore, abdominal ultrasound, nuclear imaging, computed tomography, or magnetic resonance imaging may be required for preoperative diagnosis.⁹ With our patient, the pseudocysts were dissected and then enucleated with a linear stapler due to their broad stalk-like base. However, because these pseudocysts are not infectious or neoplastic, if there is a concern for hemorrhage or a difficult excision, methods like marsupialization or fenestration can be used.

In this case, the exact pathogenesis of these nonpancreatic pseudocysts is unclear. They may have played a role in the development of the gastric prolapse, but more likely they were caused by the chronically slipped band in a susceptible patient. We felt that reduction of the prolapse in this patient was not possible until the cysts were resected. There is currently no medical literature reporting the

development of pseudocysts in the plane between the gastric wall and its associated visceral peritoneum. As such, it is difficult to determine how often this adverse event occurs with chronically slipped gastric bands and what the potential complications of pseudocyst formation are.

CONCLUSION

We report a case of nonpancreatic pseudocysts being associated with an anterior gastric prolapse following LAGB. We also report the successful laparoscopic resection of these pseudocysts, and the subsequent reduction of a previously irreducible anterior gastric prolapse. Further data would be needed to define any causal relationship between LAGB, nonpancreatic pseudocysts, gastric prolapse, the surgical technique used, the type of band used, and the time period of band slippage. Its incidental finding as a potential cause of increased gastric restriction and possible interference with spontaneous prolapse reduction has important diagnostic and surgical implications.

References:

1. Favretti F, Segato G, Ashton D, et al. Laparoscopic adjustable gastric banding in 1,791 consecutive obese patients: 12-year results. *Obes Surg.* 2007;17(2):168–175.
2. US Food and Drug Administration. LAP-BAND® Adjustable Gastric Banding (LAGB®) System Summary of Safety and Effectiveness Data. PMA No. P000008. Issued June 5, 2001. Rockville, MD: FDA; June 3, 2002.
3. Lorenzo ND, Furbetta F, Favretti F, et al. Laparoscopic adjustable gastric banding via pars flaccida versus perigastric positioning: technique, complications and results in 2549 patient. *Surg Endosc.* 2010;24(7):1519–1523.
4. Mittermair RP, Obermuller S, Perathoner A, et al. Results and complications after Swedish adjustable gastric banding - 10 year experience. *Obes Surg.* 2009;19(12):1636–1641.
5. Abuzeid AM, Banerjea A, Timmis B, Heshemi M. Gastric slippage as an emergency: diagnosis and management. *Obes Surg.* 2007;17:559–561.
6. Thornton CM, Rozen WM, So D, Kaplan ED, Wilkinson S. Reducing band slippage in laparoscopic adjustable gastric banding: the mesh plication pars flaccida technique. *Obes Surg.* 2009; 19(12):1702–1706.
7. Ros PR, Olmsted WW, Moser RP. Mesenteric and omental cysts: histologic classification with imaging correlation. *Radiology.* 1987;164:327–332.
8. Cizginer S, Tatlt S, Snyder EL, Goldberg JE, Silverman SG. CT and MRI imaging features of a non-pancreatic pseudocyst of the mesentery. *Eur J Gen Med.* 2009;6(1):49–51.
9. Wiesner W, Schob O, Hauser RS, Hauser M. Adjustable laparoscopic gastric banding in patients with morbid obesity: radiographic management, results, and prospective complications. *Radiology.* 2000;216:389–394.